

This is an Open Access document downloaded from ORCA, Cardiff University's institutional repository: <https://orca.cardiff.ac.uk/id/eprint/114078/>

This is the author's version of a work that was submitted to / accepted for publication.

Citation for final published version:

Davies, Kristen and Marshall, Paul 2018. The Ponseti method for the treatment of congenital talipes equinovarus (CTEV). *The British Student Doctor Journal* 2 (2) , pp. 17-23. 10.18573/bsdj.71

Publishers page: <http://dx.doi.org/10.18573/bsdj.71>

Please note:

Changes made as a result of publishing processes such as copy-editing, formatting and page numbers may not be reflected in this version. For the definitive version of this publication, please refer to the published source. You are advised to consult the publisher's version if you wish to cite this paper.

This version is being made available in accordance with publisher policies. See <http://orca.cf.ac.uk/policies.html> for usage policies. Copyright and moral rights for publications made available in ORCA are retained by the copyright holders.



The Ponseti method for the treatment of congenital talipes equinovarus (CTEV)

EDUCATION

AUTHOR

Kristen Davies

Lancaster Medical School

**Mr Paul Marshall FRCS
(Ortho)**

Royal Lancaster Infirmary,
University Hospitals of Morecambe
Bay

Address for Correspondence:

Mr K Davies
Royal Lancaster Infirmary,
University Hospitals of Morecambe
Bay, Lancaster, UK.
Email: k.davies@lancaster.ac.uk

K. Davies is a peer-reviewer for the British Student Doctor Journal and has previously peer-reviewed one submission. P. Marshall has no conflicts of interest to declare.

Accepted for publication: 13.06.18

ABSTRACT

Summary

Congenital talipes equinovarus (CTEV) is the most common musculoskeletal condition in newborns, affecting one-to-two per thousand babies. The Ponseti method is a treatment regime for the management of CTEV which describes a detailed method of manipulation, casting and bracing. Despite its initial publication in 1963, it only started to become popular in the 1990s, coming to UK shores in 1997 when NHS Physiotherapist Steve Wildon widely popularized the method around the country, including in Morecambe Bay. Patients who are treated with the Ponseti method report high levels of satisfaction many years after treatment. The body of literature evaluating the steps of the Ponseti method has grown in the last decade as the technique has become the gold standard treatment for clubfoot. Future research will look at how the Ponseti method can be improved in the management of CTEV.

Relevance

Medical students should be aware of CTEV and understand the steps in management of this common musculoskeletal condition in newborns.

Take Home Messages

- CTEV is the most common musculoskeletal condition in newborns and the current gold standard management is the Ponseti method.
- Ponseti method enables us to correct the majority of clubfeet with its conservative approach.
- Relapses which occur have a good prognosis when treated with surgery in the form of a tibialis anterior tendon transfer.

Introduction

Treatment of Congenital Talipes Equinovarus (CTEV), also known as clubfoot, has changed dramatically over the last twenty years with the introduction of the Ponseti method. This conservative mode of treatment, which involves manipulating joints using casts, was first described by Dr. Ponseti in 1963 (1) at the University of Iowa and is considered to be the most effective method of treating clubfoot worldwide. Ponseti published a further detailed description of his method in 1972 (2) and reported the results of his method in a series of long term studies. (3-5) The recommendations which he made in his first two papers are still valid today with only minor adjustments being made by himself or his colleagues.

Prior to the introduction of the Ponseti method, a number of conservative techniques were used to treat clubfoot. (6) The first documented treatment for clubfoot by Hippocrates was similar to the Ponseti method used today. As early as 400 BC, Hippocrates described managing clubfoot with manipulations and bandages as if the foot was a 'wax model' which needed to be manipulated gently. Treatment options then varied between surgical and conservative management, with popular methods including the Kite method, French method and surgery. (6)

The Ponseti method initially had a slow uptake and has only been accepted widely within the past 15 years, despite its original description 52 years ago. The method now, however, is firmly the choice of management. The Ponseti method was found to be the treatment of choice among members of the Paediatric Orthopaedic Society of North America (POSNA), with 96.7% stating that it was their preferred method for the treatment of idiopathic clubfoot. (7) A series of reviews from around Europe and beyond have also yielded results showing the superiority of the Ponseti method. (8-10) When compared directly to surgical treatment, the Ponseti method has reduced stiffness and increased range of motion of the ankle joint, in addition to not being exposed to the risks of surgery. (11)

Congenital Talipes Equinovarus (CTEV/Clubfoot)

Clubfoot (CTEV) is the most common musculoskeletal condition in newborns, affecting one-to-two per thousand babies. (12) In most cases, the aetiology is unclear, and as such termed idiopathic CTEV. In other cases, it may be associated with a genetic syndrome such as spina bifida. (13) There are a number of hypotheses for the cause of CTEV, such as neuromuscular disease, (14) lack of foetal movement in utero (15) and genetic microduplication. (16) Boys are more affected than girls (2.5:1) (17) and the condition has a 50% chance of being bilateral. (18) It characteristically has four deformities, with forefoot cavus and adductus and hindfoot varus and equinus. (6) This leaves the foot looking like it has been internally rotated with the toes almost facing upwards towards the midline of the body.

From an anatomical point of view, the appearance is due to the talus being distorted and focussed laterally and the navicular being subluxated off the talar head so that it may articulate with the medial malleolus. The ankle and subtalar joints are in a fixed equinus, the calcaneus is in equinus, varus and rotated internally (Figure 1). These changes in the shape and position of the tarsal bones appear to have an excessive pull on the tibialis posterior, gastrocnemius, soleus, tibialis anterior and long toe flexors. The size of the leg muscles is negatively correlated with the severity of the clubfoot and the ligaments in the affected clubfeet are very thick and taut.

Casting and Manipulation

The Ponseti method to correct clubfoot is started within the first couple of weeks from birth. The method involves five-to-eight weeks of leg plaster casts, which run from the toe to the groin, which are changed once a week. Short leg casts are not used as they cannot hold the abduction and have the potential to slip off, recognised to be an important factor in the development of complex clubfoot (feet which significantly shortened with a rigid equinus and severe plantar flexion of all metatarsals). (19) During this time a number of stretches are used to help correct the deformity, which is recommended to be performed prior to casting (Figure 2). Firstly, the cavus is corrected with forefoot supination with pressure applied to the first metatarsophalangeal joint in order to raise it, meaning that the forefoot must be supinated to align it with the hindfoot in order to decrease cavus. The varus is then corrected by rotating the calcaneus and forefoot around the talus, with the head of the talus acting as a fulcrum, so that the foot is pointing now pointing outwards. It is important not to touch the calcaneus as it may block the motion of calcaneus which must be able to move from underneath talus. Finally, the equinus is corrected with stretches to dorsiflex the foot. It is important not to actively dorsiflex the foot prior to subtalar joint correction.

One of the most common errors which occurs during casting and stretching is the inadequate counter pressure on the talus. (20) Talus is very small in infants and is often more superior and anterior than would be expected. If counter pressure is applied too inferiorly or the pressure is over too broad of an area, calcaneus can be blocked and cannot move out from underneath the talus. When this happens, the abducting forces act on Lisfranc joint (the articulation between the midfoot and the forefoot) and the Chopart joint (transverse tarsal joint) causing abduction of the midfoot and possibly the formation of a lateral crease. This is regarded as a red flag during casting. (21)

In terms of the types of cast, Ponseti recommended a thin cast with little padding which should be moulded to the foot. The risk of the cast slipping can be prevented by using a cast with a well moulded heel and one which is high enough to reach the groin with the knee in at least 90° degrees of flexion. The second and third casts carry

the highest risk of slipping off, particularly if patients have a severe equinus and cavus. (21) Casts should only be removed just before the new cast is applied. Premature removal of casts the night before a new one is applied has been shown to result in a higher number of casts being required for correction. (22) The casts are usually changed once a week but accelerated protocols have also been reported; Morcudende et al. (5) found similar success rates when changing the casts every five days and Harnett et al. (23) found similar results when changing casts three times per week compared to a weekly change group. Shorter intervals between cast changes, however, may not be preferable. Pirani et al. suggested that tissues may need a certain amount of time in the corrected position within the cast in order to adapt. (24) This is due to changes in growth as a result of different mechanical loading in fast-growing tissues. (24)

CTEV severity and treatment progress using the Ponseti method is measured using the Pirani score. (25) The score shows whether the deformity is correcting normally or whether there is a problem. Scoring involves looking at six signs, three in the midfoot (such as the lateral head of the talus) and three in the hindfoot, (such as the posterior crease) and a score of 0, 0.5 or 1 is given depending on severity of the deformity. (25) A score of four or more means that the patient is likely to require at least four casts, whereas a purely hindfoot score of 2.5 has a high chance of requiring a tenotomy. (25)

Percutaneous Achilles tenotomy

Following casting, many patients will require a Percutaneous Achilles tenotomy (pAT) to relieve the remaining equinus. A pAT involves releasing the Achilles tendon from its insertion on the calcaneum. Ponseti originally reported that pAT was required in 79% of cases, (1) with subsequent studies reporting rates similar to this (80-90%). (5, 26) Timing of the procedure is crucial to the success of the procedure. Ponseti recommended pAT when there was less than 15-20 degrees of dorsiflexion and when the foot had been abducted to at least 60 degrees. (20) This is necessary as to allow the calcaneus to be able to move out completely from underneath talus, correcting the subtalar misalignment. If pAT is attempted before 60-70 degrees of abduction and before the correction of the subtalar alignment the hindfoot will likely stay uncorrected. After the operation, a post tenotomy cast should be applied and moulded in maximum abduction and dorsiflexion to achieve good correction. If the foot is not dorsiflexed after the tenotomy, this may result in insufficient dorsiflexion once the cast has been removed.

The tenotomy was originally recommended to be performed under local anaesthetic by Ponseti, however, a number of studies have used either local or general anaesthetic with both being found to be safe and effective. (27, 28) A recent review article concluded that pAT can be potentially performed under either local or general anaesthesia with the choice being mostly dependent on the setting

and experience of the staff involved. (21)

Boots and braces

Following the casting and manipulation phases of treatment, the affected feet are fitted with open-toed boots attached to, and connected to one another, via a "Denis Browne bar". The bar-connected brace maintains the corrected foot in 60 to 70 degrees of external rotation on the affected side and in 30 to 40 degrees of external rotation on the normal side. The bar should be bent from 5 to 10 degrees and hold the feet in a valgus position with sufficient length so that the heels of the shoes are the same as the width of the shoulders. (29) Whilst wearing the brace, the shoes maintain the foot in 10 to 15 degrees of dorsiflexion. (30) Although the foot appears to be 'over-corrected' into abduction whilst in the brace, the result is not a real overcorrection but full abduction. (30)

Initially, Ponseti had described the use of such a foot abduction orthosis (FAO) following three months of a full time brace for an additional twenty-one months (average mean duration). (1) Ponseti found that this yielded a high recurrence rate and recommended that the FAO to be used at night for a number of years in his second paper. (2) These shoes are required to be worn for twenty-three hours a day for the following three months and then during the night for approximately four years. Following successful management with the Ponseti method, the patient has a pain-free, functional foot with good mobility. They are able to wear non-modified shoes.

One of the most significant risk factors for relapse of clubfoot after correction is non-compliance with the boots, with parental educational level being an important factor. (31) Studies have looked into ways of improving compliance, with the use of a dynamic brace (32) and using strategies to educate the parents and provide written instructions (33) both resulting in a higher level of compliance.

Results of treatment

The Ponseti method has been found to yield very good results for correcting clubfoot with an initial success rate of 90% (1) and 98% reported. (5) 90% of a group of patients Ponseti treated with his method were also found to be satisfied with the function and appearance of their feet when followed up nineteen years later. (3) Some of these patients were followed up a further eleven years later showed no deterioration of the appearance or function of their feet. (4)

Despite the high success rate using the Ponseti method, complications may arise. Overcorrection has been reported as a common complication with one study reporting 12.2% of feet being left with a valgus overcorrection. Overcorrection was also found to be a significant predictor of pain complaints following Ponseti therapy ($p < 0.001$). (34)

For patients who relapse, a tibialis anterior tendon transfer is recommended. This procedure was found to be performed in 21% of feet treated by Ponseti in a follow-up study. (35) A similar figure has been found in other studies. (36, 37) The procedure is especially recommended if the relapse is mostly dynamic supination and adduction. In this procedure it is recommended that a full transfer to the third cuneiform is performed. (1, 2) Relapse may occur after this procedure though; a recent study reviewed patients treated by tibialis anterior tendon transfer after initially having successful treatment from the Ponseti method. They found that relapse after tibialis anterior tendon transfer occurred in 15% of feet. (38)

Finding its feet in the UK

With over fifty years of use in the United States, the Ponseti method was popularised on British shores in 1997 in the North West with NHS Physiotherapist Steve Wildon. Mr Wildon approached Mr Paul Marshall, the current lead clinician for the Department of Orthopaedics and Trauma at the Royal Lancaster Infirmary, to start this form of treatment in the UK. The method has only grown in its use since then with a centre set up in Manchester dedicated to the treatment of clubfoot with the Ponseti method by Miss Naomi Davis, a Consultant Paediatric Orthopaedic Surgeon in Manchester. Miss Davis is a former registrar of Mr Paul Marshall. Miss Davis set up the Ponseti Clinic for Clubfoot Management in Manchester in early 2002.

There are, however, a number of variations in how the Ponseti method is used depending on the part of the country. Comparing the University Hospitals of Morecambe Bay Trust method of implementing the Ponseti method to the method at the Manchester clinic yields a couple of differences. Firstly, in Manchester, the stretches which are used during the casting phase are not performed. Secondly, in Manchester a Plaster of Paris is used compared to a soft cast which is used within the Morecambe Bay trust. Plaster of Paris is a cheaper alternative to the soft cast but it is harder to remove. This may be to do with the number of patients seen at the respective sites, as the Manchester site sees many more clubfeet due to the area it covers compared to the Morecambe Bay site, so more staff are available to remove the cast and having a cheaper cast makes treating these patients more economically viable.

Conclusion

Despite taking a number of decades to become the mainstay of treatment, the Ponseti method enables us to correct the majority of clubfeet with its conservative approach. In addition, the method is popular amongst patients, with follow-up studies from Ponseti showing high rates of satisfaction and no deterioration of appearance of function of the feet. The last decade has highlighted the popularity of the regime, reflected by the increasing body of literature analysing the Ponseti method. Research is now focusing

on making the Ponseti method more effective by aiming for a shorter casting time or a reduced rate of relapse, using techniques such as an accelerated method, (23) adjuvant therapy with Botulinium A toxin (39) and different casting methods. (40)

References

1. Ponseti IV SE. Congenital club foot: the results of treatment. *J Bone Joint Surg Am* 1963;43(A):261-344.
2. Ponseti IV, Campos J. Observations on pathogenesis and treatment of congenital clubfoot. *Clinical orthopaedics and related research*. 1972;84:50-60.
<https://doi.org/10.1097/00003086-197205000-00011>
PMid:5032850
3. Laaveg SJ, Ponseti IV. Long-term results of treatment of congenital club foot. *The Journal of bone and joint surgery American volume*. 1980;62(1):23-31.
<https://doi.org/10.2106/00004623-198062010-00004>
PMid:7351412
4. Cooper DM, Dietz FR. Treatment of idiopathic clubfoot. A thirty-year follow-up note. *The Journal of bone and joint surgery American volume*. 1995;77(10):1477-89.
<https://doi.org/10.2106/00004623-199510000-00002>
PMid:7593056
5. Morcuende JA, Abbasi D, Dolan LA, Ponseti IV. Results of an accelerated Ponseti protocol for clubfoot. *Journal of pediatric orthopedics*. 2005;25(5):623-6.
<https://doi.org/10.1097/01.bpo.0000162015.44865.5e>
PMid:16199943
6. Miedzybrodzka Z. Congenital talipes equinovarus (clubfoot): a disorder of the foot but not the hand. *Journal of anatomy*. 2003;202(1):37-42.
<https://doi.org/10.1046/j.1469-7580.2003.00147.x>
PMid:12587918 PMCID:PMC1571059
7. Zions LE, Sangiorgio SN, Ebramzadeh E, Morcuende JA. The current management of idiopathic clubfoot revisited: results of a survey of the POSNA membership. *Journal of pediatric orthopedics*. 2012;32(5):515-20.
<https://doi.org/10.1097/BPO.0b013e318259ff79>
PMid:22706469
8. Chotel F, Parot R, Durand JM, Garnier E, Hodgkinson I, Berard J. [Initial management of congenital varus equinus clubfoot by Ponseti's method]. *Revue de chirurgie orthopedique et reparatrice*

de l'appareil moteur. 2002;88(7):710-7.

9. Tindall AJ, Steinlechner CW, Lavy CB, Mannion S, Mkandawire N. Results of manipulation of idiopathic clubfoot deformity in Malawi by orthopaedic clinical officers using the Ponseti method: a realistic alternative for the developing world? *Journal of pediatric orthopedics*. 2005;25(5):627-9.

<https://doi.org/10.1097/01.bpo.0000164876.97949.6b>

PMid:16199944

10. Goksan SB, Bursali A, Bilgili F, Sivacioglu S, Ayanoglu S. Ponseti technique for the correction of idiopathic clubfeet presenting up to 1 year of age. A preliminary study in children with untreated or complex deformities. *Archives of orthopaedic and trauma surgery*. 2006;126(1):15-21.

<https://doi.org/10.1007/s00402-005-0070-9>

PMid:16283342

11. Švehlík M, Floh U, Steinwender G, Sperl M, Novak M, Kraus T. Ponseti method is superior to surgical treatment in clubfoot – Long-term, randomized, prospective trial. *Gait & Posture*. 2017;58:346-51.

<https://doi.org/10.1016/j.gaitpost.2017.08.010>

PMid:28866453

12. Dobbs MB, Nunley R, Schoenecker PL. Long-term follow-up of patients with clubfeet treated with extensive soft-tissue release. *The Journal of bone and joint surgery American volume*. 2006;88(5):986-96.

<https://doi.org/10.2106/JBJS.E.00114>

<https://doi.org/10.2106/00004623-200605000-00009>

PMid:16651573

13. Swaroop VT, Dias L. Orthopaedic management of spina bifida—part II: foot and ankle deformities. *Journal of children's orthopaedics*. 2011;5(6):403-14.

<https://doi.org/10.1007/s11832-011-0368-9>

PMid:23205142 PMCID:PMC3221758

14. Lovell ME, Morcuende JA. Neuromuscular disease as the cause of late clubfoot relapses: report of 4 cases. *Iowa Orthop J*. 2007;27:82-4.

PMid:17907435 PMCID:PMC2150663

15. Hester TW, Parkinson LC, Robson J, Misra S, Sangha H, Martin JE. A hypothesis and model of reduced fetal movement as a common pathogenetic mechanism in clubfoot. *Med Hypotheses*. 2009;73(6):986-8.

<https://doi.org/10.1016/j.mehy.2009.04.056>

PMid:19786327

16. Peterson JF, Ghaloul-Gonzalez L, Madan-Khetarpal S, Hartman J, Surti U, Rajkovic A, et al. Familial microduplication of 17q23.1-q23.2 involving TBX4 is associated with congenital clubfoot and reduced penetrance in females. *Am J Med Genet A*. 2014;164A(2):364-9.

<https://doi.org/10.1002/ajmg.a.36238>

PMid:24592505

17. Wallander H, Hovelius L, Michaelsson K. Incidence of congenital clubfoot in Sweden. *Acta orthopaedica*. 2006;77(6):847-52.

<https://doi.org/10.1080/17453670610013123>

PMid:17260191

18. Huntley JS. Optimising the management of congenital talipes. *The Practitioner*. 2013;257(1765):15-8, 2.

19. Ponseti IV, Zhivkov M, Davis N, Sinclair M, Dobbs MB, Morcuende JA. Treatment of the complex idiopathic clubfoot. *Clinical orthopaedics and related research*. 2006;451:171-6.

<https://doi.org/10.1097/01.blo.0000224062.39990.48>

PMid:16788408

20. Ponseti IV. Common errors in the treatment of congenital clubfoot. *International orthopaedics*. 1997;21(2):137-41.

<https://doi.org/10.1007/s002640050137>

PMid:9195271 PMCID:PMC3616653

21. Radler C. The Ponseti method for the treatment of congenital club foot: review of the current literature and treatment recommendations. *International orthopaedics*. 2013;37(9):1747-53.

<https://doi.org/10.1007/s00264-013-2029-8>

<https://doi.org/10.1007/s00264-013-2031-1>

PMid:23928728 PMCID:PMC3764299

22. Terrazas-Lafargue G, Morcuende JA. Effect of cast removal timing in the correction of idiopathic clubfoot by the Ponseti method. *The Iowa orthopaedic journal*. 2007;27:24-7.

PMid:17907426 PMCID:PMC2150656

23. Harnett P, Freeman R, Harrison WJ, Brown LC, Beckles V. An accelerated Ponseti versus the standard Ponseti method: a prospective randomised controlled trial. *The Journal of bone and joint surgery British volume*. 2011;93(3):404-8.

<https://doi.org/10.1302/0301-620X.93B3.24450>

PMid:21357965

24. Pirani S, Zeznik L, Hodges D. Magnetic resonance imaging study of the congenital clubfoot treated with the Ponseti method. *Journal of pediatric orthopedics*. 2001;21(6):719-26. <https://doi.org/10.1097/00004694-200111000-00004>

<https://doi.org/10.1097/01241398-200111000-00004>

PMid:11675543

25. Dyer PJ, Davis N. The role of the Pirani scoring system in the management of club foot by the Ponseti method. *The Journal of bone and joint surgery British volume*. 2006;88(8):1082-4.

<https://doi.org/10.1302/0301-620X.88B8.17482>

PMid:16877610

26. Herzenberg JE, Radler C, Bor N. Ponseti versus traditional methods of casting for idiopathic clubfoot. *Journal of pediatric orthopedics*. 2002;22(4):517-21.

<https://doi.org/10.1097/01241398-200207000-00019>

<https://doi.org/10.1097/00004694-200207000-00019>

PMid:12131451

27. Lebel E, Karasik M, Bernstein-Weyel M, Mishukov Y, Peysner A. Achilles tenotomy as an office procedure: safety and efficacy as part of the Ponseti serial casting protocol for clubfoot. *Journal of pediatric orthopedics*. 2012;32(4):412-5.

<https://doi.org/10.1097/BPO.0b013e31825611a6>

PMid:22584844

28. Parada SA, Baird GO, Auffant RA, Tompkins BJ, Caskey PM. Safety of percutaneous tendoachilles tenotomy performed under general anesthesia on infants with idiopathic clubfoot. *Journal of pediatric orthopedics*. 2009;29(8):916-9.

<https://doi.org/10.1097/BPO.0b013e3181c18ab5>

PMid:19934709

29. Zhao D, Liu J, Zhao L, Wu Z. Relapse of clubfoot after treatment with the Ponseti method and the function of the foot abduction orthosis. *Clinics in orthopedic surgery*. 2014;6(3):245-52.

<https://doi.org/10.4055/cios.2014.6.3.245>

PMid:25177447 PMCid:PMC4143509

30. Staheli L. Ponseti Management. Seattle, WA.: Global HELP; 2009 [accessed 22 June 2018]. Available from: http://www.global-help.org/publications/books/book_cfponseti.html.

31. Dobbs MB, Rudzki JR, Purcell DB, Walton T, Porter KR, Gurnett CA. Factors predictive of outcome after use of the Ponseti

method for the treatment of idiopathic clubfeet. *The Journal of bone and joint surgery American volume*. 2004;86-A(1):22-7.

<https://doi.org/10.2106/00004623-200401000-00005>

PMid:14711941

32. Garg S, Porter K. Improved bracing compliance in children with clubfeet using a dynamic orthosis. *Journal of children's orthopaedics*. 2009;3(4):271-6.

<https://doi.org/10.1007/s11832-009-0182-9>

PMid:19495824 PMCid:PMC2726866

33. Zions LE, Dietz FR. Bracing following correction of idiopathic clubfoot using the Ponseti method. *The Journal of the American Academy of Orthopaedic Surgeons*. 2010;18(8):486-93. <https://doi.org/10.5435/00124635-201008000-00005>

PMid:20675641

34. Hayes CB, Murr KA, Muchow RD, Iwinski HJ, Talwalkar VR, Walker JL, et al. Pain and overcorrection in clubfeet treated by Ponseti method. *Journal of pediatric orthopedics Part B*. 2018;27(1):52-5.

35. Bor N, Coplan JA, Herzenberg JE. Ponseti treatment for idiopathic clubfoot: minimum 5-year followup. *Clinical orthopaedics and related research*. 2009;467(5):1263-70.

<https://doi.org/10.1007/s11999-008-0683-8>

PMid:19130158 PMCid:PMC2664421

36. Eberhardt O, Peterlein CD, Fernandez FF, Wirth T. [Mid-term results of idiopathic clubfeet treated with the Ponseti method]. *Zeitschrift fur Orthopadie und Unfallchirurgie*. 2012;150(2):190-7.

<https://doi.org/10.1055/s-0031-1298271>

PMid:22354441

37. Church C, Coplan JA, Poljak D, Thabet AM, Kowtharapu D, Lennon N, et al. A comprehensive outcome comparison of surgical and Ponseti clubfoot treatments with reference to pediatric norms. *Journal of children's orthopaedics*. 2012;6(1):51-9.

<https://doi.org/10.1007/s11832-012-0387-1>

PMid:23449014 PMCid:PMC3303018

38. Masrouha KZ, Morcuende JA. Relapse after tibialis anterior tendon transfer in idiopathic clubfoot treated by the Ponseti method. *Journal of pediatric orthopedics*. 2012;32(1):81-4.

<https://doi.org/10.1097/BPO.0b013e31823db19d>

PMid:22173393

39. Cummings RJ. The effectiveness of botulinum A toxin as an adjunct to the treatment of clubfeet by the Ponseti method:

a randomized, double blind, placebo controlled study. *J Pediatr Orthop.* 2009;29(6):564-9.

40. Pittner DE, Klingele KE, Beebe AC. Treatment of clubfoot with the Ponseti method: a comparison of casting materials. *J Pediatr Orthop.* 2008;28(2):250-3.

<https://doi.org/10.1097/BPO.0b013e318164f8e7>

PMid:18388724

Figures

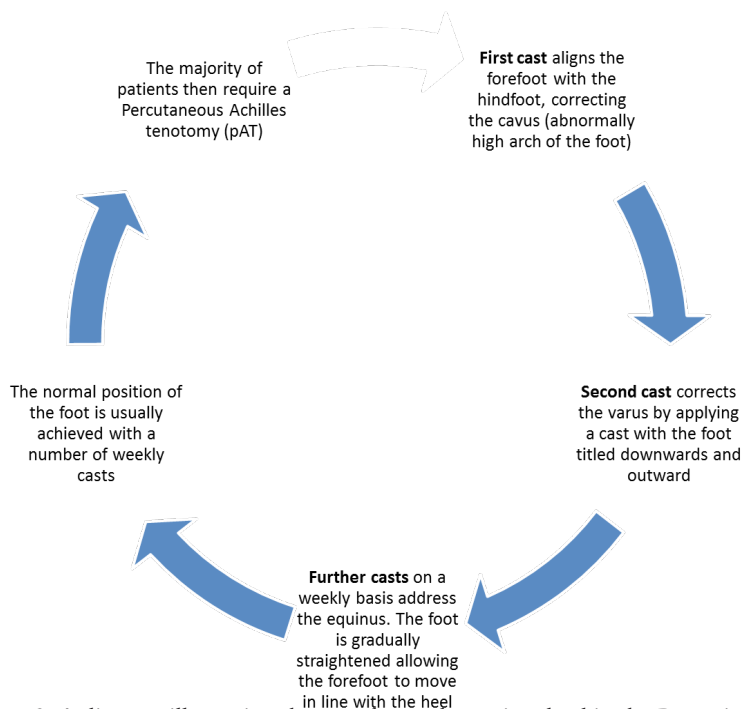
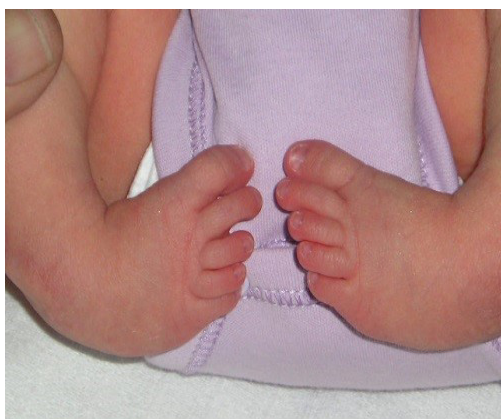

Figure 2: A diagram illustrating the stretches and casts involved in the Ponseti method



The British Student Doctor is an open access journal, which means that all content is available without charge to the user or his/her institution. You are allowed to read, download, copy, distribute, print, search, or link to the full texts of the articles in this journal without asking prior permission from either the publisher or the author.

bsdj.org.uk



[/thebsdj](https://www.facebook.com/thebsdj)



[@thebsdj](https://twitter.com/thebsdj)



[@thebsdj](https://www.instagram.com/thebsdj)

Journal DOI

[10.18573/issn.2514-3174](https://doi.org/10.18573/issn.2514-3174)

Issue DOI

[10.18573/bsdj.v2i2](https://doi.org/10.18573/bsdj.v2i2)

This journal is licensed under a Creative Commons Attribution-NonCommercial-NoDerivatives 4.0 International License. The copyright of all articles belongs to **The British Student Doctor**, and a citation should be made when any article is quoted, used or referred to in another work.



Cardiff University Press

Gwasg Prifysgol Caerdydd

The British Student Doctor is an imprint of Cardiff University Press, an innovative open-access publisher of academic research, where 'open-access' means free for both readers and writers.

cardiffuniversitypress.org