



# Subdural haematoma in neonates following forceps-assisted delivery: case series and review of the literature

Malik Zaben<sup>1,2</sup> · S. Manivannan<sup>1</sup> · C. Petralia<sup>1</sup> · P. Leach<sup>1</sup>

Received: 28 September 2018 / Accepted: 26 December 2018  
© The Author(s) 2019

## Abstract

**Purpose** Subdural haematoma (SDH) is a recognised complication of forceps-assisted delivery (FAD). There are no guidelines regarding its management. This study aims to provide a better insight into the management and outcomes of neonatal SDH post-FAD.

**Methods** Retrospective review of our neonatal database and systematic review of the literature for neonatal cases that presented with SDH after FAD. Retrospective neurosurgical database search for cases of neonatal SDH post-FAD managed in our unit between January 2007 and January 2017. Systematic review of the literature was performed using PRISMA guidelines. The inclusion criteria are as follows: (1) neonates; (2) forceps-assisted delivery; (3) evidence of SDH on imaging, with or without other traumatic lesions.

**Results** A literature search yielded nine studies with 30 patients meeting our inclusion criteria. In addition, four cases were identified from our institutional database. Forty-two percent ( $n = 14$ ) had their SDH managed surgically, with subsequent full neurological recovery in 57%. In comparison, 95% ( $n = 18$ ) of the conservatively managed patients made a full recovery. Hydrocephalus was present in 1/19 and 11/14 of the conservatively managed and surgically managed patients respectively.

**Conclusions** Conservative management can lead to a full neurological recovery in SDH following FAD in neonates. However, a significant minority may still need neurosurgical intervention for the SDH or subsequent hydrocephalus; therefore, we advocate early transfer to a specialist neuroscience centre.

**Keywords** Birth-related injuries · Traumatic brain injury · Paediatric neurosurgery

## Introduction

Instrumental delivery is performed for 5–20% of infants in developed countries [1] with a median estimate of 7.5% in Europe [2]. Although recent trends show a preference towards the use of vacuum devices [3], forceps-assisted delivery (FAD) continues to be used widely. Maternal complications of FAD include post-partum bleeding, anal sphincter injuries, and psychological trauma [4]. Use of forceps to grasp the baby's head can result in significant foetal injury, including subgaleal haematoma, facial trauma, neonatal jaundice, and

retinal haemorrhages [5]. One recognised complication is the development of a subdural haematoma (SDH) (Fig. 1). This tends to present within 24 h of birth with hypotonia, respiratory distress, seizures, and/or a tense fontanelle [6]. Management usually requires liaison with neurosurgical and intensive care teams. Currently, there are no guidelines regarding management of post-FAD SDH and their outcomes are yet to be fully explored. In this study, we aim to provide better insight into the management of neonatal SDH post-FAD by (1) presenting similar cases from our unit, and (2) summarising a review of the literature regarding its presentation, management, and outcomes.

✉ Malik Zaben  
ZabenM@cardiff.ac.uk

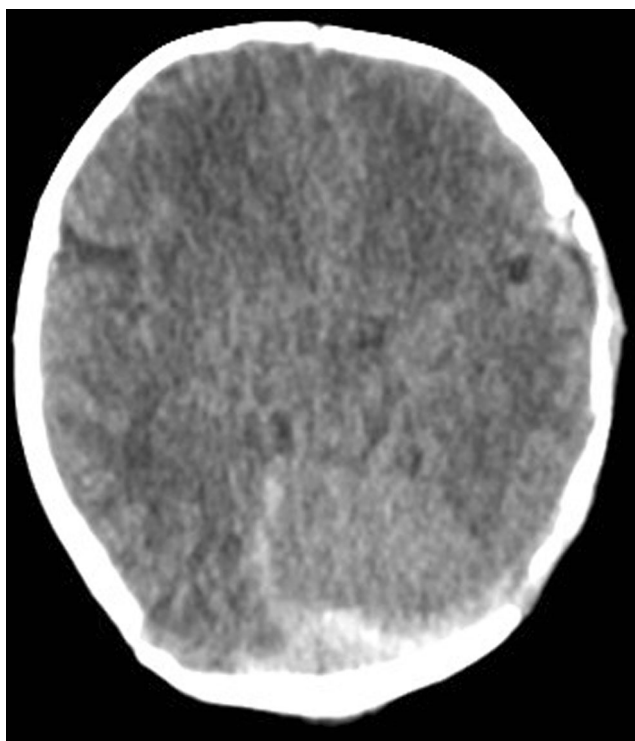
<sup>1</sup> Department of Paediatric Neurosurgery, University Hospital of Wales, Cardiff, UK

<sup>2</sup> Neuroscience and Mental Health Research Institute (NMHRI), School of Medicine, Cardiff University, Room 4FT 80E, 4th Floor, University Hospital Wales, Heath Park, Cardiff CF14 4XN, UK

## Methods

### Institutional data

A retrospective review of the neurosurgical database at our local unit was performed between January 2007 and January



**Fig. 1** Axial CT slice demonstrating neonatal posterior fossa subdural haematoma following forceps-assisted delivery referred to our unit

2017 for cases of neonatal SDH following forceps-assisted delivery. Patient demographics, obstetric details, timing/onset/features of presentation, imaging findings, management, and subsequent follow-up details were obtained.

## Literature review

The structure of the search strategy for this literature review was based on the Preferred Reporting Items for Systematic Reviews and Meta-Analyses (PRISMA) guidelines [7].

## Search strategy

A multi-database literature search across PubMed and Ovid was performed on February 12, 2018 using combinations of the following search terms: “subdural haematoma”, “forceps-related injuries”, “birth-related injuries”, “newborn”, and “neonate”. Articles fulfilling the following criteria were included: (1) neonates with subdural haematoma with or without other accompanying intracranial bleeds, (2) forceps-assisted delivery with or without initial failure of ventouse, (3) radiographic evidence of intracranial haemorrhage, (4) full-text articles, and (5) articles published from January 1, 1980 onwards. Articles reporting cohorts with a wide range of delivery methods were included only if details of neonates with forceps-assisted delivery could be specifically distinguished.

## Data analysis

Studies were evaluated with respect to the following: (1) obstetric factors including both maternal and neonatal factors; (2) clinical presentation including timing of onset, symptoms, and imaging findings; (3) management; and (4) outcomes and follow-up.

## Case series

Using the same criteria as the literature review, we have identified four cases of post-FAD SDH in our unit.

### Case 1

This male neonate was born at a gestational age of 41 weeks, weighing 2780 g. Onset of labour was spontaneous with a total duration of 10 h. Presentation was cephalic and FAD was performed. APGAR score was 6 at 1 min and 10 at 5 min. The baby was discharged home on Day 1. However, his parents noticed abnormal eye movements soon after discharge, which were retrospectively considered to be seizures. The baby was re-admitted, and three further right-sided focal seizures were witnessed on Day 3. Subsequent CT head showed a frontal intracranial haemorrhage (ICH) and a left SDH with midline shift. The patient was loaded with phenobarbitone and transferred immediately to the local Neurosurgical unit. On admission, the baby had poor tone in upper and lower limbs, absent Moro reflex, poor suck, and marked head lag. Over the course of the admission, symptoms were improved with conservative management. The patient was discharged after 1 day in intensive care and 2 days in special care. Follow-up at 1 year showed no evidence of neurological impairment.

### Case 2

This female neonate was born at a gestational age of 38 weeks, weighing 4440 g. Induction of labour was performed due to foetal abnormalities (right pelvicalyceal dilatation and shoulder dystocia) and maternal hypertension. Presentation was cephalic and FAD was performed. APGAR score was 6 at 1 min and 9 at 5 min. The baby was born in a critical condition with an absent heart rate and poor respiratory effort. Positive end-expiratory pressure was given until 3 min of life, and she developed some grunting after transfer to the neonatal unit. However, she had two further episodes of acute desaturation and was kept in for observation. At 8 h post-admission, right-sided focal seizures were noted. She was loaded with phenobarbitone and had only one further episode of seizures on Day 2. CT head demonstrated a left-sided extradural and SDH overlying the tentorium cerebelli. She was referred to Neurosurgery, and the decision for conservative management

was made. She spend 1 day in intensive care, 1 day in high dependency, and 9 days in special care before discharge. There was no evidence of neurological deficit at 6 months follow-up.

### Case 3

This male neonate was born at a gestational age of 35 weeks, weighing 3000 g. Onset of labour was spontaneous with cephalic presentation; FAD was performed. APGAR score was 6 at both 1 and 5 min, and 7 at 10 min. The baby was born with significant forceps-related injuries to the face and head, with left-sided proptosis secondary to orbital fracture. He was tachycardic with a weak cry, minimal response to stimulation, hypotonic, and cyanotic. He was promptly intubated and ventilated. After 1 day in intensive care, he was transferred to special care. He improved moderately following transfer but increased tone in the upper limbs and reduced tone in the lower limbs were noted. Initial USS was normal. However, CT head demonstrated left frontal extra-dural haematoma and SDH overlying the occipital lobes, cerebellum, and tentorium cerebelli. Small foci of intra-parenchymal bleeds and intraventricular blood were noted. The decision for conservative management was made. After 5 days on special care, he was transferred to the neonatal unit. There was no evidence of focal neurological deficit on discharge. Marked improvement in proptosis was noted.

### Case 4

This male neonate was born at a gestational age of 41 + 6 weeks, weighing 3700 g. Induction of labour was performed due to failure to progress. Initially, FAD was attempted but this was abandoned and emergency C-section performed. APGAR score was 6 at 1 min and 9 at 5 min. Significant right-sided head injury at birth indicated further imaging. CT head demonstrated right parietal fracture, multifocal parietal haemorrhage, and a thin right-sided SDH. All injuries were considered to be related to the failed attempt at FAD. The baby was initially floppy and was immediately transferred to resuscitation, requiring a short period of stimulation and inflation breaths. He developed left-sided focal seizures at 28 h. On Day 2, he had further generalised tonic clonic seizures. Phenobarbitone was administered. The decision for conservative management was made, and he was successfully discharged on Day 7. There was no evidence of focal neurological deficit on discharge.

## Literature review: results

A total of nine full-text articles were yielded from our literature search (see Table 1). The majority were case series [6,

8–11, 15], with two retrospective studies [12, 14] and one prospective study [13]. A total of 30 patients were identified across evaluated articles that fit our inclusion criteria.

## Patient demographics

Where gender was specified, 11 were male and 3 were female babies (see Table 2). Mean weight at birth was 3276 g (range 1220–4220 g, 30 patients). Of studies reporting head circumference, mean value was 34.3 cm (range 27–37 cm, 12 patients). Average APGAR score was 6 at 1 min and 7 at 5 min (21 patients). FAD alone was performed successfully in 23 patients, but in 7 patients, it was performed following failed ventouse delivery.

## Clinical presentation

Majority presented acutely within 24 h of birth (73.1%, 19/26 patients, see Table 3). Common presenting symptoms include hypotonia (36.7%), lethargy (30%), respiratory distress (20%), and seizures (16.7%). Less common features included strabismus, facial palsy, cephalhaematoma, and haemotympanum. These are likely associated with craniofacial injuries sustained during FAD. A small proportion of patients were asymptomatic (23.3%).

## Management

Approximately half of patients were treated surgically for clot evacuation (46.7%, 14/30) and the remainder managed conservatively (see Table 4). The predominant distinguishing feature between these two groups was the presence of hydrocephalus. The majority of surgical candidates had hydrocephalus (78.6%, 14/30) while only one conservatively managed patient had hydrocephalus. Ventriculoperitoneal (VP) shunts were subsequently inserted in three surgically managed patients.

## Outcomes

Conservatively managed patients all had complete neurological recovery (93.8%, 15/16 patients) except one patient that died (see Table 4). More than half of surgically managed patients made a full recovery (57.1%, 8/16 patients). The remainder of patients either had persistent neurological deficits (18.8%, 3/16 patients) or global developmental delay (18.8%, 3/16 patients) but no deaths.

## Discussion

Development of SDH in neonates is an uncommon but recognised complication of FAD. In this review, we have reported both our personal experience with management of this

**Table 1** Summary of the included studies and our case series

Study	Design	Sample	Location	Data collection period (years)	Summary
Serfontein et al. [8]	Case series	2	Canada	–	Case series of 3 patients, two of which fit the inclusion criteria. Both underwent surgical evacuation with successful outcomes.
Menezes et al. [9]	Case series	3	USA	–	Case series of 3 patients, two of which fit the inclusion criteria. Both underwent surgical evacuation with successful outcomes.
Koch et al. [6]	Case series	3	USA	–	Case series of 7 patients, three of which fit the inclusion criteria. Details successful conservative management of all cases.
Govaert et al. [10]	Case series	1	Belgium	–	Case series of 8 patients, one of which fit the inclusion criteria. Difficult delivery following forceps assistance in very preterm (28 weeks) boy. USS at birth demonstrated likely haemorrhage. Post mortem demonstrated tentorial tear near falco-tentorial junction, and large posterior fossa SDH.
Huang et al. (1991)	Case series	1	Taiwan	–	One patient fit inclusion criteria. Median incisura tentorial haemorrhage identified on CT following symptoms at 22 h. Conservatively managed successfully.
Govaert et al. [11]	Case series	1	Belgium	–	Case series of 7 patients, one of which fit the inclusion criteria. Term delivery with failed forceps traction. Suspicious USS at birth triggered CT at Day 6 which revealed intracranial bleed. However, at 6 months, there were no radiological nor clinical findings.
Perrin et al. [12]	Retrospective	6	Canada	9	Valuable benefit of surgical intervention in posterior fossa SDH patients, largely with satisfactory outcomes.
Whitby et al. [13]	Prospective	8	UK	1 2/3	Those delivered by forceps after attempted ventouse delivery were more likely to have SDH than any other method of delivery. All were managed conservatively with successful outcomes at 4 weeks.
Blauwblomme et al. [14]	Retrospective	8	France	25	Valuable benefit of surgical intervention for evacuation of posterior fossa SDH in patients with clinical/ radiological findings of brainstem compression or hydrocephalus.
Current case series	Retrospective	4	UK	10	Conservative management of four patients with SDH post-FAD. Two patients had posterior fossa SDH. No neurological impairment at follow-up in all cases.

condition and evaluated the literature for similar cases. The risk of post-FAD SDH likely emerges from a combination of (1) evolution of a comparatively narrow female pelvis compared to her primate ancestors and increased brain volume of the newborn at birth [16] and (2) prolonged instrumental manipulation of newborn's deformable skull during delivery.

**Table 2** Summary of patient demographics and obstetric factors of cases from literature review

Parameter	Value	<i>N</i>
Sample size	30	
Gender	11 Male, 3 Female	14
Weight (g)	3276 (1220–4220)	30
Head circumference (cm)	34.3 (27–37)	12
Apgar (1 min)	5.8	21
Apgar (5 min)	7.4	21
Forceps only	23	30
Failed ventouse, forceps	7	30

Of the four cases reported from our unit, three were males, which was consistent with the male preponderance observed in evaluated studies. The reason for this is unclear, but further evidence is required to support possible male susceptibility to post-FAD SDH. Birth weight in all four neonates was variable. Average birthweight in evaluated studies was 3276 g, which is similar to the average birth weight of babies of European heritage [17]. Indeed, there is no evidence for a relationship between birthweight and risk of sustaining SDH. In our cases, FAD alone was performed without initial failed ventouse delivery, although the procedure was abandoned and emergency C-section was performed in one case. It is possible that failed ventouse delivery prior to FAD increases the risk of neonatal SDH. One study [13] prospectively studied the frequency of clinically silent subdural haemorrhage in 111 neonates on MRI. When compared to other subgroups, FAD following failed ventouse delivery resulted in a greater risk of SDH, which was statistically significant. Although this applies to clinically silent SDH, it is unclear whether this can be generalised to all cases of neonatal SDH post-FAD. This observed risk could be

**Table 3** Summary of clinical presentation of patients from literature review

Parameter	No.	%
Onset		
< 1h	12	46.2
3–6 h	3	11.5
24 h	4	15.4
3 days	1	3.8
4 days	3	11.5
5 days	2	7.7
20 days	1	3.8
Symptoms		
Hypotonia	11	36.7
Lethargy	9	30
Tense fontanelle	6	20
Respiratory dysfunction		
Increased HC		
Seizures	5	16.7
Feeding difficulty	3	10
Hypertonia		
Strabismus	2	6.7
Facial palsy	1	3.3
Mydriasis		
Jaundice		
Cephalhaematoma		
Haemotympanum		
Fever		
Opisthotonus		
Asymptomatic	7	23.3

due to the protracted delivery and instrumental manipulation of the neonatal head rather than the choice of instrument as such. Further studies recording duration of attempted instrumental delivery may help stratify risk of intracranial bleeding.

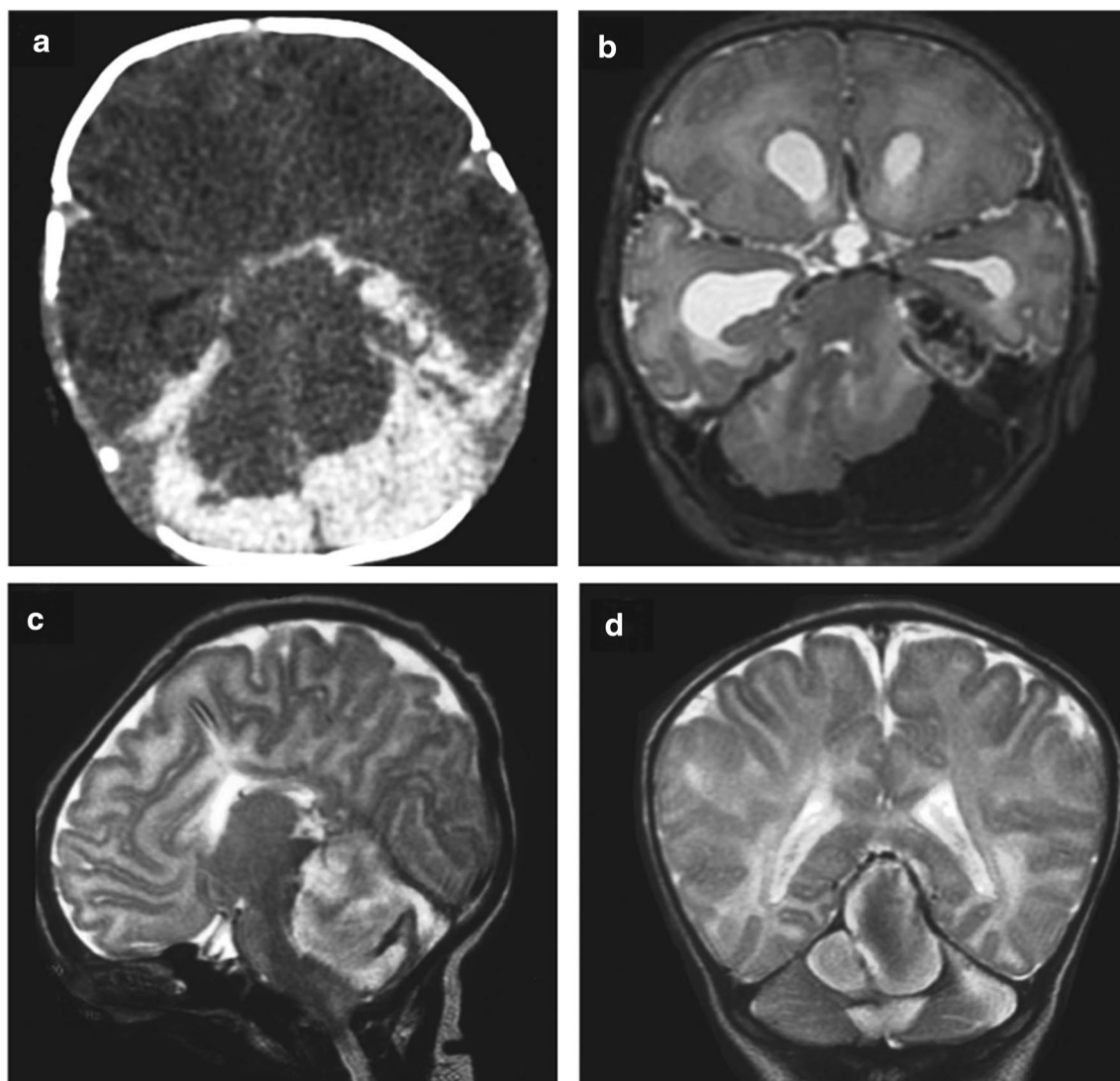
Clinical presentation is acute, but not necessarily reflected by condition immediately following birth. APGAR scores improved between 1 and 5 min across our cases, and this is corroborated by findings across included studies. Non-specific neurological symptoms begin to manifest over the first 24 h

**Table 4** Summary of the surgical and conservative management of posterior fossa subdural haematoma in infants in literature review

	Surgical	Conservative
Patients	14	16
Hydrocephalus	11	1
VP shunt	3	0
Outcomes		
Complete resolution	8	15
Persistent deficit	3	0
Global delay	3	0
Death	0	1

following birth, typically with hypotonia or lethargy, or more dramatically with onset of seizures as demonstrated in three of our cases. Other presenting features such as facial nerve palsy, proptosis, or cephalhaematoma (see Table 3) are more likely to be the result of craniofacial trauma from instrumental use. Nonetheless, they are indicative of the possibility of underlying intracranial damage. Delayed deterioration with features of raised ICP may be a result of hydrocephalus [10]. Ultrasound (USS) as first line imaging for detection of SDH demonstrated mixed success in included studies [6, 14]. However, one study [14] demonstrated effective use of USS for detection of hydrocephalus. Given that a large proportion of surgically managed patients had hydrocephalus, USS may be useful in this situation. USS was used in one of our patients but did not detect SDH, which was demonstrated in the subsequent CT. Therefore, CT head should be performed where possible if there is clinical suspicion of neonatal SDH. The effect of accompanying intracranial bleed on presentation, management, and outcomes is unclear. Two of our cases had accompanying EDH, and two had accompanying ICH. Included studies reported isolated SDH in approximately two thirds of cases. Complexity of injury and difficulty of imaging interpretation suggest that isolated SDH is less common. It is unclear whether the anatomical location of SDH affects presentation or outcomes. For instance, posterior fossa SDH confers the risk of brainstem compression and hydrocephalus (Fig. 2) but further studies are required to confirm whether prognosis is worse than neonatal SDH in other locations. Two of our patients (Case 2 and 3) had posterior fossa SDH and presented with symptoms of respiratory distress, but this was no different to the other cases. Thus, it is unclear whether location of SDH should influence risk stratification or management.

Management of neonatal SDH post-FAD requires joint care between neurosurgical and neonatal intensive care team. The general paradigm involves seizure control, ventilatory support when required, and close monitoring for further deterioration and neurosurgical intervention. In more than half of cases, conservative management is sufficient, demonstrated by full recovery in 93.8% from included studies. This is consistent with our own experience, as all four cases were managed conservatively with no evidence of neurological impairment at follow-up. However, our follow-up duration did not extend into adulthood. Only 3 patients from included studies were followed up long term. Further studies are required to evaluate any longer-term effects on development. Some patients will inevitably require surgical evacuation of SDH. Notably, most of these patients had hydrocephalus, which likely contributed to further delayed deterioration and resulted in surgery [14]. In contrast, only one conservatively managed patient had hydrocephalus. This is consistent with our conservatively managed cases. Nonetheless, outcomes in the surgical cohort were still positive, with 57.1% achieving full resolution of symptoms and the remainder sustaining persistent neurological deficit or



**Fig. 2** Examples of two neonates (**a, b** and **c, d**) with posterior fossa subdural haematoma causing mass effect and secondary obstructive hydrocephalus. Axial CT scan (**a**), axial T2 weighted MRI (**b**), sagittal T2 weighted MRI (**c**), coronal T2 weighted MRI (**d**) (adapted from Blauwblomme et al. [14])

global developmental delay. This is likely indicative of more severe pre-existing brain damage within the surgical cohort. This highlights the importance of close monitoring and prompt neurosurgical intervention on clinical deterioration or development of alarming features such as hydrocephalus.

## Conclusions

Acute deterioration following FAD in the presence of external signs of craniofacial injury may indicate underlying SDH. This requires prompt imaging and transfer to a Neurosurgical unit with maximal medical management and close monitoring for further deterioration. Conservative management is sufficient in over half of cases with successful outcomes. In some cases, typically involving hydrocephalus,

neurosurgical intervention is required. Although outcomes are largely positive following surgery, a proportion may continue to have sustained neurological deficit.

## Compliance with ethical standards

**Conflict of interest** The authors report no conflicts of interest.

**Open Access** This article is distributed under the terms of the Creative Commons Attribution 4.0 International License (<http://creativecommons.org/licenses/by/4.0/>), which permits unrestricted use, distribution, and reproduction in any medium, provided you give appropriate credit to the original author(s) and the source, provide a link to the Creative Commons license, and indicate if changes were made.

**Publisher's note** Springer Nature remains neutral with regard to jurisdictional claims in published maps and institutional affiliations.

## References

1. Majoko F (2012) Trial of instrumental delivery in theatre versus immediate caesarean section for anticipated difficult assisted births. *10: Cd005545*
2. Macfarlane AJ, Blondel B, Mohangoo AD, Cuttini M, Nijhuis J, Novak Z, Olafsdottir HS, Zeitlin J (2016) Wide differences in mode of delivery within Europe: risk-stratified analyses of aggregated routine data from the Euro-Peristat study. *BJOG: Int J Obstet Gynaecol* 123:559–568
3. Ali UA, Norwitz ER (2009) Vacuum-assisted vaginal delivery. *Rev Obstet Gynecol* 2:5–17
4. Rather H, Muglu J, Veluthar L, Sivanesan K (2016) The art of performing a safe forceps delivery: a skill to revitalise. *Eur J Obstet Gynecol Reprod Biol* 199:49–54
5. McAnena L, O’Keefe M, Kirwan C, Murphy J (2015) Forceps delivery-related ophthalmic injuries: a case series. *J Pediatr Ophthalmol Strabismus* 52:355–359
6. Koch TK, Jahnke SE, Edwards MS, Davis SL (1985) Posterior fossa hemorrhage in term newborns. *Pediatr Neurol* 1:96–99
7. Moher D, Liberati A, Tetzlaff J, Altman DG, Group P (2009) Preferred reporting items for systematic reviews and meta-analyses: the PRISMA statement. *BMJ* 339:b2535
8. Serfontein GL, Rom S, Stein S (1980) Posterior fossa subdural hemorrhage in the newborn. *Pediatrics* 65:40–43
9. Menezes AH, Smith DE, Bell WE (1983) Posterior fossa hemorrhage in the term neonate. *Neurosurgery* 13:452–456
10. Govaert P, Calliauw L, Vanhaesebrouck P, Martens F, Barrilari A (1990) On the management of neonatal tentorial damage. Eight case reports and a review of the literature. *Acta Neurochir* 106:52–64
11. Govaert P, Vanhaesebrouck P, de Praeter C (1992) Traumatic neonatal intracranial bleeding and stroke. *Arch Dis Child* 67: 840–845
12. Perrin RG, Rutka JT, Drake JM, Meltzer H, Hellman J, Jay V, Hoffman HJ, Humphreys RP (1997) Management and outcomes of posterior fossa subdural hematomas in neonates. *Neurosurgery* 40:1190–1199 discussion 1199–1200
13. Whitby EH, Griffiths PD, Rutter S, Smith MF, Sprigg A, Ohadike P, Davies NP, Rigby AS, Paley MN (2004) Frequency and natural history of subdural haemorrhages in babies and relation to obstetric factors. *Lancet* 363:846–851
14. Blauwblomme T, Garnett M, Vergnaud E, Boddaert N, Bourgeois M, DiRocco F, Zerah M, Sainte-Rose C, Puget S (2013) The management of birth-related posterior fossa hematomas in neonates. *Neurosurgery* 72:755–762
15. Huang CC, Shen EY (1991) Tentorial subdural hemorrhage in term newborns: ultrasonographic diagnosis and clinical correlates. *Pediatr Neurol* 7:171–177
16. Raynal P, Le Meaux JP, Chereau E (2005) Anthropologic evolution of women’s pelvis. *Gynecol Obstet Fertil* 33:464–468
17. Janssen PA, Thiessen P, Klein MC, Whitfield MF, Macnab YC, Cullis-Kuhl SC (2007) Standards for the measurement of birth weight, length and head circumference at term in neonates of European, Chinese and South Asian ancestry. *Open Med* 1:e74–e88