

This is an Open Access document downloaded from ORCA, Cardiff University's institutional repository: <https://orca.cardiff.ac.uk/id/eprint/134107/>

This is the author's version of a work that was submitted to / accepted for publication.

Citation for final published version:

Aagaard Nolting, Line, Brasch-Andersen, Charlotte, Cox, Helen, Kanani, Farah, Parker, Michael, Fry, Andrew E. , Loddo, Sara, Novelli, Antonio, Dentici, Maria Lisa, Joss, Shelagh, Jørgensen, Joan P. and Fagerberg, Christina R. 2020. A new 1p36.13-1p36.12 microdeletion syndrome characterized by learning disability, behavioral abnormalities, and ptosis. *Clinical Genetics* 97 (6) , pp. 927-932. 10.1111/cge.13739

Publishers page: <http://dx.doi.org/10.1111/cge.13739>

Please note:

Changes made as a result of publishing processes such as copy-editing, formatting and page numbers may not be reflected in this version. For the definitive version of this publication, please refer to the published source. You are advised to consult the publisher's version if you wish to cite this paper.

This version is being made available in accordance with publisher policies. See <http://orca.cf.ac.uk/policies.html> for usage policies. Copyright and moral rights for publications made available in ORCA are retained by the copyright holders.



A new 1p36.13-1p36.12 microdeletion syndrome characterized by learning disability, behavioral abnormalities, and ptosis

Short running title: 1p36.13-1p36.12 deletion syndrome

Line Nolting¹, Charlotte Brasch-Andersen¹, Helen Cox², Farah Kanani³, Michael Parker³, Andrew E. Fry⁴, Sara Loddò⁵, Antonio Novelli⁵, Maria Lisa Dentici⁶, Joss Shelagh⁷, Joan P. Jørgensen⁸, Christina R. Fagerberg¹

Affiliations

¹ Department of Clinical Genetics, Odense University Hospital, Odense, Denmark.

² West Midlands Regional Clinical Genetics Unit Birmingham U.K, Birmingham, United Kingdom.

³ Sheffield Clinical Genetics Service, Northern General Hospital, Sheffield, United Kingdom.

⁴ Institute of Medical Genetics, University Hospital of Wales, Heath Park, Cardiff, United Kingdom.

⁵ Laboratory of Medical Genetics, Bambino Gesù Childrens' Hospital, Rome, Italy.

⁶ Medical Genetics Unit, Bambino Gesù Children's Hospital, Rome, Italy.

⁷ Clinical Genetics, West of Scotland Genetic Services, the Queen Elisabeth University Hospital, Glasgow, United Kingdom.

⁸ Hans Christian Andersen Children's Hospital, Odense University Hospital, Odense, Denmark

Corresponding author

Christina Ringmann Fagerberg, christina.fagerberg@rsyd.dk

Acknowledgements

We thank the patients and their families for their kind participation. This study makes use of data generated by the DECIPHER community. A full list of centres who contributed to the generation of the data is available from <http://decipher.sanger.ac.uk> and via email from decipher@sanger.ac.uk. Funding for the project was provided by the Wellcome Trust.

Conflict of interest

The authors declare no conflicts of interest.

Data Available Statement

Not relevant. Most deletions can be seen in Decipher.

Abstract

Two 1p36 contiguous gene deletion syndromes are known so far: the terminal 1p36 deletion syndrome, and a 1p36 deletion syndrome with a critical region located more proximal at 1p36.23-1p36.22. We present even more proximally located overlapping deletions from seven individuals, with the smallest region of overlap comprising 1 Mb at 1p36.13-1p36.12 (chr1:19077793-20081292 (GRCh37/hg19)) defining a new contiguous gene deletion syndrome. The characteristic features of this new syndrome are learning disability or mild intellectual disability, speech delay, behavioral abnormalities, and ptosis. The genes *UBR4* and *CAPZB* are considered the most likely candidate genes for the features of this new syndrome.

Keywords

Chromosomes, Human, Pair 1; Ptosis; Chromosome Deletion; Learning disability; Behavioral abnormality

Introduction

1p36 terminal deletion is considered the most common terminal deletion in humans with an incidence of 1 in 5000 newborns.¹⁻³ Partial monosomy of chromosome 1p36 was first described in 1980, and in 1997 Shapira et al. delineated the 1p36 deletion syndrome.⁴ The phenotype is variable with the most common features being intellectual disability, hypotonia, craniofacial dysmorphic features, growth delay, eye/vision problems, seizures and hearing impairment.⁴ Wu et al (1999) found the critical region to be of 6.29 Mb at 1p36.33-1p36.31 (chr1:1-6289973).⁵ In 2007 Kang et al defined a more proximal distinct 1p36 deletion syndrome with a critical region of 2.24 Mb at 1p36.23-1p36.22 (chr1:9124551-11362893) in five patients.⁶ The features linked to this region were cognitive deficits, congenital malformations, hirsutism, frontal and parietal bossing, epicanthic folds, and broad and arched eyebrows.⁶ We present seven individuals from five families with even more proximally located overlapping interstitial deletions in 1p36.13-1p36.12 and define this as a third contiguous gene deletion syndrome linked to 1p36.

Material and methods

[Skiv her]

Cases with overlapping deletions in 1p36 were identified via the DECIPHER Database (Database of Chromosomal Imbalance and Phenotype in Humans using Ensembl Resources).⁷ Only individuals with isolated deletions less than 5 Mb were included in the study. The literature was reviewed to identify individuals with isolated overlapping 1p36 deletions.

Consent for publication of clinical features and photos were obtained from all individuals shown in figure 1.

Candidate genes in the smallest region of overlap (SRO) were selected as OMIM genes with a pLI score > 0.8 (pLI = probability of LoF intolerance) in the Genome Aggregation database (GnomAD, accession date July 2nd, 2019).⁸

Results

Clinical features are listed in Table 1, and a summary of clinical features can be seen in Table 2. Detailed case descriptions can be seen in supplementary material.

Photos and schematic presentation of the 1p36 deletions are shown in Figure 1.

The SRO for individuals presenting with learning disability or mild intellectual disability, behavioral anomalies, and ptosis encompassed 1 Mb at chr1:19077793-20081292 (GRCh37/hg19). Individual 8 was described as non-dysmorphic and had a limited overlap with the SRO of 66 bp. She was not considered having the new microdeletion syndrome and her presence might indicate that the SRO could be even smaller.

The father of individual 3 was not available for analysis, and the mother did not have the deletion. The array data of individual 3 revealed 35 SNPs in the region of the deletion. Nine of 35 SNPs were not maternally inherited, and the deletion was concluded to be of the maternal allele. The remaining SNPs were non-informative but in concordance with loss of maternal allele. As the mother did not have the deletion, we conclude, that the deletion arose de novo in individual 3. The inheritance was thus known in all seven individuals.

Discussion

We present seven individuals with overlapping deletions in 1p36.13-1p36.12 and define a new microdeletion syndrome in 1p36 located more proximal to those previously described.

Four individuals were females, three were males. Five deletions occurred de novo (71%) while two siblings had inherited the deletion from their mother (29%). The majority was born at term and had a birth weight in the lower normal range. Postnatal growth was normal for all except one. Learning disability or mild intellectual disability was present in all except one who had moderate intellectual disability. Motor problems, behavioral anomalies and speech delay were seen in most individuals. Behavioral anomalies were seen in 57% (4/7), two of whom were diagnosed with ADHD. Dysmorphic features seen in at least 50% were congenital ptosis, pointed chin, high palate, misalignment of teeth, and epicanthus. Ophthalmologic features were seen in all (7/7), of which congenital ptosis – unilateral or bilateral – was the most distinct finding seen in 5/7 individuals (71%).

[Skiv her]

Less frequent were hypermetropia, epicanthus, deep-set eyes, and heavy eyebrows. Mild hearing loss was seen in one individual. Present in 50% or less were congenital heart defect (ASD and/or VSD, pulmonary valve dysplasia), and features of hands and feet such as clinodactyly, syndactyly, camptodactyly, and arachnodactyly.

Congenital ptosis is a distinct feature seen in more than half of the individuals. Ptosis is defined as the upper eyelid being positioned lower than normal, thereby narrowing the palpebral fissures vertical axis. Ptosis is considered congenital, when present before one year of age. Congenital ptosis can result in abnormal visual function and development, such as amblyopia. The levator palpebra superior muscle which elevates the upper eyelid is innervated by the 3rd cranial nerve, n. oculomotorius. The pathophysiologic process leading to ptosis can be either neurogenic, myogenic, aponeurotic or mechanical⁹. Congenital ptosis can occur isolated or as part of a syndrome. Congenital isolated ptosis most often occurs sporadically but can also be familial, and several loci and candidate genes have been suggested, including 1p32-1p34.1¹⁰, Xq24–27.1¹¹, and the *ZFH4* gene at 8q21.12.⁹ Congenital ptosis can be part of numerous genetic syndromes¹², some examples are congenital fibrosis of the extraocular muscles (*KIF21A*, *PHOX2A*, *TUBB3*)¹³, *SIX2* haploinsufficiency¹⁴, various types of myopathy¹⁵, neurogenetic diseases¹⁶, and mitochondrial diseases.¹⁷ The 1p36.13-1p36.12 microdeletion syndrome presented here is a new syndrome with ptosis as a distinct feature. Haploinsufficiency of one or more genes in this region is suspected to cause ptosis, but the relevant gene/genes and pathophysiological process are unknown.

The smallest region of overlap (SRO) encompasses 1 Mb at chr1:19077793-20081292. The SRO contains several genes, none of which are currently known to be haploinsufficient. The following genes, being the only ones with a pLI-score above 0.8, are suggested as possible candidate genes for features of this new microdeletion syndrome:

The *UBR4* gene (OMIM 609890), encodes a mammalian N-recognin.¹⁸ The protein is present in all tissues but highly expressed in nervous tissue, where it is involved in neurogenesis and neuronal migration, and seems to have pro-survival roles in neurons.¹⁸ *UBR4* deficient mice die during midgestation with multiple developmental anomalies.¹⁹ In humans *UBR4* has been suggested to be a modifier for episodic ataxia²⁰, and has been suggested as a candidate gene for the following phenotypes: autism²¹, autosomal recessive severe intellectual disability, epilepsy, and dysarthria²². More studies are needed to clarify the functions of *UBR4* in the brain and its role in human neurological diseases. While the ubiquitin ligase N-recognins are reported to be important for cardiac development²³, *UBR4* has so far not been shown to have a similar role. *UBR4* is highly intolerant to loss of function variants with a pLI of 1.00 (GnomAD accession date October 18th, 2019). *UBR4* is a strong candidate gene for the cognitive and behavioral symptoms in the proximal 1p36 deletion described here and might also be linked to ptosis and heart defects.

The *CAPZB* gene (OMIM 601572) encodes the beta subunit of the CAPZ protein, an actin-capping protein involved in modulating actin filaments and cytoskeleton in sarcomeres in muscle. It has been shown to be important in embryogenesis, and regulates tissue morphogenesis and cell behavior.²⁴ Clinical consequences of changes in this gene is largely unknown, however, a female infant with congenital cleft palate, micrognathia, muscular hypotonia, and developmental delay had a de novo reciprocal translocation t(1;13)(p36.13;q12.1) with the breakpoint on chromosome 1 located in the *CAPZB*-gene.²⁴ Studies on *capzb*^{-/-} zebrafish support the involvement of the *capzb*-gene in clefting and micrognathia. Malformations of craniofacial skeletal muscles were seen in *capzb*^{-/-} zebrafish,

[Skriver her]

while adult heterozygotes had subtle or no changes²⁴. While CAPZ plays a role in cardiac myofilament activation²³, no association to congenital heart malformation seems to exist with the current knowledge. CAPZB can be predicted to be LoF sensitive as the pLI is 0.91 (GnomAD accession date October 18th, 2019). CAPZB is also a candidate gene for at least some of the features of the 1p36 deletion.

In conclusion we present a new microdeletion syndrome at proximal 1p36 (1p36.13-1p36.12) characterized by learning disability or mild intellectual disability, speech delay, behavioral anomalies, and congenital ptosis. The smallest region of overlap is extended 1 Mb spanning from 19077793 bp to 20081292 bp (GRCh37; hg19). We consider the genes UBR4 and CAPZB to be the best candidate genes for the common features. More studies are needed to describe the new deletion syndrome better and clarify the genotype-phenotype correlation.

References

Reference List

1. Jordan VK, Zaveri HP, Scott DA. 1p36 deletion syndrome: an update. *Appl Clin Genet*. 2015;8:189-200.
2. Heilstedt HA, Ballif BC, Howard LA, Kashork CD, Shaffer LG. Population data suggest that deletions of 1p36 are a relatively common chromosome abnormality. *Clin Genet*. 2003;64(4):310-316.
3. Heilstedt HA, Ballif BC, Howard LA, et al. Physical map of 1p36, placement of breakpoints in monosomy 1p36, and clinical characterization of the syndrome. *Am J Hum Genet*. 2003;72(5):1200-1212.
4. Shapira SK, McCaskill C, Northrup H, et al. Chromosome 1p36 deletions: the clinical phenotype and molecular characterization of a common newly delineated syndrome. *Am J Hum Genet*. 1997;61(3):642-650.
5. Wu YQ, Heilstedt HA, Bedell JA, et al. Molecular refinement of the 1p36 deletion syndrome reveals size diversity and a preponderance of maternally derived deletions. *Hum Mol Genet*. 1999;8(2):313-321.
6. Kang SH, Scheffer A, Ou Z, et al. Identification of proximal 1p36 deletions using array-CGH: a possible new syndrome. *Clin Genet*. 2007;72(4):329-338.
7. Firth HV, Richards SM, Bevan AP, et al. DECIPHER: Database of Chromosomal Imbalance and Phenotype in Humans Using Ensembl Resources. *Am J Hum Genet*. 2009;84(4):524-533.
8. Kaimal AJ, Norton ME, Kuppermann M. Prenatal Testing in the Genomic Age: Clinical Outcomes, Quality of Life, and Costs. *Obstetrics and gynecology*. 2015.
9. McMullan TW, Crolla JA, Gregory SG, et al. A candidate gene for congenital bilateral isolated ptosis identified by molecular analysis of a de novo balanced translocation. *Hum Genet*. 2002;110(3):244-250.
10. Engle EC, Castro AE, Macy ME, Knoll JH, Beggs AH. A gene for isolated congenital ptosis maps to a 3-cM region within 1p32-p34.1. *Am J Hum Genet*. 1997;60(5):1150-1157.

11. McMullan TF, Tyers AG. X linked dominant congenital isolated bilateral ptosis: the definition and characterisation of a new condition. *Br J Ophthalmol*. 2001;85(1):70-73.
12. Pavone P, Cho SY, Pratico AD, Falsaperla R, Ruggieri M, Jin DK. Ptosis in childhood: A clinical sign of several disorders: Case series reports and literature review. *Medicine (Baltimore)*. 2018;97(36):e12124.
13. Price JM, Boparai RS, Wasserman BN. Congenital fibrosis of the extraocular muscles: review of recent literature. *Curr Opin Ophthalmol*. 2019;30(5):314-318.
14. Henn A, Weng H, Novak S, et al. SIX2 gene haploinsufficiency leads to a recognizable phenotype with ptosis, frontonasal dysplasia, and conductive hearing loss. *Clin Dysmorphol*. 2018;27(2):27-30.
15. North KN, Wang CH, Clarke N, et al. Approach to the diagnosis of congenital myopathies. *Neuromuscul Disord*. 2014;24(2):97-116.
16. Hamedani AG, Gold DR. Eyelid Dysfunction in Neurodegenerative, Neurogenetic, and Neurometabolic Disease. *Front Neurol*. 2017;8:329.
17. Watson E, Ahmad K, Fraser CL. The neuro-ophthalmology of inherited myopathies. *Curr Opin Ophthalmol*. 2019;30(6):476-483.
18. Parsons K, Nakatani Y, Nguyen MD. p600/UBR4 in the central nervous system. *Cell Mol Life Sci*. 2015;72(6):1149-1160.
19. Kim ST, Lee YJ, Tasaki T, et al. The N-recognin UBR4 of the N-end rule pathway is required for neurogenesis and homeostasis of cell surface proteins. *PLoS One*. 2018;13(8):e0202260.
20. Choi KD, Kim JS, Kim HJ, et al. Genetic Variants Associated with Episodic Ataxia in Korea. *Sci Rep*. 2017;7(1):13855.
21. Iossifov I, O'Roak BJ, Sanders SJ, et al. The contribution of de novo coding mutations to autism spectrum disorder. *Nature*. 2014;515(7526):216-221.
22. Hu H, Kahrizi K, Musante L, et al. Genetics of intellectual disability in consanguineous families. *Mol Psychiatry*. 2018.
23. Pyle WG, Hart MC, Cooper JA, Sumandea MP, de Tombe PP, Solaro RJ. Actin capping protein: an essential element in protein kinase signaling to the myofilaments. *Circ Res*. 2002;90(12):1299-1306.
24. Mukherjee K, Ishii K, Pillalamarri V, et al. Actin capping protein CAPZB regulates cell morphology, differentiation, and neural crest migration in craniofacial morphogenesis. *Hum Mol Genet*. 2016;25(7):1255-1270.

Figure Legends

Figure 1: Top: Photos of the reported individuals. Numbers refer to the numbers of the individuals in the study. Ages at the photos are: 1) 8 years, 2) 6 years, 3) 30 years, 4) 11 years, 5) 6 months, and 6) 16 years. The most consistent dysmorphic feature was ptosis or blepharophimosis as seen in individuals 1-5. Ptosis was mild in individual 2, while individuals 3, 4 and 5 had surgery for ptosis. Individuals 1-5 had pointed chin or “stuck-on chin”, while individual 6 had retrognathia. Bottom: 1p36 with the positions of the terminal deletion 1p36 and the proximal deletion 1p36 as described by Kang et al. indicated in hatched red. To the right deletions of the reported individuals of this paper and those with overlapping deletions identified from literature are shown in red, as is the smallest region of overlap (SRO). Please note that individual 8 only had a small overlap with the SRO (66 bp), this individual is not considered to have the 1p36 deletion syndrome defined here. Genes included in

[Skriv her]

the SRO at chr1:19077793-20081292 (GRCh37/hg19) are shown with the two most likely candidate genes *UBR4* and *CAPZB* (not all isoforms) encircled.

[Skriv her]

Table I

	Individual 1	Individual 2	Individual 3	Individual 4	Individual 5	Individual 6	Individual 7	Individual 8 Not affected	(Kang et al., 2007), case 1	(Zaveri et al., 2014), case 7
Decipher ID	341356	(341356)	(341356)	353614	323214	273541	353745	282936		
Sex	F	M	F	M	F	M	M	F	M	F
Age at reporting	8 y	6 y	31 y	10 y	2 y	16 y	20 y	11 y	-	-
Deletion in bp (hg19)	19077793- 20549013	19077793- 20549013	19077793- 20549013	18740425- 20891271	17214109- 20081292	19098854- 22517879	16610467- 21501038	20081226- 20700543	9124551- 21782714	12726755- 20540759
Size of deletion	1.5 Mb	1.5 Mb	1.5 Mb	2.2 Mb	2.9 Mb	3.5 Mb	4.9 Mb	619 kb	12.7 Mb	7.8 Mb
Inheritance	MI	MI	Dn	Dn	Dn	Dn	Dn	?, not MI	-	-
Cognition	LD (IQ 80)	LD (IQ 80)	LD	LD	-	Moderate ID	Mild ID	LD	-	Cognitive impairment
Speech delay	Yes	Yes	-	Yes, nasal speech	No	Yes	Yes	-	-	-
Behavior	Hyperactivity Reactive attachment disorder	Hyperactivity	ADHD Emotional unstable personality disorder at 19y	ADHD	Normal	Tantrums and night terrors as young child	Normal	Lack of emotions, inappropriat e reactions	-	-
Motor problems	Difficulties in balancing and bicycling	Tendency of falling	Difficulties in fine and gross motor skills as a child	-	Delayed	Delayed	-	-	Gross and fine motor skills delayed	-
Age at walking	16 m	16 m	13 m	-	21 m	24 m	-	-	-	-
Congenital heart defects	Small ASD and VSD (resolved spontaneously)	No	No	Small secundum ASD	No	No	Subaortic VSD (surgery 9m)	-	VSD, BAV, FOP, DAP	Tetralogy of fallot, BAV
Hearing and vision	Hypermetropia	Hypermetropia	-	No	Convergent squint. Partial 3rd and 6th nerve palsy	Mild hearing impairment	No	-	-	-
Skeletal features	-	-	-	-	-	-	Scoliosis	-	-	Kyphosis
Other features	Tubulated 1y, tonsillectomia and polypec- tomia at 2y	Periods with apnea as an infant, tubulated at 8m	-	Adenotonsil- lectomy	Eczema	Eczema, tonsillectomy 6y, persistent cough, mild hypotonia	-	Prone to constipation	Microcephaly	Seizures

Table I continued

	Individual 1	Individual 2	Individual 3	Individual 4	Individual 5	Individual 6	Individual 7	Individual 8 <u>Not affected</u>	(Kang et al., 2007), case 1	(Zaveri et al., 2014), case 7
Congenital ptosis	Yes	Yes (mild)	Yes	Yes	Yes	No	No	No	Yes	-
Eye, other	Heavy eyebrows	Upslant pf	Heavy eyebrows	-	-	Deep set eyes, slightly small pf	Synophrys, deep set eyes, blepharophimosis	-	S-shaped pf	
High plate	Yes	-	-	No	Yes	Yes	Yes	-	-	-
Teeth	Misaligned	Overbite	-	-	-	Misaligned	Misaligned	-	-	-
Pointed chin	Yes	Yes	Yes	Yes	Yes	Yes	Yes	-	-	-
Hands and feet	-	Clinodactyly of right hand 2. and 5. finger and left 5. finger, simian crease left hand	Bilateral pes planus in childhood		-	Bilateral 5th finger camptodactyly 2-3 toes syndactyly	Arachnodactyly	-	Contractures of the digits Camptodactyly of 3rd, 4th and 5th digits bilateral	-
Other	-	Elongated face, large distance between nipples	Wide nose Voluminous upper lip	Small mouth Narrow ear canals	High forehead	-	Short philtrum Elongated triangular face	-	Posterioly rotated ears Bulbous and tubular nose	-

Table II

Clinical features

Intellectual disability or learning disability	5/7	■	■	■	■	■	■	■
Speech delay	5/6	■	■	■	■	■	■	■
Motor delay	5/5	■	■	■	■	■	■	■
Behavioral anomalies	4/7	■	■	■	■	■	■	■
Congenital heart malformation	3/7	■	■	■	■	■	■	■
Congenital ptosis	5/7	■	■	■	■	■	■	■
Pointed or “stuck on” chin	6/7	■	■	■	■	■	■	■
High palate	4/5	■	■	■	■	■	■	■
Misalignment of teeth	3/4	■	■	■	■	■	■	■

Figure 1

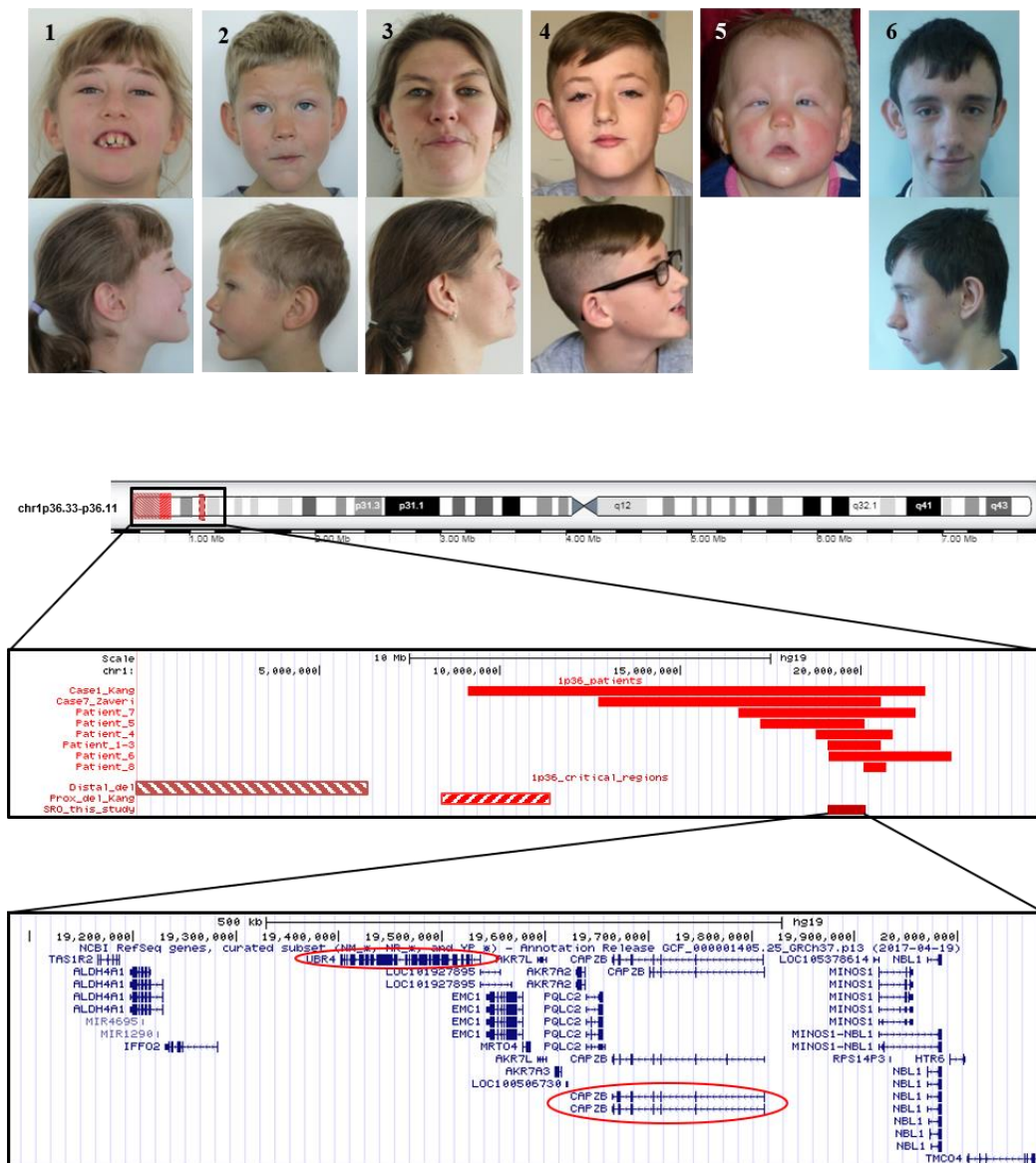


Figure 1: Top: Photos of the reported individuals. Numbers refer to the numbers of the individuals in the study. Ages at the photos are: 1) 8 years, 2) 6 years, 3) 30 years, 4) 11 years, 5) 6 months, and 6) 16 years. The most consistent dysmorphic feature was ptosis or blepharophimosis as seen in individuals 1-5. Ptosis was mild in individual 2, while individuals 3, 4 and 5 had surgery for ptosis. Individuals 1-5 had pointed chin or “stuck-on chin”, while individual 6 had retrognathia. Bottom: 1p36 with the positions of the terminal deletion 1p36 and the proximal deletion 1p36 as described by Kang et al. indicated in hatched red. To the right deletions of the reported individuals of this paper and those with overlapping deletions identified from literature are shown in red, as is the smallest region of overlap (SRO). Please note that individual 8 only had a small overlap with the SRO (66 bp), this individual is not considered to have the 1p36 deletion syndrome defined here. Genes included in the SRO at chr1:19077793-20081292 (GRCh37/hg19) are shown with the two most likely candidate genes *UBR4* and *CAPZB* (not all isoforms) encircled.

Appendix: Clinical information

Individual 1 (Decipher ID 341356) is the older maternal half-sister of individual 2. Due to IUGR the pregnancy was followed with ultrasound scans and the birth was induced but progressed vaginally uncomplicated. She was born at gestational age 39+6 with Apgar scores 9/1, 10/5. The birth weight was 2676 g (-2 SD), length 48 cm (-1 SD), and head circumference 34 cm (slightly below median). She had bilateral ptosis, most pronounced on the right eye. She cried a lot the first half year, feeding was normal. Early motor development was normal, and she walked at age 16 months. She had one febrile seizure at age 1 year. She was tubulated at 1 year and 3 months of age and had tonsillectomy and polypectomy at 2 years of age. Echocardiography soon after birth showed discrete ASD and VSD, which had resolved spontaneously at age 1 year. She had speech delay and a challenging behavior with hyperactivity, concentration difficulties, and reduced self-control. At 5 years and 4 months of age she was seen at the children psychiatric department under suspicion of ADHD, but she was too young to get this diagnosis. She attended normal elementary school but has learning difficulties. She had difficulties in motor skills with balancing and bicycling. At age 8 years and 8 months height was 127 cm (-1 SD), weight 24 kg (-1 SD), and head circumference 51 cm (-1 SD). Dysmorphic features were bilateral ptosis, thick eyebrows, misalignment of teeth, high palate, and protruding chin. Hands and feet were normal. A WISC-IV test at 8 year of age showed a total IQ of 80 with results of subtests spanning from 93 in verbal understanding to 69 in working memory.

Individual 2 (related to Decipher ID 341356) is the younger maternal half-brother of individual 1. He was born by uncomplicated vaginal delivery at gestational week 39+6 with Apgar scores 9/1, 10/5, and birth weight of 3610 grams (median), length 52 cm (median) and head circumference 36 cm (+1SD). At age 6 weeks he was admitted to the hospital after several apneic episodes at home. He walked at 16 months of age. He had speech delay and received speech therapy, and he had a tendency of falling. He had sleeping difficulties and uses a chain-quilt. He was described as hyperactive and easily distractible, and playing with other children requires adult supervision. He had hypermetropia +3 bilaterally. At age 6½ years height was 120 cm (- 0,5 SD), weight 22,9 kg (median), and head circumference 51 cm (median). He had elongated face, triangular protruding chin, slight bilateral ptosis and bilateral epicanthus, upwards slanting palpebral fissures and a slight overbite. Clinodactyly of 2. and 5. finger on the right hand and the 5. finger on the left hand as well as a simian crease on the left hand was seen. A WPPSI-IV test at 6 age years showed a total IQ of 80 with subtest results spanning from 103 in visuo-spatial understanding to 72 in verbal understanding.

Individual 3 (related to Decipher ID 341356) is the mother of individual 1 and 2. She was born at gestational week 39+2 with birthweight 3000 grams. She had congenital ptosis on the right eye and underwent surgery for this at 11 years of age. She had pes planus. She was diagnosed with mild developmental disorder of the type Minimal Brain Dysfunction as a young child, and later with attention deficit. She had difficulties in both fine and gross motor skills. In adulthood she was suspected for emotional personality disorder, but later she was diagnosed with ADHD for which she receives medical treatment (methylphenidat). At age 31 she was seen with heavy eyebrows, almond shaped eyes, angulated rim of upper eyelid on the right eye (after surgery for ptosis), broad nose, plump upper lip, and protruding chin. Hands and feet were normal.

Individual 4 (Not consented in Decipher) is a 10 year old boy with a small secundum ASD, but normal growth. Head circumference at 10 years and 10 months of age was 54.5cm (75th centile). He has behavioral problems and is diagnosed with ADHD for which he receives medical treatment (methylphenidate). Speech and language development was delayed. No words were used until 5 years of age. He receives speech therapy. Motor and social development were not delayed. He has learning difficulties. He had significant congenital bilateral ptosis for which he had surgery. Dysmorphic characteristics are small ear canals and small nipples. His speech is nasal (at 6 years of age he had adenotonsillectomy).

Individual 5 (Decipher ID 323214) is the first child born to healthy non-consanguineous white, European parents. Mother remained well during pregnancy, and patient was born at 39+2/40 gestation. Birth weight was 2920 grams and she did not require resuscitation or special care. Congenital ptosis was present, for which the patient underwent repair at 6 months of age. Her developmental impairment is predominantly motor: She sat at 8 months and has been cruising since 21 months. She had multiple words and was able to construct two-word phrases at 2 years of age. Her dysmorphic features include: Slender eyes, high forehead, high arched palate and pointed chin. Her general health is good. Her medical history includes eczema, convergent squint, partial 3rd and 6th nerve palsy, large angle esotropia. There is nil significant in the family history aside from both parents having dyslexia. Investigations to date: Biochemical profile normal. MRI brain and orbits aged 1 year was normal. KAT6B testing negative. Patient has been recruited into 100,000 genomes project. She continues to have regular physiotherapy input and is also under the care of the ophthalmology and general pediatric teams.

Individual 6 (Decipher ID 273541) is the male only child of non-consanguineous white British parents. The patient was referred to the Genetics Clinic at 3 years of age with concerns about his poor growth and speech delay. There was a history of short stature in his father (154cm, <0.4th centile) but he had a normal OFC (54 cm, 2nd centile) and no intellectual disability. The patient's mother was of normal height (161.5cm, 25th centile), OFC (56.1 cm, 75th centile) and intellect. There was no other family history of note. The patient was born by ventouse delivery at 38 weeks gestation following an uncomplicated pregnancy. His birth weight was 2500g (2nd-9th centile) and birth OFC 33.5cm (25th-50th centile). APGARS were 4 at 1 minute and 8 at 5 minutes. He required some bag and mask resuscitation and fed poorly in the first 24 hours but was discharged home at 48 hours of age. The patient bottle fed reasonably in infancy but only small volumes which were taken slowly. His weight fell below the 0.4th centile by 6 months of age and he remained small during childhood. The patient sat and crawled at 12 months and walked at 2 years. His OFC was 45.5 cm at 2 years and 10 months of age (<0.4th centile). When assessed at 3 years and 5 months of age he was still using single words. The patient had feeding difficulties (poor appetite, reluctant to chew, easy vomiting, milk coming out his nose) and frequent ear infections. A tonsillectomy was performed at 6 years of age and his feeding subsequently improved. The patient had particular difficulties with pronunciation and expressive language. He received speech therapy. He had eczema and a mild hearing impairment. There were no concerns about his vision. His behavior was generally good although his communication difficulties would sometimes make him frustrated. He generally slept well but was often restless in bed.

The patient was last assessed at 16 years and 3 months of age. He attended a special unit in a mainstream school. He was short with moderate intellectual disability and microcephaly. His speech and feeding were significantly improved. He had no history of seizures. He had a persistent cough which was thought to be due to either post-nasal drip or silent reflux, and he was having a trial of decongestant nasal spray, anti-reflux drugs (Gaviscon), proton pump inhibition drugs (omeprazole) and antihistamines. His growth parameters were height 159.2 cm (2nd centile), weight 39 kg (<0.4th centile) and OFC 50.5 cm (<0.4th centile). He had a pointed chin, slightly small deep-set eyes, large ears, malar hypoplasia, high palate and mildly misalignment of teeth. There was bilateral 5th finger camptodactyly and mild 2-3 toes syndactyly. His cardiovascular examination was normal. His neurological examination was normal apart from some mild muscular hypotonia.

Karyotype (46, XY), testing for Fragile X, TORCH screen, thyroid function test, sweat test, coeliac screen and basic hematology/biochemistry were all normal. Immunoglobulins were normal apart from a slightly reduced IgM level. Hand and foot X-rays and a head CT (at 3 years of age) were all reported to be normal. Array CGH found a 3.4 Mb deletion at 1p36.12 (19,098,854bp to 22,517,879 [hg19]). The deletion was confirmed by FISH and shown to be *de novo* by parental testing.

Individual 7 (Decipher ID 353745) is a 20 years-old boy, the 4th child of healthy non-consanguineous parents. The birth weight was 2750 g and Apgar score was 6 at 1 min and 7 at 5 min. At birth congenital heart defects with a subaortic ventricular septal defect (VSD), surgically corrected at 9 months, and pulmonary valve dysplasia were diagnosed. He showed persistent leukopenia due to EBV infection and thrombocytopenia. During the first months of his life, a pneumonia episode occurred. Physical examination at 20 years of age showed height 172 cm (3rd centile) and weight 58.9 kg (3rd centile). Craniofacial dysmorphisms consisted of long face, deep-set eyes, synophrys, thin palpebral fissures, blepharophimosis, short philtrum, ogival palate, scoliosis, arachnodactyly. His cognitive functioning was mildly impaired and scholar supporting was needed.

Individual 8 (Decipher ID 282936) is an 11 years old girl. She struggles with reading and writing and telling time and is assessed for dyslexia. She is good with money. She has short attention span but can fix on things if interested. She is good verbally and enjoys debating at school, and she has good memory for information she has been told or has seen on TV. She is prone to constipation and soiling and is treated with Movicol. She has been seen by Child and Adolescent Mental services because of lack of emotions and inappropriate reactions to death/ life-threatening or embarrassing situations. She is non-dysmorphic and does not have ptosis or any behaviour to suggest ADHD. She was said to be unable to sit still but did ok academically. It is not possible to get a sample from Dad.