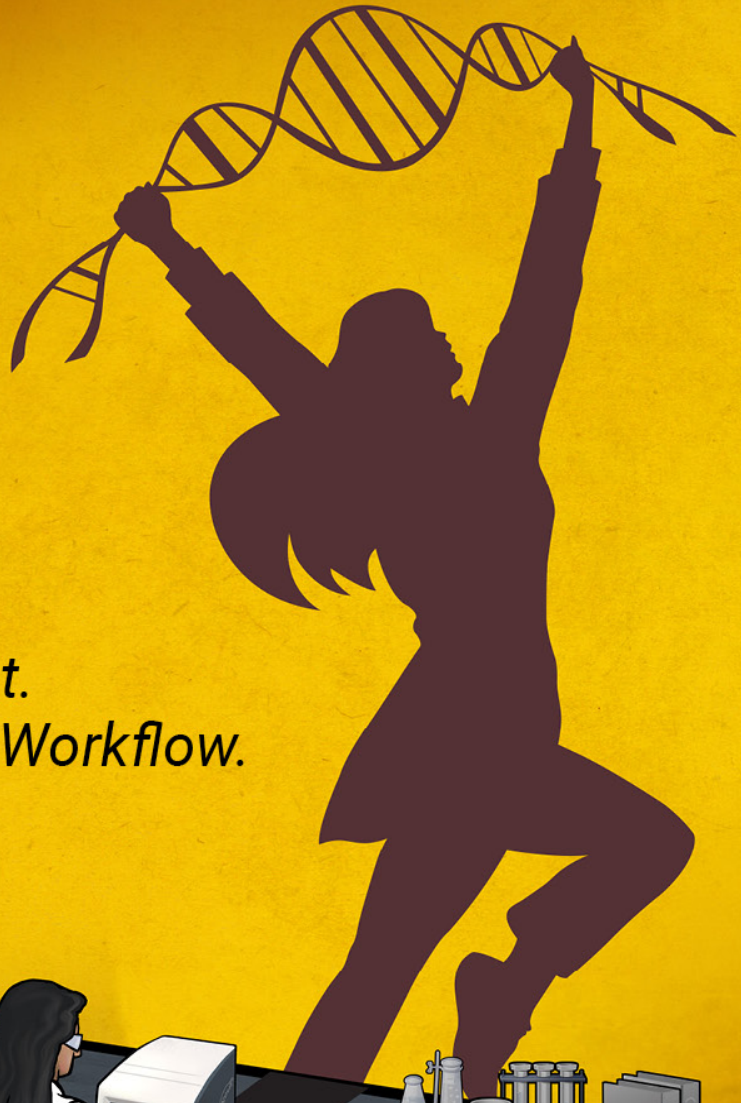



Small but Mighty

*One Small Instrument.
Take Charge of Your Workflow.*



The Spectrum Compact CE System offers Sanger sequencing and 6-dye fragment analysis. With an easy-to-use integrated touch screen, remote access software, plug-and-play prefilled consumables and unparalleled support, you can take charge of your workflow.

Discover the possibilities:

promega.com/SpectrumCompactCE



REVIEW

Head to head: should the intraductal component of invasive prostate cancer be graded?

Murali Varma^{1,2} & Jonathan I Epstein³ ¹Cardiff University, Cardiff, ²University Hospital of Wales, Cardiff, UK, and ³The Johns Hopkins Medical Institutions, Baltimore, MD, USA

Varma M & Epstein J I

(2021) *Histopathology* 78, 231–239. <https://doi.org/10.1111/his.14216>

Head to head: should the intraductal component of invasive prostate cancer be graded?

The reporting of intraductal carcinoma of the prostate (IDCP) is controversial, with conflicting recommendations having recently been published by the International Society of Urological Pathology (ISUP) and the Genitourinary Pathology Society (GUPS). Both recommend that isolated (pure) IDCP should not be graded. However, the ISUP recommends incorporating the

IDCP component of invasive prostate cancer in the Gleason score, whereas the GUPS recommends reporting IDCP as a comment, independently of the Gleason score. The arguments for and against incorporating the IDCP component of invasive prostate cancer in the Gleason score are discussed in detail.

Keywords: Genitourinary Pathology Society, Gleason grading, International Society of Urological Pathologists, intraductal carcinoma, prostate

Introduction

Intraductal carcinoma of the prostate (IDCP) is characterised by a lumen-spanning proliferation of atypical epithelium within expanded pre-existing prostatic ducts, with, at least, a partially preserved basal cell layer. IDCP was identified as a distinct entity in 1985,¹ and diagnostic criteria were described by McNeal *et al.* in 1996.² However, it gained more widespread recognition in 2006 following a report of prostate needle biopsies containing only IDCP by Guo and Epstein, who established the criteria for the diagnosis of IDCP, to be used especially on needle biopsies.³ Following a decade of extensive discussion in academic circles, IDCP was formally recognised as a biologically distinct entity in the 2016 edition of the World Health Organization classification of tumours of the prostate gland.⁴ This development and the

concurrent publication of the recommendations of the International Society of Urological Pathology (ISUP) consensus conference on Gleason grading⁵ has led to more widespread recognition of this entity by practising pathologists.

Recently, two international organisations, the ISUP and the Genitourinary Pathology Society (GUPS), have published independent updates on prostate cancer grading.^{6,7} Unfortunately, these have conflicting recommendations on the reporting of IDCP. Both recommend that isolated (pure) IDCP should not be graded. However, the ISUP recommends incorporating the IDCP component of invasive prostate cancer in the Gleason score (GS), whereas the GUPS recommends reporting IDCP as a comment, independently of the GS. Thus, a tumour with GS 4 + 3 and comedonecrosis IDCP would be reported as GS 4 + 5 = 9 according to the ISUP recommendations, but as GS 4 + 3 = 7 (comedonecrosis IDCP) according to the GUPS recommendations. This potentially confusing situation for pathologists and clinicians will make it difficult to render comparisons of prostate cancer cohorts graded according to different rules.

Address for correspondence: M Varma, Department of Cellular Pathology, University Hospital of Wales, Heath Park, Cardiff CF14 4XW, UK. e-mail: varmam@cardiff.ac.uk

We describe the rationales behind the contradictory ISUP and GUPS recommendations for reporting of IDCP associated with invasive prostate cancer. The views expressed in this article are personal opinions of the authors, and do not necessarily represent those of the ISUP or the GUPS.

Yes: the IDCP component of invasive prostate cancer should be incorporated in the GS (Murali Varma)

There are several scientific and practical arguments in favour of incorporating the IDCP component of invasive prostate cancer (IDCP-invasive) in the GS.

THE GLEASON GRADING SYSTEM IS BASED ON MORPHOLOGY

The scientific basis of Gleason grading remains the morphological examination of prostate cancer. All historical and contemporary Gleason outcome data are based on morphology without immunohistochemical examination to identify IDCP. As IDCP was not recorded as a separate prognostic factor in these studies, it is safe to assume that they had incorporated IDCP-invasive in the GS. Thus, comedonecrosis IDCP-invasive would have been graded as Gleason pattern 5 in these studies. Changing the established grading method would require evidence that the new approach is superior.

THERE IS NO EVIDENCE THAT EXCLUDING IDCP FROM THE GS IMPROVES PROGNOSTICATION

There are no outcome data indicating that IDCP-invasive has a better prognosis than the corresponding Gleason pattern. Khani and Epstein described three cases of biopsy GS 3 + 3 = 6 prostate cancer associated with IDCP-invasive in which no higher-grade invasive component was identified in corresponding prostatectomy specimens.⁸ However, these prostatectomy specimens had been only partially submitted for histological examination, precluding exclusion of unsampled higher-grade cancer. In contrast, several studies have reported that IDCP-invasive is generally associated with aggressive prostate cancer.⁹ The clinicopathological outcome of biopsy GS 3 + 3 = 6 invasive cancer associated with IDCP-invasive in the Khani and Epstein series was very different from that of biopsy GS 3 + 3 = 6, with 20% of patients showing disease progression, 13% developing metastases, and 7% suffering from prostate cancer mortality.⁸

Hence, prostate cancer grading would be less predictive of outcome if IDCP-invasive were to be excluded from the GS.

REPORTING GUIDELINES MUST NOT BE BASED ON RARE SCENARIOS

Although IDCP may rarely represent a precursor lesion, there is consensus that it generally represents invasive prostate cancer extending into pre-existing benign ducts/acini. Hence, in most cases, it will be invasive carcinoma that is being graded if IDCP-invasive in needle biopsies is incorporated in the GS. The biopsy GS provides an imperfect reflection of the true GS in the prostate gland, owing to the intrinsic sampling error of this technique,¹⁰ so clinical practice should be based on the more common scenario. In the rare scenario of GS 3 + 3 = 6 with cribriform IDCP-invasive, the case should be assigned GS 7 with an explanatory comment.

THERE IS NO INTERNATIONAL CONSENSUS ON EXCLUDING IDCP-INVASIVE FROM THE GS

IDCP is often discussed as a single entity, whereas it actually represents two biologically distinct entities requiring different reporting rules. IDCP-invasive is analogous to prostatic intraepithelial neoplasia (PIN)-like adenocarcinoma, which has the morphology of high-grade PIN but is a growth pattern of invasive prostate cancer. Hence, it would be appropriate to incorporate IDCP-invasive in the GS while not grading pure (precursor-type) IDCP. The 2014 ISUP consensus meeting on Gleason grading addressed only issues related to pure (isolated) IDCP. Grading of IDCP-invasive was not discussed or voted on in this meeting. The related publication states only that 'IDC-P without invasive carcinoma should not be assigned a Gleason grade'.⁵ Thus, there is no international consensus regarding the grading of IDCP-invasive.

ESTABLISHED IDCP CRITERIA MAY BE TOO STRINGENT FOR IDCP-INVASIVE

The widely used criteria for the diagnosis of IDCP are those described by Guo and Epstein.³ These criteria were established to identify patients with isolated (pure) IDCP in prostate biopsies who would be suitable for radical therapy even in the absence of an identified invasive component. Hence, the bar has been set very high to avoid overtreatment, and these criteria may be too restrictive for the diagnosis of

IDCP-invasive. Several studies have demonstrated that invasive prostate cancer associated with loose cribriform proliferations lacking necrosis and severe nuclear atypia has an outcome comparable to that of IDCP-invasive.^{11,12} Grading based on architecture would ensure that this component is categorised as Gleason pattern 4, whereas describing this component separately as 'atypical intraductal proliferation' would risk undergrading and undertreatment (Figure 1).

IMMUNOHISTOCHEMISTRY CANNOT EXCLUDE IDCP-INVASIVE

Exclusion of IDCP-invasive from the GS would require accurate and reproducible identification of IDCP, but an interobserver reproducibility study of 39 international experts found significant variation in the morphological diagnosis of IDCP.¹³ It is often challenging to accurately identify basal cells on routine examination, and definitive distinction of IDCP from invasive carcinoma would require immunohistochemistry. However, although basal cell marker immunoreactivity would support a diagnosis of IDCP, the absence of basal cells would not exclude IDCP. The basal cell layer is often very fragmented in expanded ducts of IDCP, and basal cells may be absent in the immunostained level (Figure 2). Thus, distinction of IDCP-invasive from invasive carcinoma may not be possible even with the use of immunohistochemistry. Variable interpretation of immunohistochemical findings could also aggravate the variation in IDCP reporting, even among experts. When a focus showed some comedonecrosis glands with basal cells and others without basal cells, Fine

*et al.*¹⁴ interpreted the focus as a combination of IDCP and invasive cancer, whereas Madan *et al.*¹⁵ would interpret the entire focus as IDCP-invasive.

QUESTIONING THE GRADING OF COMEDONECROSIS IDCP IS ASKING THE WRONG QUESTION

It has been argued that it would be inappropriate to grade comedonecrosis IDCP-invasive associated with low-grade cancer, as there is no evidence that such patients have an adverse outcome.¹⁴ However, such cases are rare, and it should be noted that there is also no evidence that patients with low-grade cancers associated with only focal comedonecrosis foci lacking basal cells have a worse outcome. Moreover, it will not be possible (particularly in needle biopsies) to exclude the possibility that the 'invasive comedonecrosis Gleason pattern 5' focus represents IDCP with basal cells that were not represented in the plane of section. It may be more reasonable to question whether comedonecrosis should be graded as Gleason pattern 5 (irrespective of the presence or absence of basal cells) rather than inconsistently grading some foci but not others.

In addition to the theoretical issues elucidated above, there are logistical issues with excluding IDCP-invasive from the GS.

VARIABLE UTILISATION OF IMMUNOHISTOCHEMISTRY IMPACTS ON IDCP RECOGNITION

There is significant variation in the utilisation of basal cell marker immunohistochemistry. Whereas

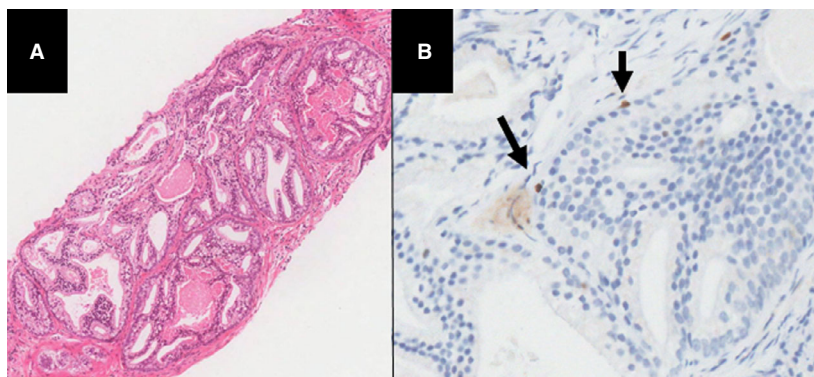


Figure 1. This focus (A), which was associated with invasive Gleason pattern 3 prostate cancer elsewhere in the biopsy (not illustrated), is morphologically consistent with cribriform Gleason pattern 4 but shows patchy basal cell marker immunoreactivity (B). The absence of comedonecrosis and marked nuclear enlargement in this loose cribriform proliferation precludes a diagnosis of intraductal carcinoma of the prostate. If grading were not based on morphology, then this case would have to be reported as Gleason score 3 + 3 prostatic adenocarcinoma with an associated atypical cribriform proliferation, which could result in undertreatment. (A, haematoxylin and eosin; B, p63.).

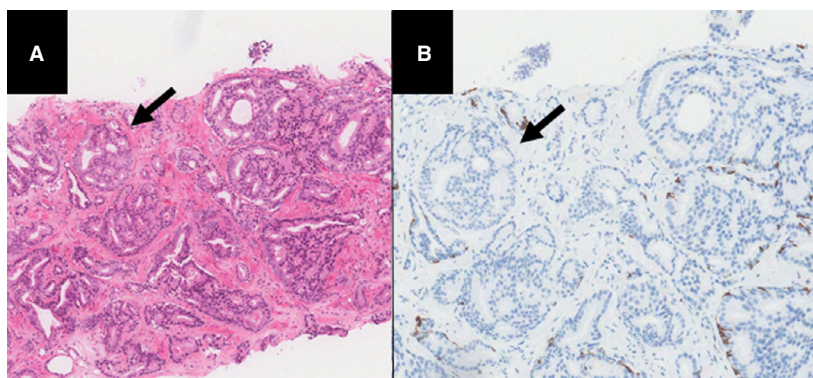


Figure 2. Gleason pattern 3 adenocarcinoma associated with cribriform glandular proliferation showing patchy basal cell marker (BCM) immunoreactivity, in keeping with intraductal carcinoma of the prostate (IDCP). The few cribriform glands lacking BCM immunoreactivity (arrow) are morphologically similar to adjacent cribriform glands with patchy BCM immunoreactivity, suggesting that these represent IDCP rather than invasive cancer. (A, haematoxylin and eosin; B, cytokeratin 5/6.). [Colour figure can be viewed at wileyonlinelibrary.com]

immunohistochemistry is used liberally in some institutions, others use it more sparingly or have limited access to this technique. International grading guidelines must be suitable for a variety of healthcare systems. Basing the GS on immunohistochemical findings risks rendering global comparisons of GS data meaningless. For example, a prostate biopsy with GS 4 + 3 invasive cancer and focal comedonecrosis would be graded as GS 4 + 5 = 9 by some pathologists, on the basis of morphology, whereas others would grade it as GS 4 + 3 = 7 associated with IDCP after immunohistochemical examination.

EXPERT GS ASSIGNMENT SHOULD NOT BE BASED ON NON-EXPERT PRACTICE

Most experts in a recent survey indicated that they would generally assign the GS on the basis of morphological identification of IDCP, but would exclude from the GS an IDCP component identified following immunohistochemistry performed by a referring non-expert pathologist.¹⁶ This could result in a case being graded differently by an expert according to whether the expert is the reporting or reviewing pathologist. Grading based on architecture would be more reproducible.

AN IDCP COMMENT MAY NOT BE ACTED UPON

The presence and significance of IDCP-invasive could be conveyed as a separate note, but this approach carries significant risk, as clinicians may disregard this information. Khani and Epstein reported that 11 (18%) patients with GS 3 + 3 = 6 plus IDCP-invasive were inappropriately managed by active surveillance,

despite the reports including a note highlighting the association of IDCP with unsampled high-grade cancer.⁸ The situation is likely to be worse in less developed healthcare systems, where the implication of IDCP is less likely to be appreciated by the pathologist and treating clinician. Most cancer registries do not record the presence of IDCP, so this critical prognostic information could be lost if not incorporated in the GS. Finally, IDCP is not part of most prognostic nomograms used to manage prostate cancer patients. It is noteworthy that similar arguments were used in the ISUP 2005 guidelines to recommend incorporating a minor component of higher-grade pattern in the biopsy GS rather than conveying this information in an accompanying note.¹⁷

PERCENTAGE OF GLEASON PATTERN 4 REPORTING IS SIMPLER IF IDCP-INVASIVE IS INCORPORATED IN THE GS

All international guidelines (GUPS, ISUP, and WHO) recommend reporting the percentage of Gleason pattern 4 in GS 7 tumours. Exclusion of cribriform IDCP-invasive from the GS would require its distinction from invasive cancer, which can be impossible without immunohistochemistry. The GUPS recommends performing immunohistochemistry only in cases in which the distinction would affect GS assignment. However, this recommendation could be confusing, particularly for general pathologists. For example, in many biopsies with prostate cancer that is morphologically GS 4 + 3 = 7, they would have to determine whether some of the cribriform component could represent IDCP, and then assess whether the GS would be altered by exclusion of this component.

International guidelines should not complicate pathology reporting unless there is clear evidence that the recommended practice has clinical utility. There is currently no evidence that the biological significance of cribriform IDCP-invasive differs from that of cribriform invasive prostate cancer.

INCONSISTENT RULES FOR INCLUSION OF IDCP IN TUMOUR GRADE AND EXTENT

Many expert urological pathologists currently incorporate IDCP-invasive in the determination of tumour extent but not in the GS.¹⁶ It would be more consistent to include IDCP-invasive in both prognostic indicators.

In the absence of evidence that the outcome of IDCP-invasive identified by immunohistochemistry is different from that of IDCP-invasive identified by morphology-based grading, it would be scientifically appropriate, simpler and more reproducible to convey the adverse prognostic significance of IDCP-invasive by incorporating it in the GS. This would ensure correct prognostication for most patients, particularly in prostate needle biopsies. Excluding IDCP-invasive from the GS would require greater use of sometimes limited immunohistochemical resources, and risk a significant number of patients being undertreated. For identification of IDCP-invasive to be based predominantly on morphology, evidence that generalists can reliably identify basal cells on haematoxylin and eosin (H&E)-stained sections would be required.

No: the IDCP component of invasive prostate cancer should be reported independently of the GS (Jonathan Epstein)

NOT ALL IDCPS REPRESENT THE INTRADUCTAL SPREAD OF HIGH-GRADE INVASIVE CARCINOMA

There are two different biological pathways in the development of IDCP. The majority of IDCPS are associated with invasive high-grade adenocarcinoma, and the IDCP is believed to represent retrograde intraductal spread of the invasive adenocarcinoma. However, a small subset of IDCPS are not associated with invasive high-grade adenocarcinoma, and appear to represent precursor lesions of prostate cancer.¹⁸

It would be problematic to grade IDCP as Gleason pattern 4 or 5 cancer in the small subset of cases that show only a low-grade (Grade Group 1) prostate cancer or no evidence of invasive cancer.^{8,19} Although these scenarios are very uncommon, grading rules should apply to all cases and not result in

erroneous grades even in a minority of patients for whom it would significantly adversely impact on prognosis and treatment. IDCPS with no invasive cancer or only low-grade invasive cancer probably represent precursor lesions that have significantly better prognostic characteristics than the more common IDCPS admixed with invasive high-grade cancer.¹⁸ I have seen several entirely embedded radical prostatectomy specimens with IDCP with necrosis that either lacked invasive cancer or only had associated focal GS 3 + 3 = 6 (Grade Group 1), and for which extensive immunohistochemical studies ruled out invasive high-grade cancer (Figures 3 and 4). In these cases, if IDCP had been graded, the grade would have been GS 4 + 5 = 9, which would have been inaccurate, as their prognosis should be excellent in the absence of either any invasive cancer or only focal low-grade cancer. In addition, if the IDCP had been graded, these patients could have received unnecessary potentially morbid adjuvant therapy. Grouping IDCP and prostate cancer together will also increase the likelihood that pathologists will not report IDCP. This may affect treatment. For example, National Comprehensive Cancer Network guidelines suggest genetic counselling or germline testing for several oncogenes if IDCP is identified.

GRADING IDCP ASSOCIATED WITH INVASIVE CANCER BUT NOT PURE IDCP IS NOT FEASIBLE

Both of the current authors agree on not grading pure IDCP. However, it can be almost impossible in some cases to determine whether a case is pure IDCP or GS 4 + 4 = 8 on routine H&E-stained sections. If the policy is to just group IDCP together with invasive cancer and grade the entire lesion, there will be the tendency to not distinguish IDCP from invasive cancer with immunohistochemistry. Consequently, there will probably be cases of pure IDCP that are graded as GS 4 + 4 = 8 or even GS 9 if the IDCP has necrosis. As noted above, these patients, on the basis of such biopsy grading, will be incorrectly labelled as having very aggressive cancer, resulting in potential overtreatment or incorrect treatment.

LACK OF EVIDENCE THAT GRADING IDCP AS INVASIVE CARCINOMA IS MORE ACCURATE PROGNOSTICALLY

In cases of GS 4 + 3 = 7 (Grade Group 3) or GS 3 + 4 = 7 (Grade Group 2) with IDCP showing comedonecrosis, if the IDCP were included in the grade the tumour would be GS 4 + 5 = 9 (Grade Group 5) or

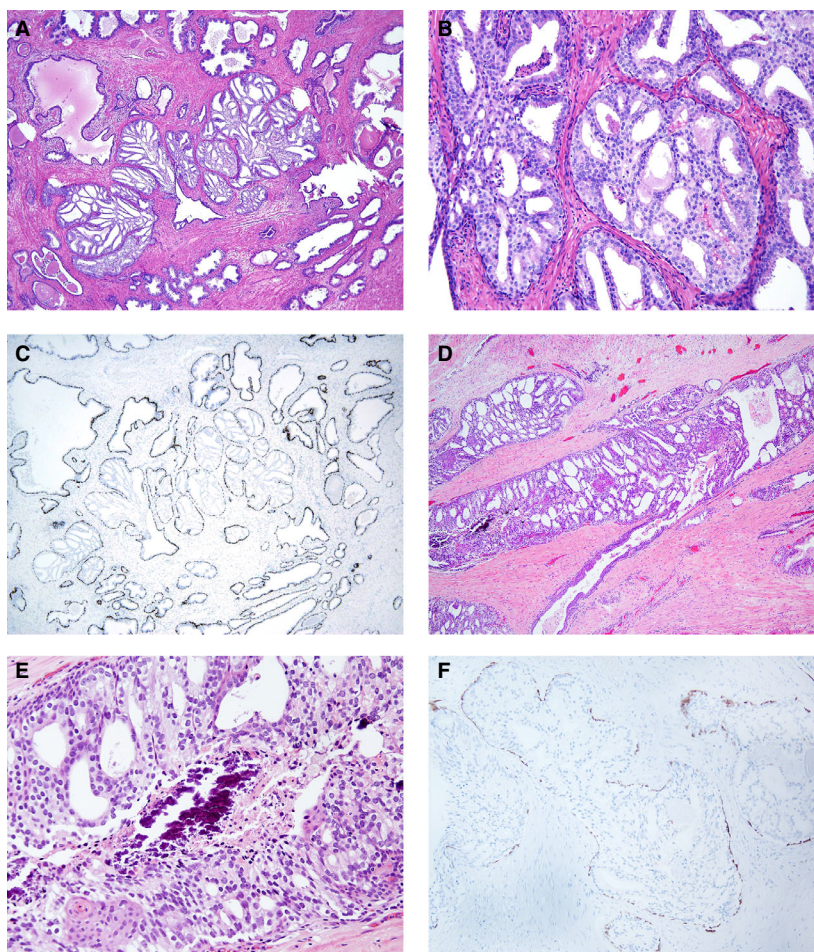


Figure 3. A, Representative image of a case of pure intraductal carcinoma of the prostate (IDCP) in a totally embedded radical prostatectomy specimen. B, Higher magnification of IDCP [same case as in (A)]. C, Immunohistochemistry for basal cell markers demonstrating intact basal cells around each gland of IDCP [same case as in (A) and (B)]. D, Pure IDCP in a large transurethral resection of the prostate specimen with extensive IDCP and no invasive carcinoma. E, Higher magnification of IDCP [same case as in (D)]. F, Immunohistochemistry for basal cell markers demonstrating intact basal cells around each gland of IDCP [same case as in (D) and (E)]

GS 3 + 5 = 8 (Grade Group 4), respectively. In the more common setting, if IDCP were graded, there would be GS 3 + 4 = 7 cases that would be upgraded to GS 4 + 3 = 7. Currently, no compelling data exist to support these increases in grade in these settings.

THE SPURIOUS CLAIM THAT HISTORICAL STUDIES INCORPORATED IDCP IN THE GRADE

One argument that has been proposed for grading IDCP as if it were invasive carcinoma is that, in historical studies in which grade correlated with prognosis, IDCP, if present, was graded as if it were invasive carcinoma. However, in these historical studies there would have been only a very small proportion of prostate cancer cases for which the highest grade would have changed if IDCP had been graded as

invasive carcinoma or not. The prognosis for this small proportion of cases with a grade change would not have any statistical impact on how well the highest grade overall in the study correlated with prognosis. Rather, the overall correlation of grade and prognosis would be driven by the much larger number of cases either lacking IDCP or in which IDCP was associated with invasive high-grade cancer. However, whether IDCP was graded could have a significant impact on an individual patient's management.

FLAWED STUDIES CONCLUDING THAT GRADING IDCP IS ACCURATE

The same faulty logic resulting in historical studies being cited has been used in contemporary studies

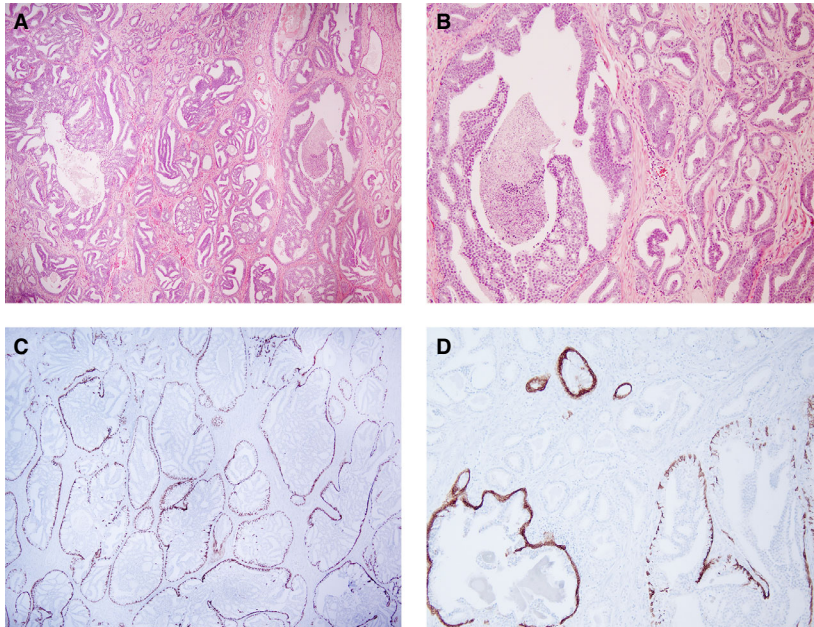


Figure 4. A, Low magnification of extensive intraductal carcinoma of the prostate (IDCP) associated with a small focus of Gleason score 3 + 3 = 6 in an entirely embedded radical prostatectomy. B, Higher magnification of (A) showing cribriform glands of IDCP with necrosis admixed with small, well-formed discrete glands of Gleason score 3 + 3 = 6. C, Low magnification of immunohistochemical staining for basal cell markers demonstrating intact basal cells around each gland of IDCP [same case as in (A) and (B)]. D, Higher magnification of immunohistochemical staining for basal cell markers demonstrating intact basal cells around each gland of IDCP and negative staining in small non-cribriform glands of Gleason score 3 + 3 = 6 [same case as in (A) and (B)]. [Colour figure can be viewed at wileyonlinelibrary.com]

determining how often incorporation of IDC in the grade would change the Grade Group.²⁰ Only cases in which the grade would be affected by the incorporation of IDCP should be analysed to determine whether the incorporation or exclusion of IDCP better correlates with prognosis. In addition, some of the contemporary studies have included cohorts of only sextant (six cores) biopsies, which is not relevant to current practice. IDCP sampled on sextant biopsy was probably markedly under-represented, and therefore its impact was minimal. Another flaw in these studies is the use of the H&E appearance to determine whether IDCP was present. In many cases with cribriform Gleason pattern 4, it is almost impossible to determine whether there is IDCP or infiltrating cribriform Gleason pattern 4. Finally, some studies have used 'Global Grade Group'; this involves averaging all the cancer in a case as if it were one long core and assigning a grade on that basis, and/or combining all of the tumour in a radical prostatectomy, as opposed to looking at the index tumour nodule grade. Reporting of only the global grade makes these studies not applicable to current practice in the USA and many other parts of the world, where assigning a global grade is not routine practice.

EXPEDIENCY IS NOT NECESSARILY BEST FOR PATIENT CARE

A frequent argument for including IDCP in the grade is that one cannot reliably identify basal cells on H&E-stained sections and, in some cases, immunohistochemistry is needed to identify IDCP in order to factor it out for grading. However, it is not necessary to perform basal cell immunohistochemistry on needle biopsy and radical prostatectomy specimens to identify IDCP if the results of the stains would not change the overall highest GS/Grade Group for the case. This is the situation in the vast majority of cases, as IDCP is typically associated with overt infiltrating high-grade cancer. In the setting of overt invasive high-grade carcinoma, it is reasonable to grade glands that have the differential diagnosis of high-grade carcinoma versus IDCP as all being invasive carcinoma. However, for the uncommon biopsy that shows either no definite invasive carcinoma or GS 6 cancer along with cribriform glands that include a differential diagnosis of IDCP versus Gleason pattern 4 cancer, one should perform immunohistochemistry for basal cell markers.

The counterargument states: 'Percentage Gleason pattern 4 reporting is simpler if IDCP with invasive

carcinoma is incorporated in the GS.' I agree that it is simpler, but we should not determine practice patterns on the basis of what is 'simpler'. As noted above, the GUPS recommends performing immunohistochemistry only in cases in which the distinction would affect the highest GS per part for the case. In terms of the percentage of Gleason pattern 4, the only situation in which immunohistochemistry would need to be performed would be if one could not distinguish between GS 3 + 4 = 7 (Grade Group 2) and GS 4 + 3 = 7 (Grade Group 3). This is very infrequent. Probably the most critical aspect of reporting the percentage of Gleason pattern 4 for Grade Group 2 is to identify patients whose cancers have a minimal percentage of Gleason pattern 4, and who, in certain circumstances, could be candidates for active surveillance. In patients with GS 3 + 4 = 7 (Grade Group 2), in whom the percentage of Gleason pattern 4 might vary according to whether IDC is present, this would not be critical. For example, consider a hypothetical case with the abnormal area consisting of 60% Gleason pattern 3, 10% poorly formed glands, and 30% cribriform glands, with a differential diagnosis of invasive Gleason pattern 4 or IDCP. If the cribriform glands were invasive, the diagnosis would be GS 3 + 4 = 7 (Grade Group 2) with 40% Gleason pattern 4. If the cribriform glands were IDCP, then the diagnosis would be GS 3 + 4 = 7 (Grade Group 2) with 14% (10/70) Gleason pattern 4 with extensive IDCP. Either diagnosis would rule out active surveillance, either because of a greater percentage of Gleason pattern 4 in the former situation, or the presence of IDCP in the latter situation.

In my busy consulting practice, where I see ~30 prostate cancers per day, approximately in one case per week it is necessary to perform basal cell stains for accurate grading. Sometimes doing what is best and most accurate for patient care may not be the easiest or cheapest practice, but it is critical for pathologists not to take short cuts and sacrifice quality.

In summary, incorporating IDCP in the grade is not based on studies specifically addressing the subset of cases in which the grade would be affected by including or excluding IDCP. For example, there is no evidence, either for biopsies or for prostatectomies, that the presence of IDCP (versus the absence) results in prognostic difference for each individual Grade Group (or GS). Such studies in contemporary patient cohorts and practice are sorely needed. However, evidence exists that incorporating IDCP will definitely result in the wrong grade for a small subset of patients with either no cancer or low-grade cancer associated with IDCP. In practice, there is only a

small subset of cases in which the presence of IDCP would change the grade, requiring basal cell immunohistochemistry to be performed. By not incorporating IDCP in the grade, future studies in a contemporary practice can be performed to assess the specific issue of whether grading IDCP or excluding it from the grade better correlates with prognosis.

Discussion

The GUPS and the ISUP concur on the reporting of pure IDCP, with both recommending that pure IDCP should not be graded, and that immunohistochemistry should be performed in such cases when no associated invasive component is identified. There is no fundamental disagreement between the ISUP and the GUPS regarding the clinical implication of IDCP associated with invasive prostate cancer. Both agree that the presence of an IDCP component in this setting is an adverse prognostic factor. The difference of opinion pertains to how this information should be conveyed to the treating clinician. The GUPS position is that incorporating IDCP in the GS would risk overgrading. For example, rare cases of biopsy GS 3 + 3 are not associated with unsampled high-grade prostate cancer. Hence, the GUPS recommends that the presence of IDCP be clearly documented (e.g. in the biopsy summary or in a synoptic format). Conversely, the ISUP position is that excluding IDCP from the GS risks undergrading, as most patients with biopsy GS 3 + 3 associated with IDCP have high-grade invasive prostate cancer. Hence, the ISUP recommends reporting such rare cases as GS 7 with an explanatory comment.

However, the current situation can be confusing for clinicians. When a prostate cancer report comments on the presence of associated IDCP, it may be unclear whether or not this component has been incorporated in the reported GS. There is a need for international consensus on this issue.

Author Contributions

The Introduction and Discussion were written jointly by the authors. The sections arguing for and against incorporating IDCP-invasive into the GS were written separately by the authors, as indicated in the article. The final version was approved by both authors. J. Epstein was the lead author of the GUPS white paper on prostate cancer grading. M. Varma chaired the IDCP working group at the ISUP consensus conference on grading of prostatic cancer (Nice, France, 2019).

Conflict of Interest

The authors have no conflict of interest to declare.

References

- Kovi J, Jackson MA, Heshmat MY. Ductal spread in prostatic carcinoma. *Cancer* 1985; **56**: 1566–1573.
- McNeal JE, Yemoto CE. Spread of adenocarcinoma within prostatic ducts and acini. Morphologic and clinical correlations. *Am. J. Surg. Pathol.* 1996; **20**: 802–814.
- Guo CC, Epstein JI. Intraductal carcinoma of the prostate on needle biopsy: histologic features and clinical significance. *Mod. Pathol.* 2006; **19**: 1528–1535.
- Epstein JI, Oxley J, Ro JY, Van der Kwast T, Zhou M. Tumours of the prostate: intraductal carcinoma. In Moch H, Humphrey PA, Ulbright TM, Reuter V eds. *World Health Organization classification of tumours of the urinary system and male genital organs*. Lyon:IARC Press, 2016; 64–165.
- Epstein JI, Egevad L, Amin MB *et al.* The 2014 International Society of Urological Pathology (ISUP) consensus conference on Gleason grading of prostatic carcinoma: definition of grading patterns and proposal for a new grading system. *Am. J. Surg. Pathol.* 2016; **40**: 244–252.
- van Leenders GJLH, van der Kwast TH, Grignon DJ *et al.* The 2019 International Society of Urological Pathology (ISUP) consensus conference on grading of prostatic carcinoma. *Am. J. Surg. Pathol.* 2020; **44**: e87–e99.
- Epstein JI, Amin MB, Fine SW *et al.* The 2019 Genitourinary Pathology Society (GUPS) White Paper on contemporary grading of prostate cancer. *Arch. Pathol. Lab. Med.* [published online ahead of print, 2020 Jun 26] 2020. <https://doi.org/10.5858/arpa.2020-0015-RA>.
- Khani F, Epstein JI. Prostate biopsy specimens with Gleason 3+3=6 and intraductal carcinoma: radical prostatectomy findings and clinical outcomes. *Am. J. Surg. Pathol.* 2015; **39**: 1383–1389.
- Varma M, Delahunt B, Egevad L, Samaratunga H, Kristiansen G. Intraductal carcinoma of the prostate: a critical re-appraisal. *Virchows Arch.* 2019; **474**: 525–534.
- Danneman D, Drevin L, Delahunt B *et al.* Accuracy of prostate biopsies for predicting Gleason score in radical prostatectomy specimens. Nationwide trends 2000–2012. *BJU Int.* 2017; **119**: 50–56.
- Shah RB, Nguyen JK, Przybycin CG *et al.* Atypical intraductal proliferation detected in prostate needle biopsy is a marker of unsampled intraductal carcinoma and other adverse pathological features: a prospective clinicopathological study of 62 cases with emphasis on pathological outcomes. *Histopathology* 2019; **75**: 346–353.
- Hickman RA, Yu H, Li J *et al.* Atypical intraductal cribriform proliferations of the prostate exhibit similar molecular and clinicopathologic characteristics as intraductal carcinoma of the prostate. *Am. J. Surg. Pathol.* 2017; **41**: 550–556.
- Iczkowski KA, Egevad L, Ma J *et al.* Intraductal carcinoma of the prostate: interobserver reproducibility survey of 39 urologic pathologists. *Ann. Diagn. Pathol.* 2014; **18**: 333–342.
- Fine SW, Al-Ahmadie HA, Chen YB, Gopalan A, Tickoo SK, Reuter VE. Comedonecrosis revisited: strong association with intraductal carcinoma of the prostate. *Am. J. Surg. Pathol.* 2018; **42**: 1036–1041.
- Madan R, Deebajah M, Alanee S *et al.* Prostate cancer with comedonecrosis is frequently, but not exclusively, intraductal carcinoma: a need for reappraisal of grading criteria. *Histopathology* 2019; **74**: 1081–1087.
- Gandhi JS, Smith SC, Paner GP *et al.* Reporting practices and resource utilization in the era of intraductal carcinoma of the prostate: a survey of genitourinary subspecialists. *Am. J. Surg. Pathol.* 2020; **44**: 673–680.
- Epstein JI, Allsbrook WC, Amin MB, Egevad L, ISUP Grading Committee. The 2005 International Society of Urological Pathology (ISUP) consensus conference on Gleason grading of prostate carcinoma. *Am. J. Surg. Pathol.* 2005; **29**: 1228–1242.
- Miyai K, Divatia MK, Shen SS, Miles BJ, Ayala AG, Ro JY. Heterogeneous clinicopathological features of intraductal carcinoma of the prostate: a comparison between ‘precursor-like’ and ‘regular type’ lesions. *Int. J. Clin. Exp. Pathol.* 2014; **7**: 2518–2526.
- Robinson BD, Epstein JI. Intraductal carcinoma of the prostate without invasive carcinoma on needle biopsy: emphasis on radical prostatectomy findings. *J. Urol.* 2010; **184**: 1328–1333.
- Rijstenberg L, Hansum T, Hollemans E *et al.* Intraductal carcinoma has minimal impact on Grade Group assignment in prostate cancer biopsy and radical prostatectomy specimens. *Histopathology* [published online ahead of print, 2020 Jun 15]. 2020. <https://doi.org/10.1111/his.14179>.