

This is an Open Access document downloaded from ORCA, Cardiff University's institutional repository: <https://orca.cardiff.ac.uk/id/eprint/149190/>

This is the author's version of a work that was submitted to / accepted for publication.

Citation for final published version:

Shetty, Shashikant, Janardhanan, Anupama, Perumalswamy, Vijaylakshmi, Mishra, Chitaranjan and Dunn, Matt J. 2022. Acquired vertical pendular nystagmus in diffuse unilateral subacute neuroretinitis: A diagnostic dilemma. *Indian Journal of Ophthalmology - Case Reports* 2 (2) , pp. 503-505. 10.4103/ijo.IJO_2360_21

Publishers page: http://dx.doi.org/10.4103/ijo.IJO_2360_21

Please note:

Changes made as a result of publishing processes such as copy-editing, formatting and page numbers may not be reflected in this version. For the definitive version of this publication, please refer to the published source. You are advised to consult the publisher's version if you wish to cite this paper.

This version is being made available in accordance with publisher policies. See <http://orca.cf.ac.uk/policies.html> for usage policies. Copyright and moral rights for publications made available in ORCA are retained by the copyright holders.



Acquired vertical pendular nystagmus in diffuse unilateral subacute neuroretinitis: A diagnostic dilemma

Anupama Janardhanan, Vijaylakshmi Perumalswamy, Shashikant Shetty, Chitaranjan Mishra¹, Matt J Dunn²

A retinal infectious pathology, an acquired vertical nystagmus, and a suspicious neuroimaging result! Independently, these three entities are not uncommon. However, when they are consecutively observed in a young patient, it ramifies into an intriguing clinical scenario. A 17-year-old diagnosed case of diffuse unilateral subacute neuroretinitis presented to us with acute-onset vertical oscillations. On neuroimaging, she was found to have cerebellar dysgenesis. This case prompted us to revisit the pathogenesis of acquired vertical nystagmus and evaluate whether it resulted from disturbance of afferent (severe visual impairment) or efferent (cerebellar dysfunction) components of the neural integrator mechanism.

Key words: Cerebellar dysgenesis, neuroretinitis, pendular nystagmus, vertical oscillations

Diffuse unilateral subacute neuroretinitis (DUSN) is an inflammatory retinal degeneration caused by a motile nematode, leading to severe vision loss. It penetrates the subretinal space and inflicts retinal damage as it progresses.^[1]

Vertical pendular nystagmus is etiologically diverse. A slow frequency pendular vertical eye oscillation known as the Hiemann-Bielchowsky phenomenon (HBP) is frequently noted in young patients with profound vision loss.^[2] Acquired vertical pendular nystagmus is usually attributed to underlying neurological disorders, although 13% may be attributed to a non-neurological cause.^[3]

Here, we describe a case report with an interesting sequence of findings leading to a diagnostic dilemma.

Video available on: www.ijoreports.in

Access this article online

Quick Response Code:



Website:

www.ijoreports.in

DOI:

10.4103/ijor.IJO_2360_21

Departments of Paediatric Ophthalmology and Strabismus Services and ¹Vitreo-Retinal Services, Aravind Eye Hospital and Postgraduate Institute of Ophthalmology, Madurai, Tamil Nadu, India, ²School of Optometry and Vision Sciences, Cardiff University, Cardiff, United Kingdom

Correspondence to: Dr. Shashikant Shetty, Head of the Department, Department of Paediatric Ophthalmology and Strabismus Services, Aravind Eye Hospital, Anna Nagar, Madurai - 625 020, Tamil Nadu, India. E-mail: drshashikants1@gmail.com

Received: 09-Sep-2021

Revision: 02-Nov-2021

Accepted: 24-Nov-2021

Published: 13-Apr-2022

Case Report

A 17-year-old female patient presented to us with gradual progressive painless loss of vision in the right eye (RE) over 6 months. She also complained of abnormal vertical eye movements in RE for the last 10 days, noticed by her relatives.

On examination, the best-corrected visual acuity (BCVA) of the RE was perception of hand movements only, and left eye (LE) BCVA was 20/20 (0.00 logMAR).

Pupil evaluation showed a grade 3, relatively afferent pupillary defect in the RE; slit-lamp biomicroscopy did not reveal any other abnormality. There was no evidence of anterior chamber inflammation or lenticular opacity. Fundus examination (RE) showed old anterior vitreous face cells (2+; SUN classification^[4]). There was diffuse disc pallor, attenuated arterioles, and retinal pigment epithelial (RPE) degeneration at the macula with an epiretinal membrane. The peripheral retina showed pigment clumps in the equatorial region and diffuse RPE degeneration with vitreous condensation. Fundus features and autofluorescence were compatible with late-stage DUSN (consistent with de Amorim Garcia Filho *et al.*)^[1] [Fig. 1a and b].

Spectral-domain optical coherence tomography centered on the fovea and optic disc was performed using high-definition 5-line raster scans and three-dimensional 512 × 128 macular cube scans passing through the fovea and optic disc of the RE. It revealed RPE atrophy at the macula [Fig. 1c].

Ocular motility evaluation confirmed a low-amplitude (0.4°), medium-frequency (3.7 Hz) asymmetrical unilateral vertical pendular nystagmus in the RE (video clip). There was no variation with change in gaze/posture/head tilt or on convergence. Ocular movements were full. Nystagmus was recorded using a high-speed eye tracker. In accordance with the clinical diagnosis, it demonstrated a uniform sinusoidal pattern along the vertical plane [Fig. 2a]. Computed tomography scan of the brain showed cerebellar dysgenesis with prominent cerebellar sulci [Fig. 2b and c]. Systemic examination including a detailed neurological evaluation revealed no abnormal findings or neurological deficits. Ocular examination of LE was normal. In light of this, the patient was advised to attend regular follow-up appointments.

Discussion

The causative nematode of DUSN has an affinity for the posterior pole of the retina. According to the literature, 71% of patients develop severe irreversible vision loss, and 92% are diagnosed in the late stage, as with the case presented here.^[1]

This is an open access journal, and articles are distributed under the terms of the Creative Commons Attribution-NonCommercial-ShareAlike 4.0 License, which allows others to remix, tweak, and build upon the work non-commercially, as long as appropriate credit is given and the new creations are licensed under the identical terms.

For reprints contact: WKHLRPMedknow_reprints@wolterskluwer.com

Cite this article as: Janardhanan A, Perumalswamy V, Shetty S, Mishra C, Dunn MJ. Acquired vertical pendular nystagmus in diffuse unilateral subacute neuroretinitis: A diagnostic dilemma. *Indian J Ophthalmol Case Rep* 2022;2:503-5.

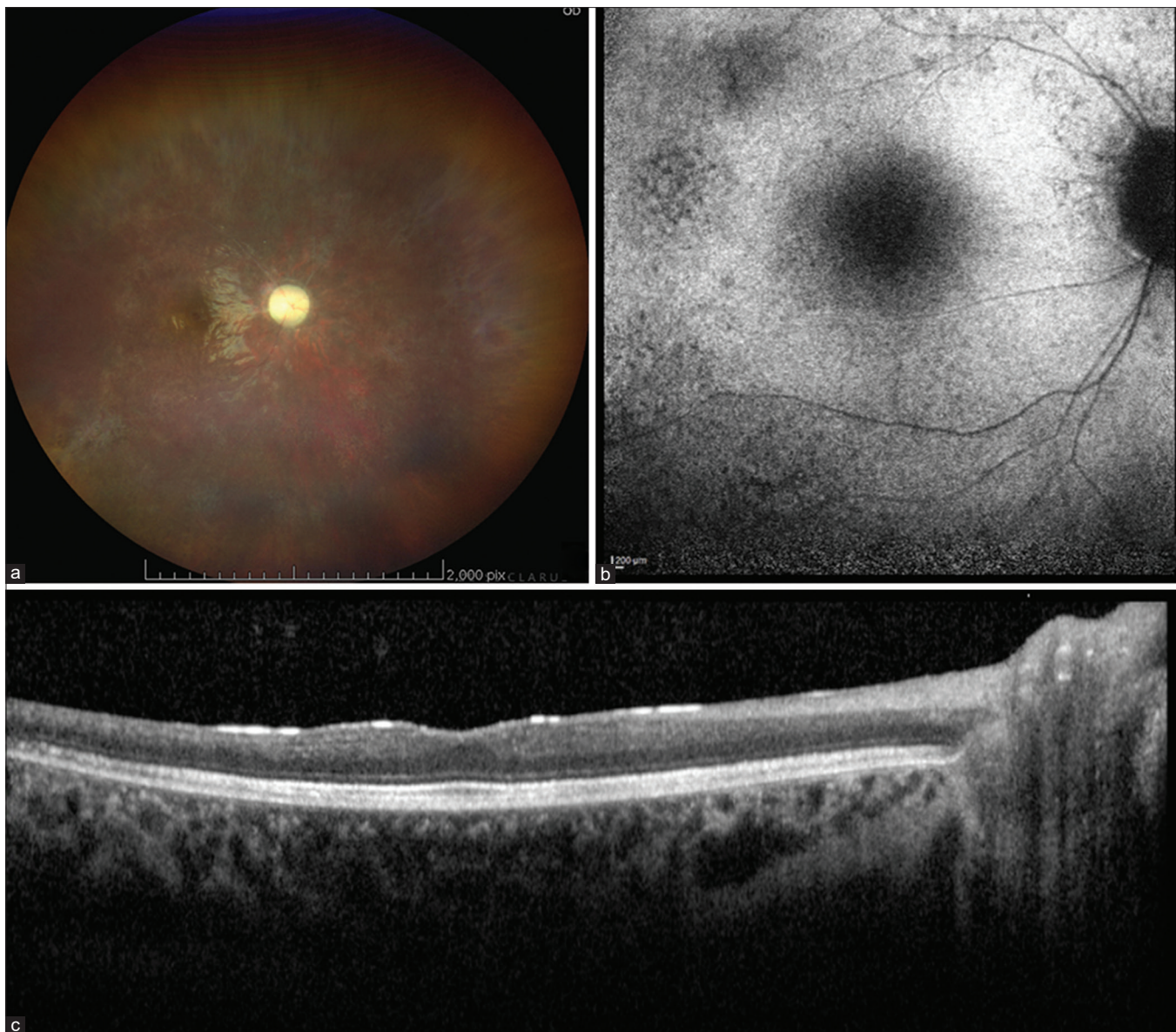


Figure 1: (a) Wide-angle fundus image showing disc pallor, attenuated arterioles, and RPE degeneration at the macula with an epiretinal membrane (ERM). The peripheral retina showing pigment clumps with diffuse RPE degeneration. Device: Clarus™ 500 (Carl Zeiss Meditech Inc., USA) (b) Fundus autofluorescence showing hypoautofluorescence at the fovea and patchy hypoautofluorescence along the arcades, suggestive of RPE degeneration. (c) OCT of the macula showing thinning of the inner retinal layers more than the outer retinal layers with hyperreflective ERM. Device for b and c: Spectralis HRA (Heidelberg Engineering, Germany)

Our diagnostic dilemma was whether the unocular vertical pendular nystagmus was a result of vision loss due to HBP or was it due to the cerebellar pathology.

HBP is characterized by involuntary, unilateral, coarse, slow drifting movements and is usually associated with severe vision loss. It typically has a frequency of <1 Hz, an amplitude of about 5° or less, and a velocity of not more than 25°/s.^[6] Leigh *et al.* proposed HBP to be a result of fluctuations in yoking mechanisms.^[6] Davey *et al.*^[7] believed that the condition arises due to the loss of potential for fusion. He differentiated HBP from acquired vertical pendular nystagmus of neurological cause by its characteristics as HBP tends to have a lower frequency and higher amplitude.

Our case exhibited an acquired vertical pendular nystagmus with medium-frequency (3.7 Hz) oscillations. Therefore, we deemed it unlikely to be HBP.

The mechanism leading to the development of vertical pendular nystagmus in neurological cases has been proposed to be disruption of the neural integrator system. Normal gaze shifting involves the collaboration of visual, cerebellar, and proprioceptive feedback and their action at the extraocular muscles. Obstruction at any of these steps may cause involuntary oscillating eye movements. Long-term overcompensation by feedback circuits results in an inconsistent neural integrator signal, potentially leading to an acquired pendular nystagmus.^[8]

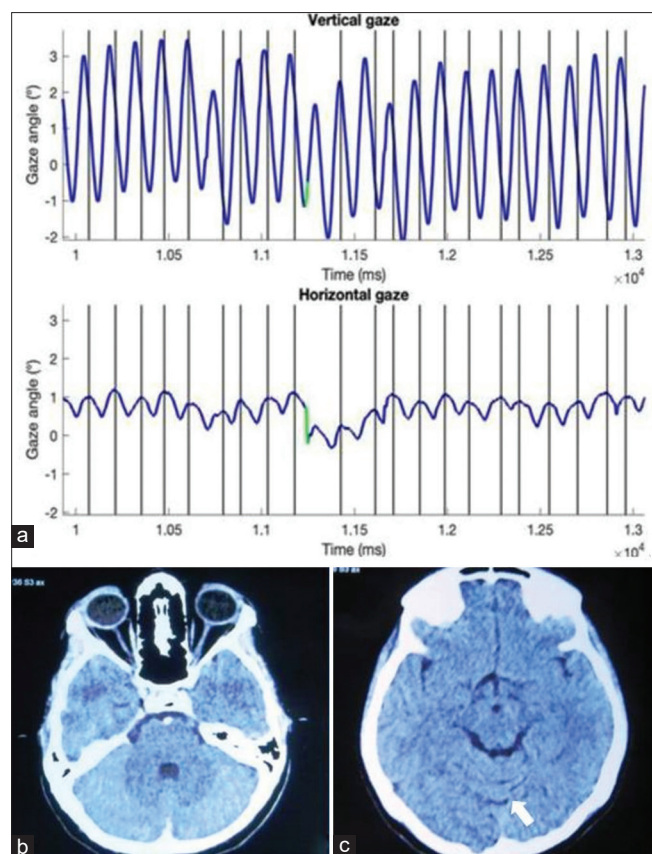


Figure 2: (a) Nystagmogram of the patient (RE), showing vertical pendular nystagmus. Vertical black lines indicate nystagmus cycles. The green portion indicates a saccade. Eye tracker: EyeLink 1000+ (SR Research, Canada) (b and c) Computed tomography of the brain. Axial section showing cerebellar dysgenesis and prominent cerebellar sulci (white arrow)

Multiple sclerosis (MS) is the most common etiology of acquired vertical nystagmus.^[3,8] MS was ruled out for our patient by neuroimaging and clinical evaluation. Many authors have proposed that acquired pendular nystagmus may result from cerebellar afflictions.^[9,10] Carota *et al.*^[9] suggested that damage to the projections arising from the paramedian cerebellar tract culminating into the pontine tegmentum leads to denervation of the dorsal cap of the inferior olive and results in the development of vertical nystagmus.

Because our patient did not report any other features suggestive of cerebellar involvement (oscillopsia, vertigo, or any gait abnormality),^[10] the nystagmus could either be an isolated presentation or an early presentation of cerebellar pathology yet to produce systemic features.

Conclusion

We present this case because of the diagnostic challenge it posed. We conclude that the vertical pendular nystagmus in our patient

appears to be due to an underlying neurological (cerebellar) cause resulting from disruption of the gaze stability mechanism and manifesting in a pronounced manner due to the vision loss. This atypical presentation throws light on the well-crafted neural integrator pathways that keep a check on abnormal eye movements.

Declaration of patient consent

The authors certify that they have obtained all appropriate patient consent forms. In the form the patient(s) has/have given his/her/their consent for his/her/their images and other clinical information to be reported in the journal. The patients understand that their names and initials will not be published and due efforts will be made to conceal their identity, but anonymity cannot be guaranteed.

Financial support and sponsorship

Nil.

Conflicts of interest

There are no conflicts of interest.

References

- de Amorim Garcia Filho CA, Gomes AH, de A Garcia Soares AC, de Amorim Garcia CA. Clinical features of 121 patients with diffuse unilateral subacute neuroretinitis. *Am J Ophthalmol* 2012;153:743–9.
- Schneider RM, Thurtell MJ, Eisele S, Lincoff N, Bala E, Leigh J. Neurological basis for eye movements of the blind. *PLoS One* 2013;8:e56556.
- Shawkat FS, Kriss A, Thompson D. Vertical or asymmetric nystagmus need not imply neurological disease. *Br J Ophthalmol* 2000;84:175–80.
- Jabs DA, Nussenblatt RB, Rosenbaum JT; Standardization of Uveitis Nomenclature (SUN) Working Group. Standardization of uveitis nomenclature for reporting clinical data. Results of the First International Workshop. *Am J Ophthalmol* 2005;140:509–16.
- Yee RD, Jelks GW, Baloh RW, Honrubia V. Uniocular nystagmus in monocular visual loss. *Ophthalmology* 1979;86:511–8.
- Leigh RJ, Thurston SE, Tomsak RL, Grossman GE, Lanska DJ. Effect of monocular visual loss upon stability of gaze. *Invest Ophthalmol Vis Sci* 1989;30:288–92.
- Davey K, Kowal L, Friling R, Georgievski Z, Sandbach J. The Heimann-Bielschowsky phenomenon: Dissociated vertical nystagmus. *Aust N Z J Ophthalmol* 1998;26:237–40.
- Kang S, Shaikh AGJ. Acquired pendular nystagmus. *Neuro Sci* 2017;375:8–17.
- Carota A, Düron N, Cereda C. Vertical pendular nystagmus and hypertrophic inferior olivary nuclei degeneration: An “odd couple”. *J Neurol* 2012;259:372–4.
- Lee H, Kim HA. Acute vertical pendular nystagmus and delayed oculopalatal tremor in a patient with bilateral horizontal gaze palsy. *J Clin Neurol* 2020;16:163–5.