

This is an Open Access document downloaded from ORCA, Cardiff University's institutional repository: <https://orca.cardiff.ac.uk/id/eprint/157415/>

This is the author's version of a work that was submitted to / accepted for publication.

Citation for final published version:

Pickrell, William Owen and Fry, Andrew E. 2023. Epilepsy genetics: a practical guide for adult neurologists. *Practical Neurology* 23 (2) , pp. 111-119. 10.1136/pn-2022-003623

Publishers page: <http://dx.doi.org/10.1136/pn-2022-003623>

Please note:

Changes made as a result of publishing processes such as copy-editing, formatting and page numbers may not be reflected in this version. For the definitive version of this publication, please refer to the published source. You are advised to consult the publisher's version if you wish to cite this paper.

This version is being made available in accordance with publisher policies. See <http://orca.cf.ac.uk/policies.html> for usage policies. Copyright and moral rights for publications made available in ORCA are retained by the copyright holders.



Epilepsy Genetics – A Practical Guide for Adult Neurologists

William Owen Pickrell^{1,2} and Andrew E. Fry.^{3,4}

¹Department of Neurology, Morriston Hospital, Swansea Bay University Health Board, Swansea, Wales, UK

²Swansea University Medical School, Swansea University, Swansea, Wales, UK

³All Wales Medical Genomics Service, University Hospital of Wales, Heath Park, Cardiff, Wales, UK CF14 4XW

⁴Division of Cancer and Genetics, School of Medicine, Cardiff University, Cardiff, Wales UK CF14 4XN, UK

Current Word Count (Limit 4000): Main text = 3028

Tables = 4

Figures =3

Boxes = 2

References = 78

Correspondence to Owen Pickrell, w.o.pickrell@swansea.ac.uk

Keywords

Epilepsy, genetics, adults.

Abstract

An understanding of epilepsy genetics is important for the adult neurologist as genetic diagnoses are of clinical benefit. In this review we describe the key features of different groups of genetic epilepsies. We describe the common genetic tests that are available and how to interpret them.

Key Points

- A genetic cause can be found for a proportion of adults with certain types of epilepsy and can be of clinical benefit.
- Epilepsy gene panels/whole exome sequencing and chromosomal microarrays are typically first line genetic tests with increasing use of genome sequencing.
- Genetic diagnoses can be missed in the paediatric clinic, be sceptical about historical aetiological diagnoses.
- Consider reviewing previous non-diagnostic genetic results in light of new evidence.
- Discussing genetic test results and cases within a multidisciplinary team including clinical geneticists and bioinformaticians is recommended.

Introduction

We have known about the link between epilepsy and genetics for a long time; Hippocrates wrote of epilepsy: “its origin is hereditary, like that of other diseases”.¹ However, it wasn’t until 1995 that the first epilepsy gene was discovered.² Since then, significant advances have been made in our understanding of epilepsy genetics. Although there is much we don’t understand, particularly in terms of the genetic architecture of the more common epilepsies, enough is now known that genetic diagnoses can be made and used to influence treatment decisions in the adult neurology clinic.

Most (but not all) single gene (monogenic) epilepsies will present in childhood and be diagnosed by our paediatric specialist colleagues. However, many of these children will transition to adult services where the genetic diagnosis may influence prognosis and treatment. The diagnosis might not have been made in the paediatric clinic.^{3,4} Precision therapies for certain epilepsies are available and will be an increasing part of clinical practice.⁵ It is important therefore that the adult neurologist has an understanding of epilepsy genetics. We do not offer a comprehensive review of epilepsy genetics here but describe key practical points for the adult neurologist seeing patients with epilepsy.

Taking a History

A *family history* is obviously important, but it is worth remembering that epilepsy is sometimes not fully disclosed in families, particularly in older generations. Speak with older family members if possible.⁶ Parents and grandparents can also help with recording the presence of febrile seizures in the patient and other family members which can be useful for the diagnosis of Genetic Epilepsy with Febrile Seizures plus (GEFS+) — figure 1.⁶ Typical

febrile seizures are convulsive and occur in the context of fever between the ages of 6 months and 6 years. *Febrile seizures plus* (FS+) occur outside this age or may consist of seizures that occur with and without fever.⁷ Prolonged febrile seizures, particularly with a hemiclonic component, are associated with Dravet's syndrome.⁸ Some monogenic epilepsies are due to *de novo* [footnote: Occurring due to a new mutation and not present in parents] or recessive mutations and there may be little or no family history in these situations.

The *age of onset* of different seizure types is particularly important and may give clues to a genetic diagnosis. For example early onset absence epilepsy (absences occurring in a child less than four years old) is associated with *SLC2A1* mutations⁹, most seizures start before the age of 20 in autosomal dominant nocturnal frontal lobe epilepsy,¹⁰ and age of onset helps with diagnosing particular developmental and epileptic encephalopathies (DEEs) (table 1).

Birth details are traditionally part of the epilepsy history given that perinatal events can cause epilepsy. However, changes in neonatal care have, for the most part, improved outcomes, and having a premature or a traumatic birth or a previous label of cerebral palsy might not exclude a genetic cause for epilepsy. In a recent study, 58% of adults with epilepsy and intellectual disability, who had previously been thought to have a known historic cause for their epilepsy such as perinatal trauma, were found to have a genetic diagnosis.⁴ Infants with neurological abnormalities may also be more likely to have difficult deliveries e.g. due to hypotonia.

Specific scenarios

Developmental and Epileptic encephalopathies.

DEEs are an overlapping group of syndromes, normally presenting in childhood, with severe epilepsy and associated cognitive and behavioural impairment. The seizures themselves may be the key driver to the cognitive impairment (epileptic encephalopathy) or play a less prominent role (developmental encephalopathy) but most often there is a significant overlap.¹¹

The vast majority of DEEs present in childhood but a significant proportion of patients transition to, or present in the adult clinic.^{3,4} In the adult neurology clinic we have an opportunity to make a genetic diagnosis in previously "unsolved" DEEs or DEEs falsely ascribed to symptomatic causes such as mild perinatal trauma.⁴ We also need to be aware of specific treatment options for some DEEs.

Although structural and metabolic brain problems can cause DEEs, they are mostly genetic in origin. Significant inroads have been made in understanding the underlying genetics of these disorders which are often associated with *de novo* mutations.¹² There are over one hundred genes associated with DEEs.^{12,13}

Epilepsy gene panels or whole exome/genome sequencing are standard diagnostic clinical tests for patients with DEEs and should be requested if not already done so. In some ways these tests reduce the need to remember the large number of genes associated with DEEs.¹² Be familiar with some of the more important DEEs though (table 1) as having a clear epilepsy phenotype can help interpret genetic results. However, many individuals with a

DEE do not have a distinct phenotype and genetic testing should still be considered in these cases.

Syndrome	Age at onset	Clinical Features / Pointers	Genetics
Dravet syndrome	1 st year of life, typically around 6 months	Seizures associated with fever (especially hemiclonic, or status epilepticus) common at onset. Multiple seizure types in the first year: hemiclonic, myoclonic and focal seizures with status epilepticus. Development delay usually apparent in second year and usually moderate to severe intellectual impairment. Seizures (and fever sensitivity) persist throughout life but frequency may decrease. Higher risk of sudden unexplained death in epilepsy (SUDEP). Motor problems (“crouching” gait) and decline in mobility, behavioural problems and swallowing difficulties feature in adulthood. ¹⁴ Sodium channel anti-seizure medications can make seizures worse. Treatment options include fenfluramine, cannibidol and ketogenic diet. ^{8 15 16}	>80% have pathogenic <i>SCN1A</i> variants. ¹⁷ Other genes associated with similar phenotype include <i>GABRA1</i> , <i>GABRG2</i> , <i>HCN1</i> , <i>KCNA2</i> , <i>SCN1B</i> . ¹⁸
Early infantile epileptic encephalopathy Ohtahara syndrome	0–3 months	Frequent intractable seizures, tonic seizures. Consider <i>early myoclonic encephalopathy</i> if myoclonic seizures predominate. Structural brain aetiology most common. Also, metabolic as well as genetic causes. Can evolve to West or Lennox-Gastaut Syndrome. Normally severe developmental delay. Abnormal EEG with burst suppression can evolve to hypsarrhythmia. ¹²	<i>STXBP1</i> (most common maybe 10%) others include <i>SCN2A</i> , <i>STXBP1</i> , and <i>KCNQ2</i> . ¹²
Epilepsy of infancy with migrating focal seizures	1 st year of life, typically 0–6 months	Rare and severe with focal seizures migrating between hemispheres. Most have severe developmental problems after onset of seizures. EEG can be normal initially, slowing with time, ictal changes correlate with seizures. ^{12 19}	Genes include <i>KCNT1</i> (30%), <i>SCN2A</i> , <i>SCN1A</i> , <i>PLCB1</i> , <i>TBC1D24</i> and <i>CHD2</i> . ¹⁹
West syndrome	1 st year of life, typically around 6 months	Infantile spasms at onset with EEG hypsarrhythmia. Structural (tuberous sclerosis) and metabolic causes as well as genetic causes. Corticosteroids, vigabatrin and the ketogenic diet can be useful. Can evolve to Lennox-Gastaut syndrome.	Genes include <i>CDKL5</i> , <i>ARX</i> , <i>SPTAN1</i> and <i>STXBP1</i>
Epileptic encephalopathy with continuous spike-and-wave during sleep	Childhood onset, typically 4–5 years.	Progressive cognitive decline is prominent and is associated with characteristic EEG abnormality of continuous slow spike and wave in slow sleep. Seizures can remit but cognitive impairment can persist. A spectrum including Landau-Kleffner syndrome (milder phenotype with prominent aphasia)	<i>GRIN2A</i>
“Metabolic” DEEs		Rare but potentially treatable genetic metabolic problems which can present as a DEE include: <i>guanidinoacetate methyltransferase (GAMT) deficiency</i> – DEE phenotype, low serum creatinine can be a clue, check plasma and urine creatine, creatinine and guanidinoacetate. MR spectroscopy can be diagnostic. Oral creatine supplementation and dietary manipulation can cause dramatic improvements. ²⁰ <i>Pyridoxine dependent epilepsy (PDE)</i> is typically neonatal onset with drug resistant epilepsy and a DEE phenotype that responds to high doses of pyridoxine. Elevated plasma and urinary levels of alpha-amino adipic semialdehyde. ²¹	<i>GAMT</i> (<i>GAMT</i> deficiency) – recessive <i>ALDH7A1</i> (<i>PDE</i>) – recessive

Table 1 Important developmental and epileptic encephalopathies (DEEs).

Specific Genetic Epilepsy Phenotypes

Some epilepsies have well described genetic causes. For example, familial epilepsy syndromes or epilepsies due to mitochondrial disease (table 2)— request genetic testing in these cases.

Gene/Syndrome	Clinical presentation/clues	Genetics
Genetic epilepsy with febrile seizures plus (GEFS+)	A wide spectrum of epilepsies within the family consisting predominately of febrile seizures but also febrile seizures plus**, generalised (absence, myoclonic, atonic) and focal seizures. ⁷ A GEFS+ family has at least two individuals with GEFS+ phenotypes, including at least one with febrile seizures or febrile seizures plus (figure 1). GEFS+ families may have individuals with developmental or epileptic encephalopathies, particularly Dravet syndrome or Myoclonic-astatic epilepsy.	<i>SCN1A</i> (19%), <i>GABRG2</i> (9%), <i>SCN1B</i> (8%)
Glucose transporter 1 deficiency syndrome (GLUT1)	Variants in <i>SLC2A1</i> which encodes a brain glucose transporter can produce a spectrum of phenotypes including epileptic encephalopathies and milder epilepsies with or without intellectual disability. ²² Can also cause early onset absence epilepsy (onset <4 years) and/or paroxysmal exercise induced dyskinesia (limb movements including dystonia and chorea after exercise). ^{9 23} Responds well to the ketogenic diet. ²³	<i>SLC2A1</i>
Autosomal dominant sleep-related hypermotor epilepsy (ADSHE)*	Seizures from sleep usually starting in childhood and persisting into adulthood. Brief tonic or hypermotor seizures occurring in clusters. Awake seizures are rare. Mostly drug responsive, particularly to carbamazepine. ²⁴ Sometimes more severe with drug resistance and intellectual disability/psychiatric comorbidities, <i>KCNT1</i> variants associated with a more severe phenotype. ^{25 26}	<i>CHRNA4</i> , <i>CHRN2</i> , <i>CHRNA2</i> (nicotinic AChR subunit genes) and <i>DEPDC5 KCNT1</i> .
Autosomal dominant epilepsy with auditory features (ADEF) [§]	Seizures with auditory features typically starting in adolescence. Auditory auras, commonly sounds such as ringing or buzzing, sometimes receptive aphasia and auditory hallucinations. Focal and focal to bilateral convulsive seizures. Seizures can be sometimes triggered by sounds. Relatively drug responsive. ^{24 27}	<i>LG11</i> (30–50% of familial cases, 2% of sporadic cases). Also <i>DEPDC5</i> , <i>RELN</i> . ^{28 29}
Familial focal epilepsy with variable foci (FFEVF)	Focal epilepsy in multiple family members with different seizure foci in different family individuals (seizure focus remaining constant within the individual). E.g. temporal lobe epilepsy in the proband, frontal lobe epilepsy in father, occipital lobe epilepsy in grandfather. Variety in epilepsy onset and severity but mostly drug responsive, sometime psychiatric comorbidity. Can occur in families with fewer affected individuals. <i>DEPDC5</i> is part of the mammalian target of rapamycin pathway raising possible treatment options. ^{24 30}	<i>DEPDC5</i> (around 80%).
Ring chromosome 20 syndrome	Rare. Focal onset, drug resistant, seizures with frontal lobe semiology starting dramatically in childhood, typically around the age of 7. Hyperkinetic seizures during sleep as well as focal seizures with altered awareness and non-convulsive status epilepticus. Onset of seizures can be preceded by marked nocturnal hallucinations and behavioural/developmental disturbance after the onset of seizures is common. ³¹	Ring formation on chromosome 20 – check karyotype. (figure 2)
Mitochondrial disease	Clues include deafness, diabetes and short stature as well as occipital onset seizures and non-convulsive status epilepticus. ³² <i>Myoclonic epilepsy with ragged red fibres (MERRF)</i> can present as a progressive myoclonic epilepsy with cognitive change, ataxia, short stature, and multiple lipomas. ³³ <i>Mitochondrial encephalopathy with lactic acidosis and Stroke-like episodes (MELAS)</i> can present in adulthood. Seizures are a key features of the stroke-like episodes and headache and vomiting can also features. ^{34 35} <i>POLG-related epilepsies</i> can be	<i>POLG</i> and mitochondrial genes m.8344A>G (90% of MERRF) MELAS: m.3243A>G; m.3271T>C

	severe (Alpers-Huttenlocher Syndrome) and present with convulsive status epilepticus and epilepsia partialis continua in childhood and adolescence as well as cognitive changes and hepatopathy. Avoid sodium valproate in POLG disease. ³²	
--	--	--

Table 2 Clinical features of important genetic epilepsies and associated genetic conditions in the adult clinic. *Previously known as autosomal dominant nocturnal frontal lobe epilepsy.

**Febrile seizures plus are febrile seizures occurring outside the normal age range for febrile seizures (6 months to 6 years) or afebrile seizures occurring concurrently with febrile seizures. AChR = Acetylcholine receptor. §Previously called autosomal dominant partial/lateral temporal epilepsy with auditory features.

Progressive Myoclonic Epilepsies

The progressive myoclonic epilepsies (PME) are a rare, heterogeneous group of disorders characterised by predominantly progressive myoclonic seizures and progressive cognitive decline and ataxia (table 3).³⁶ Of note is that cognition is largely preserved in Unverricht-Lundborg disease. PMEs predominantly present in childhood or early adolescence and are mostly autosomal recessive.³⁷ Consider PME in a case of juvenile myoclonic epilepsy with progressive (particularly action) myoclonus, additional features such as ataxia or cognitive decline and a family history. It is now possible to get a genetic diagnosis for at least 70% of PMEs.^{37 38}

Syndrome	Clinical Features / Pointers	Genetics
Unverricht-Lundborg disease (ULD)	Most common and mildest PME. Progressive disabling action myoclonus. <i>Cascade</i> seizures with increasingly intense myoclonus. Occasional generalised tonic-clonic seizures. Photosensitivity common. ^{36 39} Preserved cognition until relatively late distinguishes from other PMEs. Geographical variation in prevalence (Baltic myoclonus). Avoid sodium-channel blocking drugs.	<i>CSTB</i> (dodecamer nucleotide repeats)
Neuronal ceroid lipofuscinosis (NCL)	Group of neurodegenerative lysosomal storage disorders. Common cause of childhood dementia. Prominent cognitive decline and visual failure, also cerebellar atrophy myoclonus and other seizures. Genetically heterogeneous, currently at least 14 genes, age at onset useful to classify. Other diagnostic tests e.g. skin biopsy can be useful. ^{36 40}	Loci: CLN1-14 Genes: <i>PPT1, TPP1, CLN3, DNAJC5, CLN5, CLN6, MFSD8, CLN8, CTSD, ATP13A2, CTSF, KCTD7</i>
Lafora disease (LD)	Adolescent onset in otherwise normal individuals. Headaches, myoclonus, occipital seizures, visual hallucinations. Biopsy can reveal Lafora bodies (polyglucosan inclusions). Progressive dementia and death usually 10 years after onset. ^{36 41 42}	<i>EPM2A, NHLRC1, PRDM8</i>
Others	<i>Myoclonic Epilepsy with Ragged Red Fibres (MERRF)</i> – see table 2. <i>Sialidosis</i> is a lysosomal storage disorder with ‘cherry red spots’ seen on fundoscopy as well as visual decline, ataxia and dysmorphia (sialidosis type 2). <i>Spinal muscular atrophy associated with progressive myoclonus epilepsy (SMA-PME)</i> is caused by acid ceramidase deficiency and has typically distal lower motor neurone weakness.	MERRF (mitochondrial) Sialidosis: <i>NEU1</i> , SMA-PME: <i>ASAH1</i>

Table 3 The progressive myoclonic epilepsies (PME).

Malformations of cortical development

Malformations of cortical development (MCD) are neurodevelopmental disorders caused by abnormal formation of the cerebral cortex. They are diverse in their aetiology and presentation but represent a common cause of intractable epilepsy.⁴³ In the adult epilepsy clinic MCDs are typically discovered with an abnormal MRI of the brain. Table 4 lists some of the most common MCDs.

Many MCDs have genetic causes and recommended genetic investigations include a chromosomal microarray and an MCD gene panel.⁴³ However, some MCDs are due to mosaic mutations (e.g. focal cortical dysplasia and hemimegalencephaly). Causative mosaic mutations may only be present in the brain and either absent or rare in other body tissues. Mosaic mutations can therefore be missed by standard tests on blood-derived DNA. Detection may require testing of alternative tissue samples (saliva, skin or brain material) and/or targeted testing (ultra-deep resequencing).

Other Structural Brain Abnormalities

Tuberous sclerosis complex is characterised by multiple benign tumours in the skin, brain and other organ systems with a variety of clinical features and presentations. Cutaneous manifestations (hypopigmented macules, angiofibromas, shagreen patches and forehead fibrous plaques) and neuropsychiatric problems occur in >90% of patients.^{44 45} Epilepsy occurs in around 80% of cases, tends to be early onset and can be severe.⁴⁵ *De-novo* (80%) and familial (autosomal dominant) mutations in *TSC1* and *TSC2* are found in more than 90% of tuberous sclerosis cases and cause an overactivation of the mTOR pathway.^{45 46} As well as anti-seizure medications, including cannabidiol and vigabatrin, treatment options include mTOR inhibitors such as everolimus, the ketogenic diet and surgery.⁴⁵

Cerebral cavernous malformations or cavernomas are low flow vascular malformations that can cause epilepsy as well as being relatively common incidental MRI findings.⁴⁷ Around 20% of patients have a familial, autosomal form of the disease and tend to have multiple cavernous malformations and pathogenic variants in one of three main genes: *CCM1* (*KRIT1*), *CCM2* and *CCM3* (*PDC10*).⁴⁸ Treatment of epilepsy associated with cavernous malformations normally involves anti-seizure medications although surgery can be an option.⁴⁸

Other genetic structural brain abnormalities that may cause epilepsy include leukoencephalopathies and neurofibromatosis.^{49 50}

Phenotype	Description	Genetics
Periventricular nodular heterotopia (PVNH)	Grey matter along the ventricular walls unilaterally or bilaterally. Can occur as part of another disorder. ⁴³ Can be caused by <i>FLNA</i> mutations (X-linked) which increase risk of systemic complications including heart, lung and GI disease. <i>FLNA</i> disease mostly affects females as usually lethal in males. ⁵¹	Numerous <i>copy number variants</i> and single gene mutations (including <i>FLNA</i>)
Polymicrogyria	Overfolding and abnormal cortical lamination. MRI: apparent cortical thickening with irregular cortical surface and ‘stippled’ grey-white junction. ⁵² Genetic and congenital causes. Congenital CMV infection accounts for around 30% of cases (suspect if additional microcephaly, congenital hearing loss, intracranial calcification). Can be associated with peroxisomal disorders (additional leukoencephalopathy) check plasma very long chain fatty acids. ⁴³	Copy number variants including 22q11.2 and 1p36 deletions and many single gene mutations including <i>GRIN1</i> , <i>WDR62</i> , <i>PIK3CA</i> and <i>PIK3R2</i>
Lissencephaly spectrum	“smooth brain”, absent or reduced gyri. Spectrum encompasses agyria, pachygyria and subcortical band heterotopia . ^{43 53} Mostly genetic causes, MRI findings/patterns can strongly predict genotype.	Include <i>LIS1</i> , <i>DCX</i> , <i>TUBG1</i> , <i>TUBA1A</i> , <i>ARX</i> ⁴³
Subcortical band heterotopia	Part of the lissencephaly spectrum. A band of grey matter separated from the cortex and lateral ventricles by zones of grey matter. ⁴³	<i>LIS1</i> (<i>PAFAH1B1</i>), <i>DCX</i>
Subcortical heterotopia (SUBH)	Heterotopic grey matter within the white matter between cortex and lateral ventricles. Less common to find genetic cause. ^{43 54}	Mostly recessive, include <i>GPSM2</i> , <i>EML1</i> , <i>TUBB</i> , <i>KATNB1</i> or <i>CENPJ</i> ^{43 54}
Tubulinopathies	Microtubules are important for neurodevelopment and mutations in tubulin genes can cause a range of MCDs including pachygyria, polymicrogyria and microlissencephaly. ⁵⁵ Additional features include dysmorphic basal ganglia, “hooked” frontal horns in the ventricles, agenesis of the corpus callosum and cerebellar and brainstem hypoplasia. Each tubulin gene is associated with a predominant phenotype. ^{43 55}	Include <i>TUBA1A</i> , <i>TUBB2A</i> , <i>TUBB2B</i> , <i>TUBB3</i> , <i>TUBB4A</i> , <i>TUBB</i> and <i>TUBG1</i>
Focal cortical dysplasia (FCD)	Focal irregularities of cortical morphology and thickness. Indistinct grey-white boundary. Can be subtle and occur as part of tuberous sclerosis. Overlap with Familial focal epilepsy with variable foci (FFEVF) (table 2)—consider if familial epilepsy.	mTOR pathway genes including <i>TSC1</i> , <i>TSC2</i> , <i>MTOR</i> ; GATOR1 complex genes including <i>DEPDC5</i> , <i>NPRL2</i> , <i>NPRL3</i> .

Table 4 – Some Malformations of cortical development (MCD) that can cause epilepsy.

‘Common’ Epilepsies

Most people with epilepsy in clinic will have generalised or non-lesional focal epilepsy [footnote: No obvious acquired cause (e.g. stroke, cerebral infection, traumatic brain injury) for the epilepsy and a normal MRI brain or a MRI brain without a lesion to explain the epilepsy], without an underlying cause, family history or suggestion of a known genetic phenotype. Genetics makes a significant contribution to the aetiology of these *common, idiopathic* epilepsies with the risk of developing epilepsy increased two to four times in first-degree relatives and increased concordance in monozygotic twins.^{56 57}

It is unlikely that these epilepsies are caused by a single genetic problem. One study found heterozygous intestinal-cell kinase variants in 7% of individuals with Juvenile Myoclonic Epilepsy, but this finding could not be replicated in a large independent cohort.^{58 59}

We now know that the combined effect of common genetic variants, rare genetic variants and copy number variants contribute towards the genetic cause of common epilepsies.^{22 60-62} Other genetic mechanisms that are likely to play a role include modifier genes, nucleotide repeats, and epigenetic factors.^{5 22 63}

At present we would not *routinely* recommend genetic tests for common, idiopathic generalised or *drug-responsive* focal epilepsies without additional features (see box 1). This could change in the future, for example polygenic risk scores may provide information on the prognosis and treatment options available for idiopathic epilepsies.⁵

Treatment and prognosis

Obtaining a genetic diagnosis can inform treatment options.⁶⁴ For example sodium channel blocking drugs should be avoided in Dravet syndrome caused by *SCN1A* loss of function mutations, the ketogenic diet may improve outcomes for people with *SLC2A1* mutations and sodium valproate can cause severe hepatotoxicity in *POLG* deficiency.⁶⁴ Genetic treatments, for example anti-sense oligonucleotide therapies, have been used experimentally for epilepsy and hold significant promise for the future.⁶⁵

Human Leucocyte Antigen (HLA) genotype can influence the risk of severe adverse drug reactions and HLA genotyping can be considered before starting carbamazepine treatment (HLA-B*1502 for certain Asian ethnicities and HLA-A*3101 for Japanese, Korean and European ethnicity).^{66 67} There are no other clinical pharmacogenetic tests at present despite the likelihood that genetics influences treatment response.

Recent studies have shown higher schizophrenia polygenic risk scores in people with epilepsy with post-ictal psychosis and levetiracetam induced psychosis when compared to those without.^{68 69} This raises the possibility that genetic testing may help predict prognosis and outcomes in future, although none are clinically available at present.⁷⁰

Genetic Testing

When should I request a genetic test in epilepsy clinic?

The threshold for requesting an epilepsy genetic test is continuing to fall. It may be in the near future that almost all people with epilepsy will have a genetic test. However currently we would recommend prioritising genetic testing for cases where results are most likely to have the highest yield and influence clinical management (box 1).⁷¹

Developmental and Epileptic encephalopathies (DEEs) (table 1)
Epilepsy with intellectual disability and/or other neurodevelopmental disorder
Individual and or family phenotype suggestive of a known genetic cause (table 2)
Features suggestive of mitochondrial disease (table 2)
Progressive myoclonic epilepsies (table 3)
Malformations of cortical development (table 4) or other genetic structural abnormality
Early onset (<3 years)
Drug resistant epilepsy of unknown aetiology

Box 1 Clinical scenarios where genetic testing is indicated

Advantages and disadvantages to genetic testing

Obtaining a genetic diagnosis can have clear clinical benefits. These include: selecting specific treatment options and avoiding contraindicated treatments, informing prognosis, enabling pre-conception planning and genetic counselling, preventing unnecessary investigation, identifying groups of patients for clinical trials, providing an explanation, and *ending the diagnostic odyssey*.^{72 73}

There are also disadvantages. It is important to consider the broader implications of requesting a genetic test, discussing these with the patient and/or family as part of the consent process. For example, test results may not give an answer, have implications for other family members, give uncertain results (variants of uncertain significance), and provide additional unexpected findings (particularly with whole exome and genome sequencing). Unexpected findings can include risk factors for health problems (e.g. heart disease or cancer) and uncover sensitive issues such as non-paternity in families.⁷⁴

What genetic test should I do?

Chromosomal microarrays

Molecular methods have replaced routine karyotyping, where chromosomes are stained and visualised by microscope, to detect structural genomic variants. These chromosomal microarrays (or simply 'arrays') complement gene panels and exomes because they are sensitive to medium- and large-scale deletions and duplications [also known as 'copy number variants' (CNVs)] which are often missed by sequencing-based tests.

The main array methods used are comparative genomic hybridisation (CGH) or Single Nucleotide Polymorphism (SNP) based platforms. SNP arrays have the advantage of being sensitive to uniparental disomy [footnote: inheriting two copies of the same chromosome from one parent] which can be relevant to conditions such as Angelman syndrome and Prader-Willi syndrome.

Chromosomal microarrays are now the standard tests used to detect CNVs from around a few hundred kilobases in size (figure 2). CNVs are part of normal genetic variation (perhaps accounting for 5–10% of the human genome).⁷⁵ CNVs can cause disease though and several specific CNVs are associated with epilepsy, these include 1q21.1, 15q13.3, 15q11.2, 16p11.2 and 16p13.11.^{76 77}

Chromosomal microarrays are insensitive to balanced rearrangements such as inversions, translocations and ring chromosomes. For example, karyotyping should be requested if ring chromosome 20 [r(20)] syndrome is suspected (see table 2 and figure 3). R(20) is a rare condition where the ends of chromosome 20 fuse to form a ring structure replacing the normal chromosome 20 (figure 3).³¹ R(20) is frequently mosaic [footnote: Occurring in only a proportion of cells] and so a repeat karyotype test or visualisation of more cells should be considered, after discussion with the genetics lab, if there is a strong clinical suspicion.³¹

A chromosomal microarray should be considered in an adult with unexplained epilepsy particularly if there is comorbid intellectual disability, dysmorphism, autism or schizophrenia or a family history of these conditions. The overall diagnostic yield of arrays in selected populations can be around 10%.⁷³

Epilepsy Gene Panels

Epilepsy gene panels, together with whole exome and genome sequencing, are perhaps the most common and useful genetic tests in the adult epilepsy clinic at present. Multiple (hundreds) of genes can be tested in one request.

The overall yield of an epilepsy gene panel may be around 20% but will vary with certain phenotypes and the number of genes included on the panel.⁷³ The genes that are screened on gene panels will change with time, vary regionally and nationally, and tend to be grouped into broad phenotypes e.g. developmental and epileptic encephalopathies, progressive myoclonic epilepsies or malformations of cortical development and so it is worth checking with your genetics lab. For example, almost all genes mentioned in this paper can be found in the Genomics England *R87 cerebral malformations* or *R59 Early onset or syndromic epilepsy* panels.⁷⁸

Whole Exome and Whole Genome Sequencing

These are now regularly being used clinically, often with input from a local genetics service. Genome sequencing, particularly with longer read technology, can be used to detect copy number variants and may replace the current separate microarray and gene panel approach soon as a “one-stop shop” for genetic testing.^{79 80 81}

Many testing centres will use *virtual gene panels* where sets of genes are selected for analysis from whole exome or genome sequencing results. This has the advantage of reducing the variant interpretation workload associated with whole exome and genome sequencing, being able to reanalyse different genes in future and maintaining diagnostic yield.⁸²

Additional genetic analysis

Chromosomal microarrays and current sequencing-based tests are limited in their ability to detect certain types of genetic variation. Additional targeted testing needs to be considered if these are suspected. Examples include mosaic genetic changes (see above), mitochondrial mutations, repeat expansion disorders and imprinting disorders (and promotor and intronic variants for exome sequencing).

Consider mitochondrial genetic testing if there are features of mitochondrial disease (table 1). Mitochondrial tests range from targeted testing for point mutations (e.g. MELAS, NERFF, NARP), to assays for large deletions and duplications, to whole mitochondrial genome sequencing. Variable tissue distribution may mean that variants are undetectable in blood requiring testing of muscle or urine sediment. It should be remembered that mitochondrial disorders are often caused by defects in genes encoded in the nuclear genome e.g. *POLG*.

Some epilepsies and disorders associated with epilepsy are caused by nucleotide repeat disorders. These include Unverricht-Lundborg disease (table 3) and benign adult familial myoclonic epilepsy, a rare autosomal dominant condition with cortical tremor and myoclonus and infrequent generalised tonic clonic seizures.^{63 83} Other repeat expansion disorders associated with epilepsy include Fragile X syndrome (also associated with intellectual disability and autism) and Huntington disease. Targeted PCR or Southern blotting-based techniques are required to detect these.

Angelman syndrome and Prader-Willi syndrome are examples of disorders that can be caused by abnormal methylation patterns on chromosome 15 (in addition to large chromosomal deletions and uniparental disomy as discussed above). Targeted methylation-sensitive PCR can detect methylation abnormalities as well as uniparental disomy.

How do I interpret genetic test results?

As gene panel, exome sequencing and genome sequencing are becoming more widespread we are getting more confident in interpreting their results. Please also see some excellent articles from this journal.^{81 84}

Clinical genomic laboratories employ international guidelines such as those from the American College of Medical Genetics for variant interpretation.⁸⁵ These attempt to bring objectivity and consistency to the challenge of variant interpretation. Currently American College of Medical Genetics guidelines use features such as evolutionary conservation, phenotype match, computer predictions, population genetic data and family segregation to classify variants as either: 5) *pathogenic*, 4) *likely pathogenic*, 3) *uncertain significance*, 2) *likely benign* or 1) *benign*.^{81 85}

If the test reports a variant as pathogenic, with an established phenotype matching your patient's, then you probably have the answer. Like any other clinical test there is the chance of *false positive* and *false negative* results however and sometimes it can be difficult to interpret the clinical significance of some results. Factors that you should consider when interpreting your results are shown in box 2. Remember that it is possible for a patient to have more than one genetic diagnosis. It is important to consider whether *enough* of a genetic explanation has been found (e.g., a 1q21.1 deletion detected by chromosomal microarray is a risk factor for epilepsy but would not be sufficient to explain a severe DEE).

Is there a zygosity mismatch between previously published results and your result? i.e. previously published genotypes are homozygous but the results are heterozygous.
Do the phenotypes match (although phenotypic heterogeneity is common in epilepsy)?
Is this a previously published or described variant?
The quality of published evidence of the pathogenicity of the variant.
Is this a variant that is present in the general population? (in this case it is less likely to explain a rare epilepsy)
Does the variant segregate in the family? i.e. affected family members carry the variant and unaffected family members do not carry the variant.

Box 2 Factors to consider when deciding on the clinical significance of genetic results

In South Wales we have established a quarterly epilepsy genetics multidisciplinary team meeting, attended by clinical geneticists, genetic laboratory scientists, paediatric neurologists, specialist nurses as well as neurology trainees and adult neurologists. We would advise discussing patients and test results within the genetic multidisciplinary team to aid clinical decision making and the interpretation of genetic test results. Without access to a formal genetics meeting, we would advise discussing genetic test results and requests with clinical and laboratory genetics staff and colleagues if there is any doubt.

In cases without a definite genetic diagnosis, it is worth considering research participation to look for new genetic causes, periodic reanalysis of genomic data or retesting with newer testing techniques.⁸⁶

Further Reading

www.epilepsydiagnosis.org. *Useful website with definitions of epilepsy syndromes including genes.*

www.epilepsygenetics.net Beyond the ion channel the International League Against Epilepsy (ILAE) genetics commission Blog. *Written by Dr Ingo Helbig and contains a host of very readable blogs about epilepsy genetics and related topics. Subscribe for an email update!*

Krey et al. Current practice in diagnostic genetic testing of the epilepsies. *Epileptic Disord* 2022;24:1–22. *Useful detail on genetic testing in the epilepsies from the ILAE Genetics Commission recommendations for*⁸⁶

Morris HR, Houlden H, Polke J. Whole-genome sequencing. *Practical Neurology* 2021;21:322-327.

Keogh MJ, Daud D, Chinnery PF. Exome sequencing: how to understand it. *Practical Neurology* 2013;13:399-407.

Acknowledgements

We would like to thank Dr Jana Jezkova, Clinical Scientist and Postdoctoral Fellow at Cardiff University for her help with the figures.

Conflict of Interests

The authors confirm that they have no relevant conflict of interests to declare

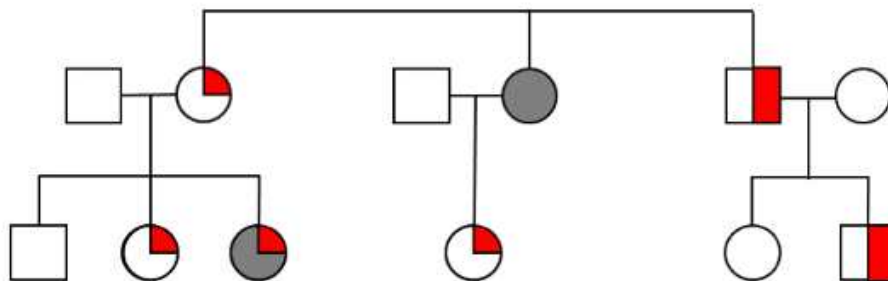


Figure 1 An example of a family with **Genetic Epilepsy with Febrile Seizures Plus (GEFS+)** – see table 2. Squares are male, circles are female. Red quadrants represent febrile seizures. Red halves represent febrile seizures plus (febrile seizures occurring outside the ages of 6 months and 6 years or afebrile seizures occurring concurrently with febrile seizures). Complete grey shading represents epilepsy.

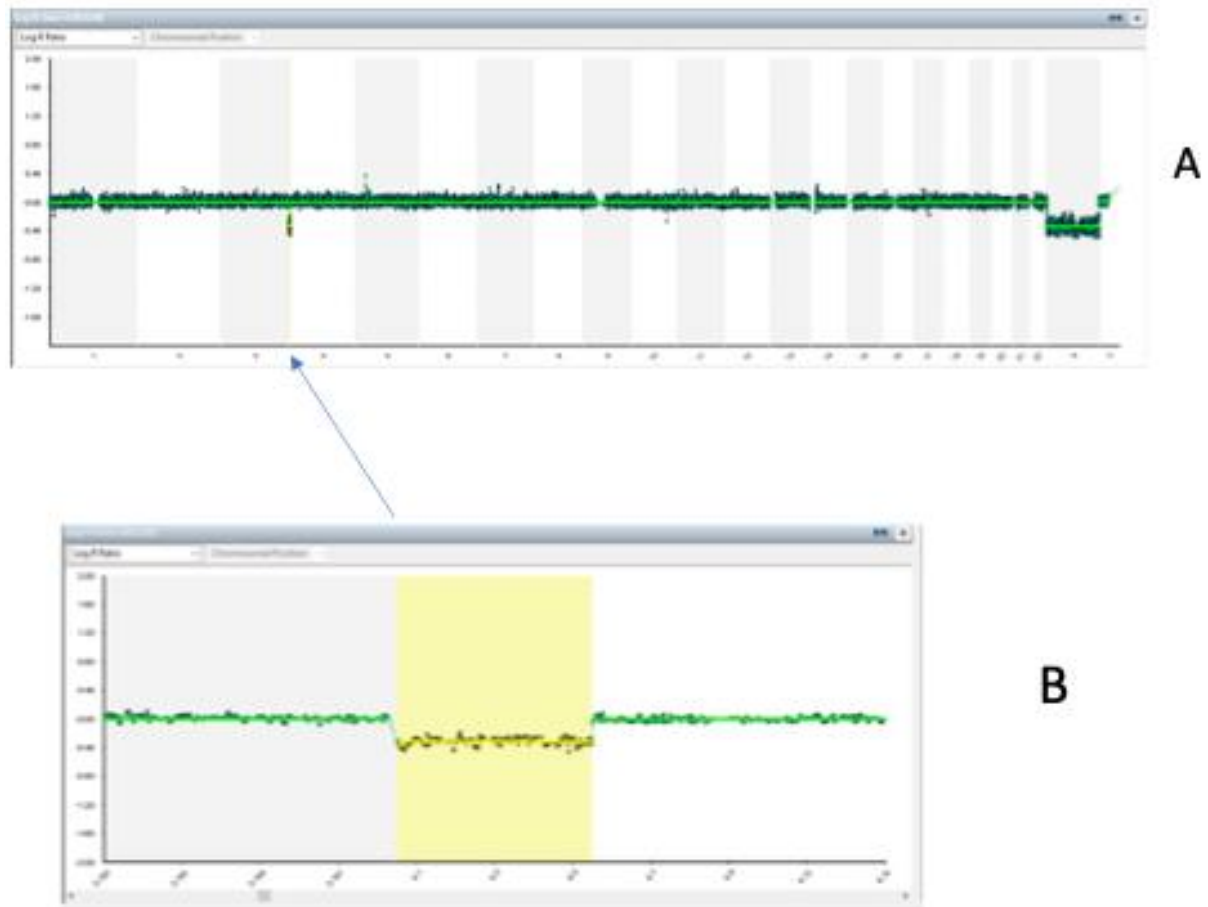


Figure 2 Output from a single nucleotide polymorphism (SNP) microarray a common way to look for copy number variants (CNVs). In this case there was a CNV, a deletion, on the short arm of chromosome 4. The lower box (B) is a scaled plot around the deletion and the yellow box highlights the deletion. There is a lower log R ratio in the yellow area representative of less sample DNA (a deletion). DNA duplications have areas of higher log R. The log R is a measure of signal intensity and correlates with the amount of DNA present.

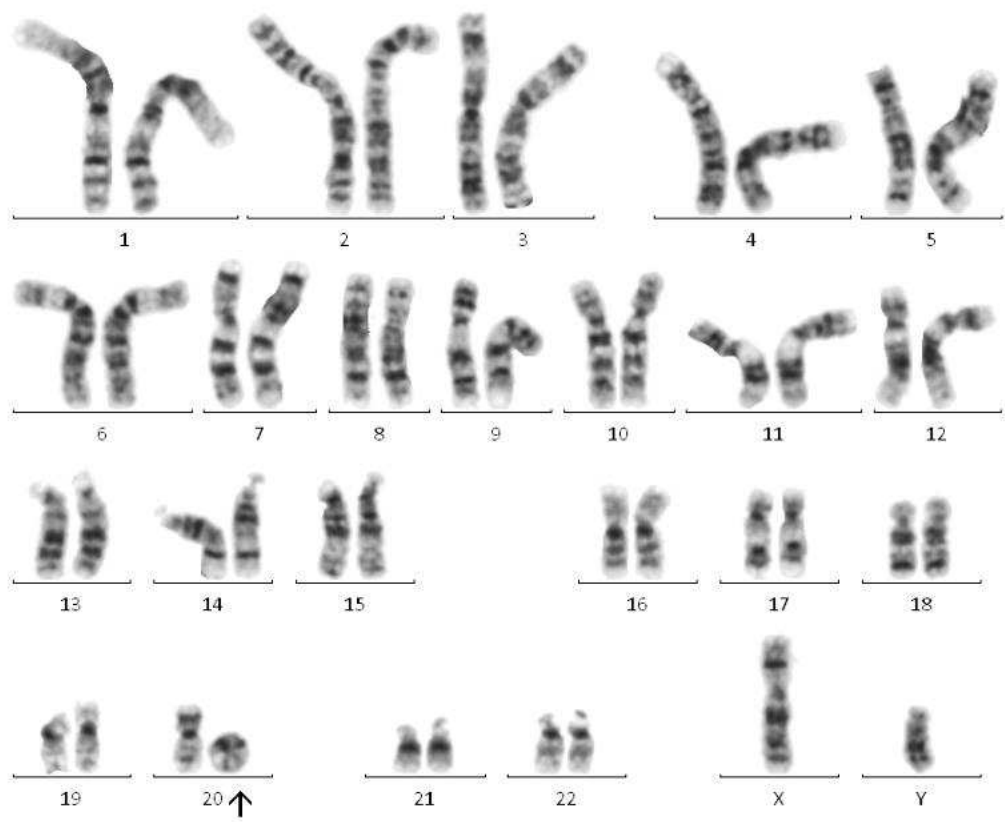


Figure 3 Karyotype showing a ring chromosome 20 (arrow). Ring chromosome 20 syndrome is a rare cause of epilepsy (table 2)

References

1. Hippocrates. The Sacred Disease The Persus Library 400 bd [Available from: <http://classics.mit.edu/Hippocrates/sacred.html> accessed 29/06/2022 2022.
2. Steinlein OK, Mulley JC, Propping P, et al. A missense mutation in the neuronal nicotinic acetylcholine receptor $\alpha 4$ subunit is associated with autosomal dominant nocturnal frontal lobe epilepsy. *Nature Genetics* 1995;11(2):201-03. doi: 10.1038/ng1095-201
3. Lewis-Smith D, Ellis CA, Helbig I, et al. Early-onset genetic epilepsies reaching adult clinics. *Brain* 2020;143(3):e19. doi: 10.1093/brain/awaa029 [published Online First: 2020/03/24]
4. Zacher P, Mayer T, Brandhoff F, et al. The genetic landscape of intellectual disability and epilepsy in adults and the elderly: a systematic genetic work-up of 150 individuals. *Genet Med* 2021;23(8):1492-97. doi: 10.1038/s41436-021-01153-6 [published Online First: 2021/04/28]
5. Knowles JK, Helbig I, Metcalf CS, et al. Precision medicine for genetic epilepsy on the horizon: recent advances, present challenges and suggestions for continued progress. *Epilepsia*;n/a(n/a) doi: <https://doi.org/10.1111/epi.17332>
6. Thomas RH, Berkovic SF. The hidden genetics of epilepsy—a clinically important new paradigm. *Nature Reviews Neurology* 2014;10(5):283-92. doi: 10.1038/nrneurol.2014.62
7. Kenneth AM, Ingrid ES, Samuel FB. Genetic literacy series: genetic epilepsy with febrile seizures <i>plus</i>. *Epileptic Disorders* 2018;20(4):232-38. doi: 10.1684/epd.2018.0985
8. Wirrell EC, Hood V, Knupp KG, et al. International consensus on diagnosis and management of Dravet syndrome. *Epilepsia* 2022;63(7):1761-77. doi: <https://doi.org/10.1111/epi.17274>
9. Arsov T, Mullen SA, Damiano JA, et al. Early onset absence epilepsy: 1 in 10 cases is caused by GLUT1 deficiency. *Epilepsia* 2012;53(12):e204-e07. doi: <https://doi.org/10.1111/epi.12007>
10. Kurahashi H, Hirose S. Autosomal Dominant Nocturnal Frontal Lobe Epilepsy. In: Adam MP, Mirzaa GM, Pagon RA, et al., eds. GeneReviews®. Seattle (WA): University of Washington, Seattle. 1993.
11. Scheffer IE, Berkovic S, Capovilla G, et al. ILAE classification of the epilepsies: Position paper of the ILAE Commission for Classification and Terminology. *Epilepsia* 2017;58(4):512-21. doi: <https://doi.org/10.1111/epi.13709>
12. McTague A, Howell KB, Cross JH, et al. The genetic landscape of the epileptic encephalopathies of infancy and childhood. *The Lancet Neurology* 2016;15(3):304-16. doi: [https://doi.org/10.1016/S1474-4422\(15\)00250-1](https://doi.org/10.1016/S1474-4422(15)00250-1)
13. OMIM. OMIM entry for DEE [Available from: <https://www.omim.org/entry/308350> accessed 11 Aug 2022.
14. Selvarajah A, Gorodetsky C, Marques P, et al. Progressive Worsening of Gait and Motor Abnormalities in Older Adults With Dravet Syndrome. *Neurology* 2022;98(22):e2204-e10. doi: 10.1212/wnl.0000000000200341
15. Dravet C. The core Dravet syndrome phenotype. *Epilepsia* 2011;52(s2):3-9. doi: <https://doi.org/10.1111/j.1528-1167.2011.02994.x>

16. Darra F, Battaglia D, Dravet C, et al. Dravet syndrome: Early electroclinical findings and long-term outcome in adolescents and adults. *Epilepsia* 2019;60(S3):S49-S58. doi: <https://doi.org/10.1111/epi.16297>
17. Claes L, Del-Favero J, Ceulemans B, et al. De novo mutations in the sodium-channel gene SCN1A cause severe myoclonic epilepsy of infancy. *Am J Hum Genet* 2001;68(6):1327-32. doi: 10.1086/320609 [published Online First: 2001/05/15]
18. Steel D, Symonds JD, Zuberi SM, et al. Dravet syndrome and its mimics: Beyond SCN1A. *Epilepsia* 2017;58(11):1807-16. doi: <https://doi.org/10.1111/epi.13889>
19. Burgess R, Wang S, McTague A, et al. The Genetic Landscape of Epilepsy of Infancy with Migrating Focal Seizures. *Annals of Neurology* 2019;86(6):821-31. doi: <https://doi.org/10.1002/ana.25619>
20. Stern WM, Winston JS, Murphy E, et al. Guanidinoacetate methyltransferase (GAMT) deficiency: a rare but treatable epilepsy. *Practical Neurology* 2017;17(3):207-11. doi: 10.1136/practneurol-2016-001475
21. Jr. GS. Pyridoxine-Dependent Epilepsy – ALDH7A1. In: Adam MP ED, Mirzaa GM, et al, ed. GeneReviews [Internet]. Seattle, 2021.
22. Perucca P, Bahlo M, Berkovic SF. The Genetics of Epilepsy. *Annual Review of Genomics and Human Genetics* 2020;21(1):205-30. doi: 10.1146/annurev-genom-120219-074937
23. Suls A, Dedeken P, Goffin K, et al. Paroxysmal exercise-induced dyskinesia and epilepsy is due to mutations in SLC2A1, encoding the glucose transporter GLUT1. *Brain* 2008;131(7):1831-44. doi: 10.1093/brain/awn113
24. Samuel G, Douglas EC, Samuel FB, et al. ILAE Genetic Literacy Series: familial focal epilepsy syndromes. *Epileptic Disorders* 2022;24(2):221-28. doi: 10.1684/epd.2021.1393
25. Heron SE, Smith KR, Bahlo M, et al. Missense mutations in the sodium-gated potassium channel gene KCNT1 cause severe autosomal dominant nocturnal frontal lobe epilepsy. *Nature Genetics* 2012;44(11):1188-90. doi: 10.1038/ng.2440
26. Derry CP, Heron SE, Phillips F, et al. Severe autosomal dominant nocturnal frontal lobe epilepsy associated with psychiatric disorders and intellectual disability. *Epilepsia* 2008;49(12):2125-29. doi: <https://doi.org/10.1111/j.1528-1167.2008.01652.x>
27. Ottman R, Winawer MR, Kalachikov S, et al. *LG11* mutations in autosomal dominant partial epilepsy with auditory features. *Neurology* 2004;62(7):1120-26. doi: 10.1212/01.Wnl.0000120098.39231.6e
28. Picard F, Makrythanasis P, Navarro V, et al. DEPDC5 mutations in families presenting as autosomal dominant nocturnal frontal lobe epilepsy. *Neurology* 2014;82(23):2101-6. doi: 10.1212/wnl.0000000000000488 [published Online First: 2014/05/13]
29. Dazzo E, Fanciulli M, Serioli E, et al. Heterozygous Reelin Mutations Cause Autosomal-Dominant Lateral Temporal Epilepsy. *The American Journal of Human Genetics* 2015;96(6):992-1000. doi: 10.1016/j.ajhg.2015.04.020
30. Dibbens LM, de Vries B, Donatello S, et al. Mutations in DEPDC5 cause familial focal epilepsy with variable foci. *Nature Genetics* 2013;45(5):546-51. doi: 10.1038/ng.2599
31. Peron A, Catusi I, Recalcati MP, et al. Ring Chromosome 20 Syndrome: Genetics, Clinical Characteristics, and Overlapping Phenotypes. *Frontiers in Neurology* 2020;11 doi: 10.3389/fneur.2020.613035
32. Lim A, Thomas RH. The mitochondrial epilepsies. *European Journal of Paediatric Neurology* 2020;24:47-52. doi: <https://doi.org/10.1016/j.ejpn.2019.12.021>

33. Costanza L, Massimo Z. Myoclonus epilepsy in mitochondrial disorders. *Epileptic Disorders* 2016;18(2):94-102. doi: 10.1684/epd.2016.0846
34. El-Hattab AW AM, Scaglia F. . MELAS. In: Adam MP MG, Pagon RA, et al, ed. GeneReviews® [Internet]: Seattle (WA): University of Washington, Seattle; 1993-2022. 2001.
35. Hawken J, Tobin P, Hu M, et al. Radiological clues to a mitochondrial problem. *Practical Neurology* 2022;22(3):239. doi: 10.1136/practneurol-2022-003356
36. Orsini A, Valetto A, Bertini V, et al. The best evidence for progressive myoclonic epilepsy: A pathway to precision therapy. *Seizure - European Journal of Epilepsy* 2019;71:247-57. doi: 10.1016/j.seizure.2019.08.012
37. Courage C, Oliver KL, Park EJ, et al. Progressive myoclonus epilepsies—Residual unsolved cases have marked genetic heterogeneity including dolichol-dependent protein glycosylation pathway genes. *The American Journal of Human Genetics* 2021;108(4):722-38. doi: 10.1016/j.ajhg.2021.03.013
38. Canafoglia L, Franceschetti S, Gambardella A, et al. Progressive Myoclonus Epilepsies: Diagnostic Yield With Next-Generation Sequencing in Previously Unsolved Cases. *Neurol Genet* 2021;7(6):e641-e41. doi: 10.1212/NXG.0000000000000641
39. Crespel A, Ferlazzo E, Franceschetti S, et al. Unverricht-Lundborg disease. *Epileptic Disord* 2016;18(S2):28-37. doi: 10.1684/epd.2016.0841 [published Online First: 2016/09/02]
40. Schulz A, Kohlschütter A, Mink J, et al. NCL diseases — clinical perspectives. *Biochimica et Biophysica Acta (BBA) - Molecular Basis of Disease* 2013;1832(11):1801-06. doi: <https://doi.org/10.1016/j.bbadis.2013.04.008>
41. Julie T, Erica T, Pasquale S, et al. Lafora disease. *Epileptic Disorders* 2016;18(2):38-62. doi: 10.1684/epd.2016.0842
42. Turnbull J, Girard J-M, Lohi H, et al. Early-onset Lafora body disease. *Brain* 2012;135(9):2684-98. doi: 10.1093/brain/aws205
43. Oegema R, Barakat TS, Wilke M, et al. International consensus recommendations on the diagnostic work-up for malformations of cortical development. *Nature Reviews Neurology* 2020;16(11):618-35. doi: 10.1038/s41582-020-0395-6
44. Webb DW, Clarke A, Fryer A, et al. The cutaneous features of tuberous sclerosis: a population study. *Br J Dermatol* 1996;135(1):1-5. [published Online First: 1996/07/01]
45. Curatolo P, Specchio N, Aronica E. Advances in the genetics and neuropathology of tuberous sclerosis complex: edging closer to targeted therapy. *The Lancet Neurology* 2022;21(9):843-56. doi: [https://doi.org/10.1016/S1474-4422\(22\)00213-7](https://doi.org/10.1016/S1474-4422(22)00213-7)
46. Au KS, Williams AT, Roach ES, et al. Genotype/phenotype correlation in 325 individuals referred for a diagnosis of tuberous sclerosis complex in the United States. *Genetics in Medicine* 2007;9(2):88-100. doi: 10.1097/GIM.0b013e31803068c7
47. Flemming KD, Lanzino G. Cerebral Cavernous Malformation: What a Practicing Clinician Should Know. *Mayo Clinic Proceedings* 2020;95(9):2005-20. doi: 10.1016/j.mayocp.2019.11.005
48. Zafar A, Quadri SA, Farooqui M, et al. Familial Cerebral Cavernous Malformations. *Stroke* 2019;50(5):1294-301. doi: doi:10.1161/STROKEAHA.118.022314
49. Lynch DS, Wade C, Paiva ARBd, et al. Practical approach to the diagnosis of adult-onset leukodystrophies: an updated guide in the genomic era. *Journal of Neurology, Neurosurgery & Psychiatry* 2019;90(5):543-54. doi: 10.1136/jnnp-2018-319481

50. Nix JS, Blakeley J, Rodriguez FJ. An update on the central nervous system manifestations of neurofibromatosis type 1. *Acta Neuropathologica* 2020;139(4):625-41. doi: 10.1007/s00401-019-02002-2
51. Chen MH WC. FLNA deficiency. In: Adam MP ED, Mirzaa GM, et al, ed. GeneReviews [Internet]. Seattle (WA): University of Washington, Seattle 2021.
52. Leventer RJ, Jansen A, Pilz DT, et al. Clinical and imaging heterogeneity of polymicrogyria: a study of 328 patients. *Brain* 2010;133(Pt 5):1415-27. doi: 10.1093/brain/awq078 [published Online First: 2010/04/21]
53. Di Donato N, Chiari S, Mirzaa GM, et al. Lissencephaly: Expanded imaging and clinical classification. *Am J Med Genet A* 2017;173(6):1473-88. doi: 10.1002/ajmg.a.38245 [published Online First: 2017/04/26]
54. Oegema R, Barkovich AJ, Mancini GMS, et al. Subcortical heterotopic gray matter brain malformations. *Classification study of 107 individuals* 2019;93(14):e1360-e73. doi: 10.1212/wnl.00000000000008200
55. Romaniello R, Arrigoni F, Fry AE, et al. Tubulin genes and malformations of cortical development. *European Journal of Medical Genetics* 2018;61(12):744-54. doi: <https://doi.org/10.1016/j.ejmg.2018.07.012>
56. Peljto AL, Barker-Cummings C, Vasoli VM, et al. Familial risk of epilepsy: a population-based study. *Brain* 2014;137(Pt 3):795-805. doi: 10.1093/brain/awt368 [published Online First: 2014/01/29]
57. Vadlamudi L, Milne RL, Lawrence K, et al. Genetics of epilepsy: The testimony of twins in the molecular era. *Neurology* 2014;83(12):1042-8. doi: 10.1212/wnl.0000000000000790 [published Online First: 2014/08/12]
58. Bailey JN, de Nijs L, Bai D, et al. Variant Intestinal-Cell Kinase in Juvenile Myoclonic Epilepsy. *New England Journal of Medicine* 2018;378(11):1018-28. doi: 10.1056/NEJMoa1700175
59. Lerche H BS, Lowenstein DH, EuroEPINOMICS-CoGIE Consortium, EpiPGX Consortium, Epi4K Consortium/Epilepsy Phenome/Genome Project. Intestinal-Cell Kinase and Juvenile Myoclonic Epilepsy. *New England Journal of Medicine* 2019;380(16):e24. doi: 10.1056/NEJMc1805100
60. International League Against Epilepsy Consortium on Complex E. Genome-wide mega-analysis identifies 16 loci and highlights diverse biological mechanisms in the common epilepsies. *Nat Commun* 2018;9(1):5269-69. doi: 10.1038/s41467-018-07524-z
61. Song M, Liu J, Yang Y, et al. Genome-Wide Meta-Analysis Identifies Two Novel Risk Loci for Epilepsy. *Frontiers in Neuroscience* 2021;15 doi: 10.3389/fnins.2021.722592
62. Niestroj L-M, Perez-Palma E, Howrigan DP, et al. Epilepsy subtype-specific copy number burden observed in a genome-wide study of 17 458 subjects. *Brain* 2020;143(7):2106-18. doi: 10.1093/brain/awaa171
63. Ishiura H, Doi K, Mitsui J, et al. Expansions of intronic TTCA and TTTTA repeats in benign adult familial myoclonic epilepsy. *Nature Genetics* 2018;50(4):581-90. doi: 10.1038/s41588-018-0067-2
64. Sisodiya SM. Precision medicine and therapies of the future. *Epilepsia* 2021;62(S2):S90-S105. doi: <https://doi.org/10.1111/epi.16539>
65. Kim J, Hu C, Moufawad El Achkar C, et al. Patient-Customized Oligonucleotide Therapy for a Rare Genetic Disease. *New England Journal of Medicine* 2019;381(17):1644-52. doi: 10.1056/NEJMoa1813279

66. Yip VL, Marson AG, Jorgensen AL, et al. HLA Genotype and Carbamazepine-Induced Cutaneous Adverse Drug Reactions: A Systematic Review. *Clinical Pharmacology & Therapeutics* 2012;92(6):757-65. doi: <https://doi.org/10.1038/clpt.2012.189>
67. Choi H, Mohit B. Cost-effectiveness of screening for HLA-B*1502 prior to initiation of carbamazepine in epilepsy patients of Asian ancestry in the United States. *Epilepsia* 2019;60(7):1472-81. doi: <https://doi.org/10.1111/epi.16053>
68. Braatz V, Martins Custodio H, Leu C, et al. Postictal Psychosis in Epilepsy: A Clinicogenetic Study. *Annals of Neurology* 2021;90(3):464-76. doi: <https://doi.org/10.1002/ana.26174>
69. Campbell C, McCormack M, Patel S, et al. A pharmacogenomic assessment of psychiatric adverse drug reactions to levetiracetam. *Epilepsia* 2022;63(6):1563-70. doi: <https://doi.org/10.1111/epi.17228>
70. Leu C, Balestrini S, Maher B, et al. Genome-wide Polygenic Burden of Rare Deleterious Variants in Sudden Unexpected Death in Epilepsy. *eBioMedicine* 2015;2(9):1063-70. doi: 10.1016/j.ebiom.2015.07.005
71. National Genomic Test Directory, Testing Criteria for Rare and Inherited Disease: National Health Service, 2022.
72. Brunklaus A, Pérez-Palma E, Ghanty I, et al. Development and Validation of a Prediction Model for Early Diagnosis of *SCN1A*-Related Epilepsies. *Neurology* 2022;10.1212/WNL.0000000000200028. doi: 10.1212/wnl.0000000000200028
73. Sheidley BR, Malinowski J, Bergner AL, et al. Genetic testing for the epilepsies: A systematic review. *Epilepsia* 2022;63(2):375-87. doi: 10.1111/epi.17141 [published Online First: 2021/12/12]
74. Physicians RCo. Consent and confidentiality in genomic medicine, 2019.
75. Zarrei M, MacDonald JR, Merico D, et al. A copy number variation map of the human genome. *Nature Reviews Genetics* 2015;16(3):172-83. doi: 10.1038/nrg3871
76. Mullen SA, Carvill GL, Bellows S, et al. Copy number variants are frequent in genetic generalized epilepsy with intellectual disability. *Neurology* 2013;81(17):1507-14. doi: 10.1212/WNL.0b013e3182a95829
77. Olson H, Shen Y, Avallone J, et al. Copy number variation plays an important role in clinical epilepsy. *Annals of Neurology* 2014;75(6):943-58. doi: <https://doi.org/10.1002/ana.24178>
78. Genomics England Gene PanelApp [Genomics England Gene Panel Browser]. Available from: <https://panelapp.genomicsengland.co.uk/panels/> accessed 12th August 2022.
79. Lin X, Yang Y, Melton PE, et al. Integrating Genetic Structural Variations and Whole-Genome Sequencing Into Clinical Neurology. *Neurology Genetics* 2022;8(4):e200005. doi: 10.1212/nxg.0000000000200005
80. Zou D, Wang L, Liao J, et al. Genome sequencing of 320 Chinese children with epilepsy: a clinical and molecular study. *Brain* 2021;144(12):3623-34. doi: 10.1093/brain/awab233
81. Morris HR, Houlden H, Polke J. Whole-genome sequencing. *Practical Neurology* 2021;21(4):322-27. doi: 10.1136/practneurol-2020-002561
82. Molina-Ramírez LP, Kyle C, Ellingford JM, et al. Personalised virtual gene panels reduce interpretation workload and maintain diagnostic rates of proband-only clinical exome sequencing for rare disorders. *Journal of Medical Genetics* 2022;59(4):393-98. doi: 10.1136/jmedgenet-2020-107303

83. Kobayashi K, Hitomi T, Matsumoto R, et al. Nationwide survey in Japan endorsed diagnostic criteria of benign adult familial myoclonus epilepsy. *Seizure - European Journal of Epilepsy* 2018;61:14-22. doi: 10.1016/j.seizure.2018.07.014
84. Keogh MJ, Daud D, Chinnery PF. Exome sequencing: how to understand it. *Practical Neurology* 2013;13(6):399-407. doi: 10.1136/practneurol-2012-000498
85. Richards S, Aziz N, Bale S, et al. Standards and guidelines for the interpretation of sequence variants: a joint consensus recommendation of the American College of Medical Genetics and Genomics and the Association for Molecular Pathology. *Genetics in Medicine* 2015;17(5):405-24. doi: 10.1038/gim.2015.30
86. Ilona K, Konrad P, Alina E, et al. Current practice in diagnostic genetic testing of the epilepsies.