

Case Report

Parosteal lipoma of the mandible: A case report and review of the literature

Julie Potter, Charlotte Richards, John Collin

Department of Oral and Maxillofacial, University Hospitals Bristol and Weston, Bristol Dental Hospital, Lower Maudlin Street, Bristol, UK

Abstract

Introduction: Lipomata are soft-tissue mesenchymal neoplasms that are benign in nature and often asymptomatic. Lipomata commonly occur in the body, however, only 1%–5% are identified within the oral cavity, and lipomata with osseous metaplasia account for <1% of all lipomata.

This report describes a patient presenting with an ossifying lipoma with parosteal localization at the mental protuberance. This is followed by review of the current literature for this rare entity.

Materials and Methods: A PubMed literature review designating search terms including “oral” and “parosteal lipoma” or “lipoma with osseous metaplasia” or “ossifying lipoma” or “osseous lipoma” was conducted.

Results: The literature review identified two previous reports of parosteal localization of lipomata in the mandible and 22 cases of lipomata with osseous metaplasia within the oral cavity.

Conclusions: With the initial suspicion of a more malevolent diagnosis, this rare entity, with only two other cases identified, is important to consider in the clinician’s differential diagnoses.

Keywords: Parosteal, lipoma, osseous lipoma, oral

Address for correspondence: Dr. Julie Potter, Victoria Hospital, NHS Fife, Hayfield Road, Kirkcaldy, KY2 5AH, UK.

E-mail: Julie_heather_potter@hotmail.co.uk

Submitted: 06-Jun-2021, **Revised:** 24-Nov-2021, **Accepted:** 24-Jan-2022, **Published:** 31-Mar-2022

INTRODUCTION

Lipomata are currently considered the most common benign soft-tissue mesenchymal neoplasm. As the main constituent of lipomata is mature adipose tissue, they appear most commonly in areas of the body where adipose tissue is present.^[1] 15%–20% of lipomata are found in the head-and-neck region, most often the neck, with only 1%–5% of all lipomata within the oral cavity.^[2] Lipomata account for only 0.1%–5% of all benign oral tumors.^[3] Lipomata most frequently develop in patients over 40 years of age, more typically in men than women and usually with a slow progression over multiple

years.^[4,5] Oral lipomata are most frequently detected in the lips, buccal mucosa, lingual and sublingual tissues.^[1]

Clinically, lipomata tend to present as well-circumscribed masses, and those involving the oral cavity are frequently yellowish, soft and nontender. Histologically, the main constituent of lipomata is mature adipose tissue without evidence of nuclear or cellular atypia.^[1,6]

The case to be discussed is an osteolipoma with parosteal localization, also coined a parosteal lipoma. As far as our

This is an open access journal, and articles are distributed under the terms of the Creative Commons Attribution-NonCommercial-ShareAlike 4.0 License, which allows others to remix, tweak, and build upon the work non-commercially, as long as appropriate credit is given and the new creations are licensed under the identical terms.

For reprints contact: WKHLRPMedknow_reprints@wolterskluwer.com

How to cite this article: Potter J, Richards C, Collin J. Parosteal lipoma of the mandible: A case report and review of the literature. *J Oral Maxillofac Pathol* 2022;26:129-30.

Access this article online	
Quick Response Code: 	Website: www.jomfp.in
	DOI: 10.4103/jomfp.jomfp_179_21

research can identify, this is the third case of a parosteal lipoma of the mandible documented in English-language literature, but it varies in its initial symptom presentation when compared with other reports of lipomata, osteolipoma and parosteal lipomata.

CASE REPORT

The patient was referred by his general medical practitioner to the Oral and Maxillofacial Surgery Department via an expedited suspected cancer pathway, for assessment of a lump of his right lower jaw noted by the patient 3 weeks prior. This lump had visibly enlarged over those few weeks and was becoming painful. The patient was also experiencing constitutional symptoms in this time period, with night sweats, fevers and chills. He had noted a slight facial asymmetry, but had no appetite, weight or skin changes, nor any sensory disturbance.

The patient's past medical history included hypogonadotropic hypogonadism primary lumbar microdiscectomy and gastroesophageal reflux disease. His regular medication included omeprazole, naproxen, testosterone injections and tramadol. The patient had no known allergies and had not smoked cigarettes for 10 years.

On examination, there was a 2 cm palpable bony hard mass fixed to the right mental protuberance, resulting in a subtle facial asymmetry. There was no associated tenderness, no overlying skin changes, sensory deficit or trismus. On intraoral examination, there was no palpable or visible buccal expansion of the labial sulcus, as this lump was positioned close to the inferior mandibular rim. No dental pathology was identified.

RADIOGRAPHIC EXAMINATION

An orthopantomogram and a mandibular occlusal radiograph were taken at this first appointment to assess the composition and location of this bony mass and to identify any potential odontogenic source.

The mandibular true occlusal radiograph [Figure 1] demonstrates a calcified, slightly multilocular appearing lesion arising from the buccal cortex of the mandible in the right parasymphiseal region. The occlusal radiograph demonstrates the area as prominent with a mildly irregular periphery and lies adjacent to the lower right lateral incisor to first premolar. Although this lesion was not readily apparent on the panoramic radiograph, it did serve to help steer the differential diagnoses away from odontological causes [Figure 2]. Although features were not entirely

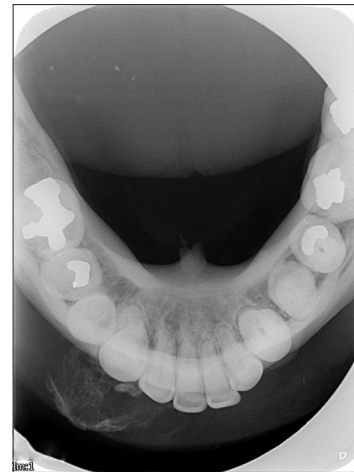

Figure 1: The mixed radiopacity lesion rising from the buccal aspect of the right parasymphiseal region is evident on this mandibular true occlusal radiograph, with an ill-defined periphery

consistent with a primary bone malignancy, an urgent biopsy was recommended by the radiologist.

Given the reported rapid progression of the lesion and constitutional symptoms, the working diagnosis was osteosarcoma. Other differential diagnoses at this time included exophytic bony lesions, such as exostosis, osteoma, osteochondroma and chondrosarcoma.^[7]

A biopsy was conducted under local anesthetic, at this initial consultation appointment following radiographic investigation. An intraoral incision was made in the right labial vestibule, and the bony lump was evident subperiosteally, but free of the mandibular cortex. Due to well-circumscribed and encapsulated nature of lesion, the base of the lump was dissected easily from the surrounding tissue and excised whole. It did not appear attached to adjacent bone, but extended inferiorly, resting against and below the inferior border of the mandible. There was a small depression of mandibular cortex at the surgical site, suggesting a compression defect from this growth.^[8]

HISTOPATHOLOGY

The hard tissue specimen measured 25 mm × 15 mm × 12 mm and was decalcified in formic acid. On microscopic examination, the lesion showed a relatively well-circumscribed polypoid structure, predominantly with mature adipose tissue and lobules of adipocytes. No significant cellular atypia, variation in cell size, nuclear atypia or conspicuous mitotic activity was identified. Islands of mature lamellar bone were scattered throughout the fatty tissue component. There are multiple foci of osseous metaplasia showing trabeculae of

remodeling bone, focally incorporating loose fibrofatty tissue with no evidence of hematopoietic cells [Figure 3 and 4].

The diagnosis agreed with the histopathologist was a benign adipocytic tumor of right mandibular parasymphysis, with a final differential diagnosis of either parosteal lipoma or lipoma with osseous metaplasia, to be correlated against the clinical picture. As this mass was firm and immobile on clinical examination, with evidence of cortical depression of the underlying mandible, coupled with the knowledge that parosteal lipomata often undergo osseous metaplasia, the diagnosis of parosteal lipoma was made.^[8]

Plan for routine 6-month follow-up, but in the COVID-19 pandemic, face-to-face follow-up has been delayed.

DISCUSSION AND REVIEW OF LITERATURE

Lipomata have been separated into four forms by the World Health Organization 2002 guidelines, according to the origin of their location. These forms include: superficial lipoma (arises within subcutaneous tissue); deep lipoma (arises within deep soft tissue, deep to investing fascia), intramuscular or intermuscular lipoma (most commonly within large muscles of thigh, upper arm and shoulder) and parosteal lipoma (arise within the surface of bone, subperiosteally).^[5,9] Furthermore, when the lipoma is intimately related to or within bone, they are categorized in accordance with their relation to the parent bones, as intraosseous (within bone), cortical (relating to cortex of bone) or parosteal.^[8] Parosteal lipomata are an uncommon type of lipoma and occur in intimate association with the periosteum of bone, mostly affect the long bones and presentation in the mandible is rare.^[8] Only two other cases of parosteal lipomata of the oral cavity have been reported, both occurring in the mandible.^[8,10]

Osseous changes in lipomata are rare, seeming to occur in some longstanding and large lipomata. Titles, often used interchangeably, for lipomata with osseous components include: osteolipoma; lipoma with osseous metaplasia; osseous lipoma or ossifying lipoma. This subtype accounts for approximately 0.3% of all lipomata. Osteolipomata are found most frequently at the long bones but have been reported at the femur, radius, humerus, tibia, fibula, clavicle, pelvis and oral cavity.^[2,8]

Raghunath *et al.* conducted a review of English literature, identifying a total of 21 cases of osteolipomata of the head and neck, with only twelve cases of osteolipoma presenting in the oral cavity. Osteolipomata were found in the tongue, sublingual tissues, buccal vestibule, buccal mucosa, hard and soft palate and submandibular region.^[2]

The parosteal lipomata exhibits an intimate relationship to the periosteum, with commonly an attachment to the periosteum, resulting in an osseous reaction occurring within the tumor. Parosteal lipomata may rest directly on the cortex, with or without cartilage or bone elements contained within the tumor.^[2] Parosteal lipomata often lead to definite bony alterations of the parent bones, such as bony hyperostosis, protuberance erosion and compressive changes. Branch-like or linear cortical protuberances and ossification are frequently seen but aggressive bone destruction is consistently absent.^[8] Parosteal lipomata usually present morphologically as homogenous, lobulated and often adherent to adjacent bone.^[8]

Two main theories for the provenance of an osteolipoma include fibroblasts within the lipoma undergoing metaplasia into osteoblasts, a process which may be initiated by repetitive external microtrauma or ischemia secondary to outgrowth of the tumor's blood supply, leading to modification of the mesenchymal calls. The other theory is that the adipocytes and osseous components originate from a multipotent, undifferentiated mesenchymal stem cell.^[1,2,8] Presentation of exophytic osseous components from the cortex of the mandible can highlight suspicions of osteochondroma, osteoma, osteosarcoma or chondrosarcoma. It is important to note that these tumors usually present without surrounding fat components. However, if spiculated periosteal new bone formation with an ill-defined border is present, one should consider osteosarcoma in their differentials.^[8,11,12]

A literature review on the search engine PubMed and Google Scholar was conducted in 2020–2021, including search terms with Boolean operators for “oral” and “parosteal lipoma” or “lipoma with osseous metaplasia” or “ossifying lipoma” or “osseous lipoma.”

INCLUSION CRITERIA

- Articles of English-language literature
- Lipoma with osseous change or parosteal lipoma
- Presentation of lipoma in the oral cavity.

EXCLUSION CRITERIA

- Osteolipomata presenting elsewhere on head and neck that didn't involve the oral cavity
- Osteolipoma of the submandibular space detected by neck examination, without intraoral involvement
- Osteolipoma with additional mesenchymal tissue evident, for example, osteochondrolipoma.
- Insufficient information in report to confirm the lipoma meets the inclusion criteria.

Table 1: Literature review using PubMed and Google Scholar searches and previous literature reviews for osteolipomata and parosteal lipoma of the oral cavity

Author	Year	Age (years)	Male/ female	Site	Clinical presentation	Imaging findings	Time present	Histopathology
Godby <i>et al.</i> ^[13]	1961	54	Male	Floor of mouth	Painless and soft mass: 7×6×3 cm	Radiopaque mass on occlusal radiography	1 year	Mature adipose tissue, cancellous bone, fibrous connective tissue and striated muscle Diagnosis: Sublingual lipoma with ectopic bone formation
Hughes ^[14]	1966	69	Male	Mandibular buccal vestibule	Painless and soft yellowish, "walnut-size" mass. Slight facial asymmetry	No pathology noted on radiography	-	Fat cells with foci of ossification surrounded by fibrous connective tissue Diagnosis: Intra-oral lipoma with osseous metaplasia
Steiner <i>et al.</i> ^[10]	1981	50	Male	Body of mandible: Right mandibular third molar region	Asymptomatic	Well-defined radiolucency on OPG	-	Diagnosis: Parosteal lipoma
Allard <i>et al.</i> ^[15]	1982	81	Female	Mandibular buccal vestibule	Facial asymmetry and painless and hard "walnut-size" mass	Well-defined radiopaque mass with irregular trabeculae on occlusal radiography	30-40 years	Homogenous adipose tissue containing fibrous septa and irregular trabeculae of lamellar bone without hematopoietic tissue Diagnosis: Oral lipoma with osseous metaplasia
Piattelli <i>et al.</i> ^[16]	2001	49	Female	Lateral margin of tongue	Painless and hard mass. Size: 0.8 cm in diameter	-	8 years	Mature adipose tissue containing lamellar bone surrounded by a fibrous pseudocapsule Diagnosis: Osteolipoma
Castilho <i>et al.</i> ^[4]	2004	65	Female	Buccal mucosa	Painless and soft yellowish mass. Size 1×1×0.8 cm	-	-	Mature fat cells supported by fibrous septa. Focal areas of woven bone surrounded by fusiform-shaped mesenchymal cells Diagnosis: osteolipoma
Saghafi <i>et al.</i> ^[17]	2008	68	Male	Mandibular buccal alveolar mucosa	Painless and hard mass. Size 1.5 cm×1.0 cm	No evidence of cortical abnormality or influence on the surrounding structures (radiography)	4 years	Adipose tissue with foci of lamellar bone surrounded by mesenchymal cells Osteolipoma
Gokul <i>et al.</i> ^[18]	2009	6	Male	Hard palate (associated with cleft of hard and soft palate)	Painless and soft mass. Size: 3.0×2.0 cm	Well-defined hypodense lesion with mixed density, showing a well-defined radiodense body (CT)	Congenital (6 years)	Lobules of adipose tissue separated by fibrovascular connective tissue septa and showing the presence of mature bone Diagnosis: Osteolipoma
De Castro <i>et al.</i> ^[6]	2010	47	Female	Buccal mucosa	Facial asymmetry. Painless nodule. Size: 3×4 cm	Patchy areas of radiopacity (occlusal radiography)	10 years	Mature adipose tissue with scattered trabeculae of lamellar bone Diagnosis: Osteolipoma
Adebiyi <i>et al.</i> ^[19]	2011	37	Female	Hard palate	Painless and hard mass. Size: 3.0×4.0 cm	Patchy areas of radiopacity (occlusal radiography)	10 years	Mature adipose tissue with scattered trabeculae of lamellar bone Diagnosis: Osteolipoma
Hsu <i>et al.</i> ^[20]	2012	71	Male	Buccal mucosa	Painless and hard mass. Size: 4.0×2.5 cm	-	4 years	Lobules of mature adipose tissue separated by fibrous septa Randomly distributed trabeculae of mature lamellar bone and foci of woven bone Diagnosis: Osteolipoma
Shabbir and Putnam ^[21]	2013	58	Female	Mandibular buccal vestibule	2×2 cm painless and hard mass. Facial asymmetry	Diffuse area right buccal sulcus with calcifications flecks. No obvious involvement with adjacent bone demonstrated on occlusal radiograph	1 year	Adipose tissue containing thin-walled vessels with intersecting trabecular type bone with surrounding fibrous tissue Diagnosis: Osteolipoma

Contd...

Table 1: Contd...

Author	Year	Age (years)	Male/female	Site	Clinical presentation	Imaging findings	Time present	Histopathology
Sun <i>et al.</i> ^[8]	2013	48	Male	Parosteal lipoma of mandible	Slow growing mass on chin associated with occasional numbness right lower lip. 8×6×5 cm mass beneath chin and bilateral mental areas. Buccogingival sulcus shallower	OPG radiograph showed no major bony changes. CT revealed broad-based, well-demarcated mass with fat attenuation beneath the surface with areas of ossification. Exophytic osseous protuberance of mandible and branch-like periosteal thickening	20 years	Mostly mature adipocytes with scattered layers of mature bone foci seen Diagnosis of ossifying parosteal lipoma
Bajpai <i>et al.</i> ^[12]	2014	55	Male	Hard palate	Painless and hard yellowish mass. Size 1.5×1.4 cm	Patchy area of radiopacity on occlusal radiography	4 years	Bone trabeculae surrounded by lobules of mature adipocytes separated by fibrous septa Diagnosis: Osteolipoma
Amaral <i>et al.</i> ^[11]	2015	51	Male	Mandibular buccal mucosa	Slight facial asymmetry. Painless and hard mass. Size: 2.0×1.5 cm	Well-defined hyperechogenic mass with areas of calcification (ultrasonography)	3 years	Proliferation of mature fat cells with central areas of lamellar bone trabeculae and fibrous septa Diagnosis: Osteolipoma
Ragunath and Manjunatha ^[2]	2015	20	Female	Floor of the mouth	Painless and hard yellowish mass. Size: 6.0×6.0 cm	Well-defined, hypodense lesion with irregular hyperdense areas on CT	3 years	Central areas of osseous trabeculae and lobules of mature adipose tissue Diagnosis: Osteolipoma
Omonte <i>et al.</i> ^[1]	2015	29	Female	Buccal mucosa	Painless and hard mass. Size 1.5×1.5 cm	Spherical radiopacity with an irregular trabecular pattern (soft-tissue radiography)	8 months	Mature adipose tissue with fibrous septa and irregular trabeculae of immature bone Tumor surrounded by a thin osseous layer and a fibrous capsule Diagnosis: Osteolipoma
Raviraj <i>et al.</i> ^[22]	2016	38	Female	Buccal mucosa	Painless swelling in her left inner cheek, gradually increasing 2×2×3 cm	Multiple dense homogenous radio-opacities in the left mandibular posterior region on OPG	10 years	Adipose tissue and bony trabeculae Diagnosis: Osteolipoma
Fukushima <i>et al.</i> ^[23]	2016	28	Male	Coronoid process	Presenting symptom of trismus and bone-like hard mass was palpated around lower edge of zygomatic bone. Soft-tissue tumor, 66×45×21 mm	Contrast-enhanced magnetic resonance image showed that the mass mainly composed of adipose tissue	10-12 years	Diffuse proliferation of mature adipose cells was observed, and mature bone tissue was widely distributed within the tumor. In part of these tissues, a lining of osteoblasts was observed, with no lipoblasts Diagnosis: Osteolipoma
Firth <i>et al.</i> ^[24]	2017	56	Female	Buccal mucosa	Mass in right buccal mucosa adjacent to 47	CT shows calcified lesion in the right buccal mucosa	-	Partially encapsulated lobules of adipose tissue. Within one area, there was a fibrous connective tissue surrounding piece of vital bone with large fibro-fatty marrow space and prominent blood vessels Diagnosis: Osteolipoma

Contd...

Table 1: Contd...

Author	Year	Age (years)	Male/ female	Site	Clinical presentation	Imaging findings	Time present	Histopathology
Anbinder <i>et al.</i> ^[25]	2017	46	Female	Vestibule of posterior maxilla	Slight facial asymmetry. Slowly growing since childhood. Wears complete upper denture 2 cm in size	CT demonstrates well-defined hypodense lesion with hyperdense areas in the vestibular area of the posterior maxilla	~30 years	Incisional biopsy disclosed compact lamellar bone that surrounded mature adipose tissue - Lesion was attached to maxilla by wide base Histopathology showed mature adipose tissue interspersed with mature trabeculae of lamellar bone. Lesion surrounded by compact lamellar bone Diagnosis: Osteolipoma
Arantes <i>et al.</i> ^[26]	2017	60	Female	Parasymphiseal mandible/ submental	Painless right submental swelling with discrete facial asymmetry. 1.5 cm well-defined, mobile nodular mass	No alteration on OPG. CT with 3D reconstruction demonstrated a hyperdense mass well-circumscribed on the right parasymphysis. Central calcified portion measuring 1.2 cm	5 years	Nonencapsulated proliferation of mature adipose tissue. Connective tissue septa served separating adipocytes at lobules Some areas of normal bony trabeculae were observed Diagnosis: Osteolipoma
Attar and Mohammadi ^[3]	2020	37	Female	Hard palate	Slow-growing and painless palatal swelling, 3×4 cm in relation to upper left posterior teeth. Normal appearance of overlying mucosa	Occlusal radiograph showed patchy areas of radiopacity	10 years	Mature adipose tissue composed of uniform adipocytes, with trabeculae of lamellar bone scattered throughout. Diagnosed as osteolipoma
Sharma and Dhillon ^[27]	2020	35	Male	Hard palate	Painless round to oval palatal mass with irregular margins, immobile and nontender 4 cm×2.7 cm×0.8 cm in size	Noncontrast CT scan of facial bones demonstrated well-circumscribed, fat-containing, calcified hard palate lesion	8 years	Tissue lined by keratinized stratified squamous epithelium. Scattered bony trabeculae with features of osteoblastic rimming were identified Diagnosed as hard palate osteolipoma
Potter J <i>et al.</i>	2021	48	Male	Parasymphiseal mandible	Painful, apparently rapidly enlarging lesion right parasymphysis, with concurrent symptoms of night sweats, fever, and chills Slight facial asymmetry Immobile 25 mm×15 mm×12 mm in size	Occlusal radiograph demonstrated calcified, slightly multilocular appearing mass arising from buccal mandible in the right parasymphiseal region, prominent with mildly irregular periphery No abnormality detected on OPG	3 weeks	Circumscribed polypoid structure, predominantly mature adipose tissue, with lobules of adipocytes Islands of mature lamellar bone scattered throughout fatty tissue. Multiple foci of osseous metaplasia and no hematopoietic cells Diagnosis of parosteal lipoma or lipoma with osseous metaplasia

OPG: Orthopantomogram, CT: Computed tomography

The literature review identified two previous reports of parosteal localization of lipomata in the mandible and 22 cases of lipoma with osseous metaplasia within the oral cavity. This led to a total of 24 cases, which are detailed below.

Table 1 displays the reported cases of oral osteolipomata chronologically, with inclusion of the date of publication,

author, patient age in years (Y) and gender (M– Male, F– Female), presentation and location of the lesion, along with radiographic and histopathological findings. The two cases of parosteal lipomata are highlighted in green.

Table 1 demonstrates that the average, mean age at which osteolipomata are detected is 46-years-old, with the

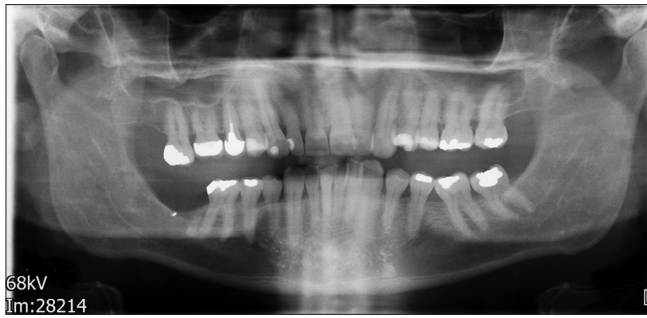

Figure 2: Panoramic radiograph. No obvious odontogenic or bony pathology is noted

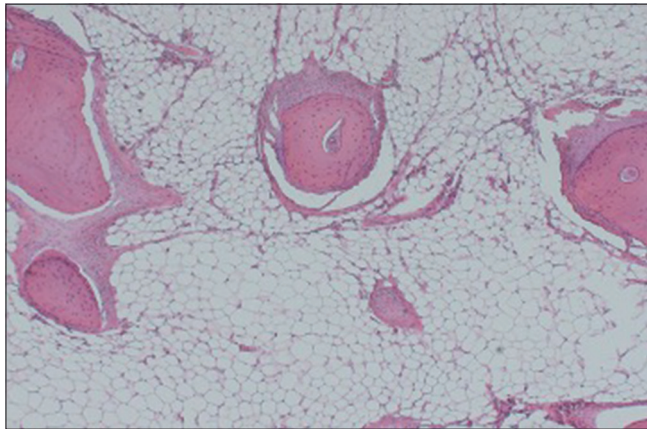


Figure 3: Low-power view photomicrograph demonstrating islands of mature lamellar bone scattered among the fatty tissue component

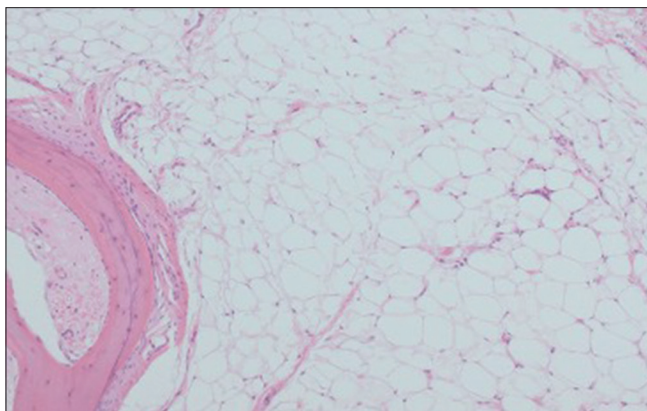


Figure 4: High-power photomicrograph demonstrating mature adipose tissue and lobules of adipocytes

duration of lesion being present for the average mean of 10.8 years. Only three out of the 26 cases presented with symptoms, including paresthesia from pressure of the mass and trismus. No other history of pain documented except for this current case. This review demonstrated a slight predilection of osteolipomata for female gender (52%). This is in contrast to existing literature, which have shown oral lipomata and osteolipomata to be more common in men.^[1-27]

The treatment for lipomata, including parosteal and osseous lipomata, is surgical excision. It is not often difficult to dissect a lipoma contained within soft tissue, or a parosteal lipoma abutting the bone. If the lesion has an intimate osseous relationship, is fixed or has altered the parent bone form, surgical excision requires subperiosteal dissection, with potential for more invasive surgical procedures such as an osteotomy or segmental resection of bone, to free the mass from underlying bone. Local recurrence of these benign neoplasms is rare and malignant changes within parosteal lipomata have not been documented.^[2,8]

CONCLUSIONS

Osteolipomata of the oral soft tissues are rare, particularly parosteal lipomata. The increasing cases in the literature should remind the clinician and pathologist to keep this entity in mind. Histopathological diagnosis according to the criteria mentioned in this review will help to categorize these rare lesions and further understand their origin. Despite their benign nature and lack of recurrence, it is essential to differentiate these entities from the malignant lesions, including osteosarcoma.^[1]

Declaration of patient consent

The authors certify that they have obtained all appropriate patient consent forms. In the form the patient (s) has/have given his/her/their consent for his/her/their images and other clinical information to be reported in the journal. The patients understand that their names and initials will not be published and due efforts will be made to conceal their identity, but anonymity cannot be guaranteed.

Acknowledgments

We would like to thank Dr. Miranda Pring, Consultant of Oral and Maxillofacial Pathology, for the histopathology.

Financial support and sponsorship

Nil.

Conflicts of interest

There are no conflicts of interest.

REFERENCES

1. Omonte SV, de Andrade BA, Leal RM, Capistrano HM, Souza PE, Horta MC. Osteolipoma: A rare tumor in the oral cavity. *Oral Surg Oral Med Oral Pathol Oral Radiol* 2016;122:e8-13.
2. Raghunath V, Manjunatha B. Osteolipoma of Floor of the Mouth. *BMJ Case Rep* 2015. [doi: 10.1136/bcr-2015-209883].
3. Attar B, Mohammadi S. Osteolipoma of the oral cavity mimicking an intrabony lesion: A case report. *Oral Maxillofac Surg Cases* 2020;6:100168.
4. Castilho RM, Squarize CH, Nunes FD, Pinto Júnior DS. Osteolipoma: A rare lesion in the oral cavity. *Br J Oral Maxillofac Surg* 2004;42:363-4.

Potter, *et al.*: Parosteal Lipoma of the Mandible

5. Upadhyaya JD, Cohen DM, Islam MN, Bhattacharyya I. Firm, dome-shaped mass of lower lip. *Oral Surg Oral Med Oral Pathol Oral Radiol* 2017;126:4-8.
6. de Castro AL, de Castro EV, Felipini RC, Ribeiro AC, Soubhia AM. Osteolipoma of the buccal mucosa. *Med Oral Patol Oral Cir Bucal* 2010;15:e347-9.
7. Santosh AB, Boyd D, Laxminarayana K. Proposed Clinico-Pathological Classification for Oral Exophytic Lesions. *J Clin Diagn Res* 2015;9:ZE01-8.
8. Sun Z, Sun L, Zhang Z, Ma X. Ossifying parosteal lipoma of the mandible: A case report and review of the literature. *Dentomaxillofac Radiol* 2013;42:57852073.
9. Fletcher C, Unni K, Mertens F. Pathology and Genetics of Tumours of Soft Tissue and Bone. World Health Organisation Classification of Tumours. IARC Press, International Agency for Research on Cancer, Lyon. 2002.
10. Steiner M, Gould AR, Rasmussen J, LaBriola D. Parosteal lipoma of the mandible. *Oral Surg Oral Med Oral Pathol* 1981;52:61-5.
11. Amaral MB, Borges CF, de Freitas JB, Capistrano HM, Mesquita RA. Osteolipoma of the oral cavity: A case report. *J Maxillofac Oral Surg* 2015;14:195-9.
12. Bajpai M, Kumar M, Agarwal D, Agrawal S, Gupta S, Kumar M. Osteolipoma of the palate – An unusual presentation. *Natl J Maxillofac Surg* 2014;5:250-1.
13. Godby A, Drez P, Field J. Sublingual lipoma with ectopic bone formation. Report of a case. *Oral Surg Oral Med Oral Pathol* 1961;14:625-9.
14. Hughes CL. Intraoral lipoma with osseous metaplasia. Report of a case. *Oral Surg Oral Med Oral Pathol* 1966;21:576-8.
15. Allard R, Blok P, Van der Kwast W. Oral lipomas with osseous and chondrous metaplasia; report of two cases. *J Oral Pathol* 1982;11:18-25.
16. Piattelli A, Fioroni M, Iezzi G. Osteolipoma of the tongue. *Oral Oncol* 2001;37:468-70.
17. Saghafi S, Mellati E, Sohrabi M. Osteolipoma of the oral and pharyngeal region; report of a case and review of the literature. *Oral Surg Oral Med Oral Pathol Oral Radiol Endod* 2008;105:e30-4.
18. Gokul S, Ranjini KV, Kirankumar K, Hallikeri K. Congenital osteolipoma associated with cleft palate: A case report. *Int J Oral Maxillofac Surg* 2009;38:91-3.
19. Adebisi KE, Ugboko VI, Maaji SM, Ndubizu G. Osteolipoma of the palate: Report of a case and review of the literature. *Niger J Clin Pract* 2011;14:242-4.
20. Hsu HH, Lee LY, Chang KP. Pathology quiz case 2. Osteolipoma of the buccal space. *Arch Otolaryngol Head Neck Surg* 2012;138:97-8.
21. Shabbir F, Putnam G. Oral Osteolipoma: A case report. *Oral Surg* 2013;7:56-8.
22. Raviraj J, Kumar-Bokkasam V, Suresh D, Venkata S. Osteolipoma of buccal mucosa: Case report and literature review. *J Clin Exp Dent* 2016;8:e214-8.
23. Fukushima Y, Kitamura T, Hayashi N, Enoki Y, Sato T, Yoda T. A huge osteolipoma involving the coronoid process: A case report. *J Oral Sci* 2016;58:141-4.
24. Firth NA, Allsobrook O, Patel M. Osteolipoma of the buccal mucosa: A case report. *Aust Dent J* 2017;62:378-81.
25. Anbinder AL, Milhan NVM, Trocino BS, Taylor AM. Osteolipoma in posterior maxilla: A case report. *J Oral Diag* 2017;02:e20170026.
26. Arantes D, Gomez R, Noronha V. Osteolipoma: A painless mandibular mass. *Oral Sci Int* 2017;15:18-21.
27. Sharma S, Dhillon V. Osteolipoma: An extremely rare hard palate tumour. *Cureus* 2020;12:e8146.