



# Contouring Atlas for Delineation of Swallowing-Related Structures for PATHOS Trial

*Nachi Palaniappan<sup>1</sup>, Waheeda Owadally<sup>1</sup>, Matthew Beasley<sup>2</sup>, Mererid Evans<sup>1</sup>*

1 Velindre Cancer Centre, Cardiff

2 Bristol Haematology and Oncology Centre, Bristol

# Disclaimer

The outlines shown represent consensus view of the authors and is based on the publications referenced in the radiotherapy guidance document for PATHOS.

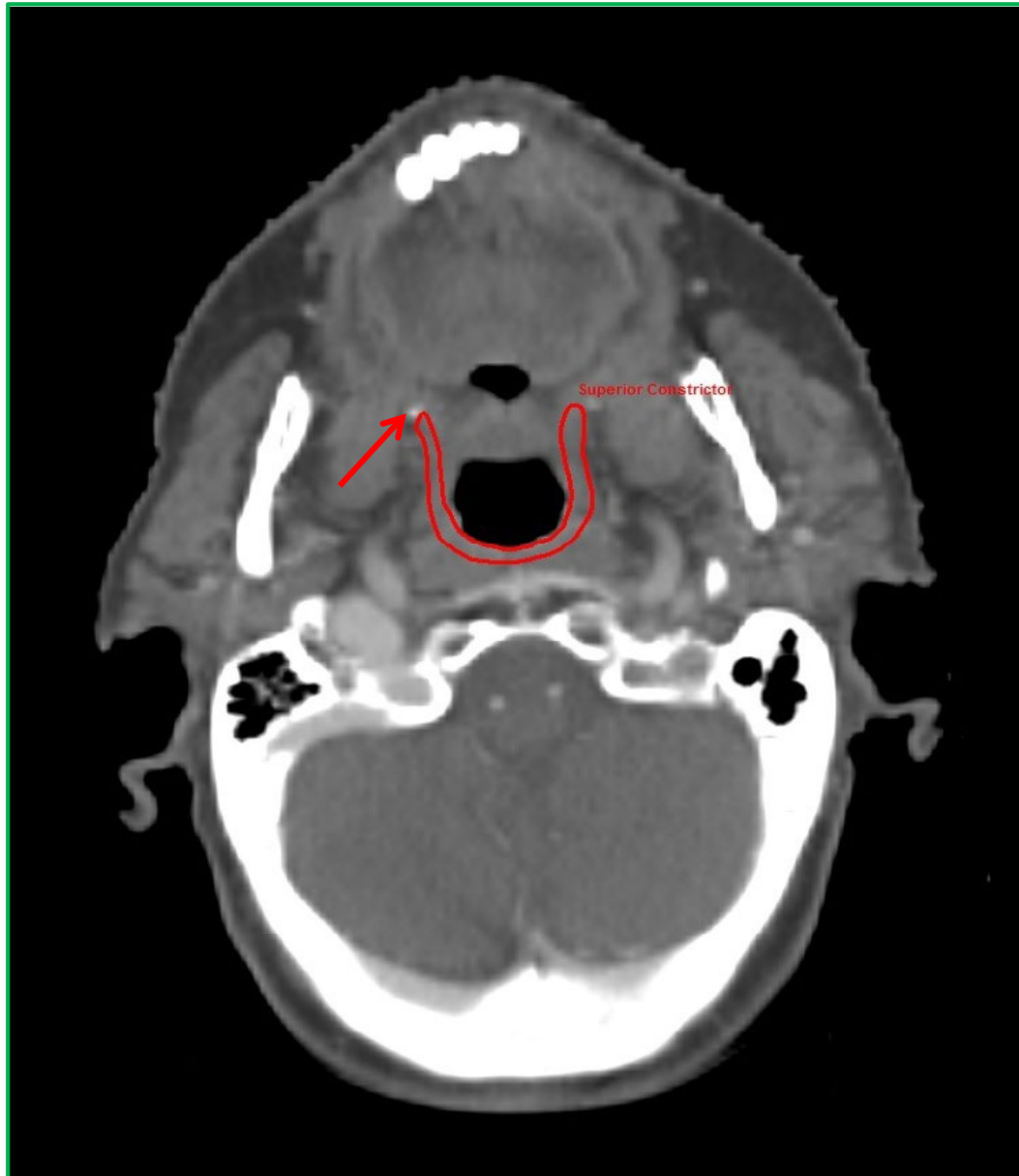
The material presented in this guidance document is intended for delineating swallowing related structures in PATHOS Trial.

Authors retain copyright for this document and are not responsible for use of this material outside of this study.

## Helpful Tips to Navigate the Document

1. To navigate quickly, use bookmark on the left to go to respective structures.
2. The cranial slice of each structure has boundaries displayed on the right.
3. To see boundaries of each structure on other slices, click and hold the mouse over the text on the bottom right.

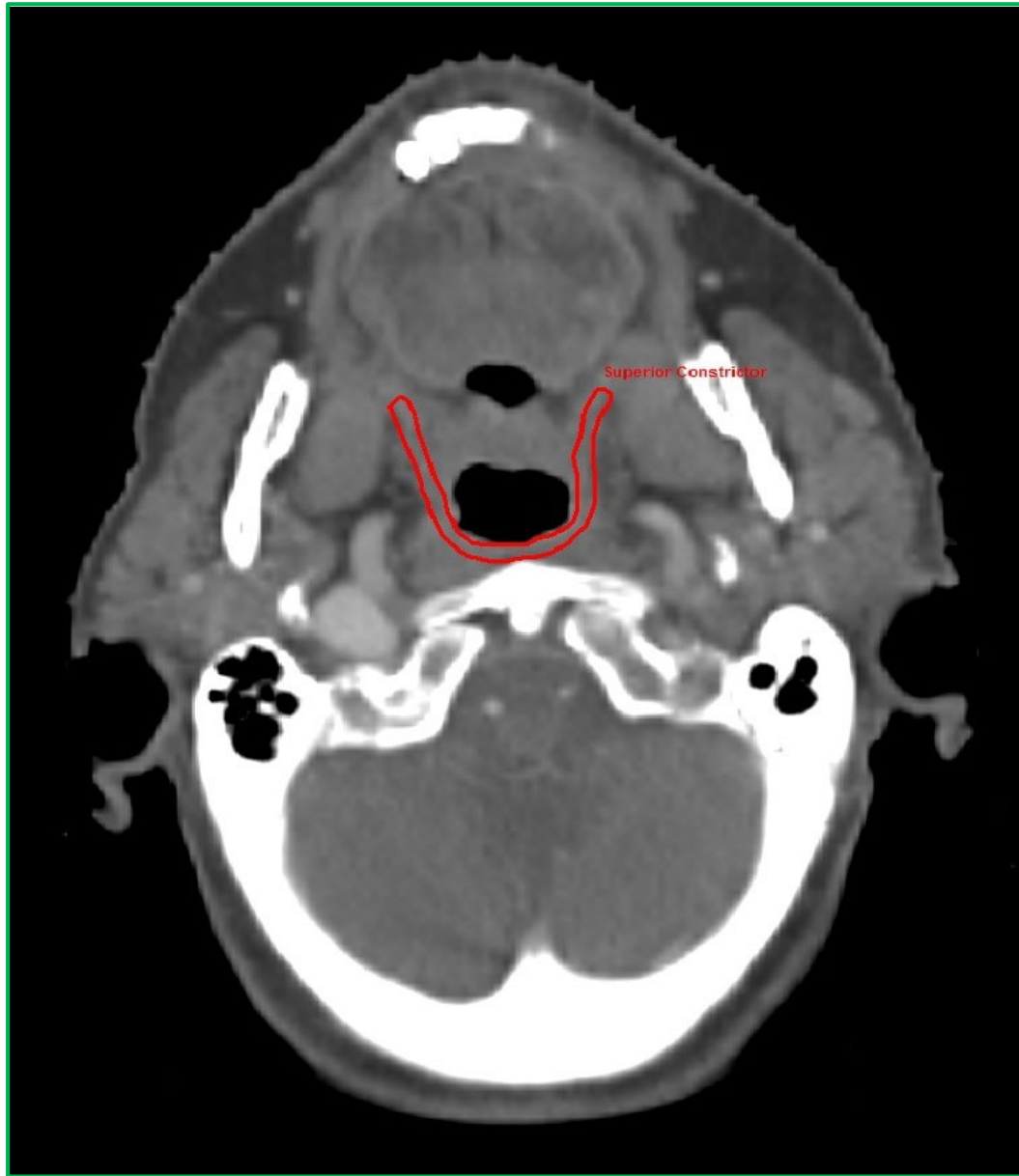# Superior Constrictor - Cranial Boundary

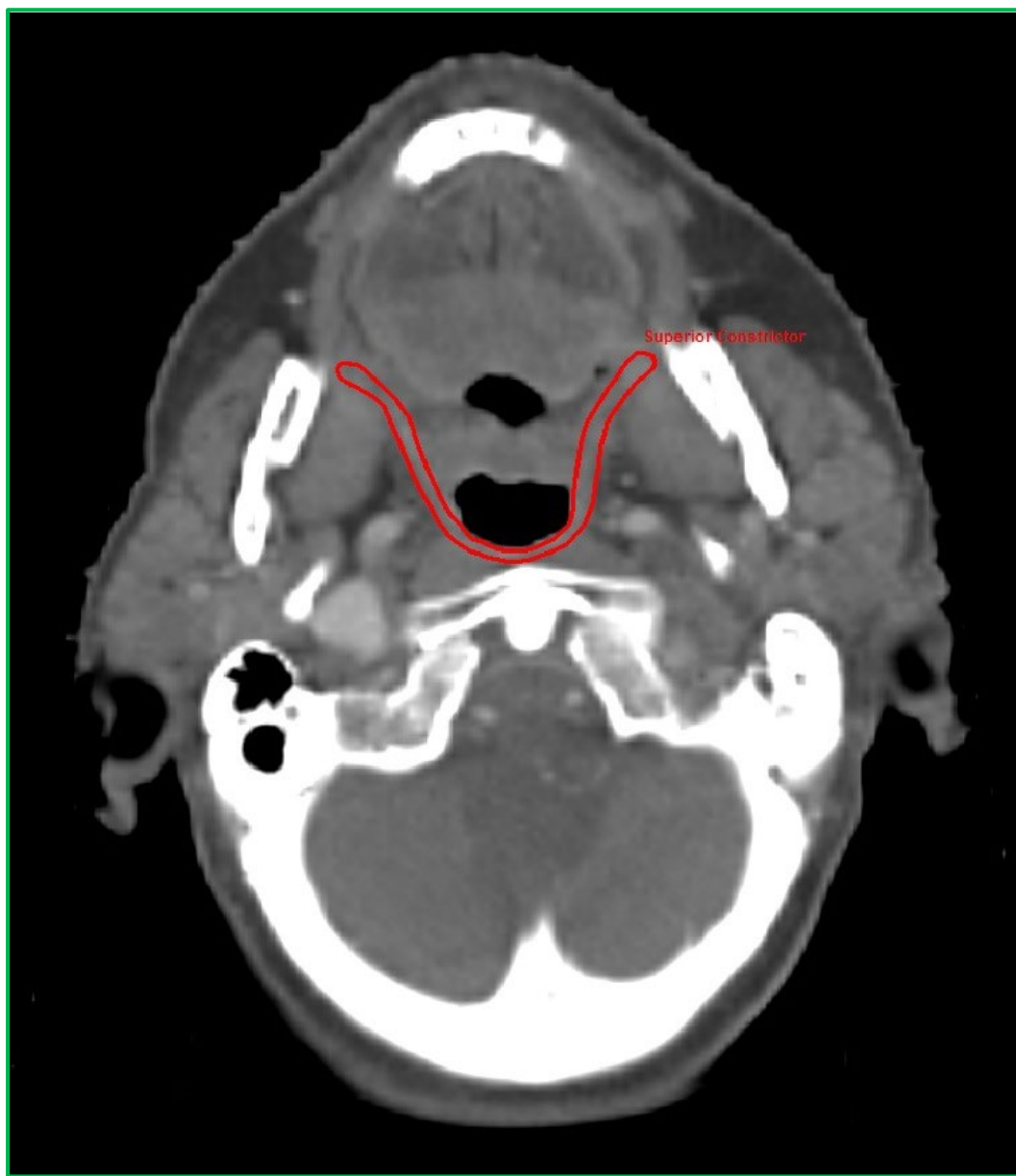


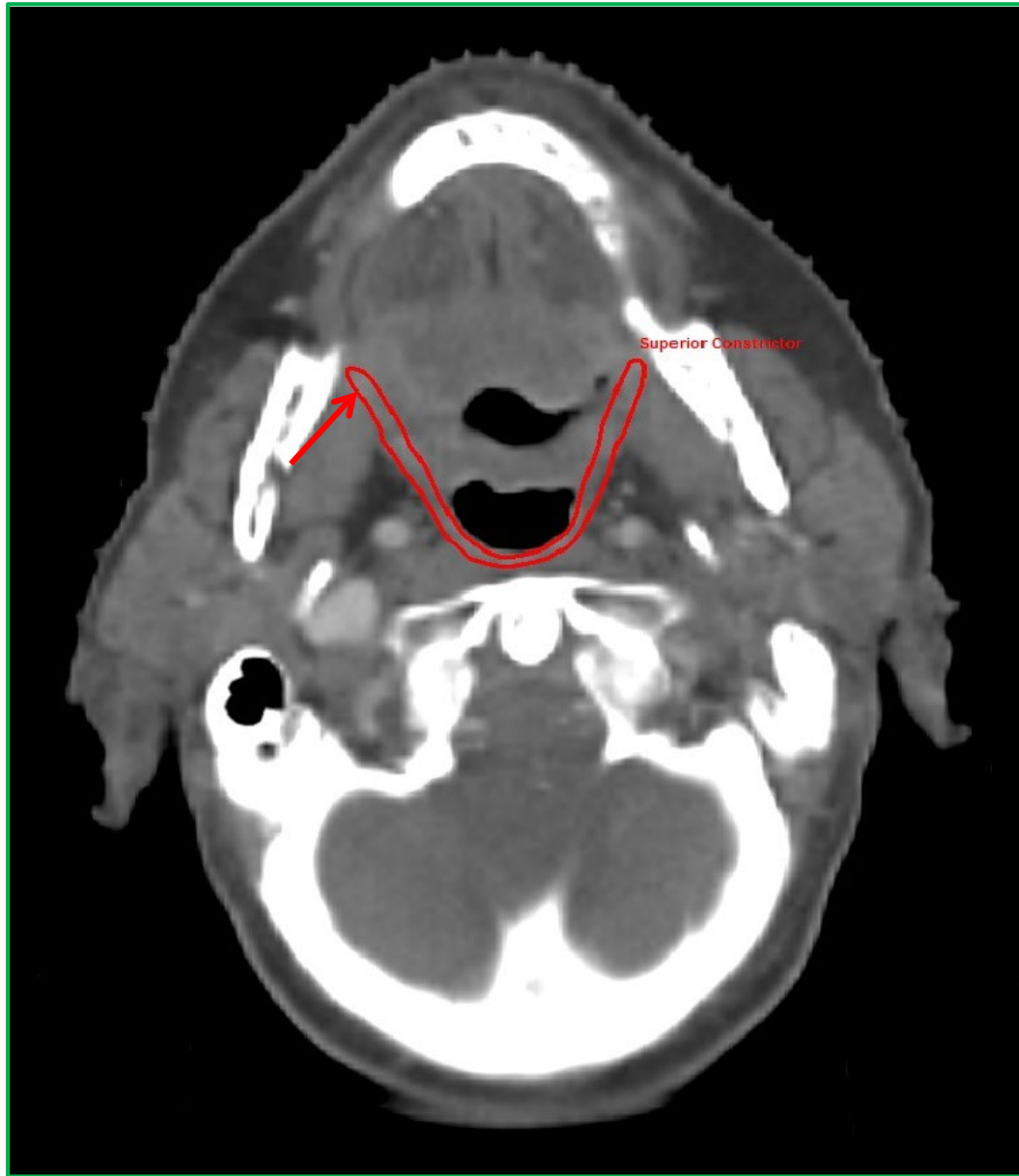
Red arrow - Right Pterygoid hamulus

Cranial	Caudal tip of pterygoid hamulus
Caudal	Lower edge of C2
Anterior	Tongue base/pharyngeal lumen
Posterior	Prevertebral muscle
Lateral	Medial pterygoid / Parapharyngeal space
Medial	Pharyngeal lumen

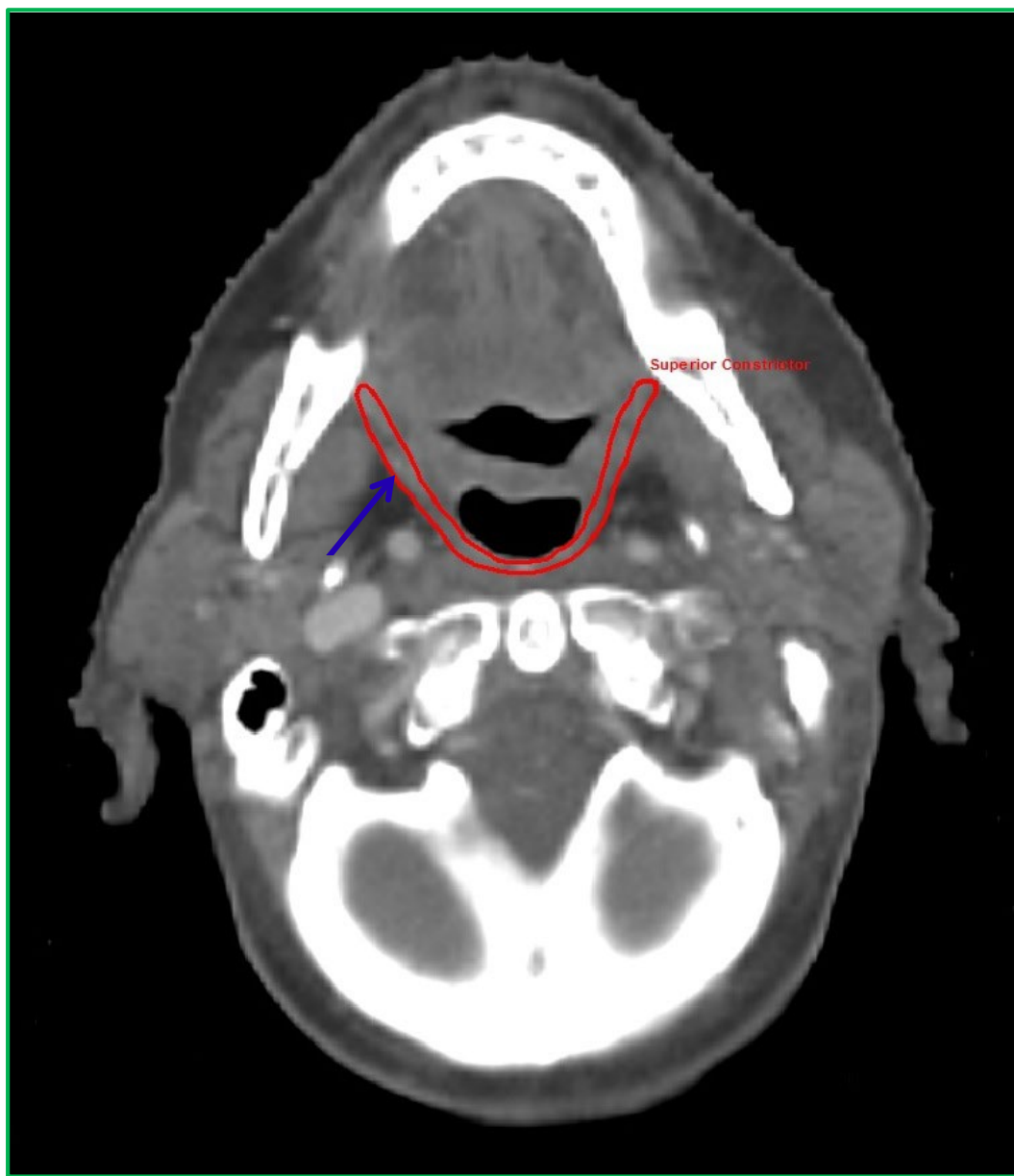
**Superior Constrictor Boundaries**





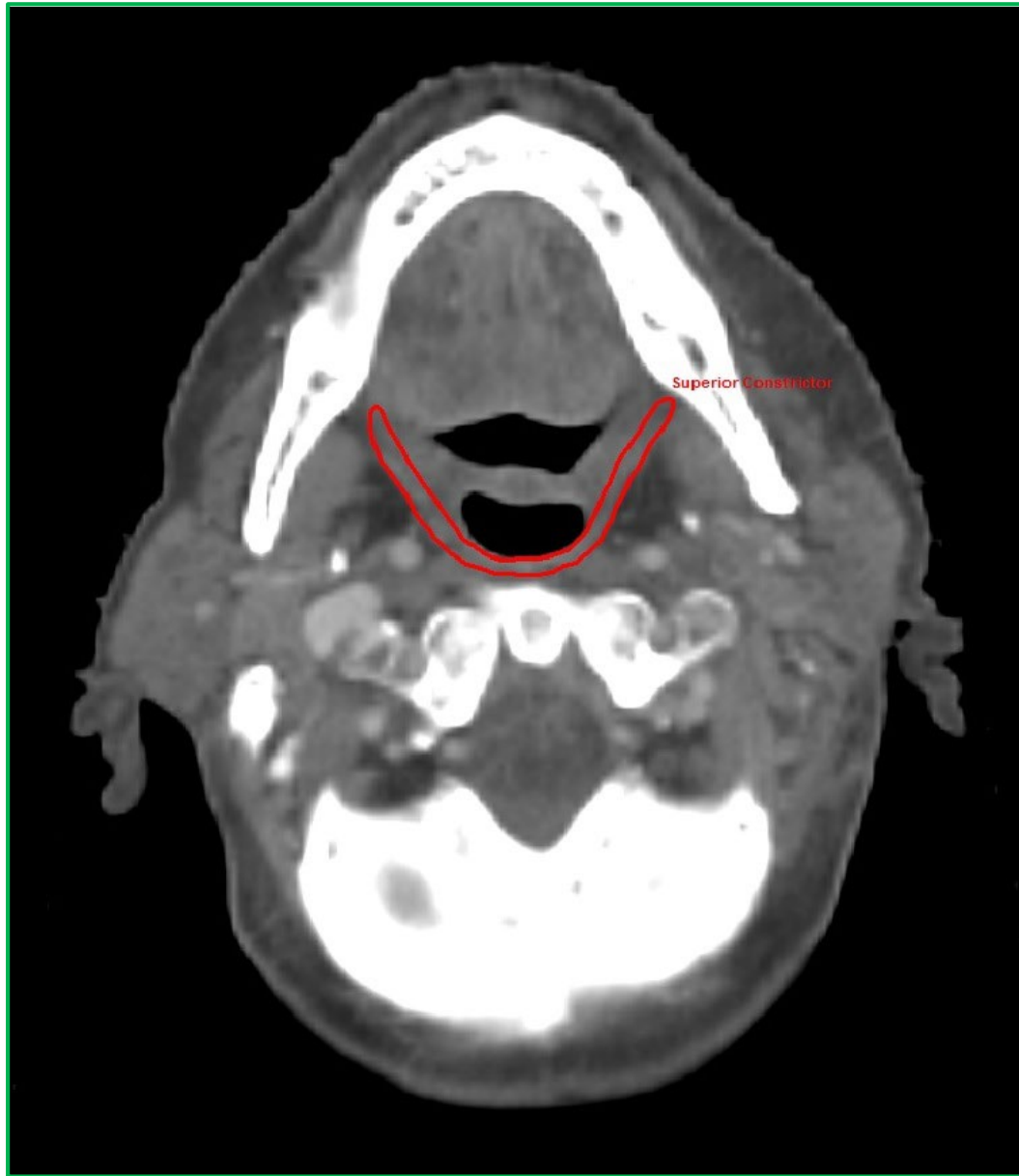


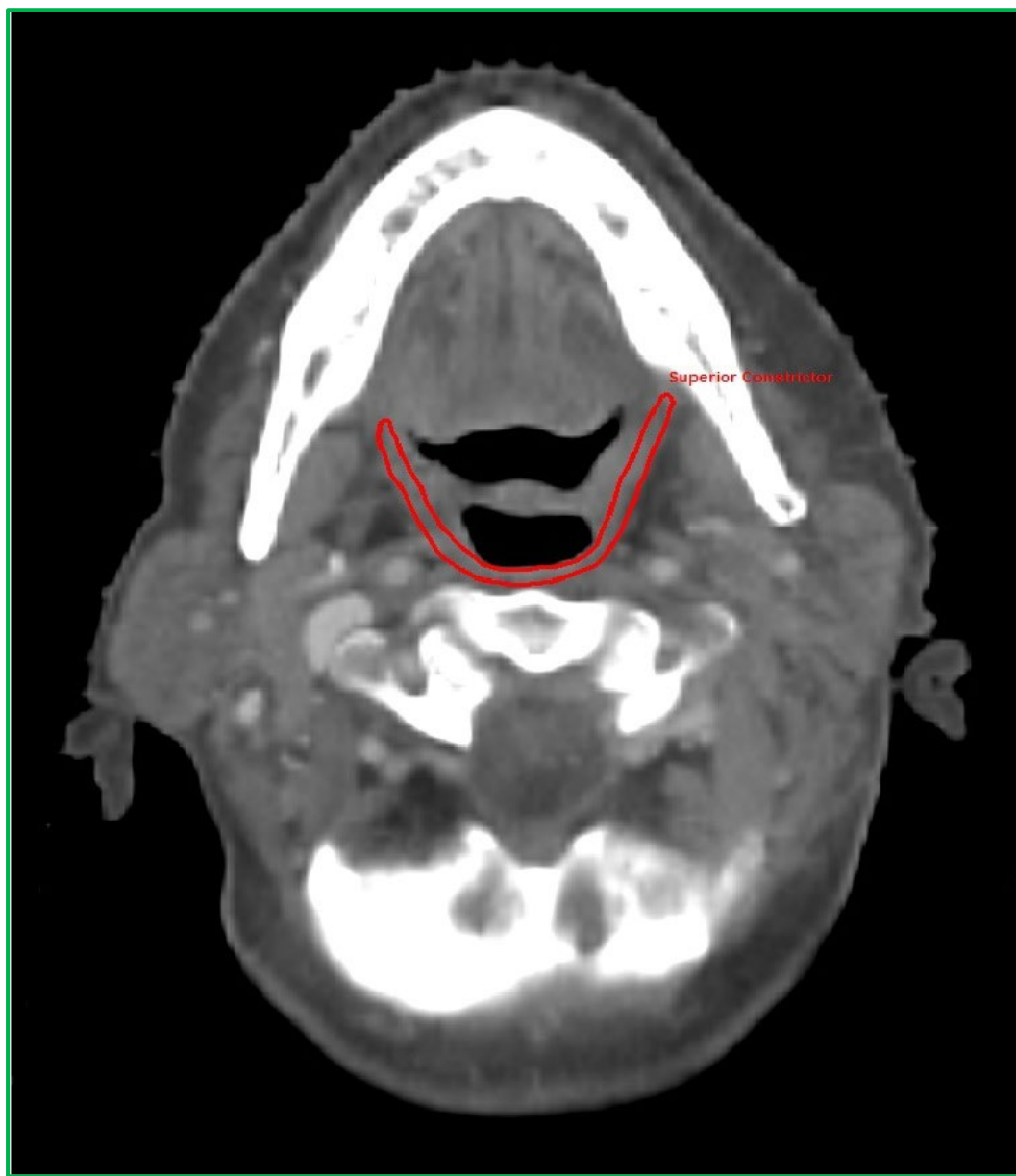
**Red arrow - Medial border of Medial Pterygoid**

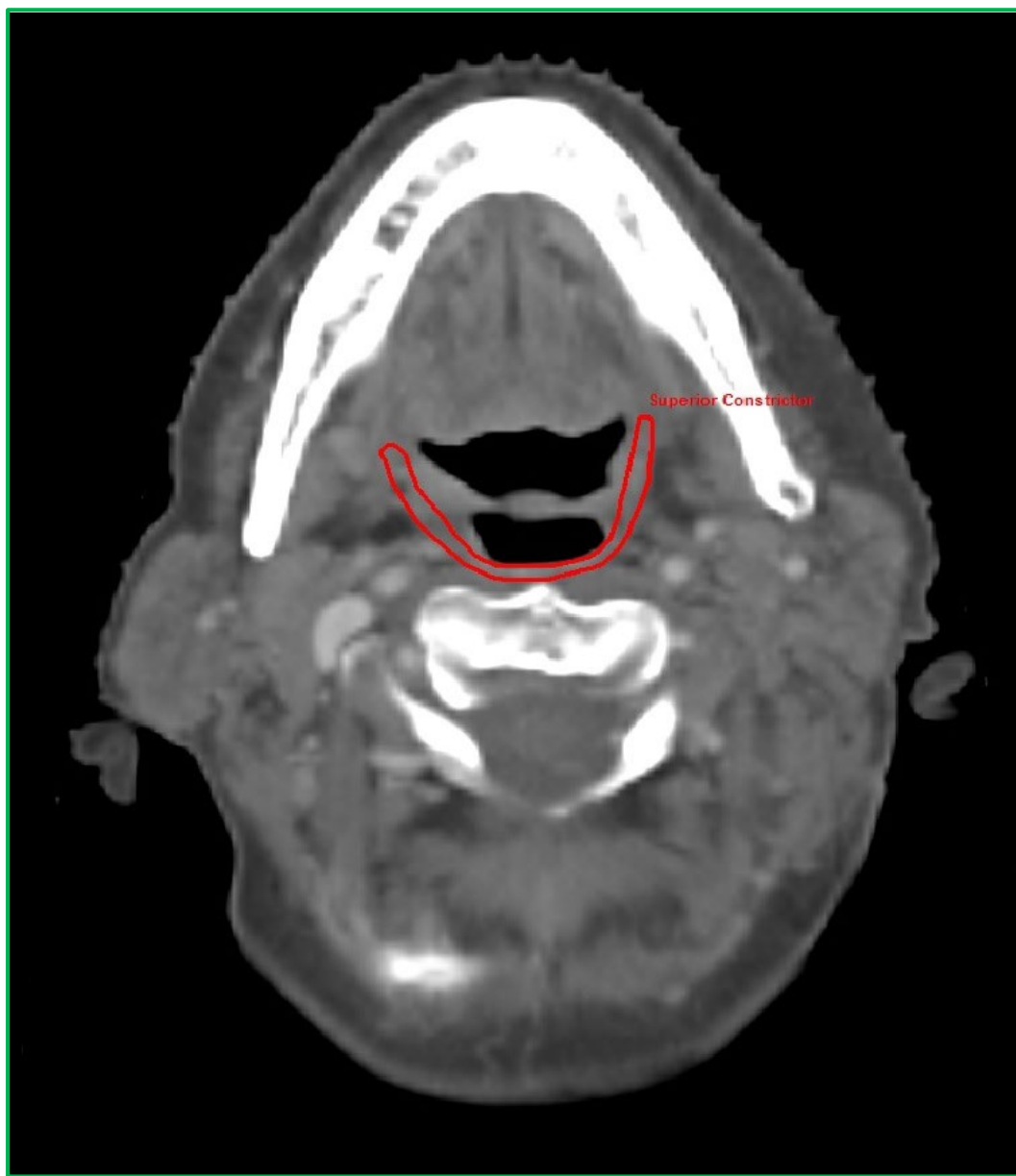


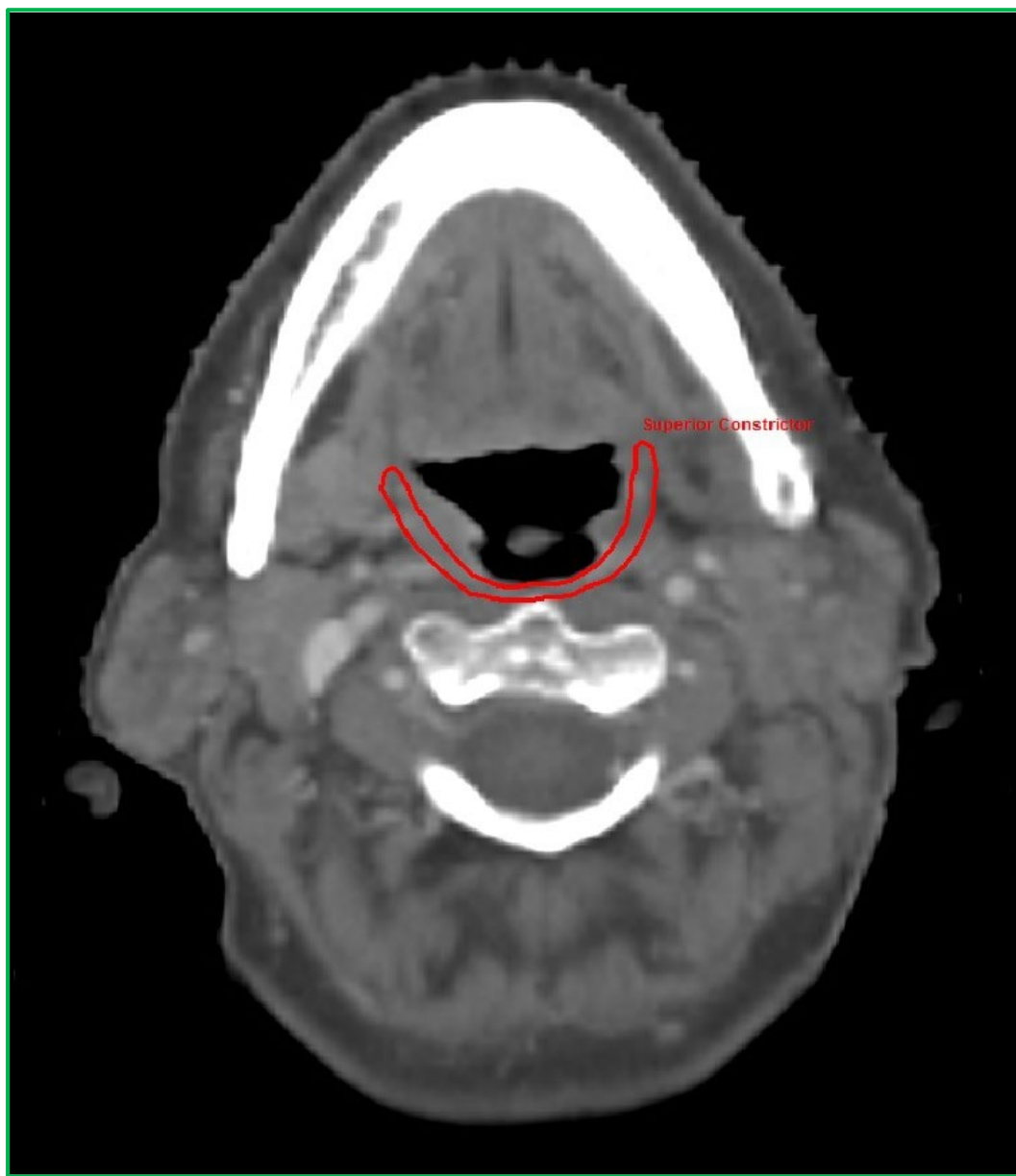
**Blue arrow - Medial border of Parapharyngeal space**

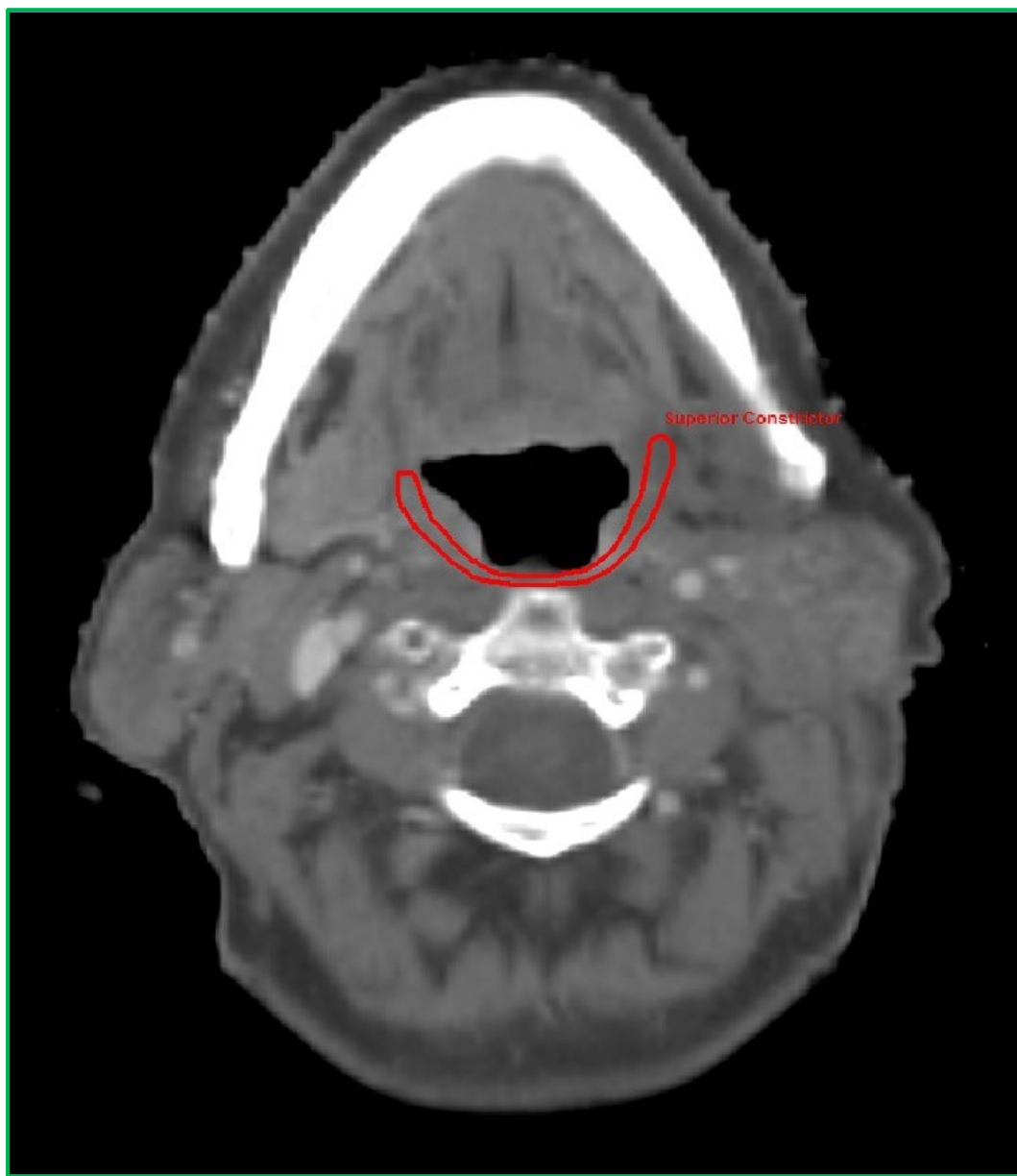


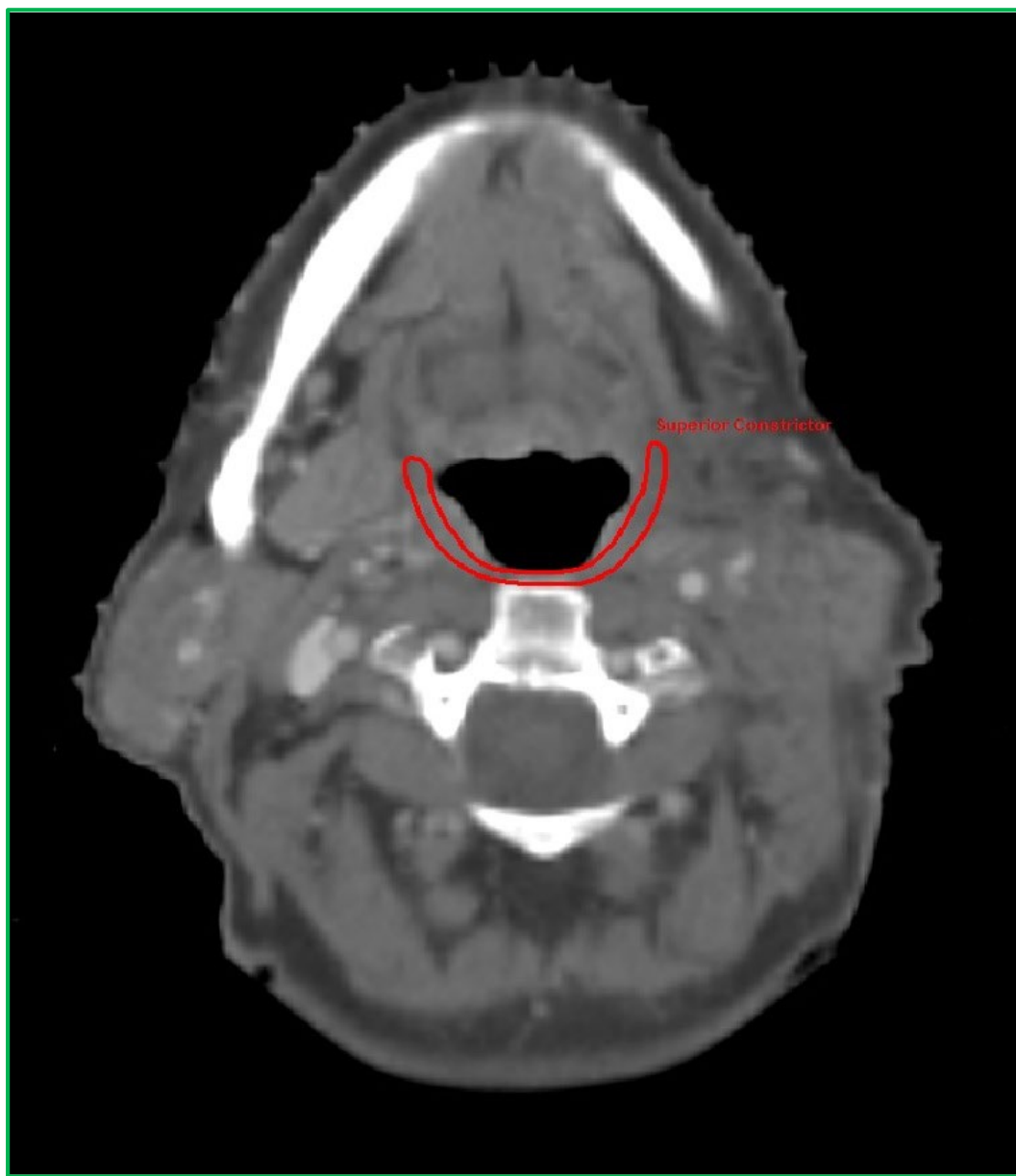


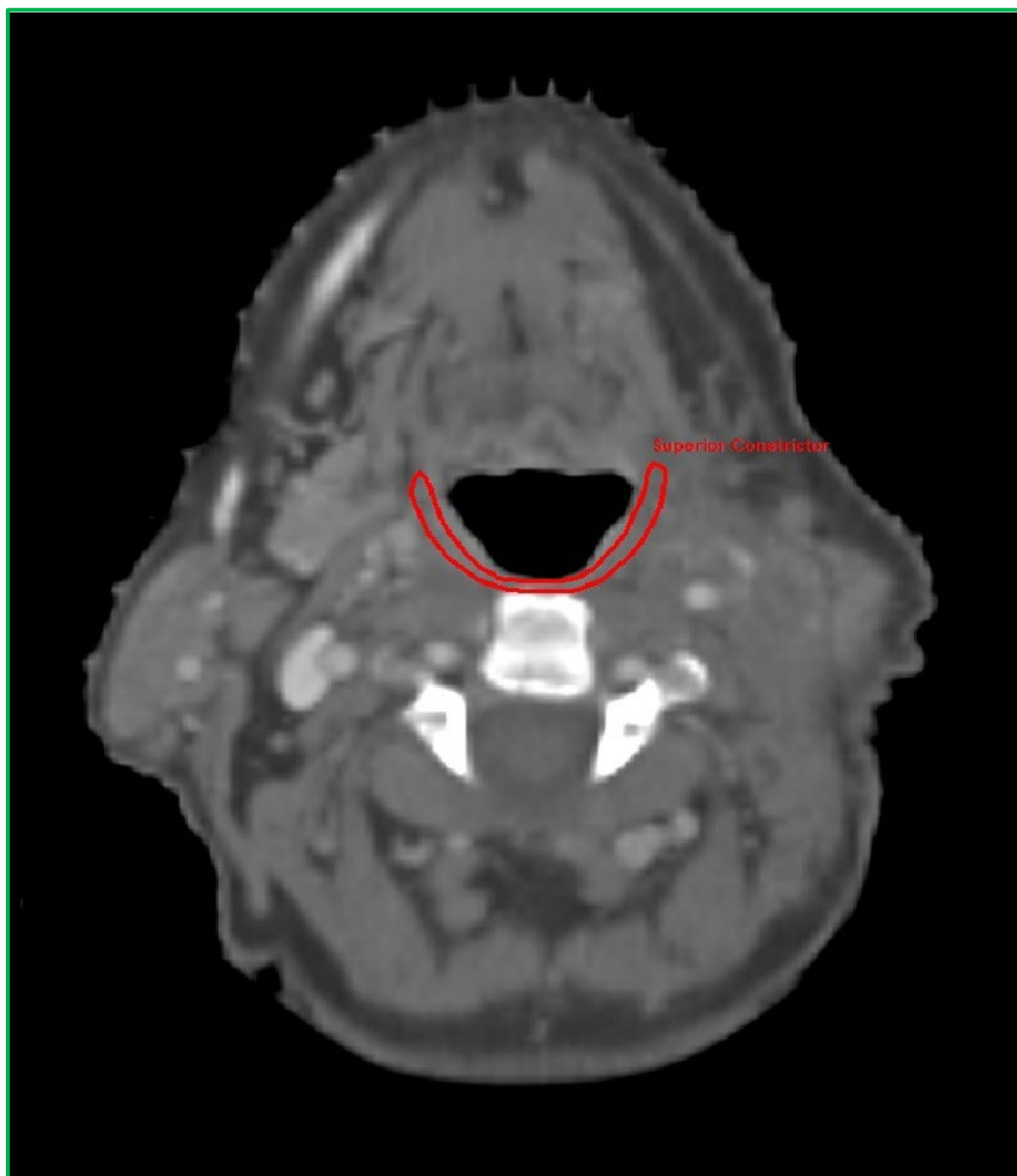




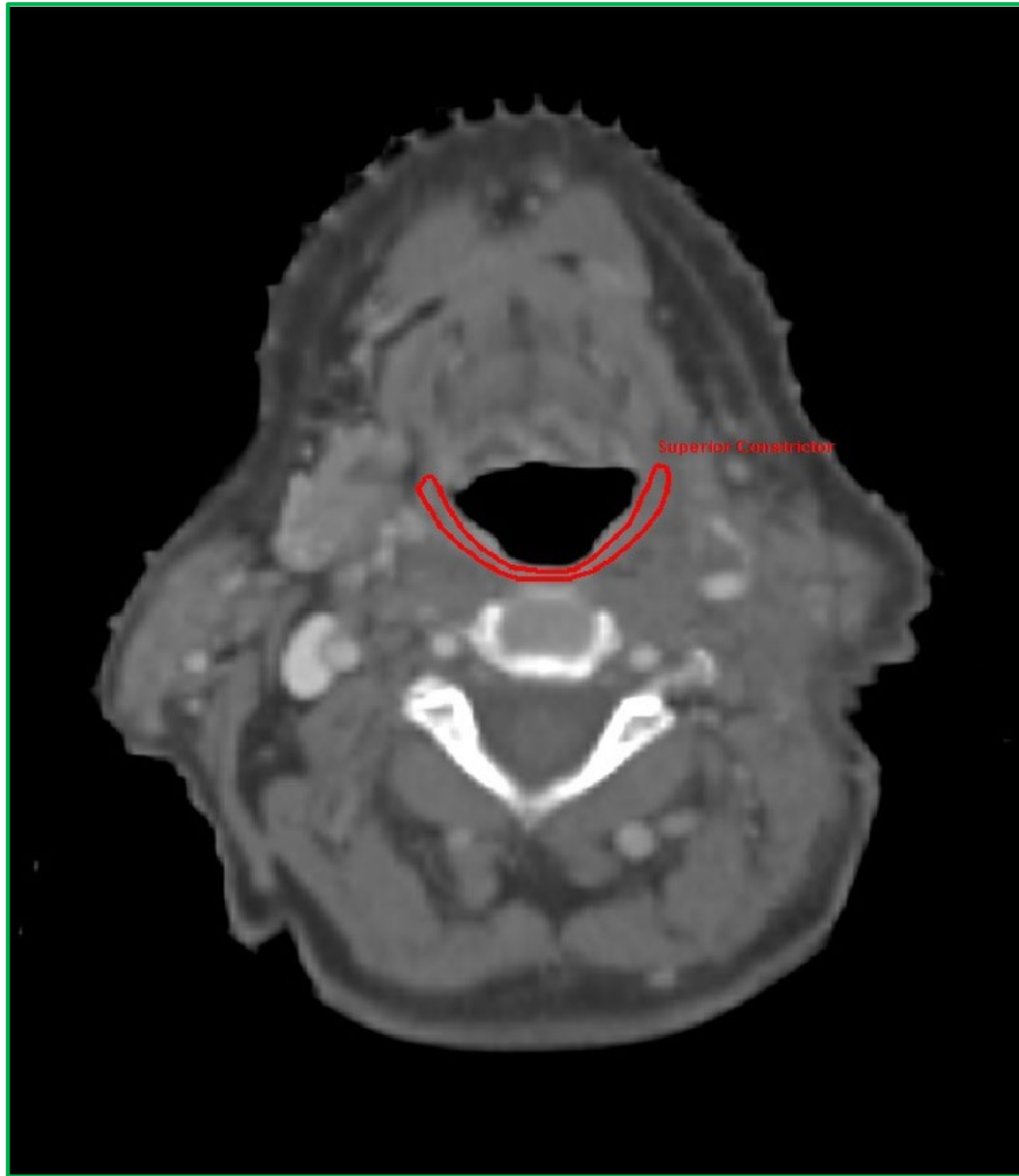






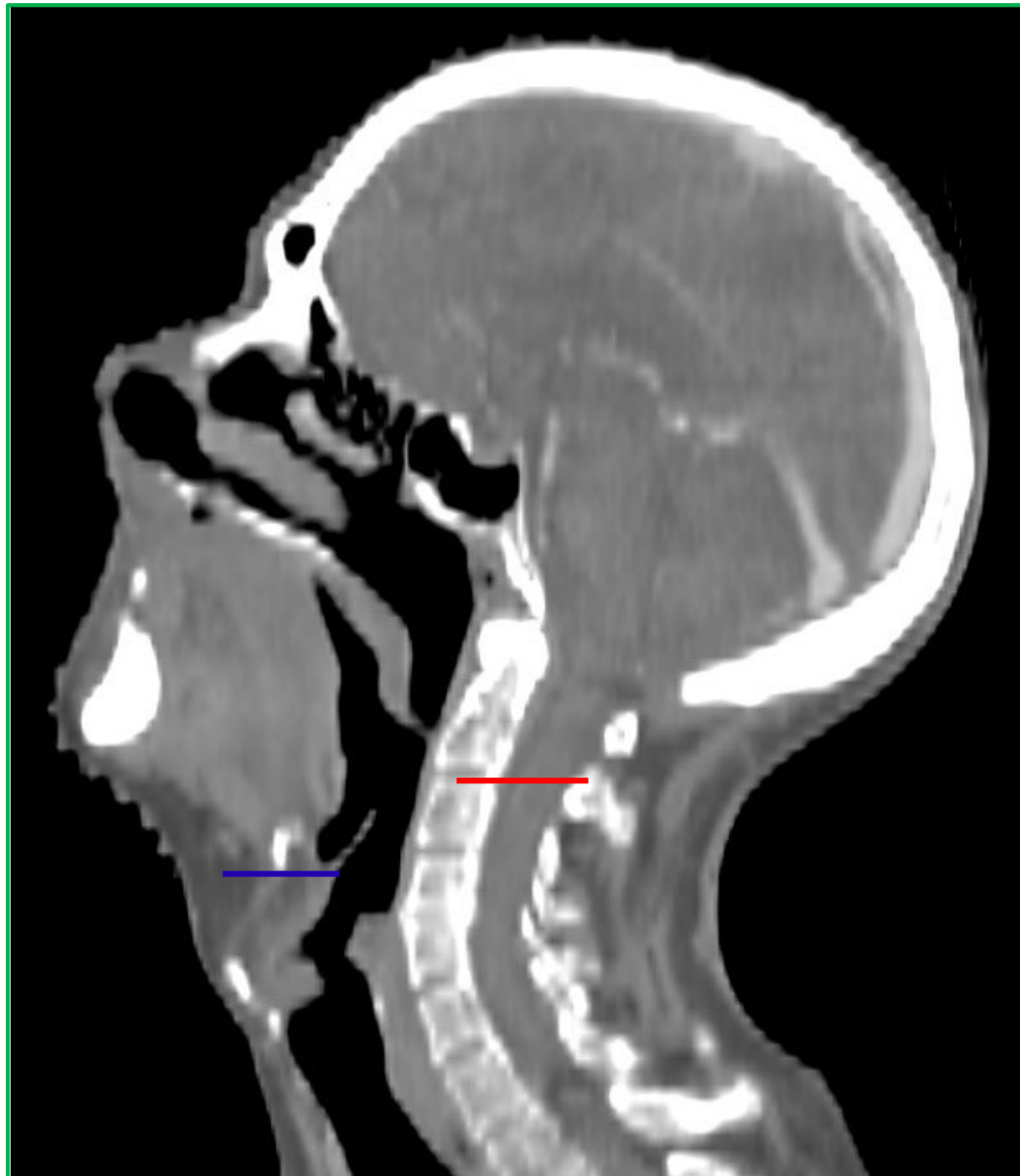


## Superior Constrictor - Caudal Boundary





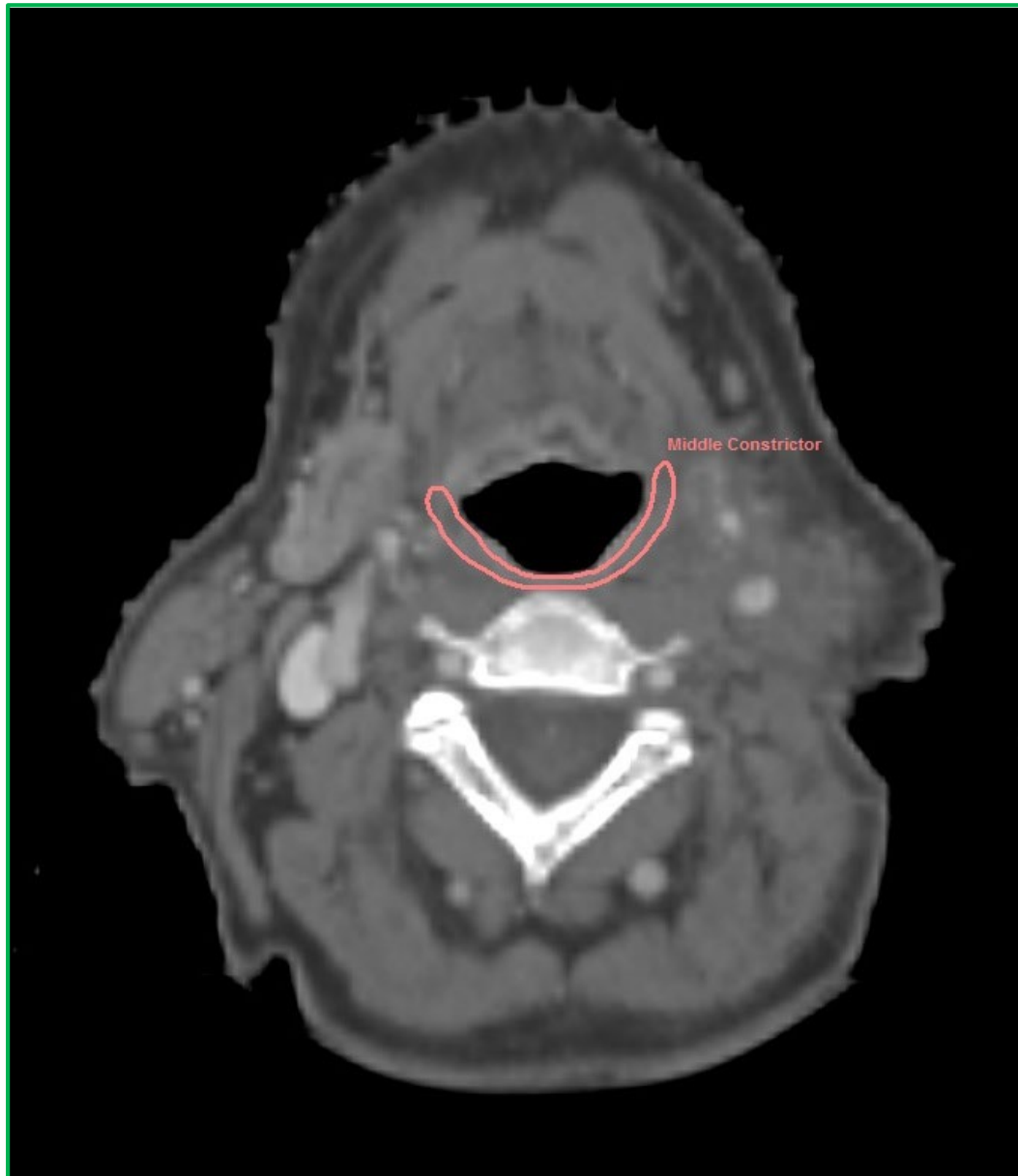
## Middle Constrictor - Cranial & Caudal Boundary on Sagittal Slice



Red line - Upper edge of C3

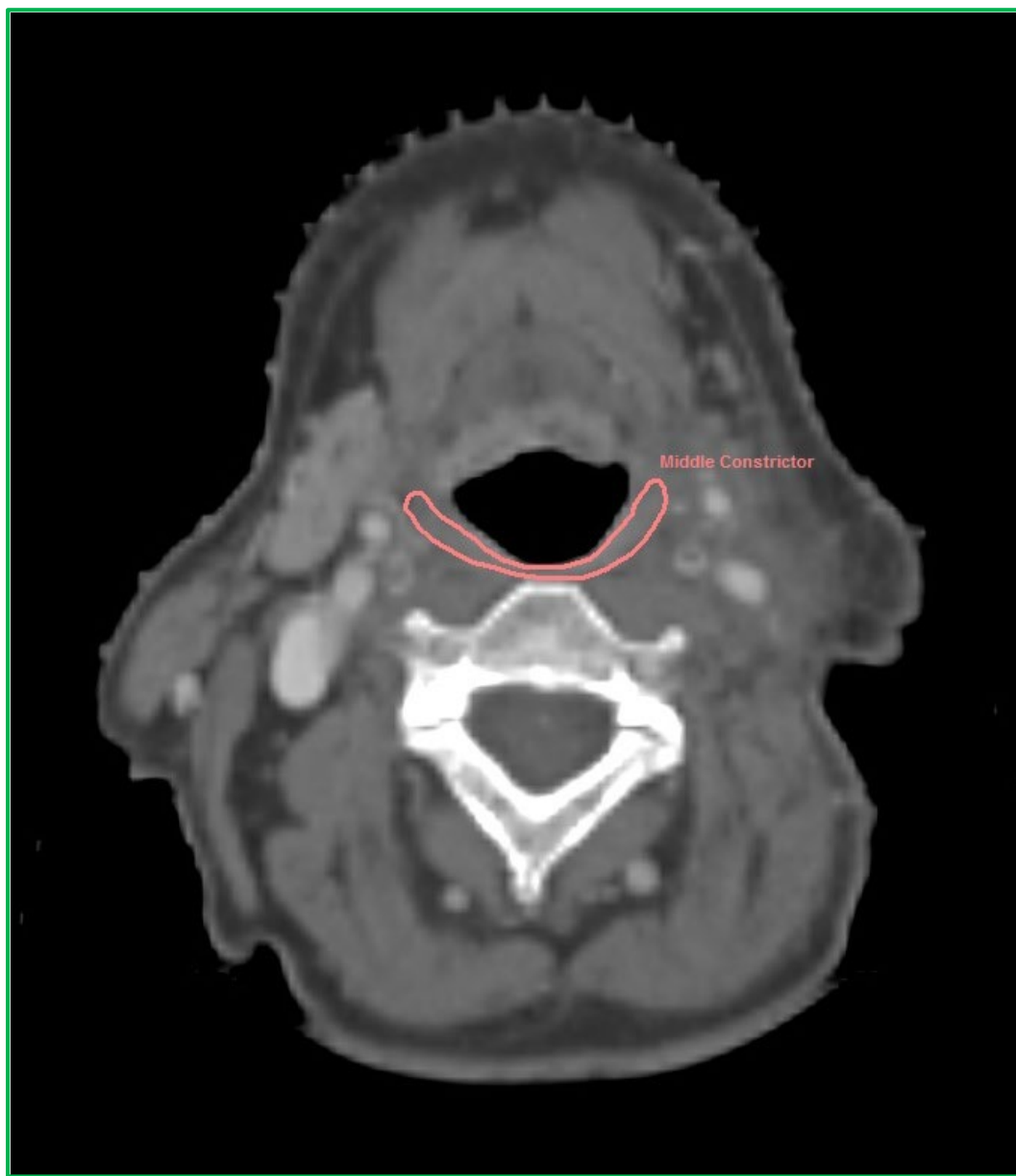
Blue line - Caudal edge of hyoid

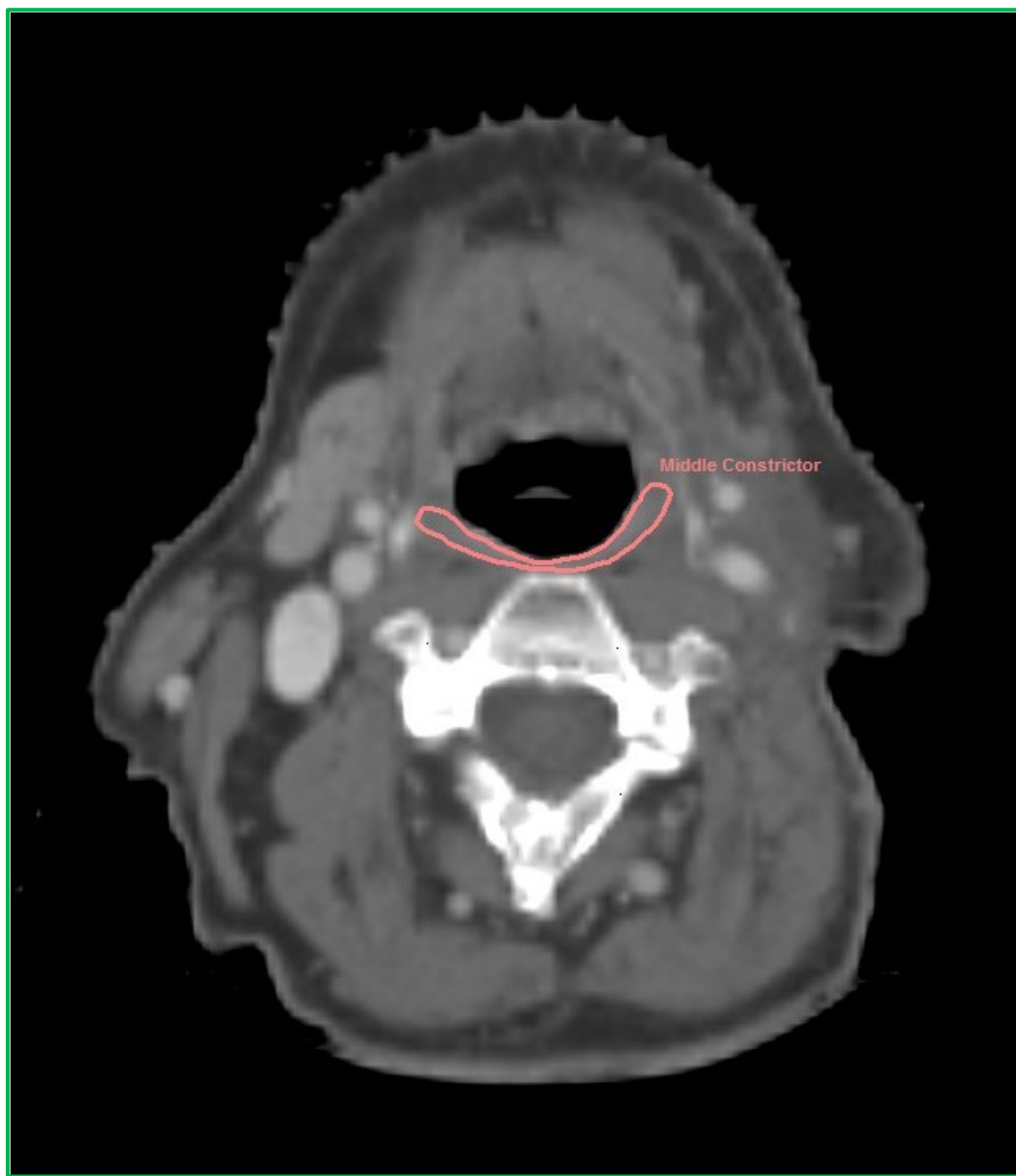
## Middle Constrictor - Cranial Boundary

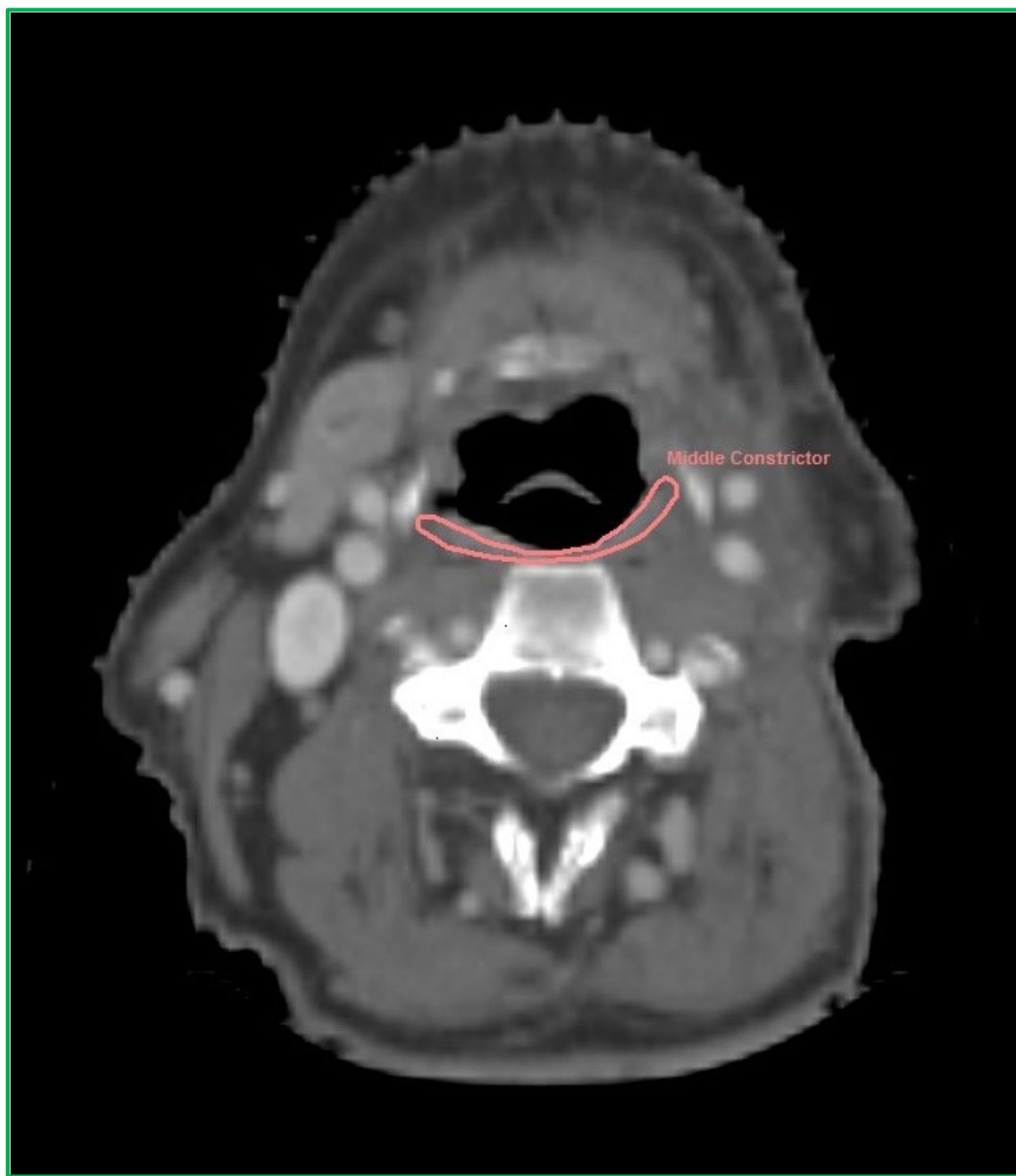


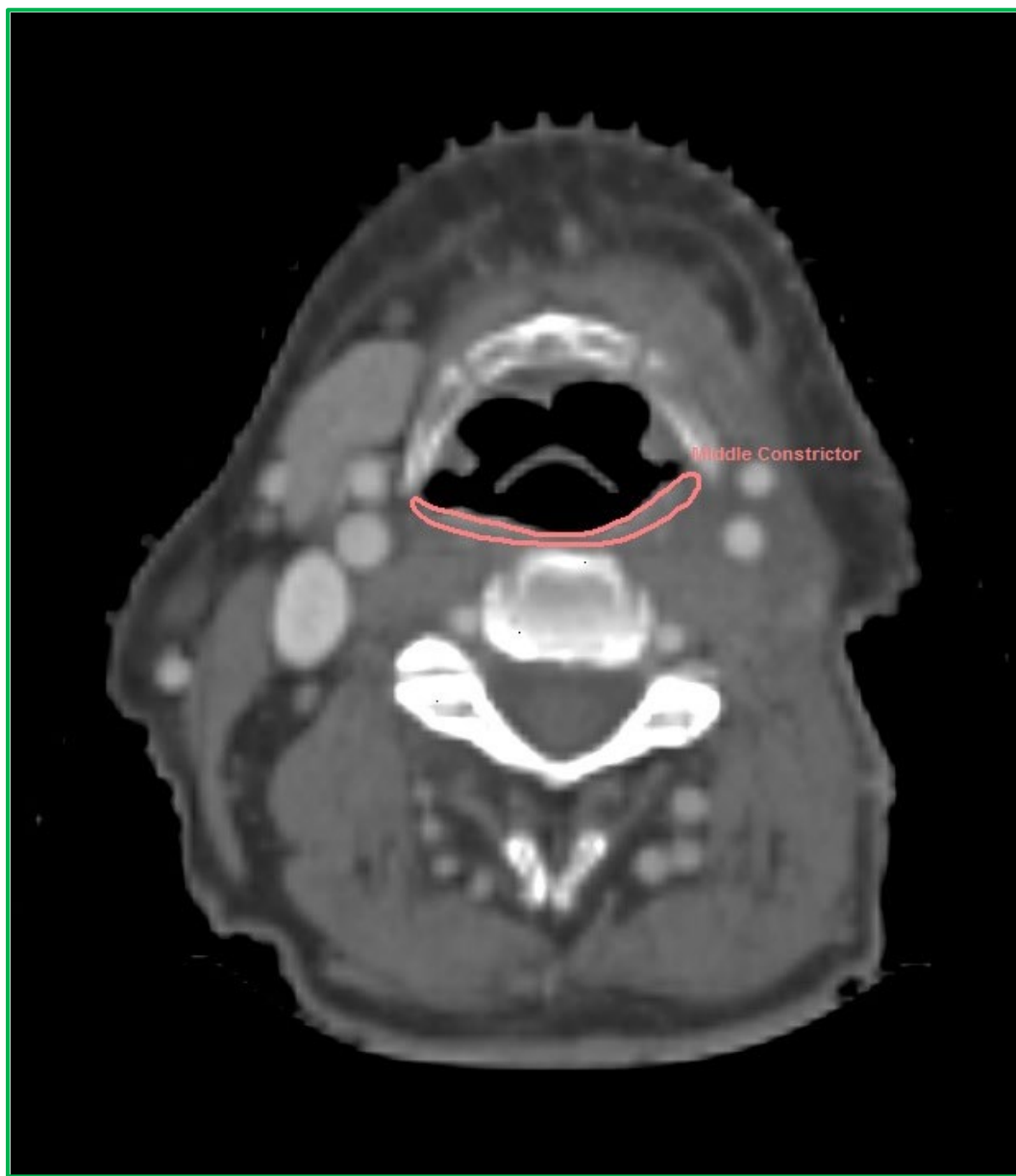
<b>Cranial</b>	<b>Upper edge of C3</b>
<b>Caudal</b>	<b>Caudal edge of hyoid bone</b>
<b>Anterior</b>	<b>Tongue base/ hyoid bone</b>
<b>Posterior</b>	<b>Prevertebral muscle</b>
<b>Lateral</b>	<b>Greater horn of hyoid</b>
<b>Medial</b>	<b>Pharyngeal lumen</b>

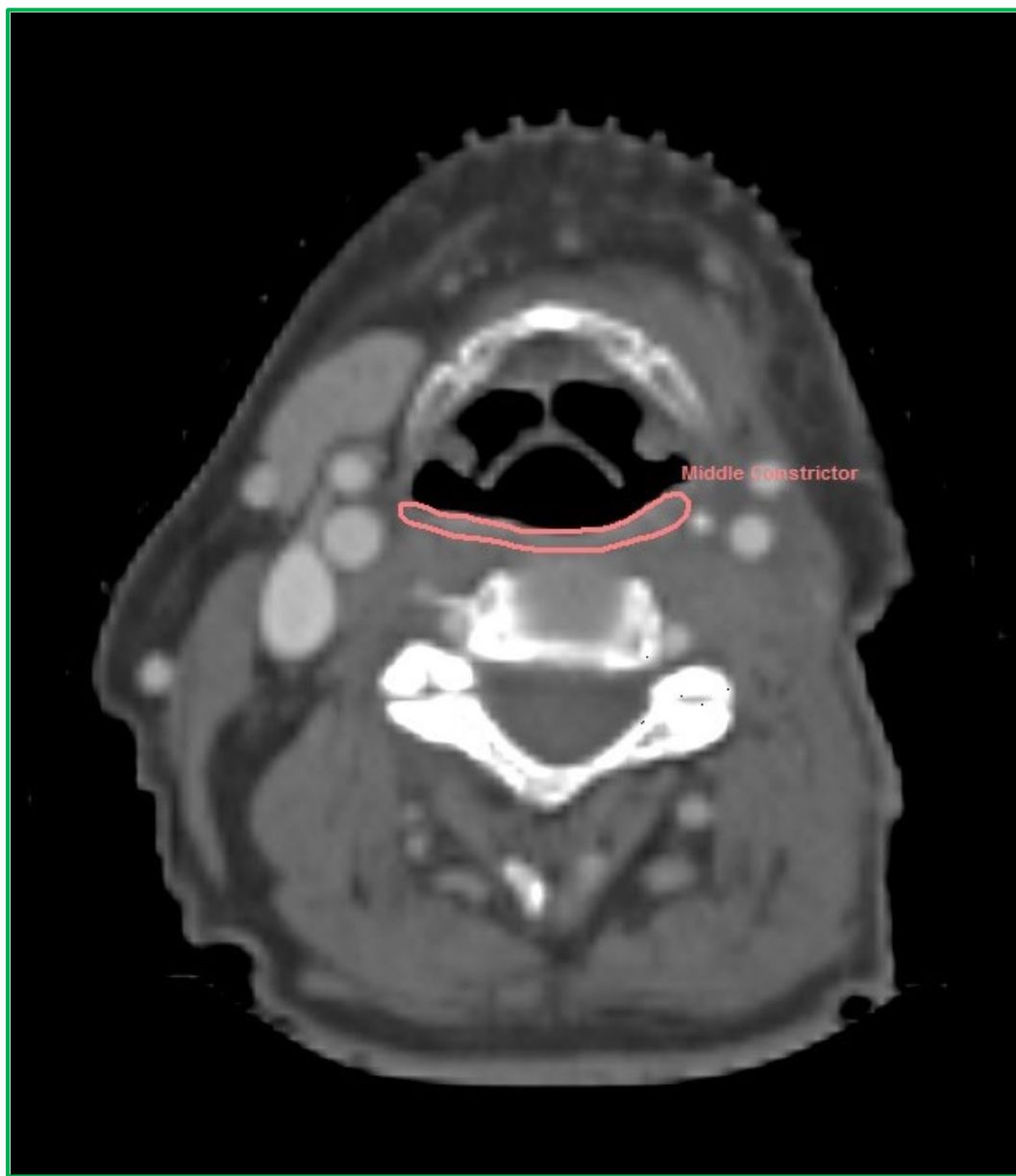
### Middle Constrictor Boundaries



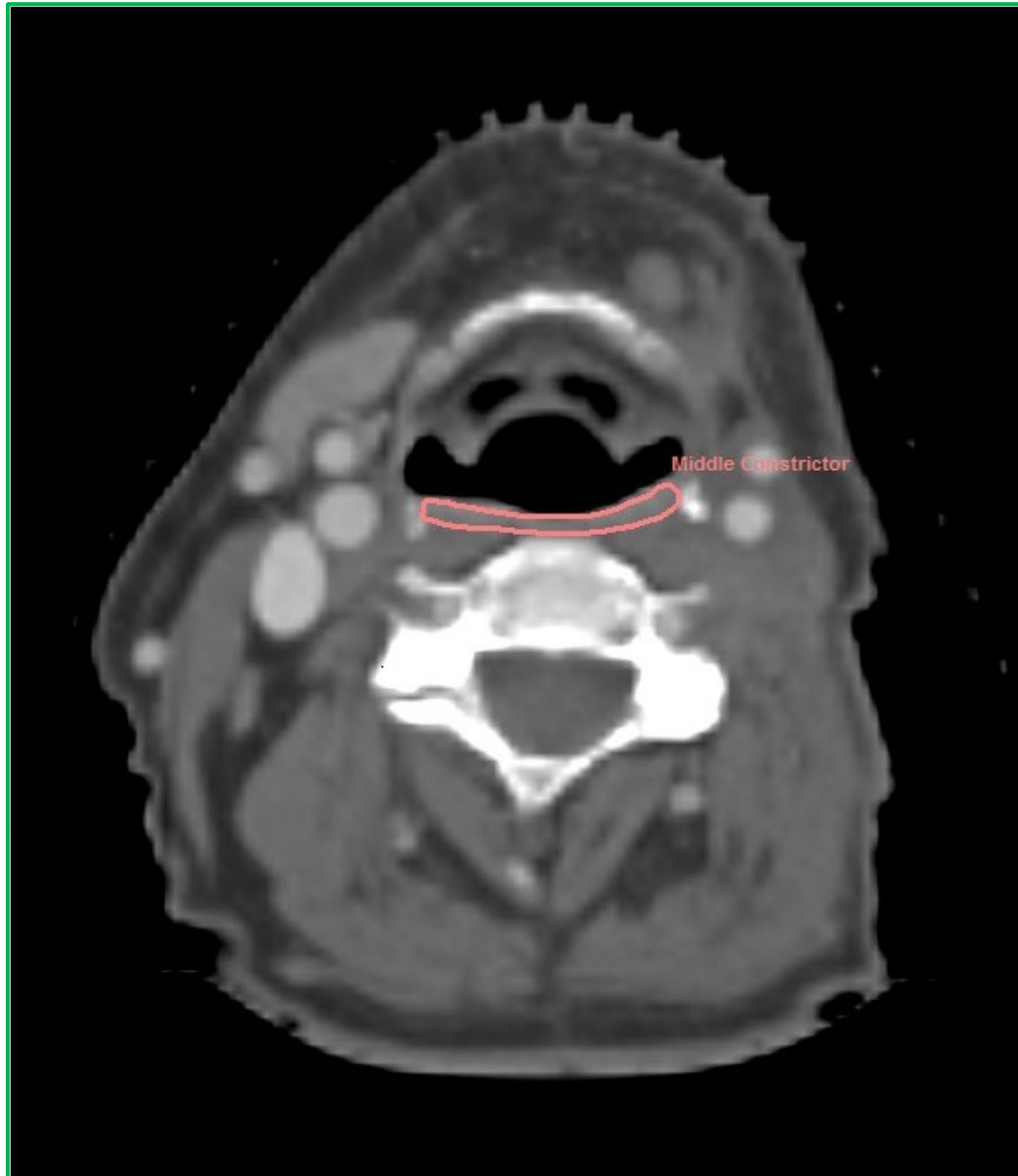






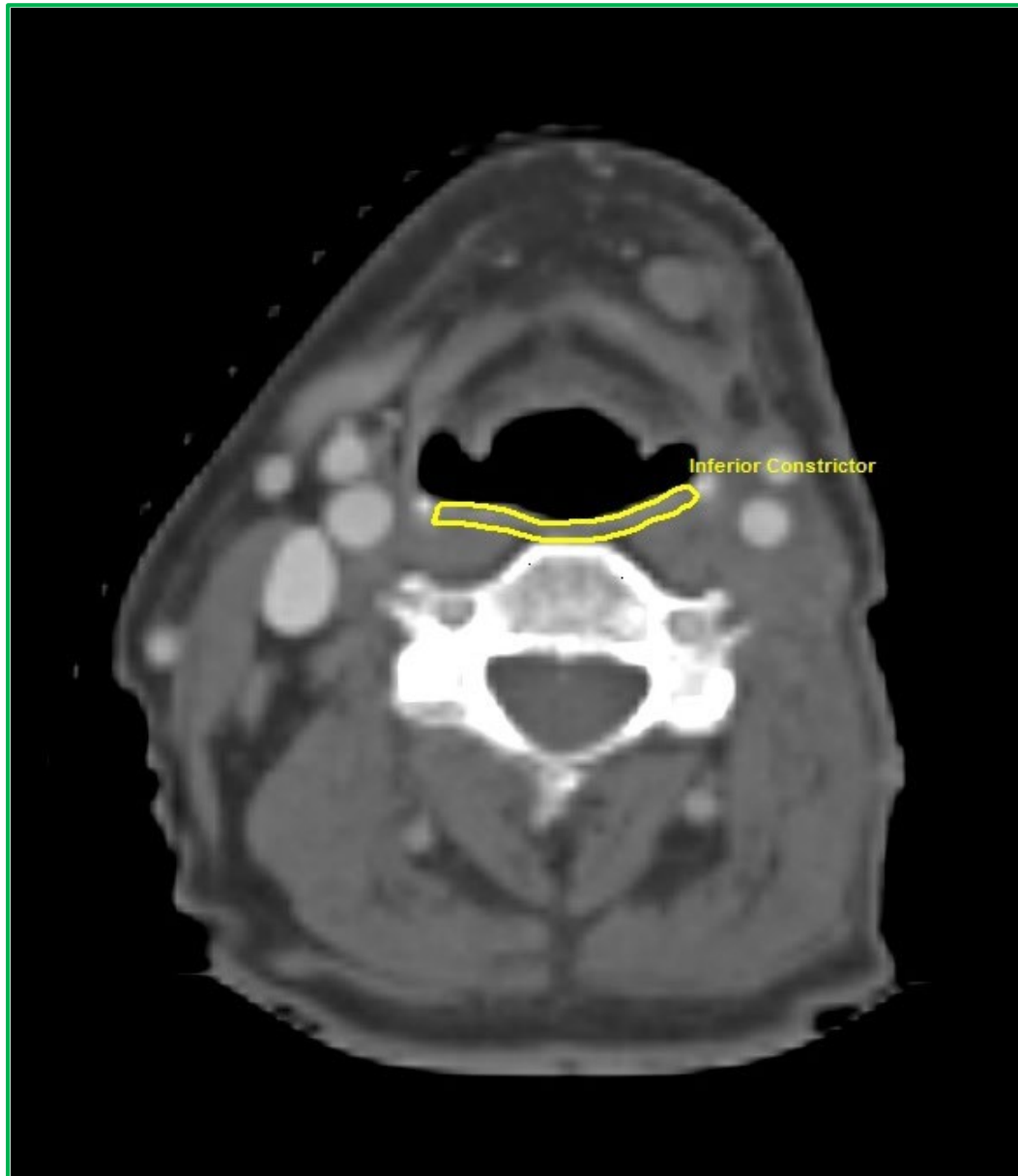


## Middle Constrictor - Caudal Boundary



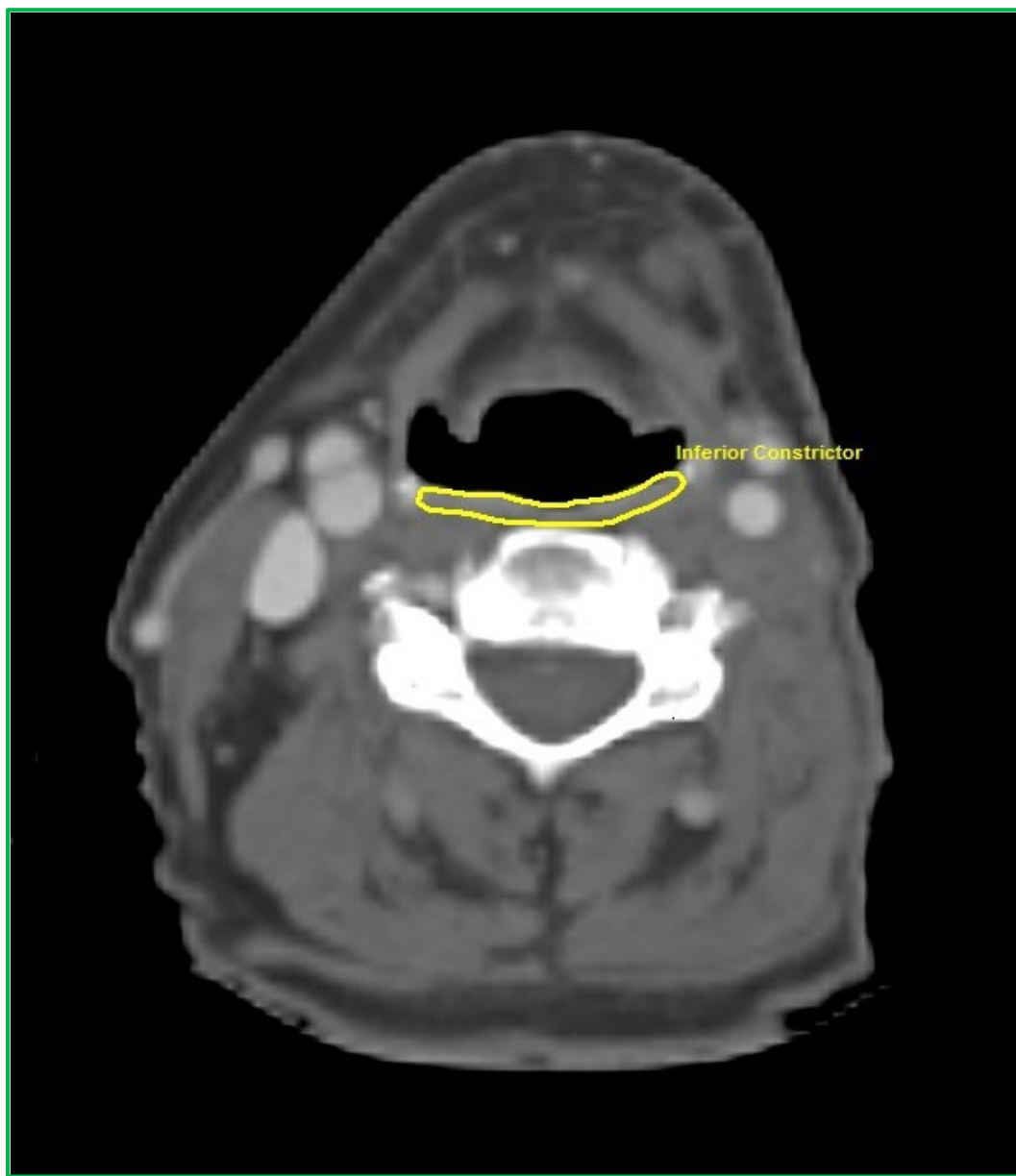


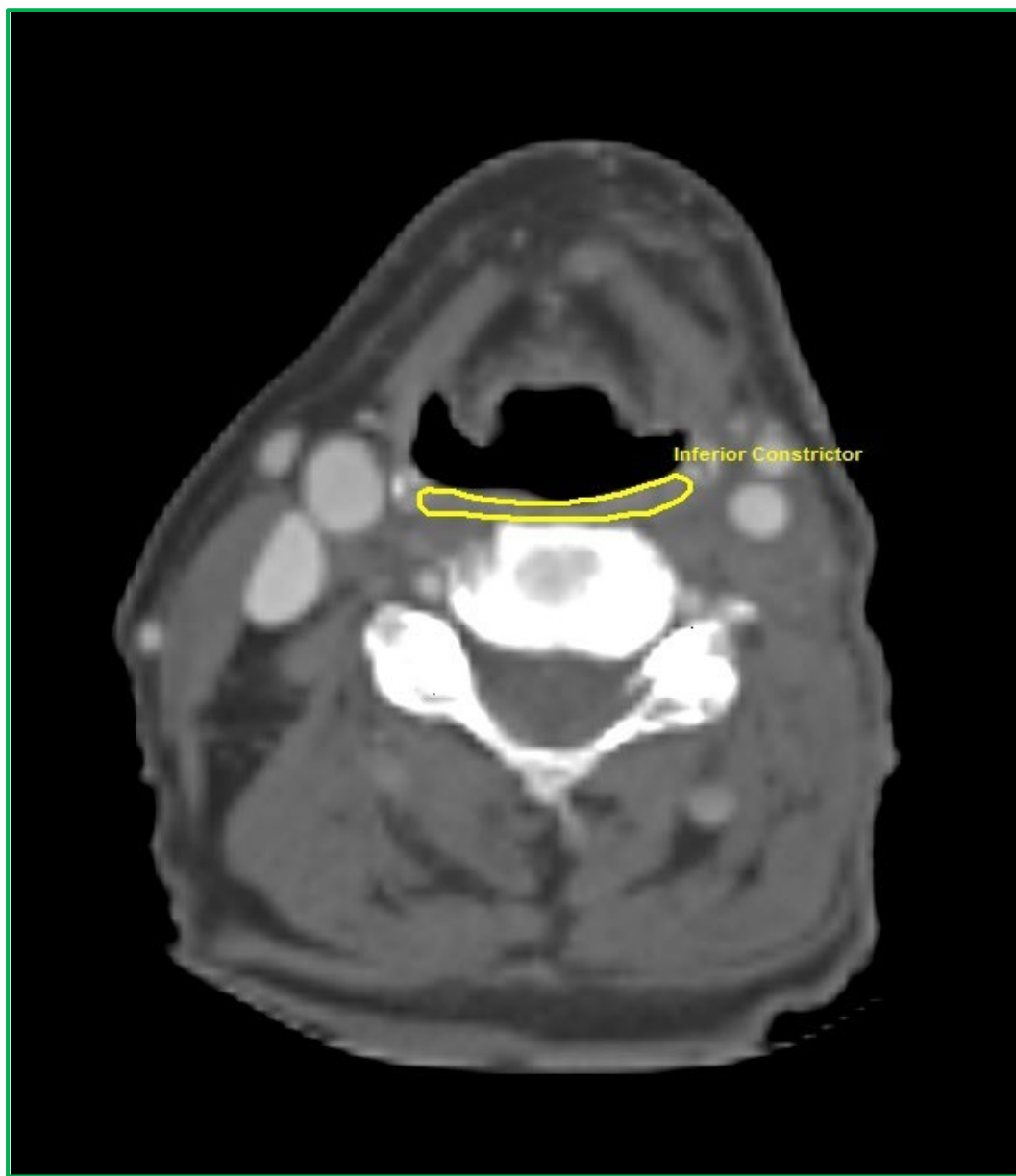
## Inferior Constrictor - Cranial Boundary

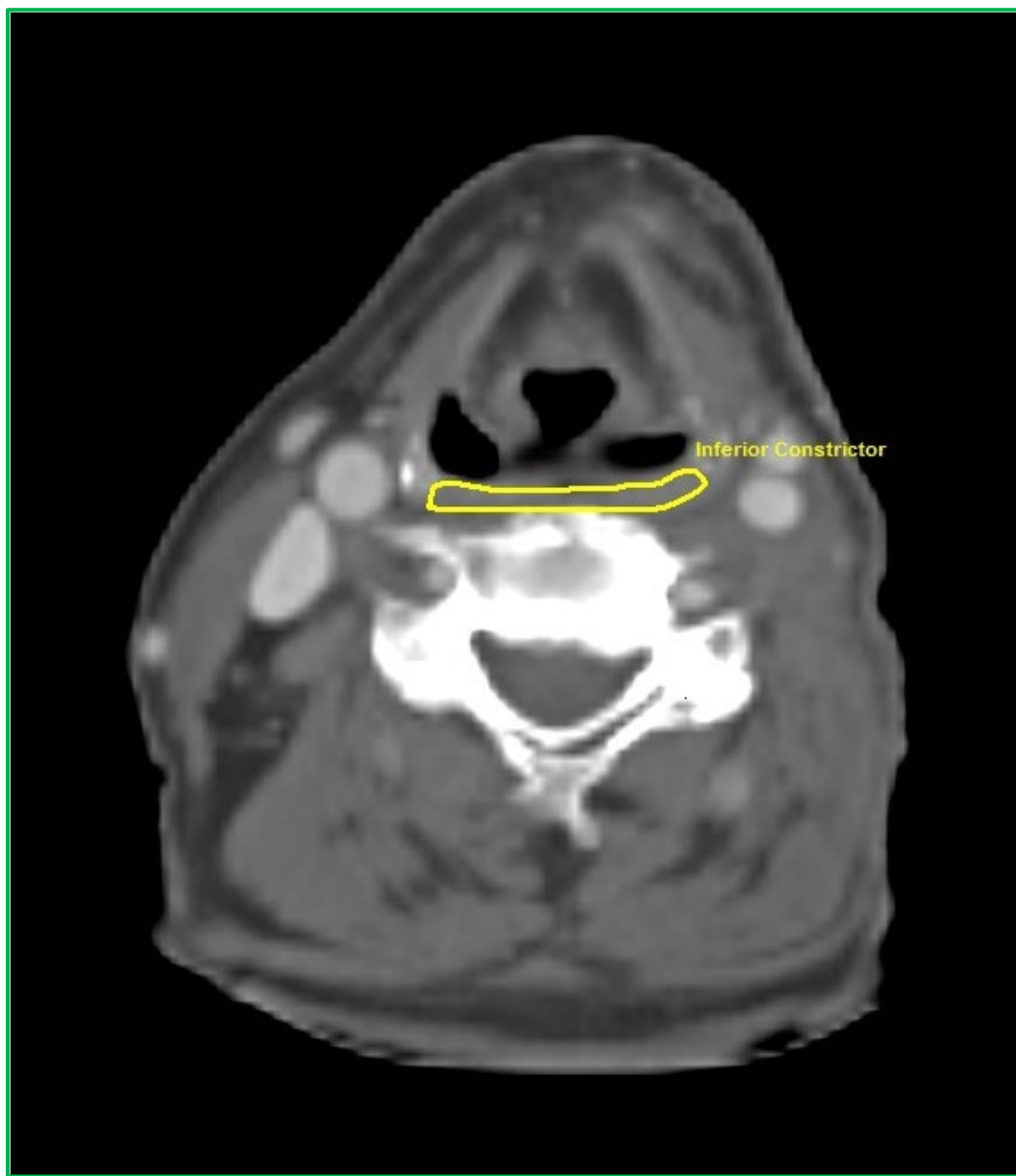


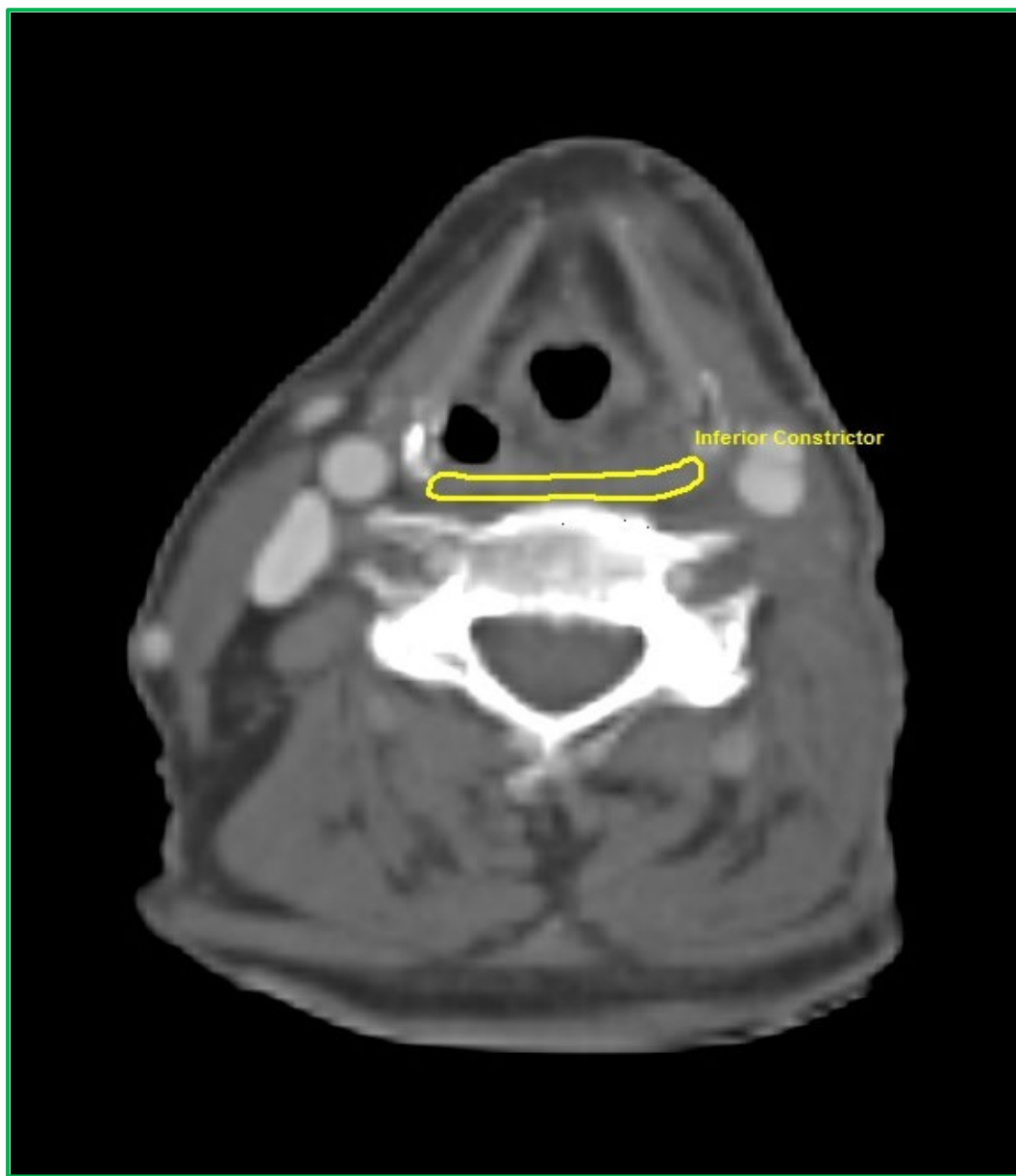
<b>Cranial</b>	<b>First slice caudal to lower edge of hyoid</b>
<b>Caudal</b>	<b>Lower edge of arytenoids</b>
<b>Anterior</b>	<b>Soft tissue of supraglottis/ glottis</b>
<b>Posterior</b>	<b>Prevertebral muscle</b>
<b>Lateral</b>	<b>Superior horn of Thyroid cartilage</b>

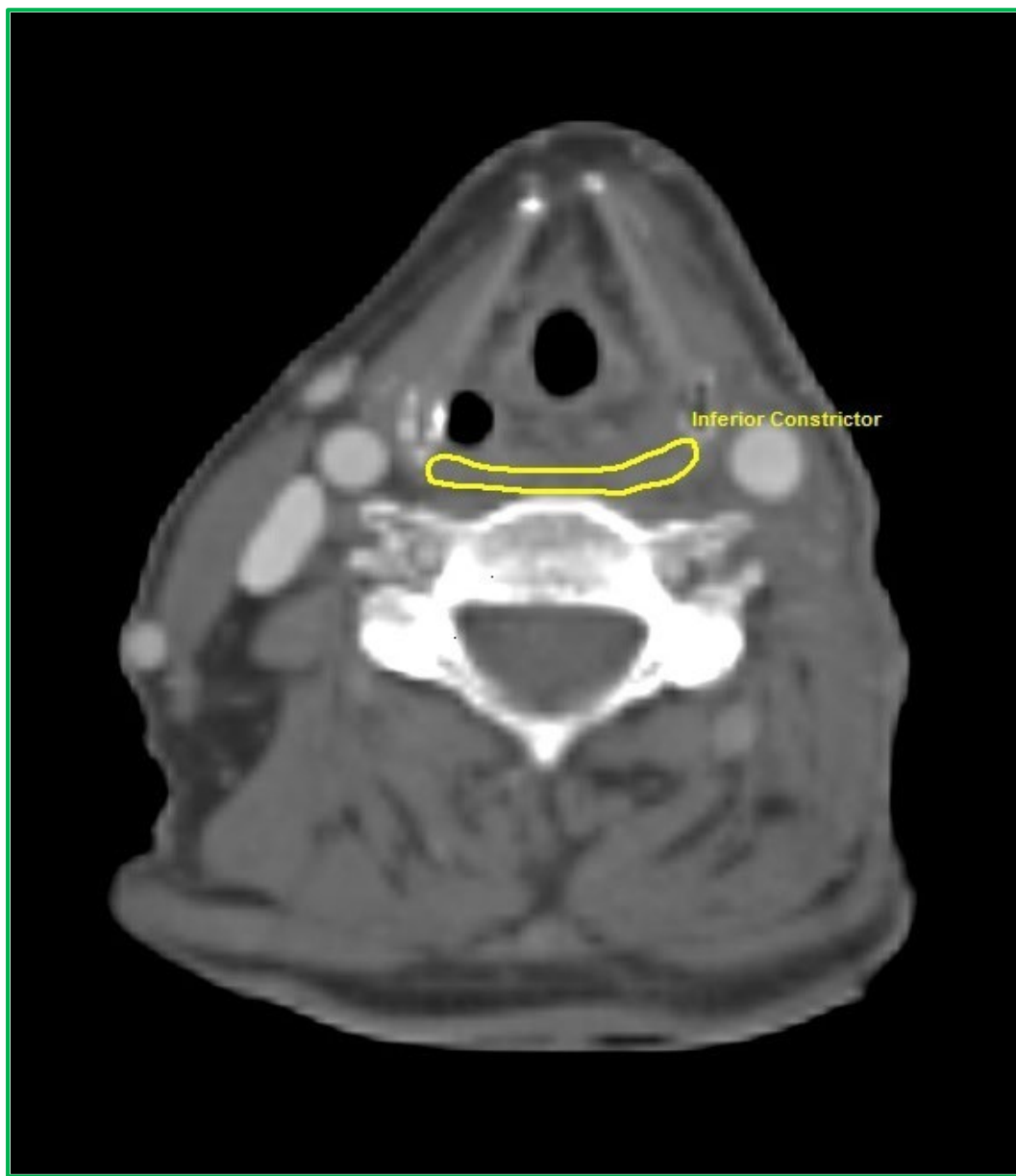
### Inferior Constrictor Boundaries

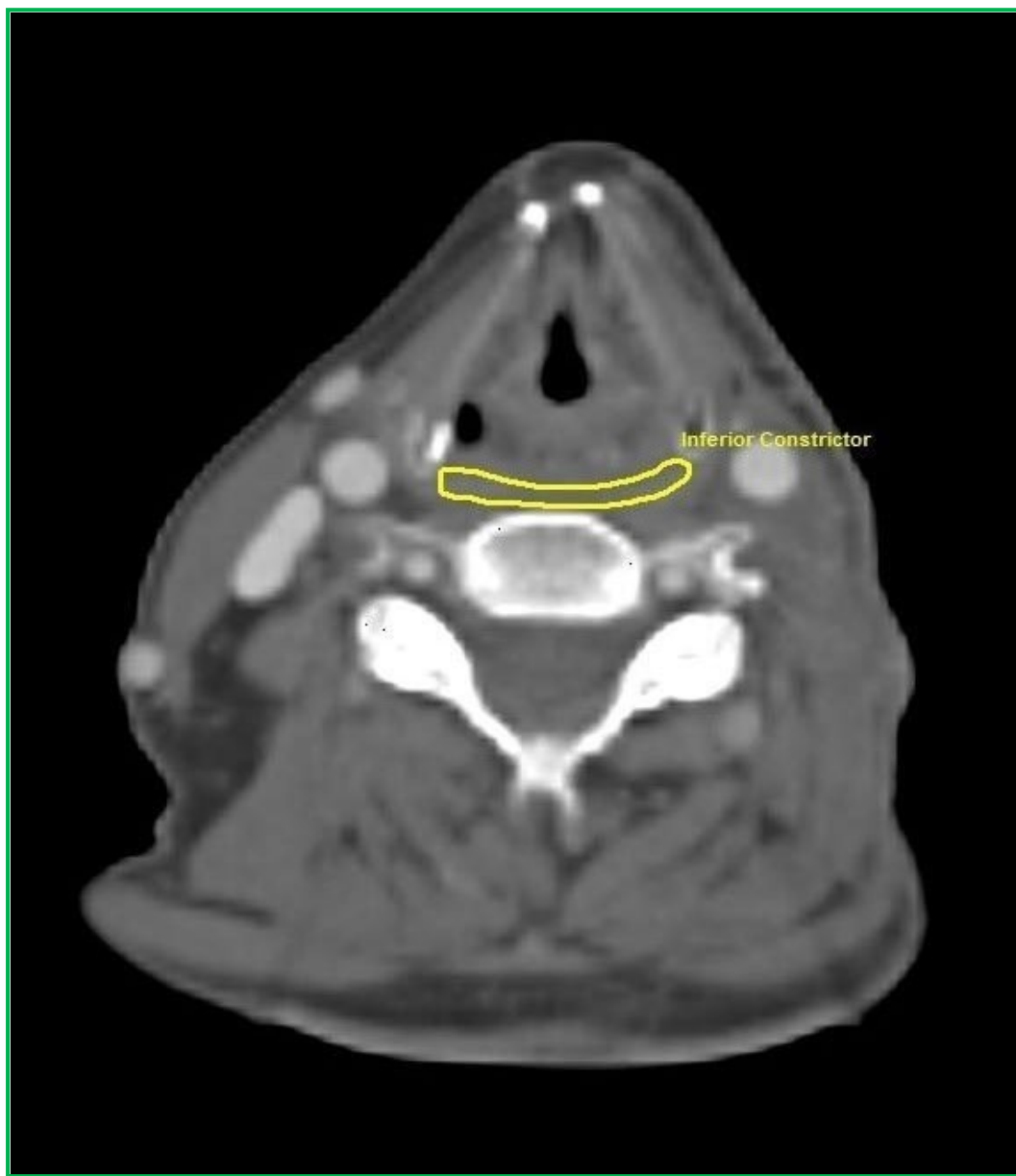


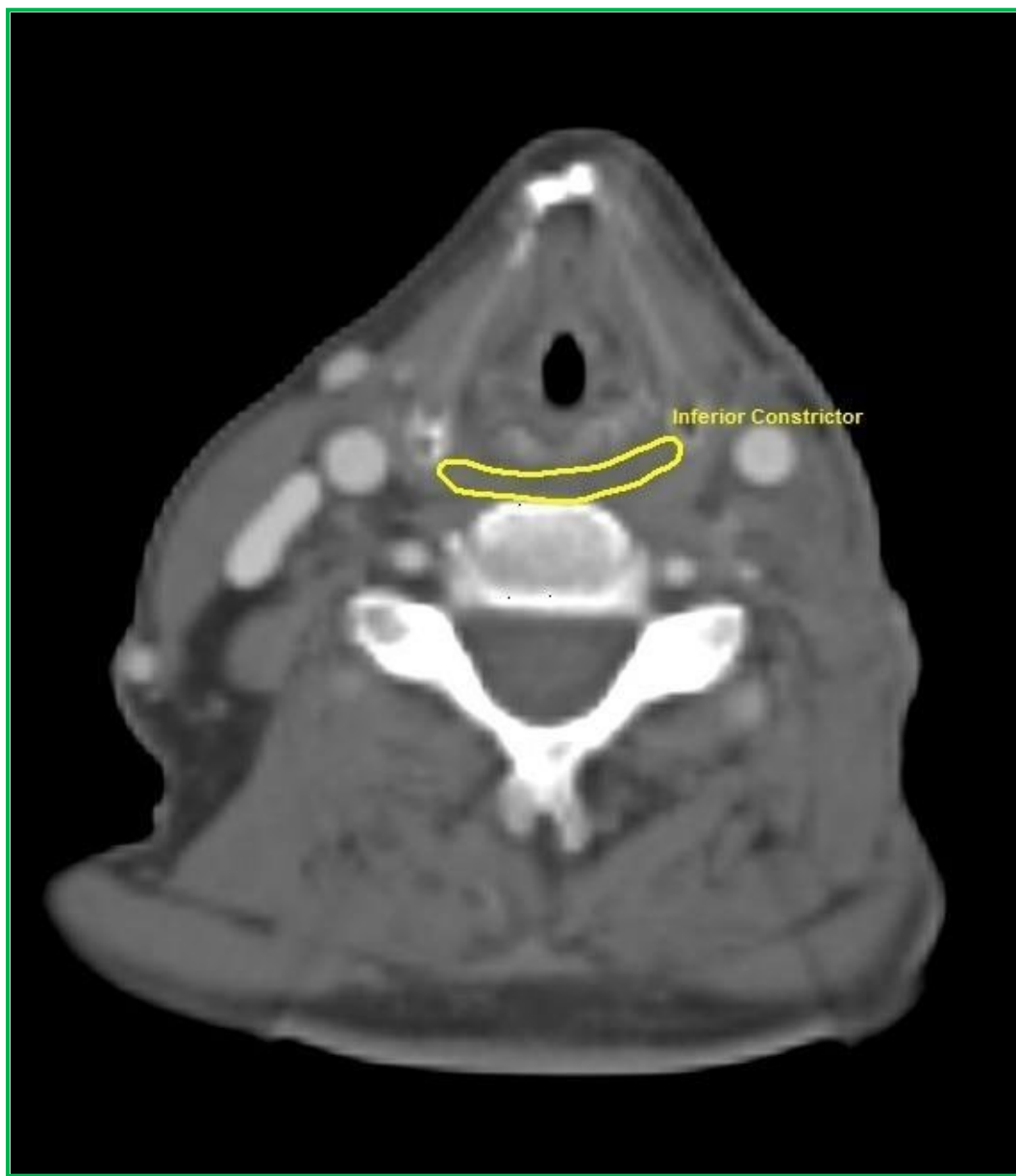






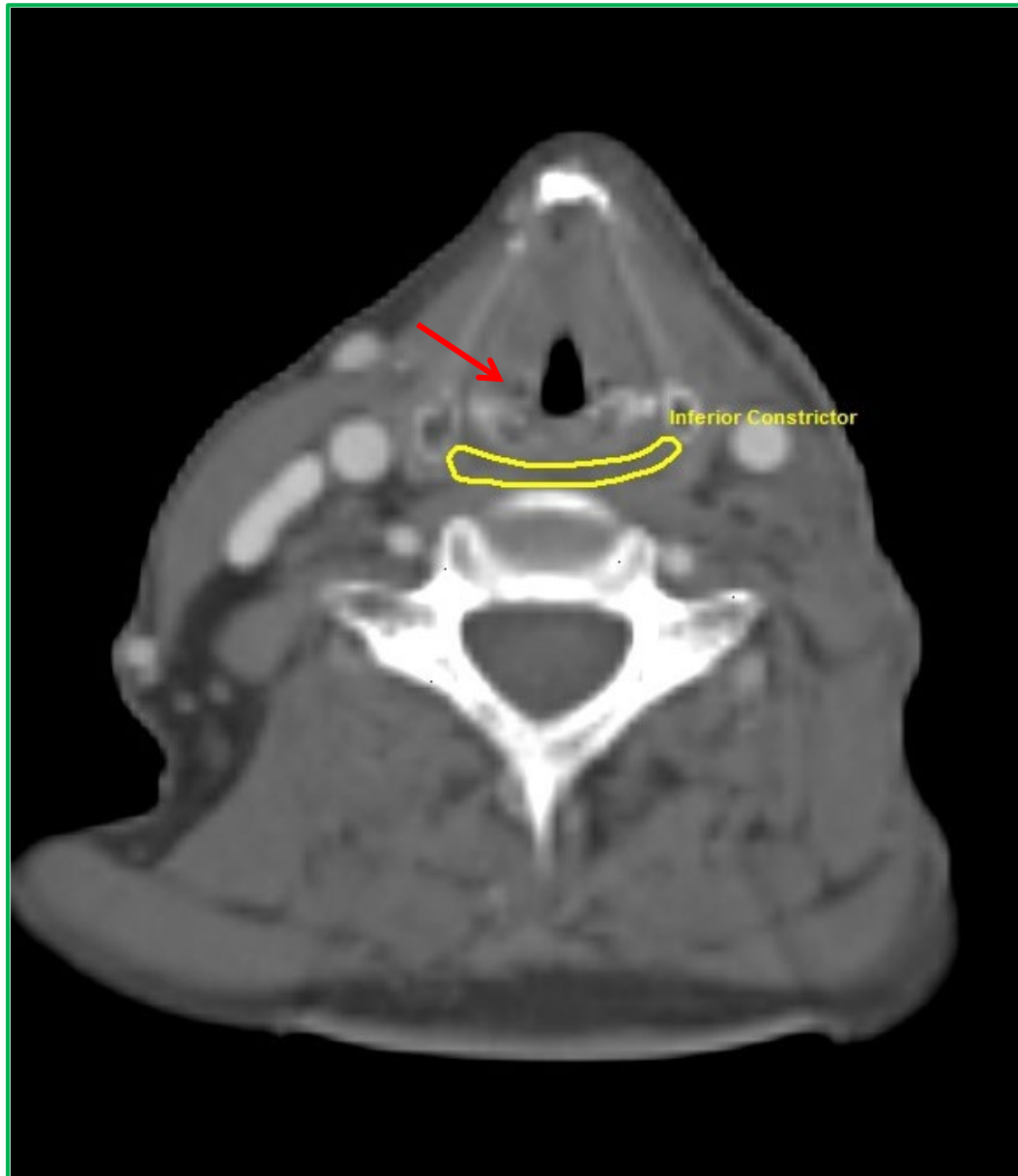






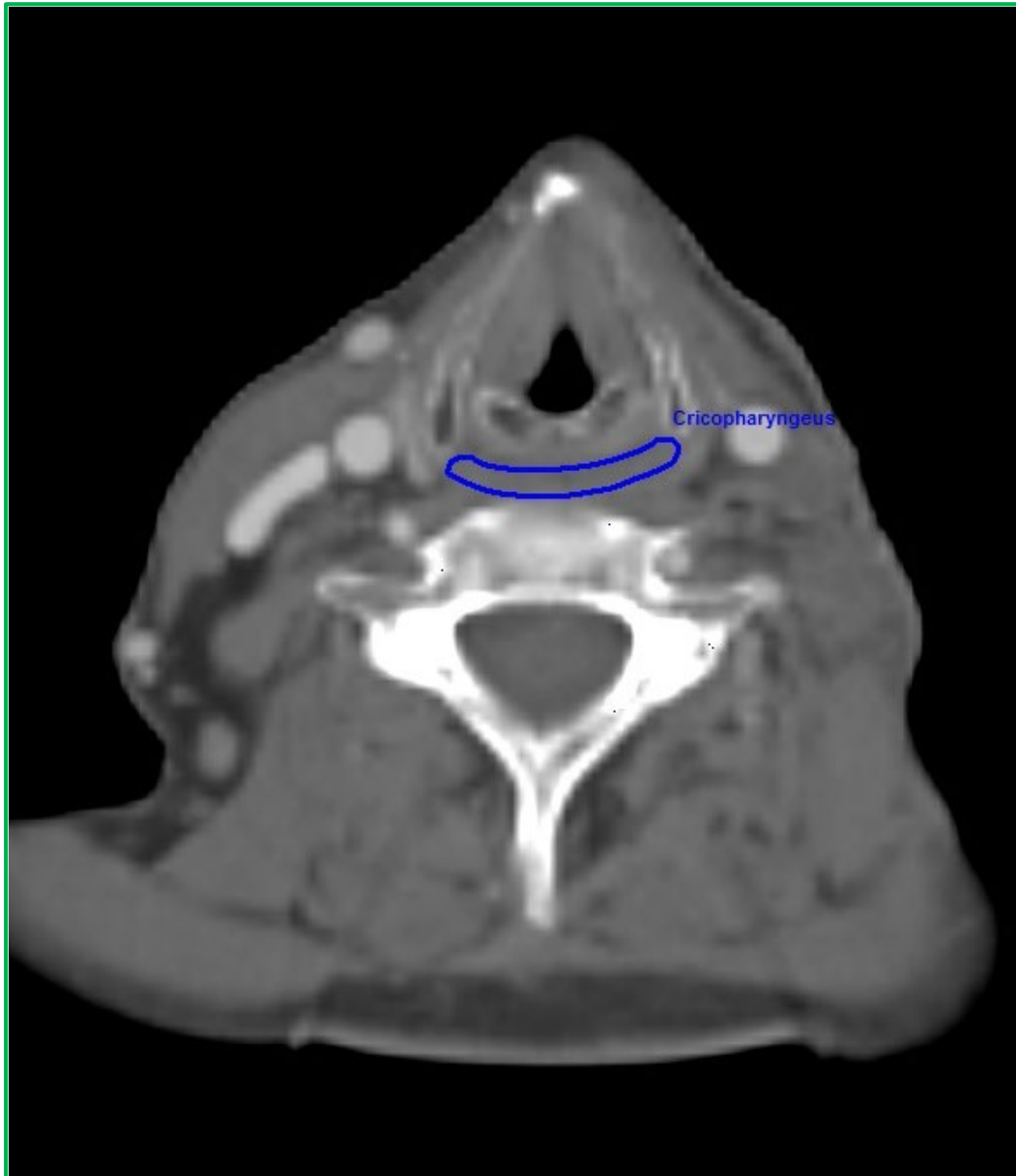


## Inferior Constrictor - Caudal Boundary



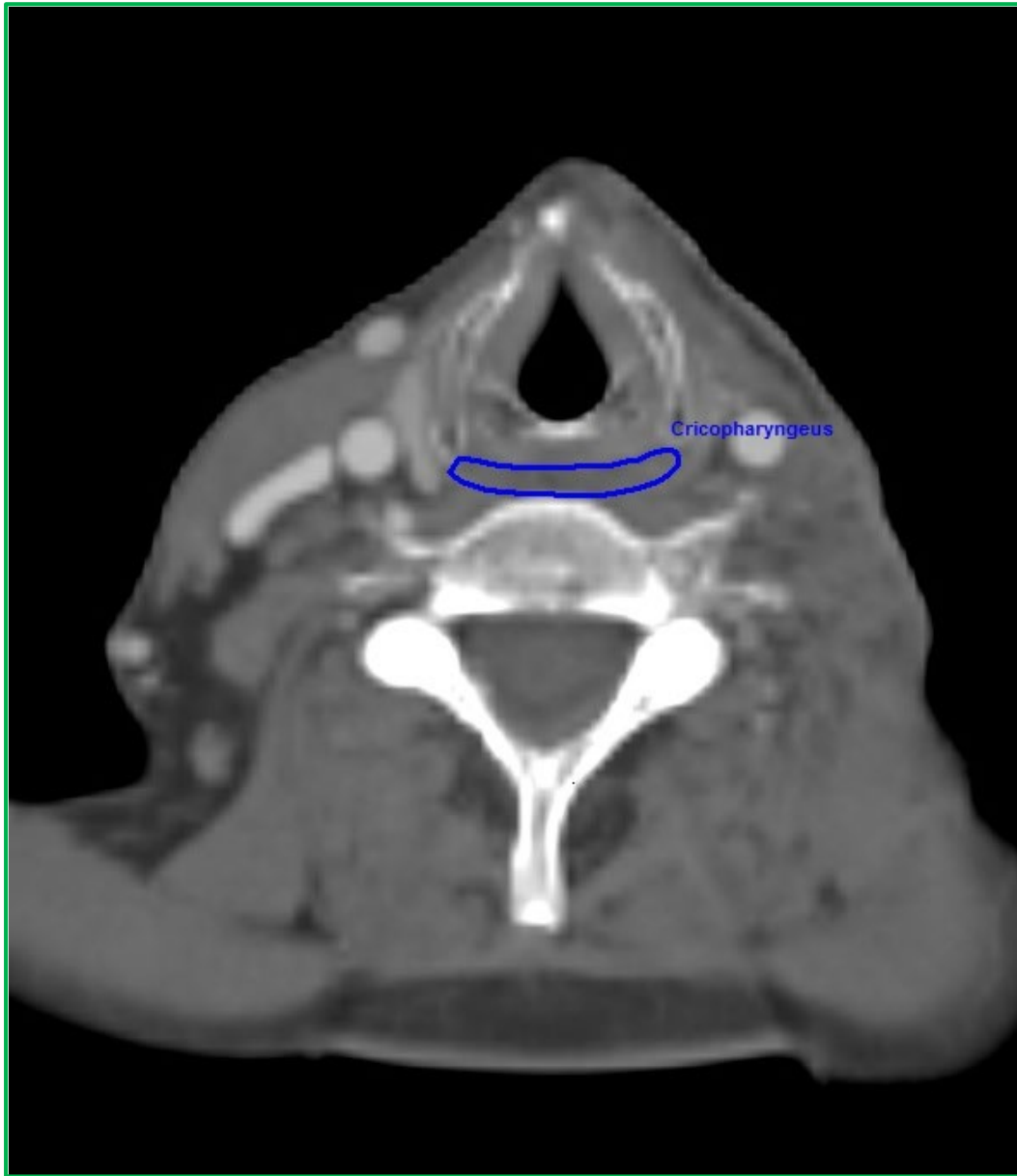
Red arrow - Lower edge of arytenoid

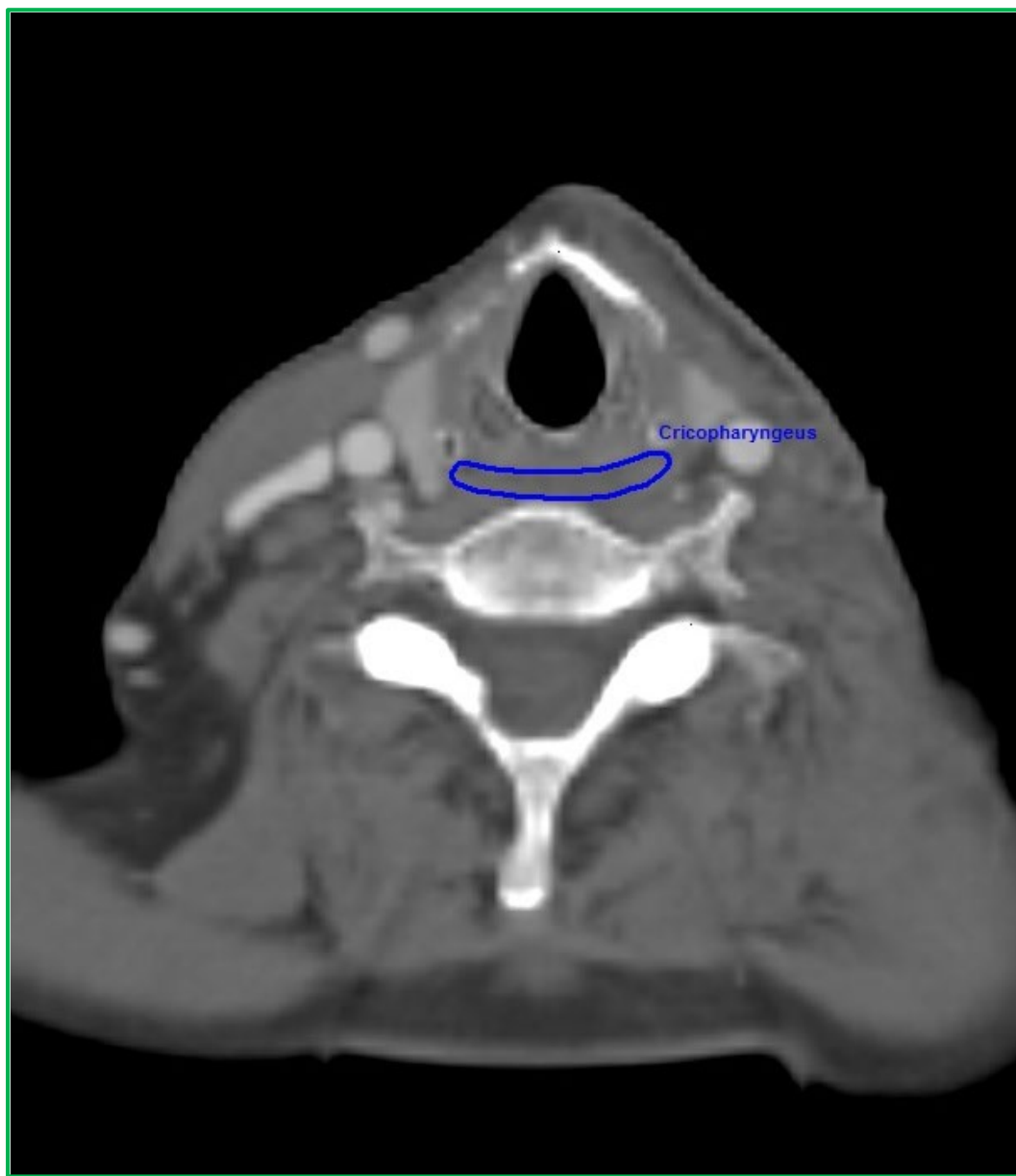
# Cricopharyngeus - Cranial Boundary

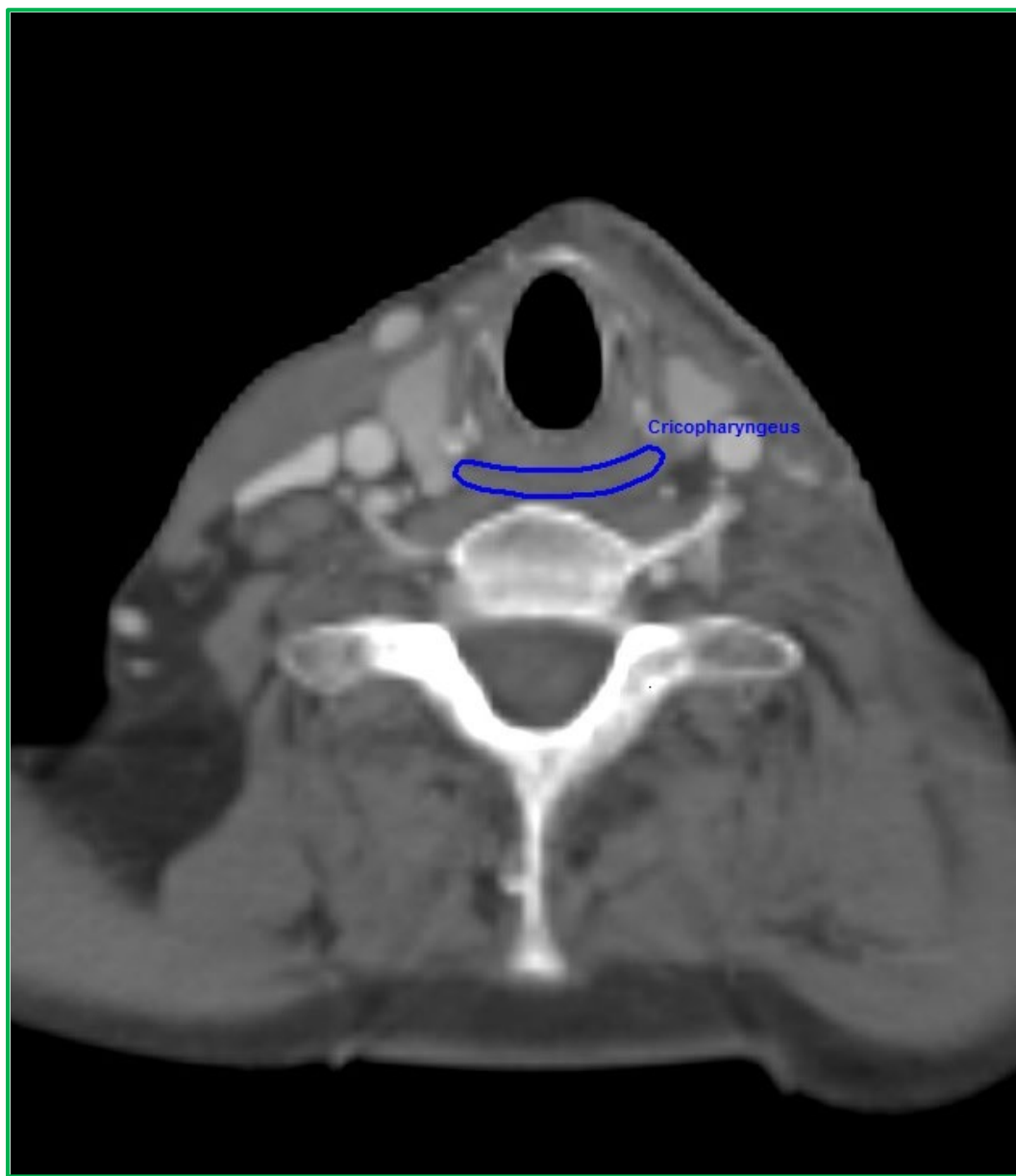


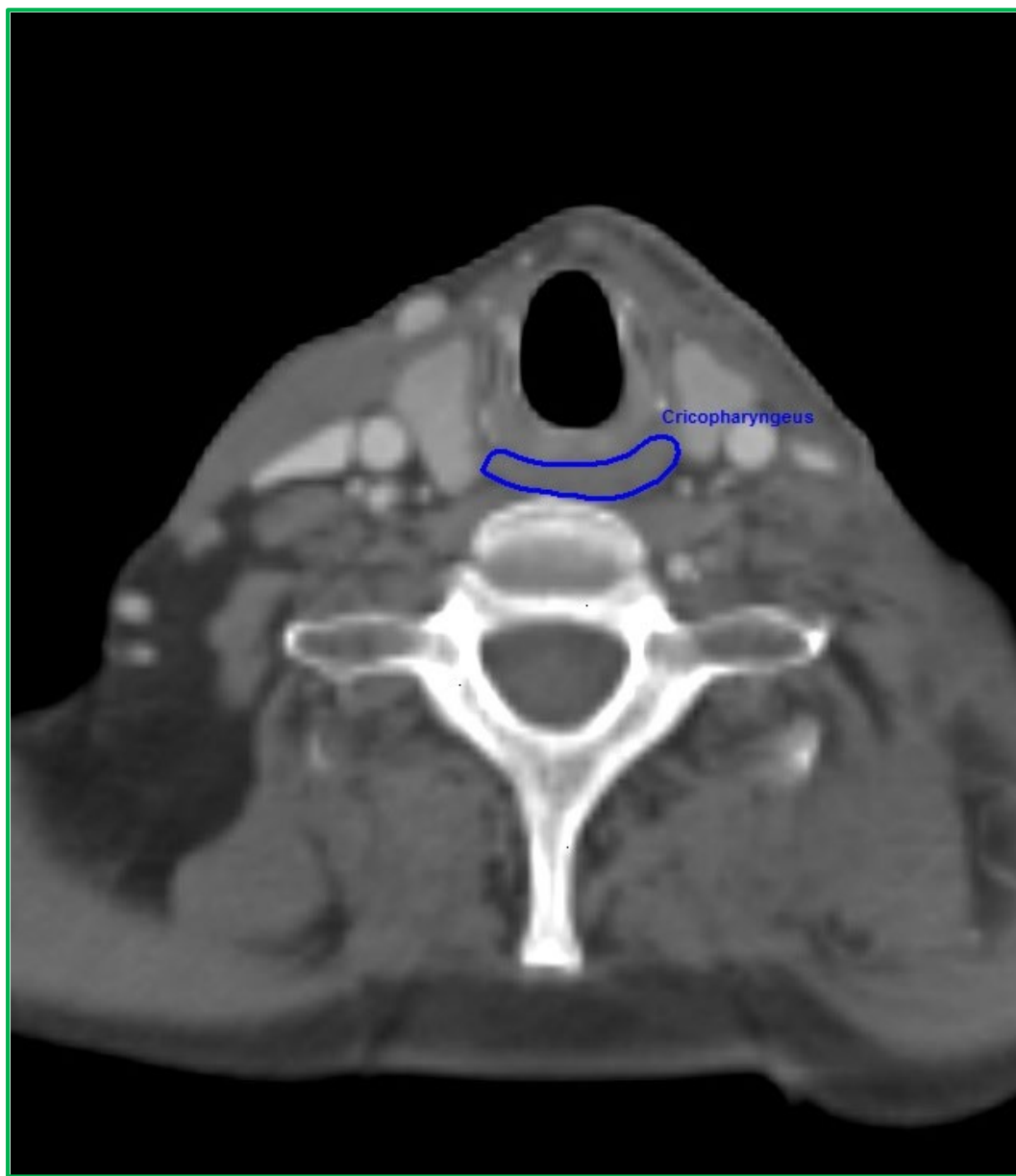
<b>Cranial</b>	<b>First slice caudal to arytenoids</b>
<b>Caudal</b>	<b>Lower edge of cricoid</b>
<b>Anterior</b>	<b>Posterior edge of cricoid</b>
<b>Posterior</b>	<b>Prevertebral muscle</b>
<b>Lateral</b>	<b>Thyroid cartilage/ Fatty tissue/ Thyroid gland</b>

## Cricopharyngeus Boundaries

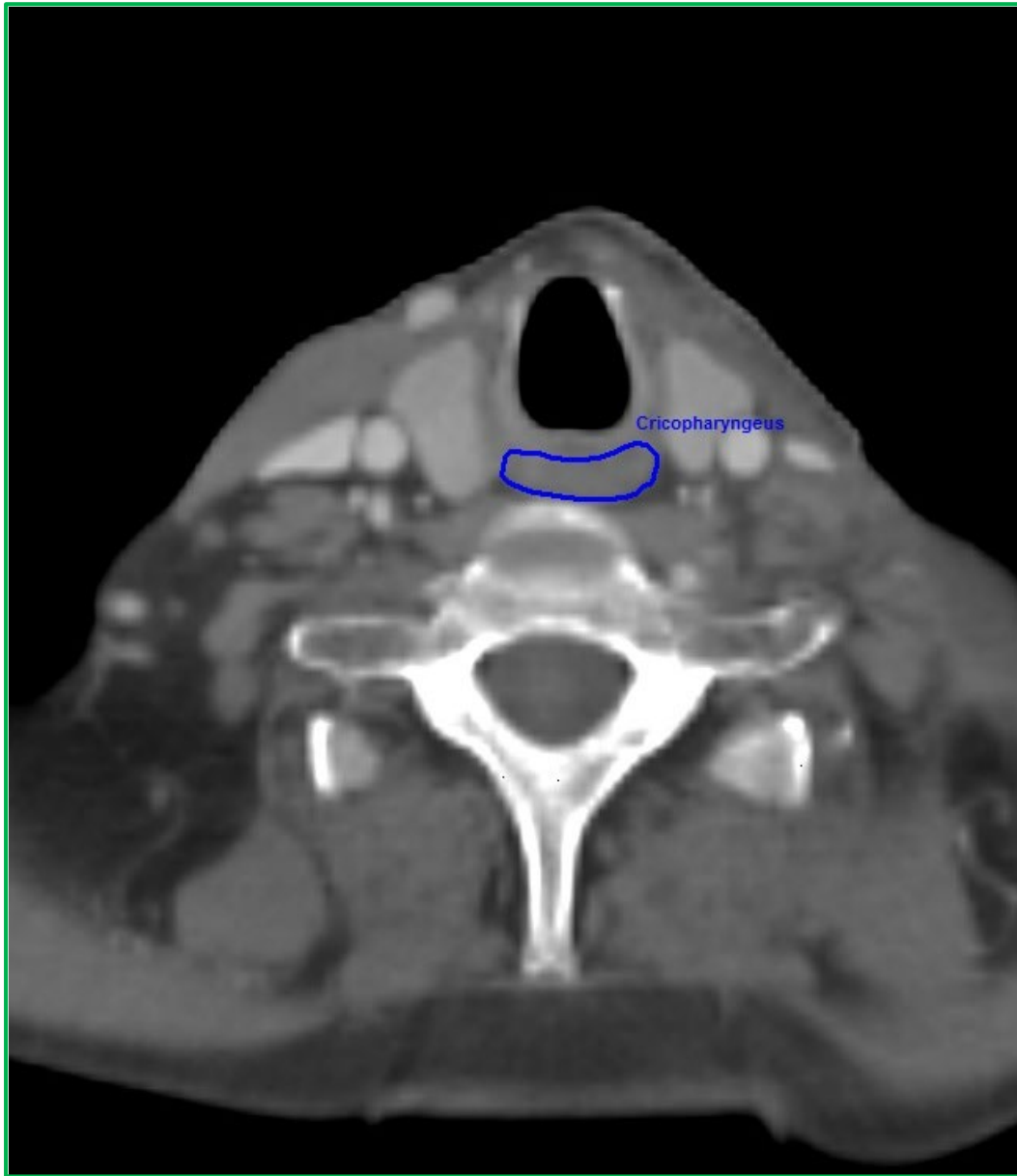




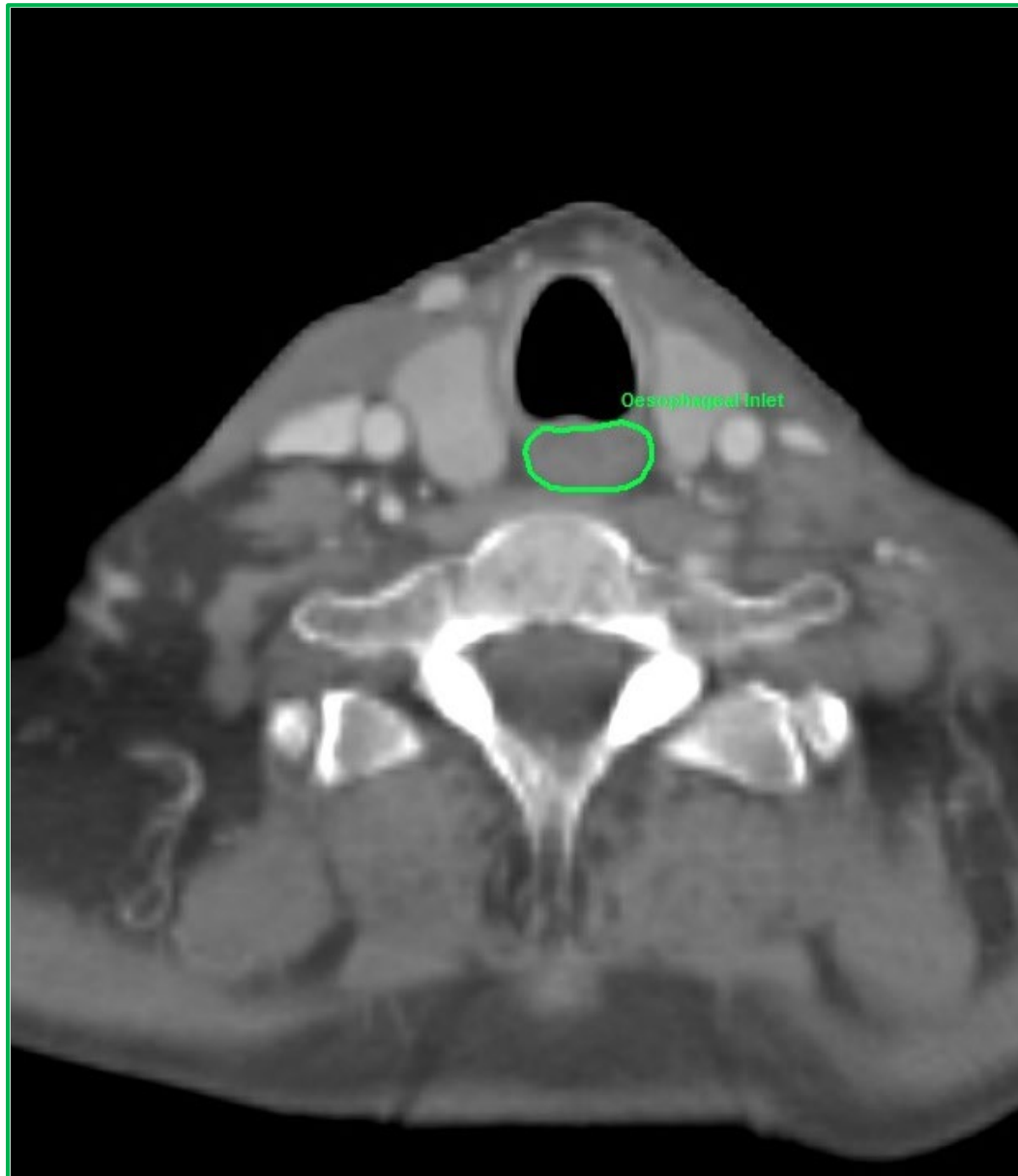




## Cricopharyngeus - Caudal Boundary



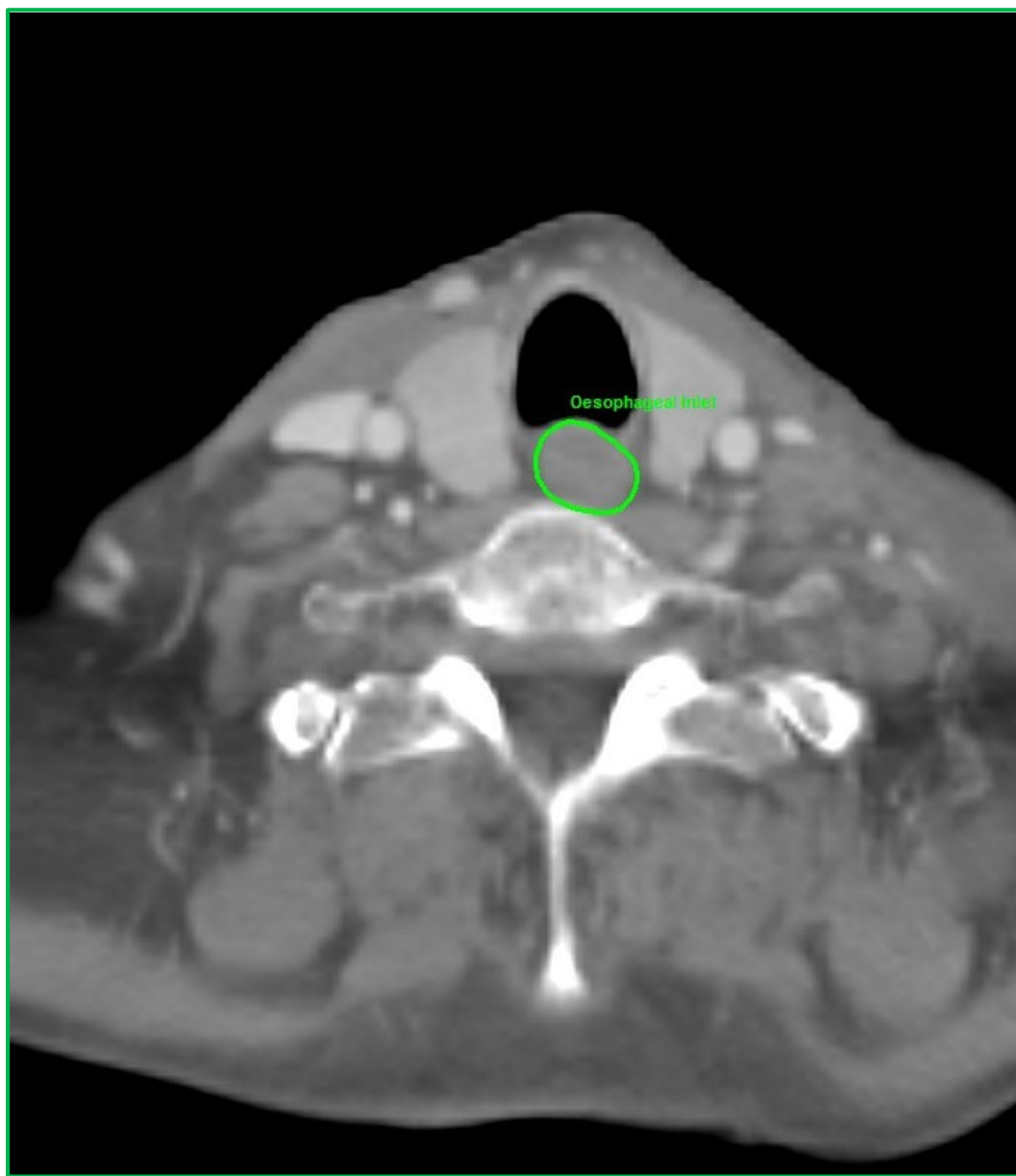
## Oesophageal Inlet - Cranial Boundary

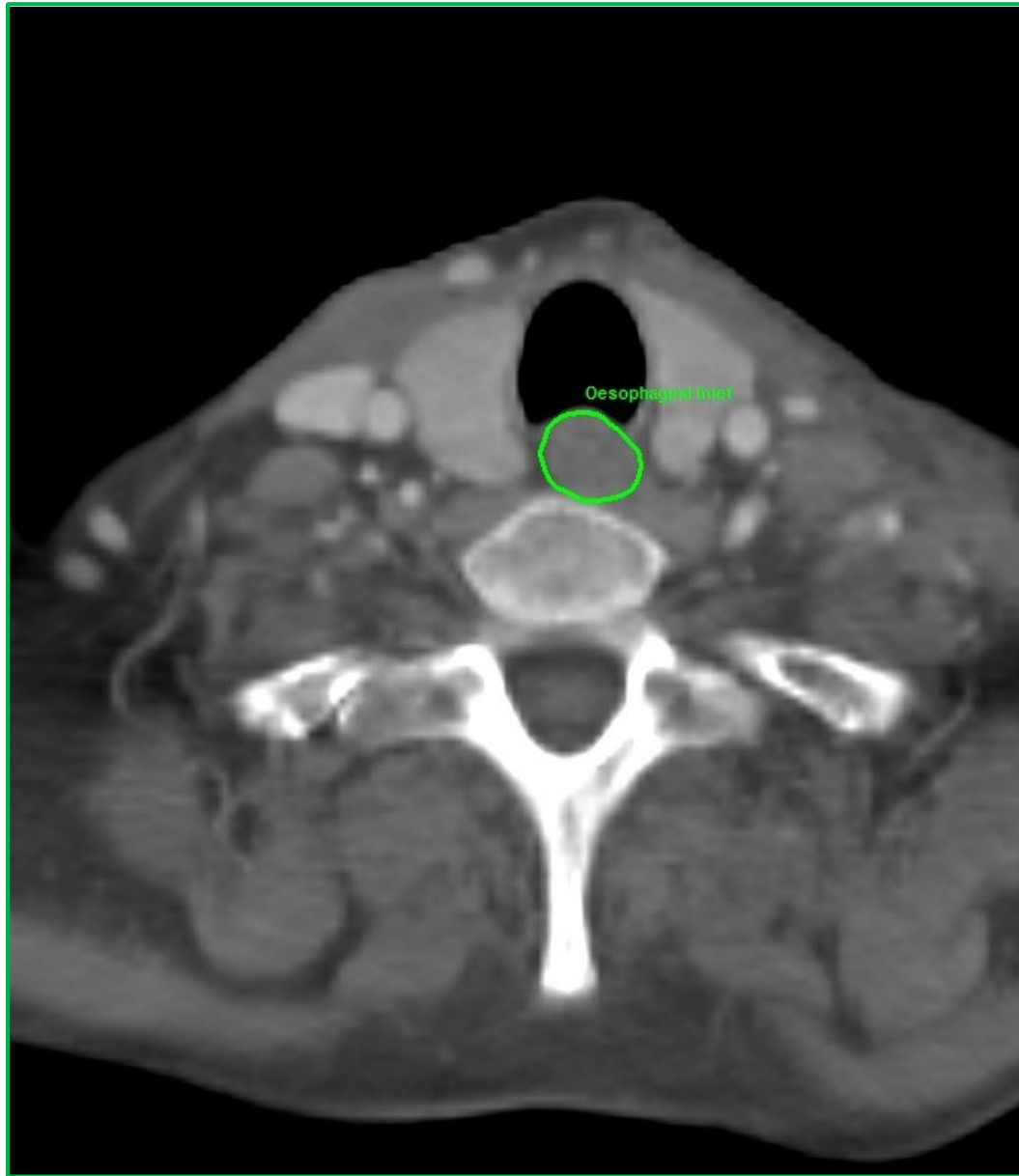


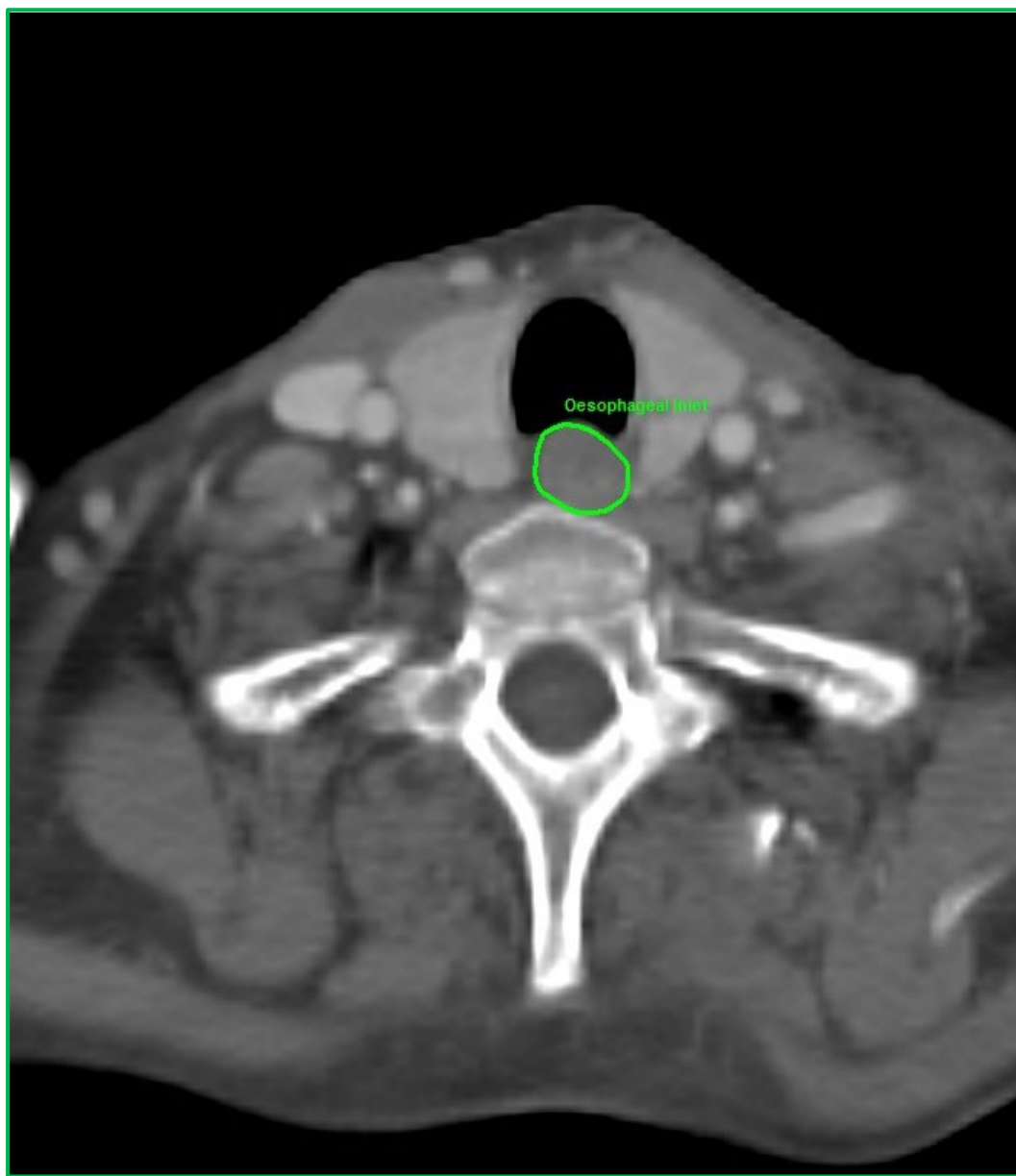
<b>Cranial</b>	<b>First slice caudal to lower edge of cricoid</b>
<b>Caudal</b>	<b>1 cm caudal to superior border of Oesophageal inlet</b>
<b>Anterior</b>	<b>Tracheal lumen</b>
<b>Posterior</b>	<b>Prevertebral muscle</b>
<b>Lateral</b>	<b>Fatty tissue/ Thyroid gland</b>

### Oesophageal Inlet Boundaries

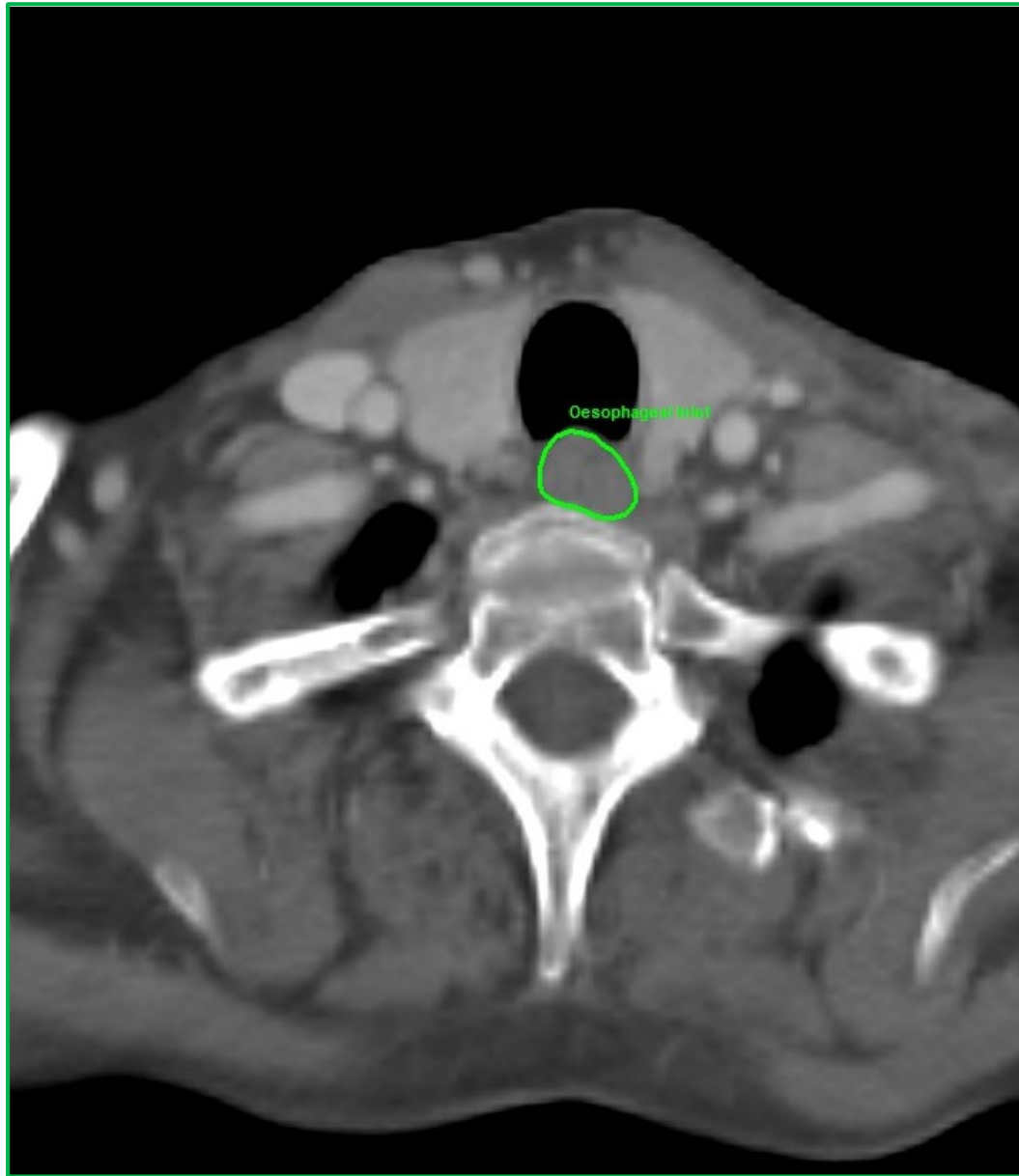




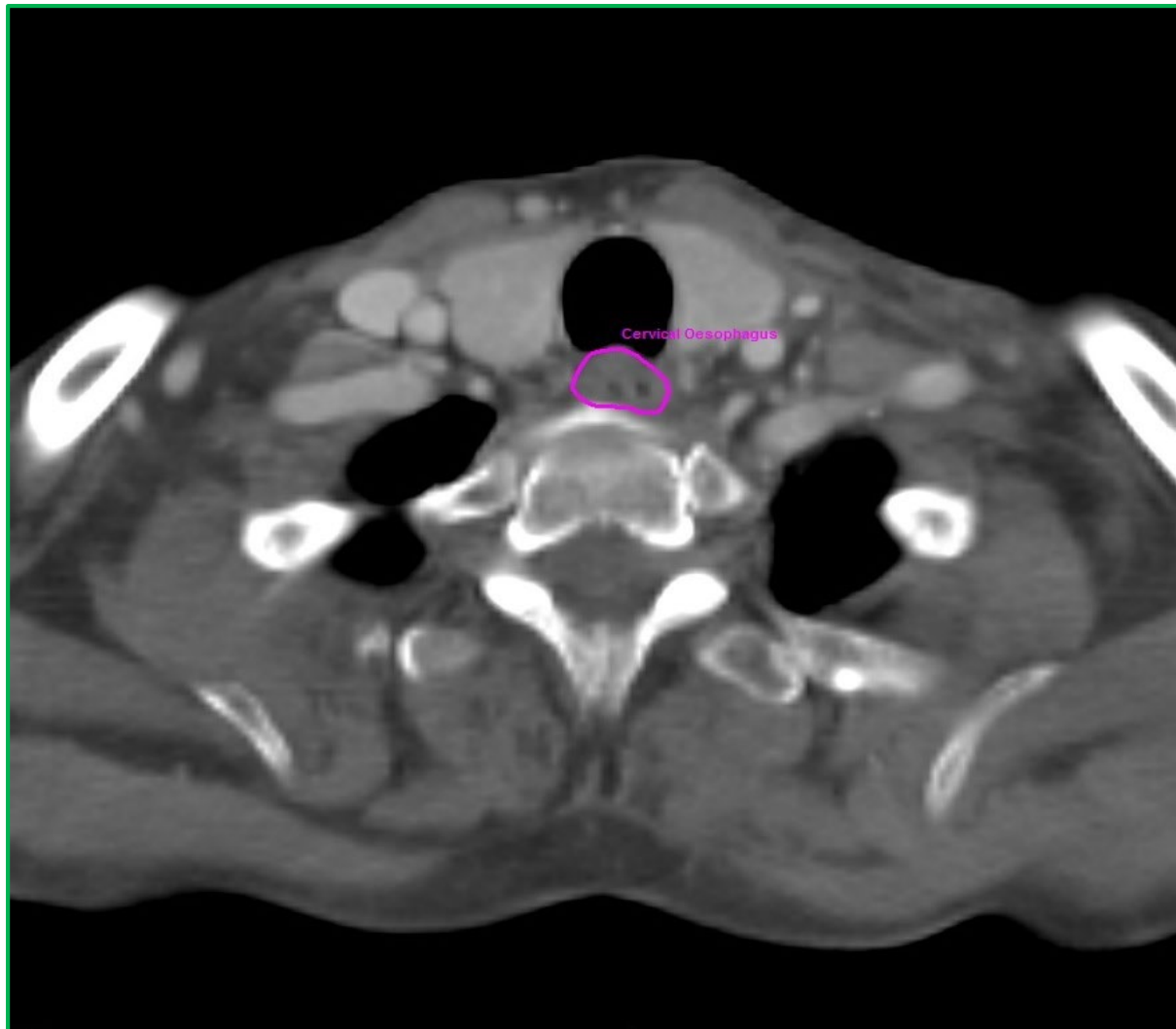




## Oesophageal Inlet - Caudal Boundary

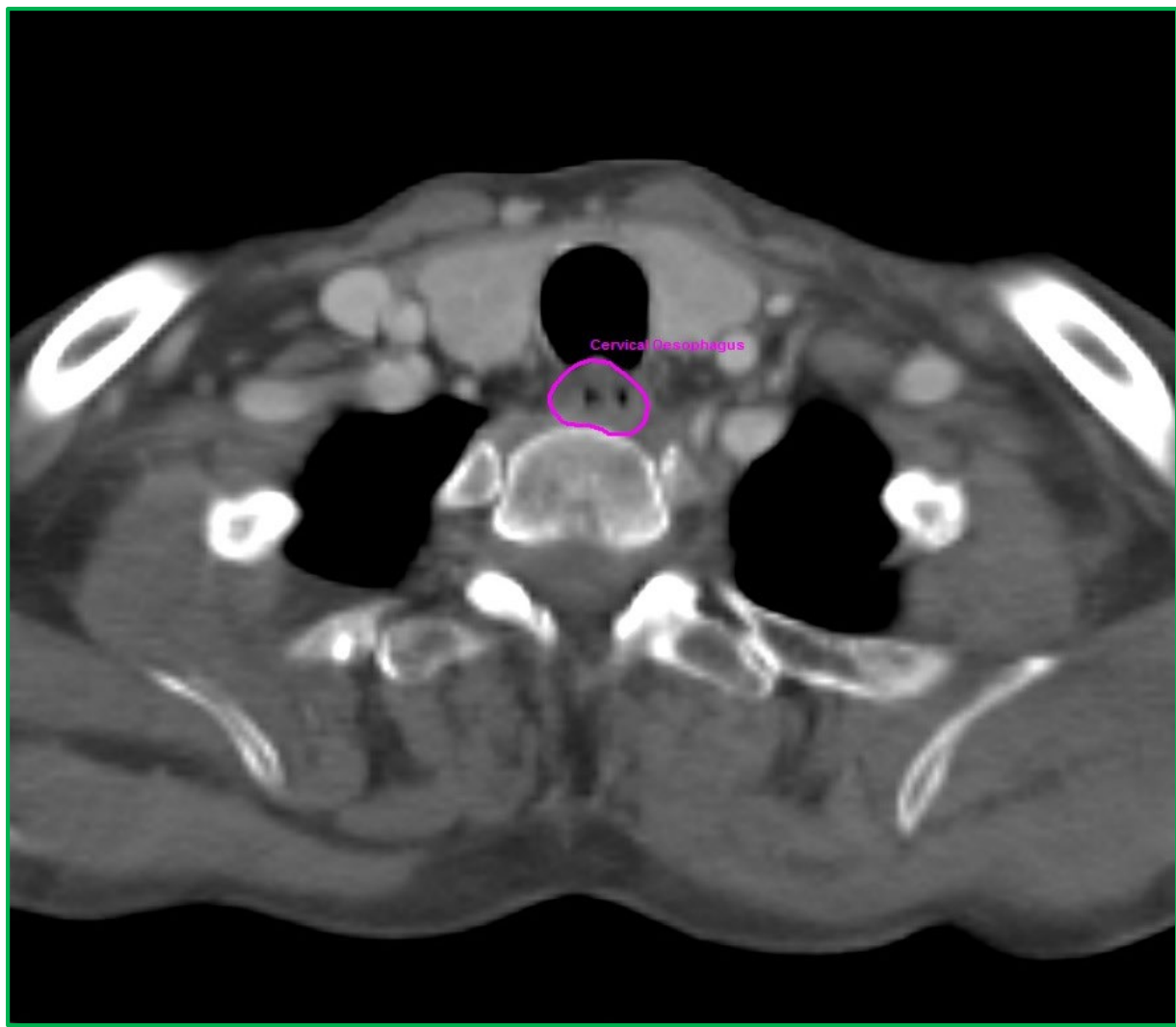


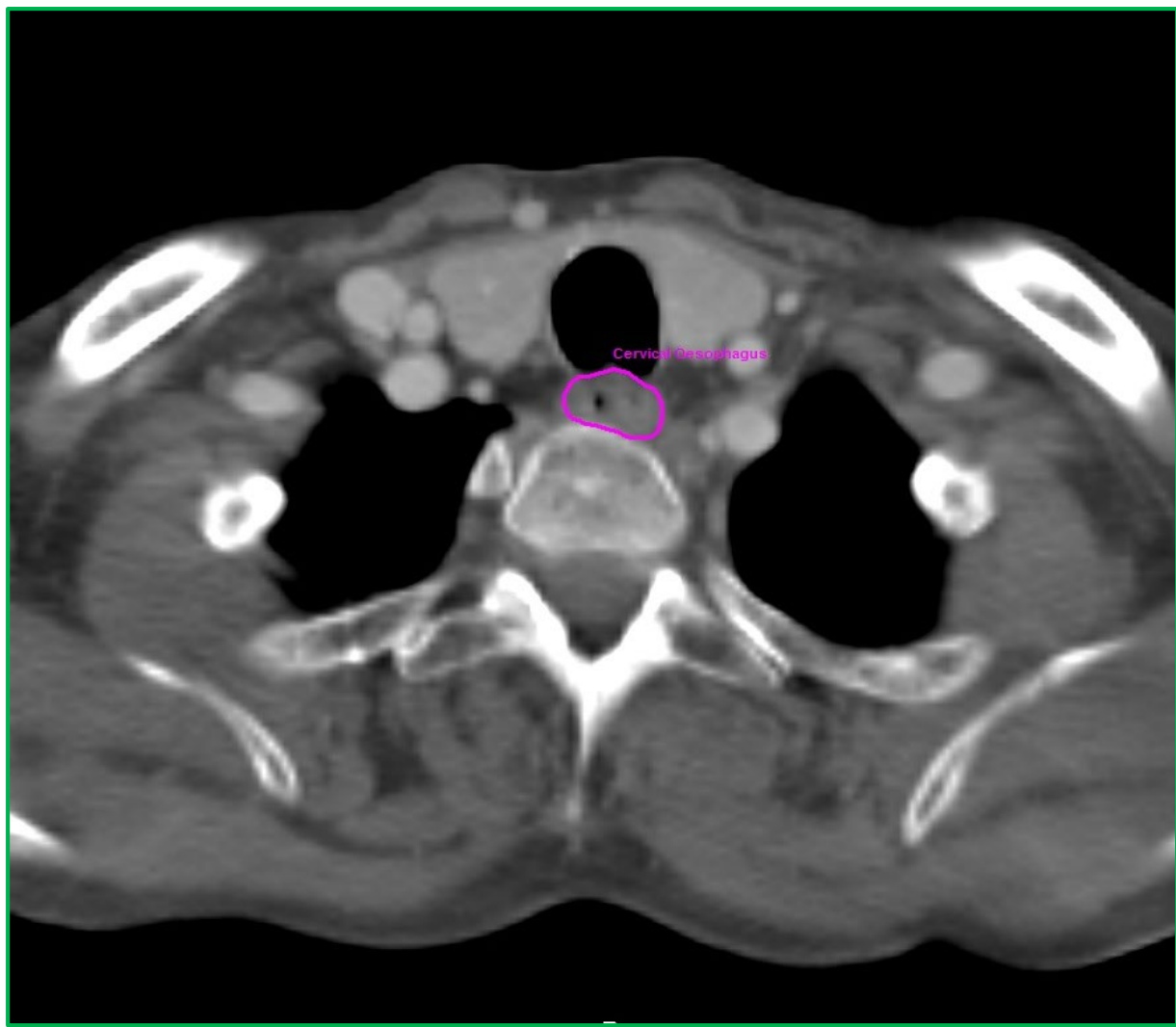
# Cervical Oesophagus - Cranial Boundary

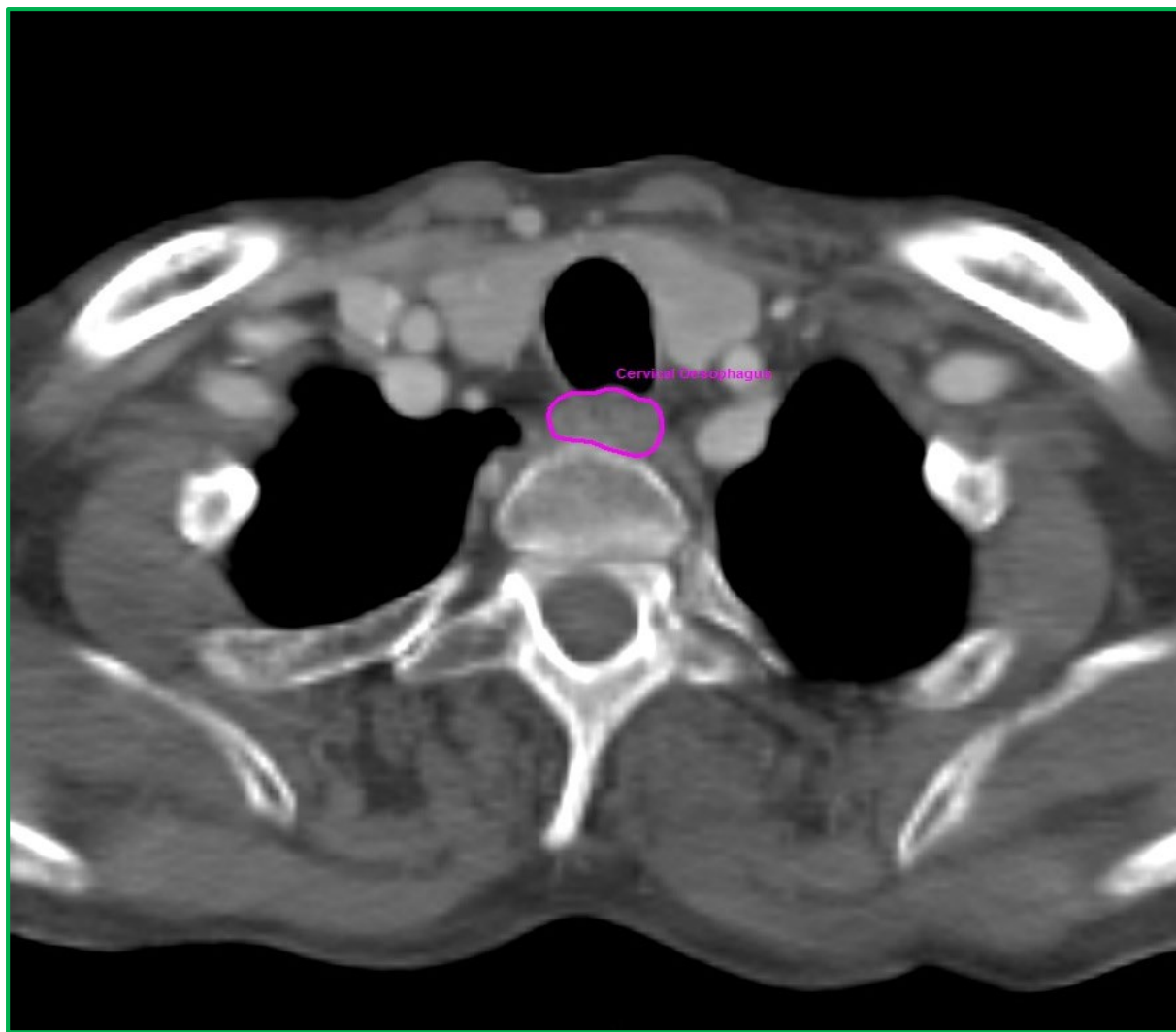


<b>Cranial</b>	<b>1 cm caudal to lower edge of cricoid</b>
<b>Caudal</b>	<b>Sternal notch</b>

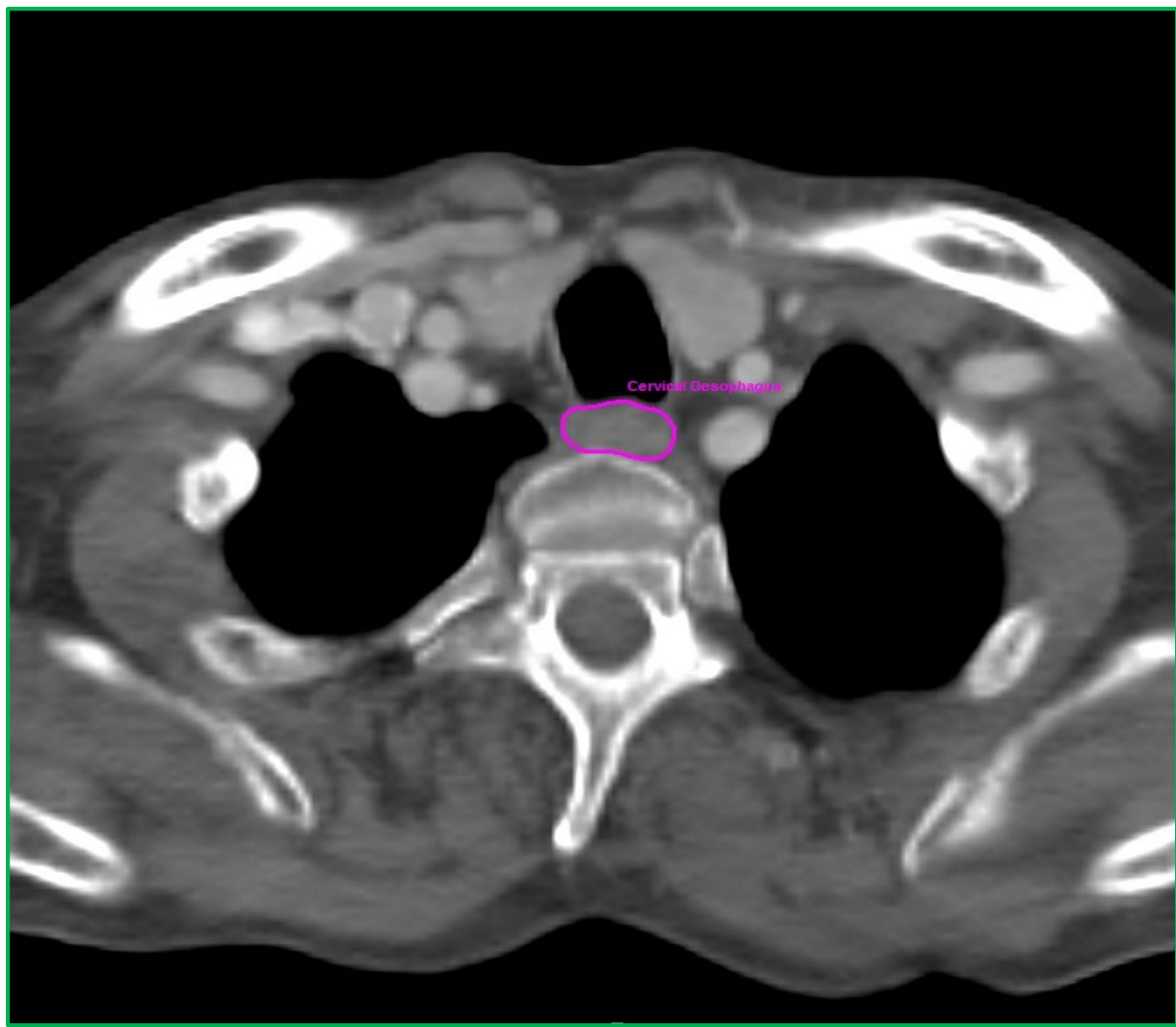
**Cervical Oesophagus Boundaries**

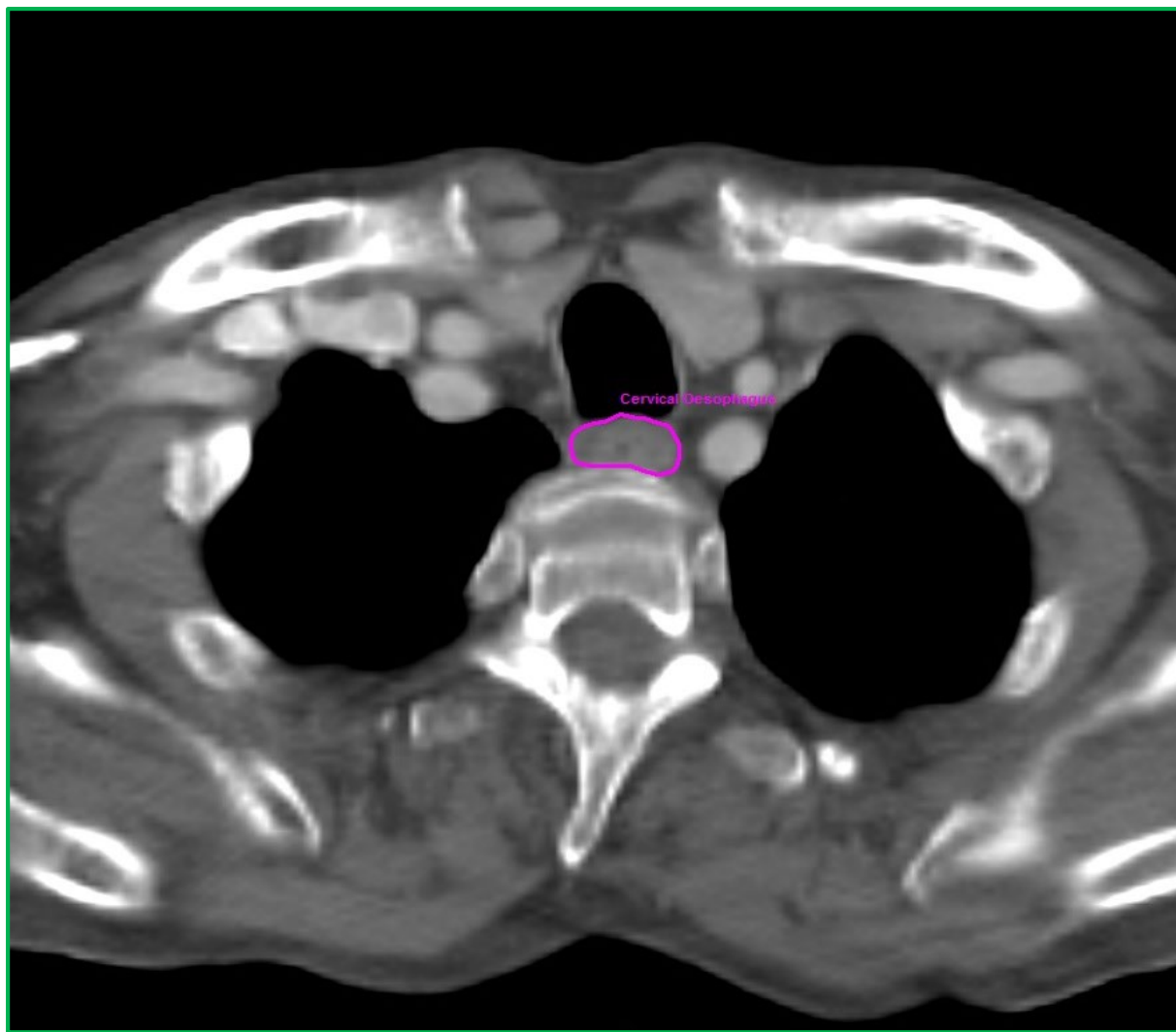


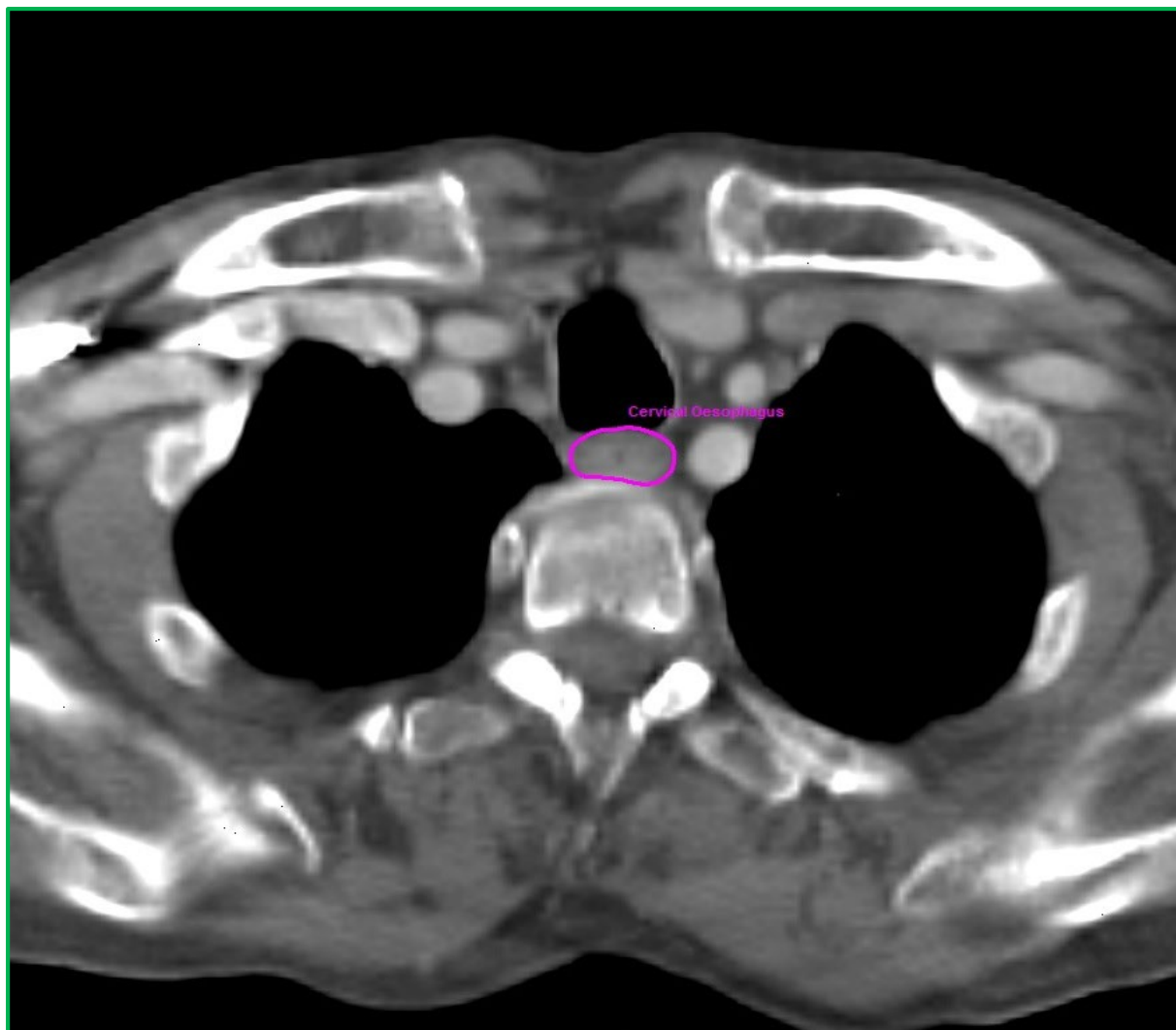


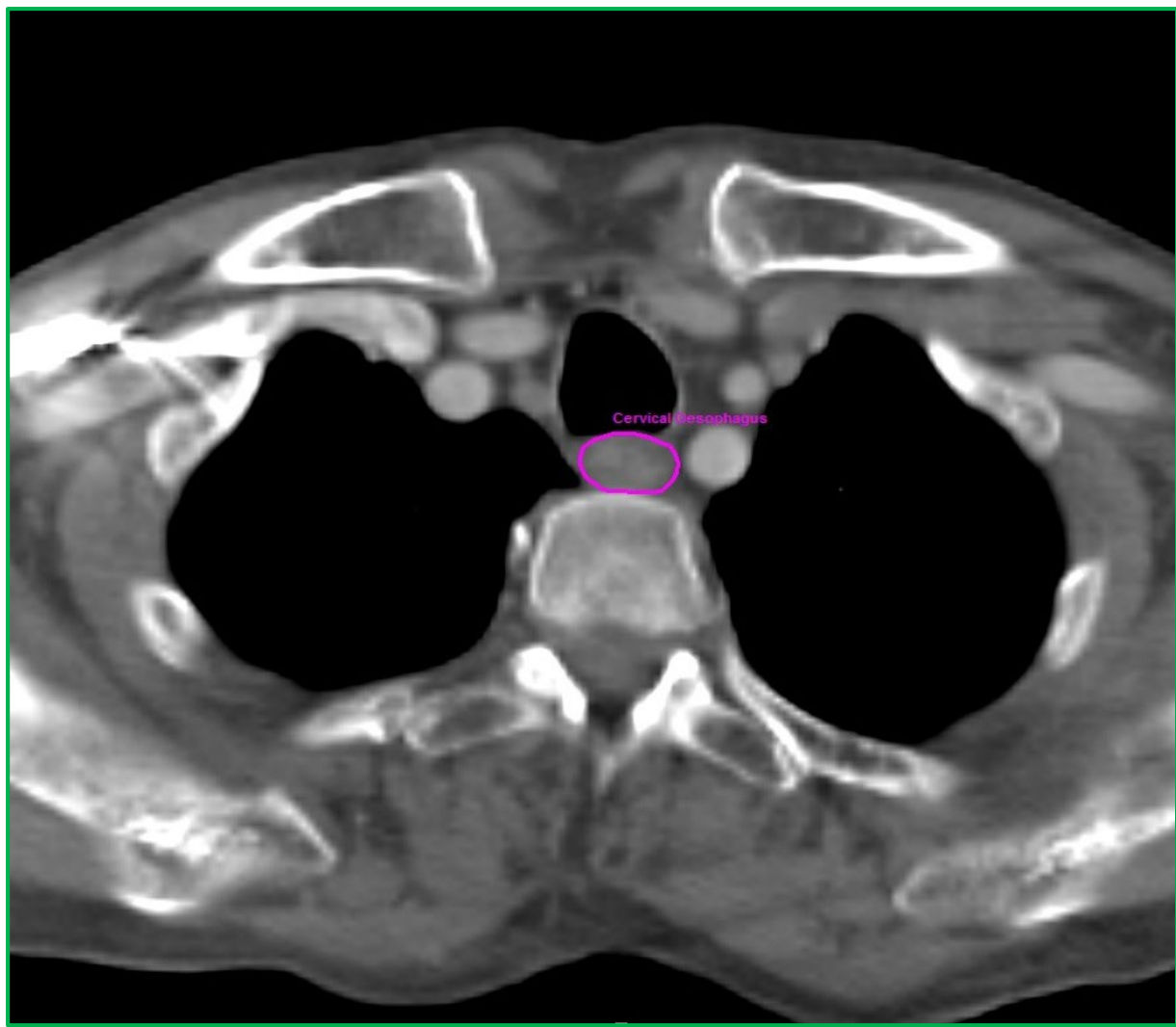


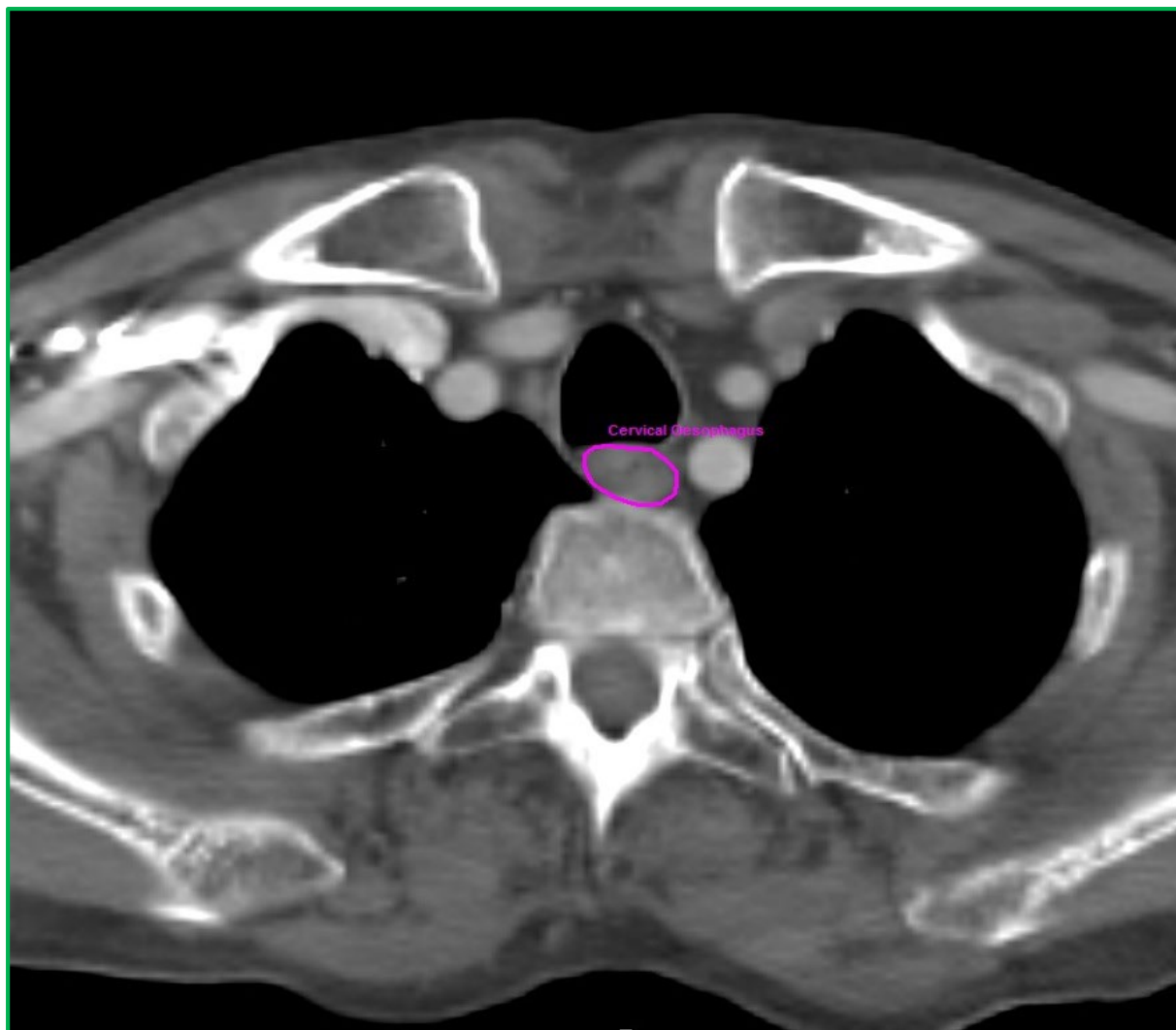




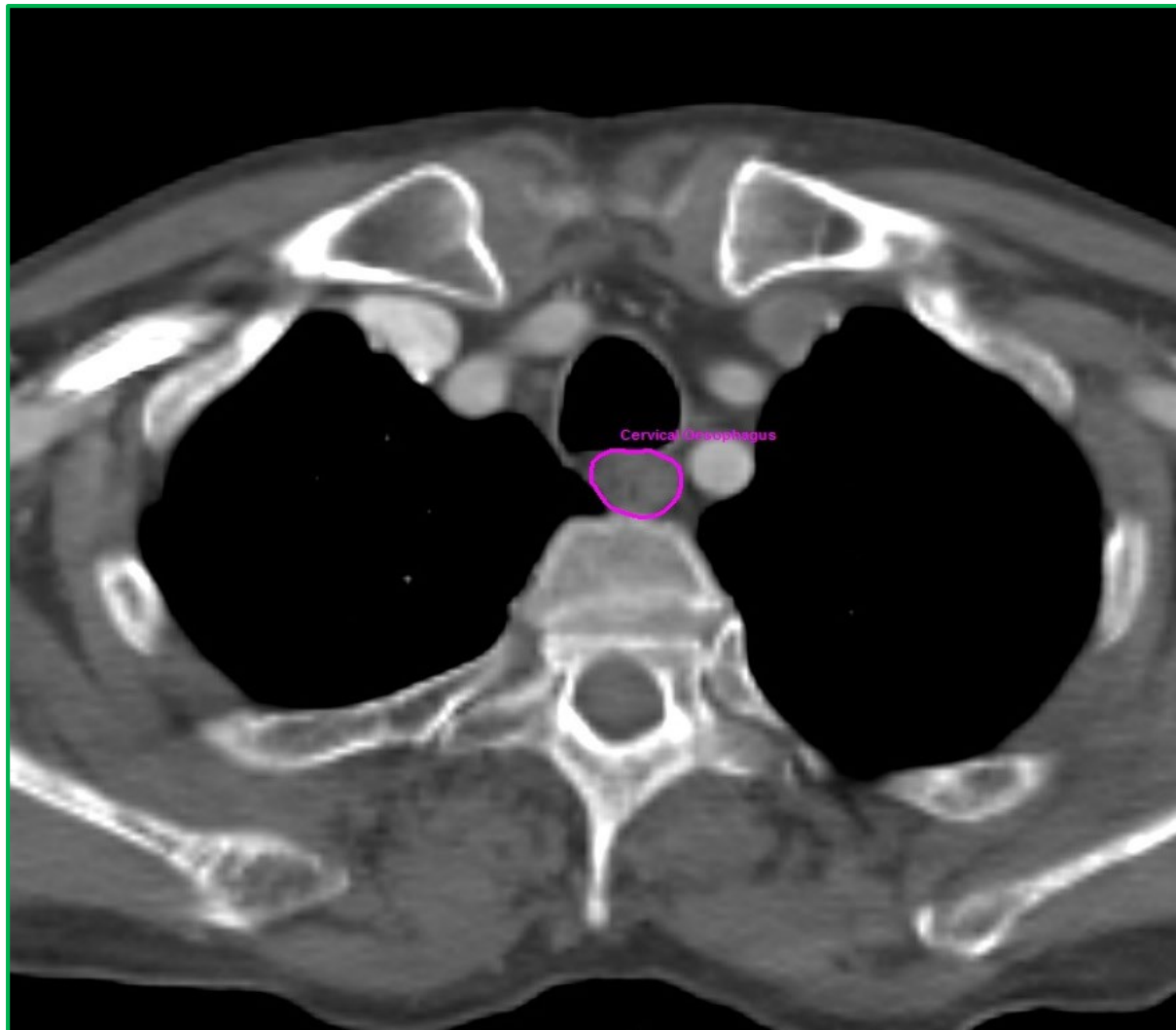




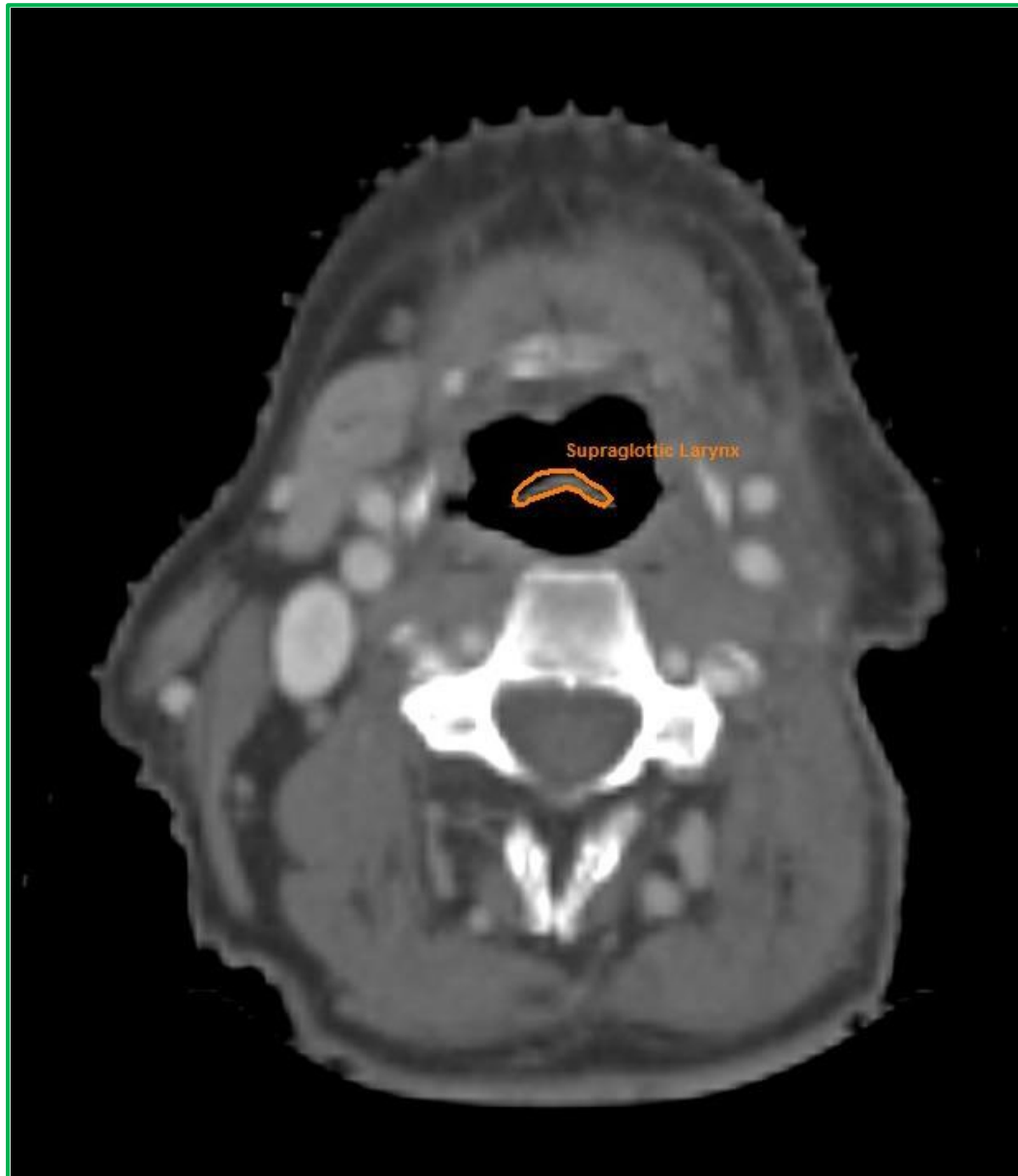




## Cervical Oesophagus - Caudal Boundary

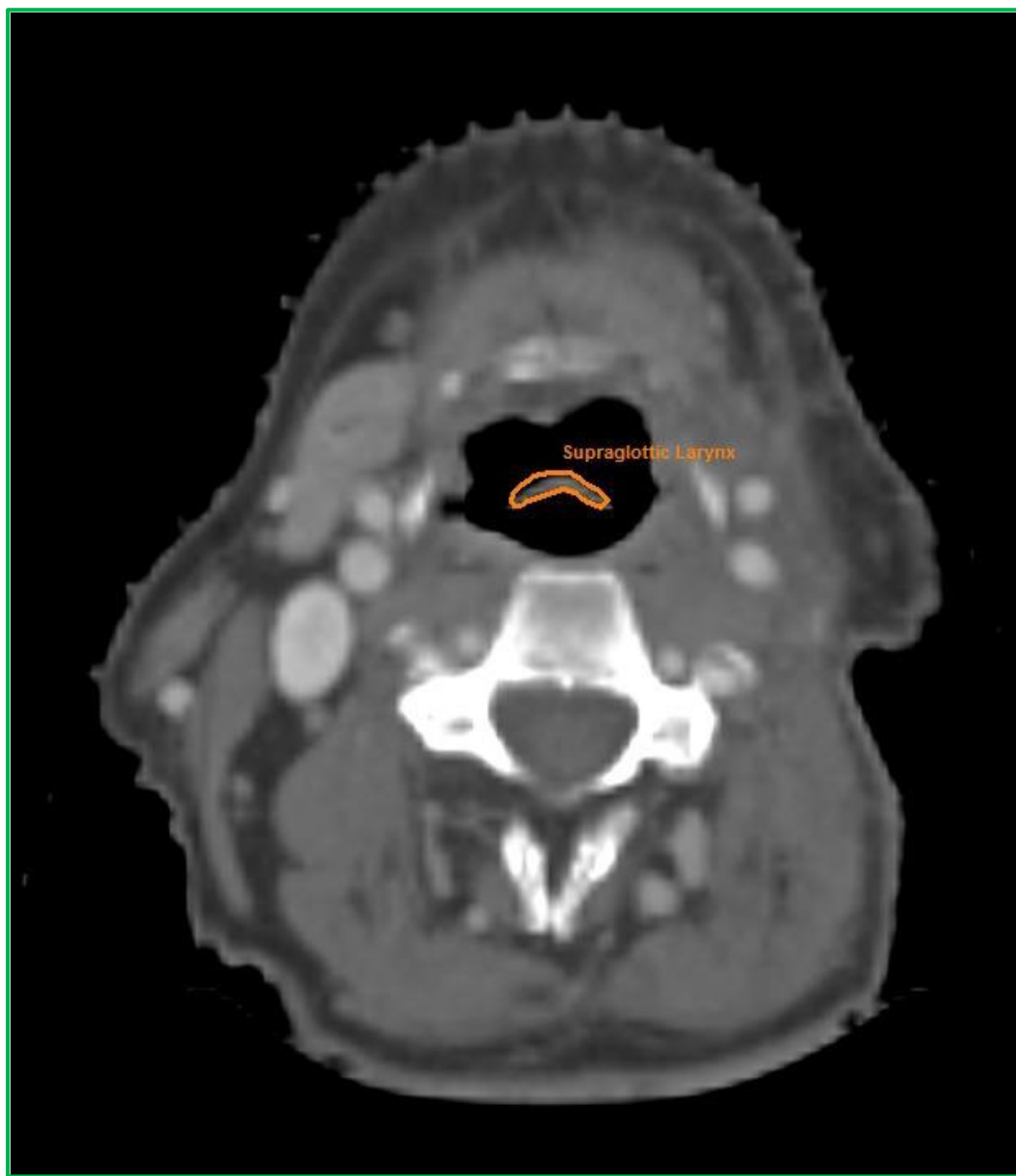


# Supraglottic Larynx - Cranial Boundary

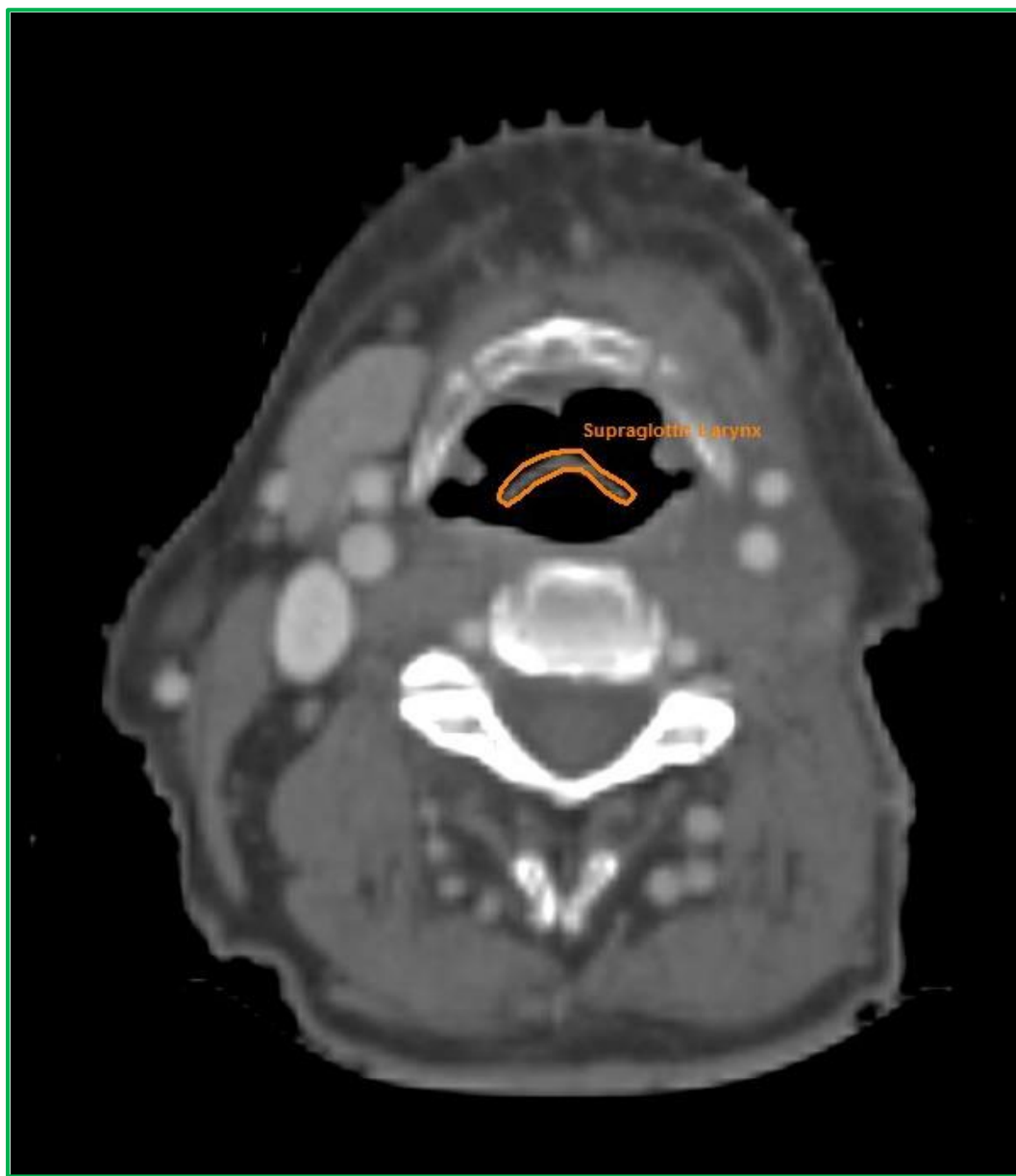


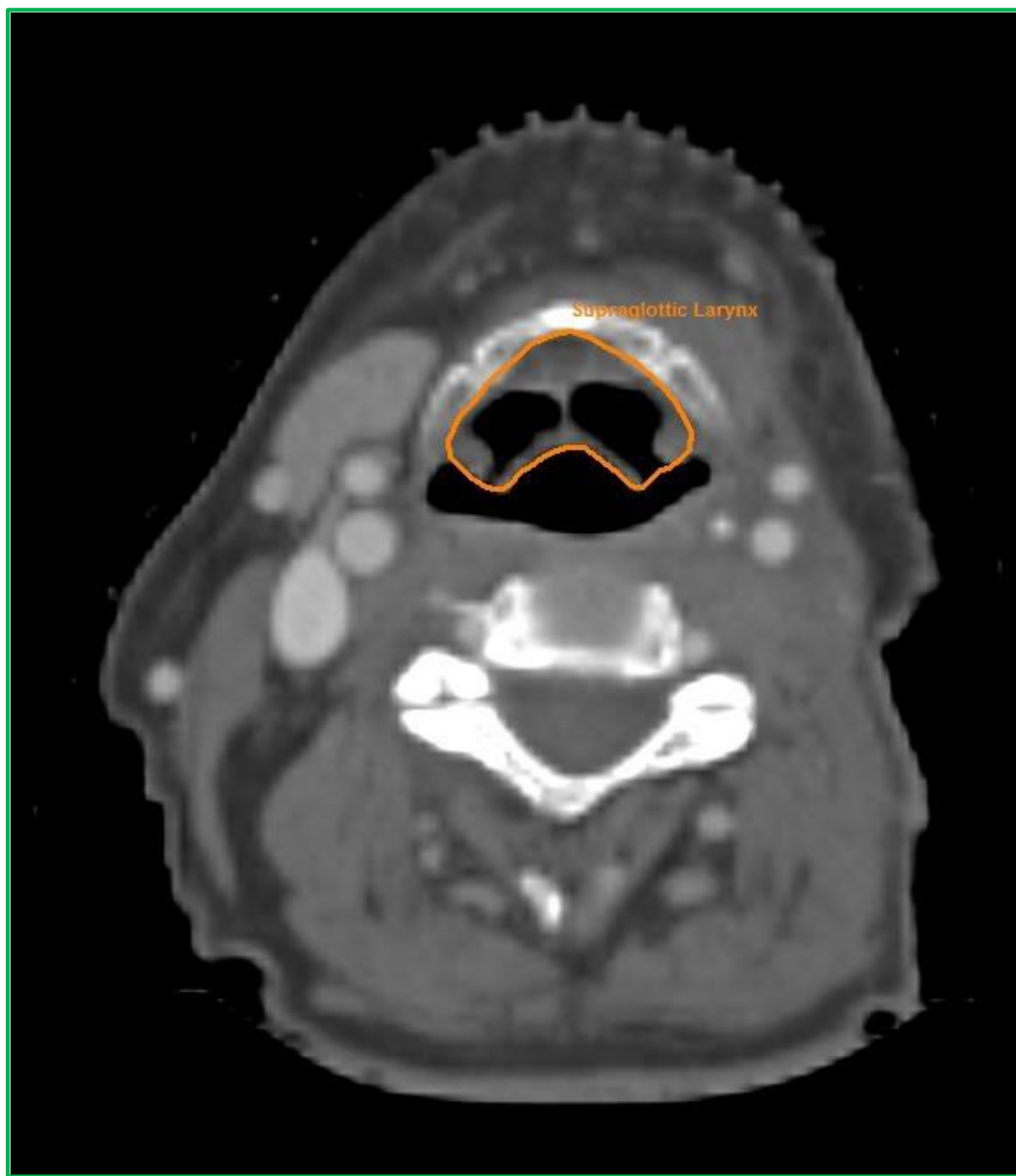
<b>Cranial</b>	<b>Tip of epiglottis</b>
<b>Caudal</b>	<b>First slice cranial to upper edge of arytenoids</b>
<b>Anterior</b>	<b>Hyoid/ Pre epiglottic space/ Thyroid cartilage</b>
<b>Posterior</b>	<b>Pharyngeal lumen/ Inferior constrictor</b>
<b>Lateral</b>	<b>Thyroid cartilage Parapharyngeal space</b>
<b>Medial</b>	<b>Pharyngeal lumen</b>

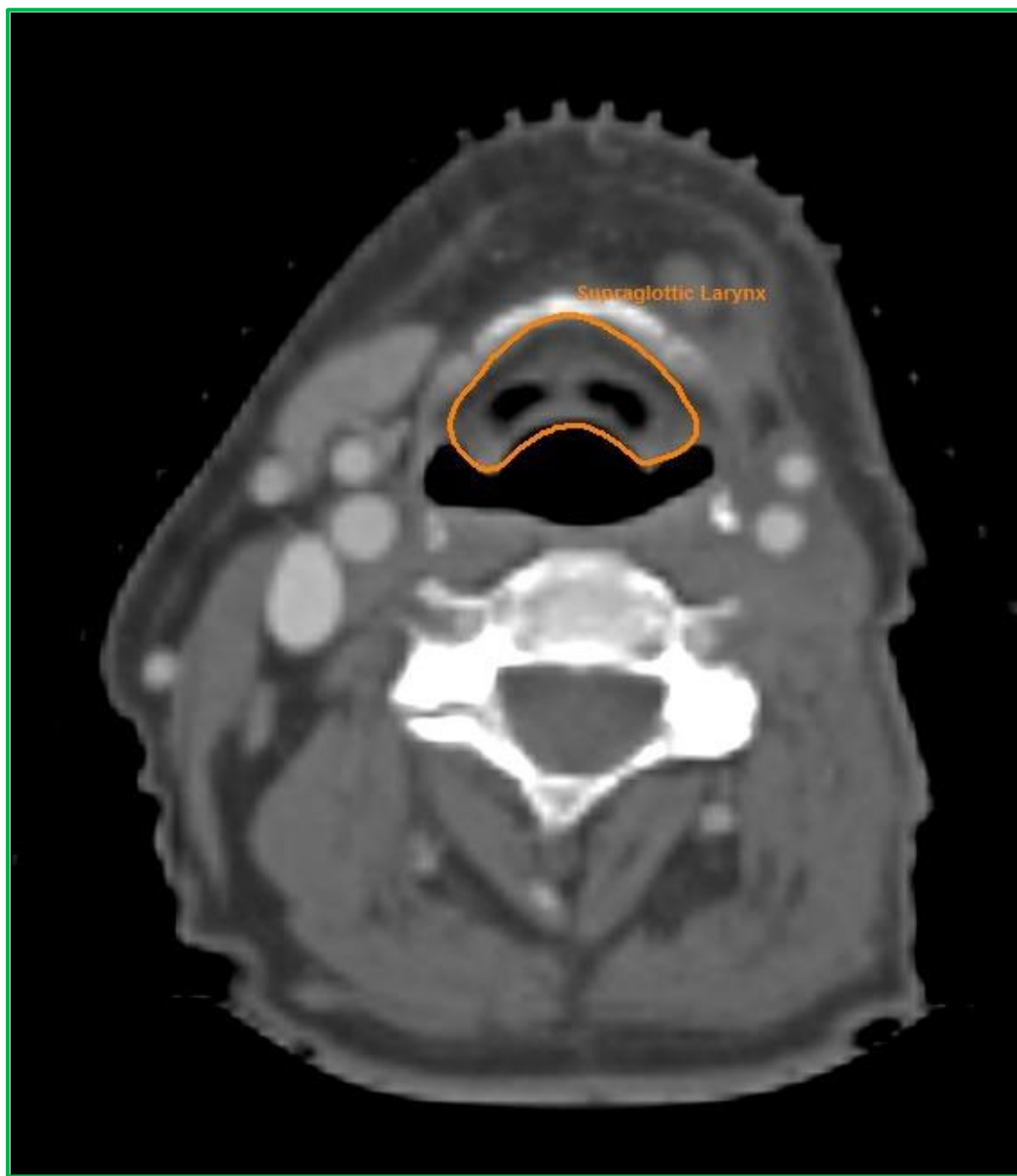
## Supraglottic Larynx Boundaries

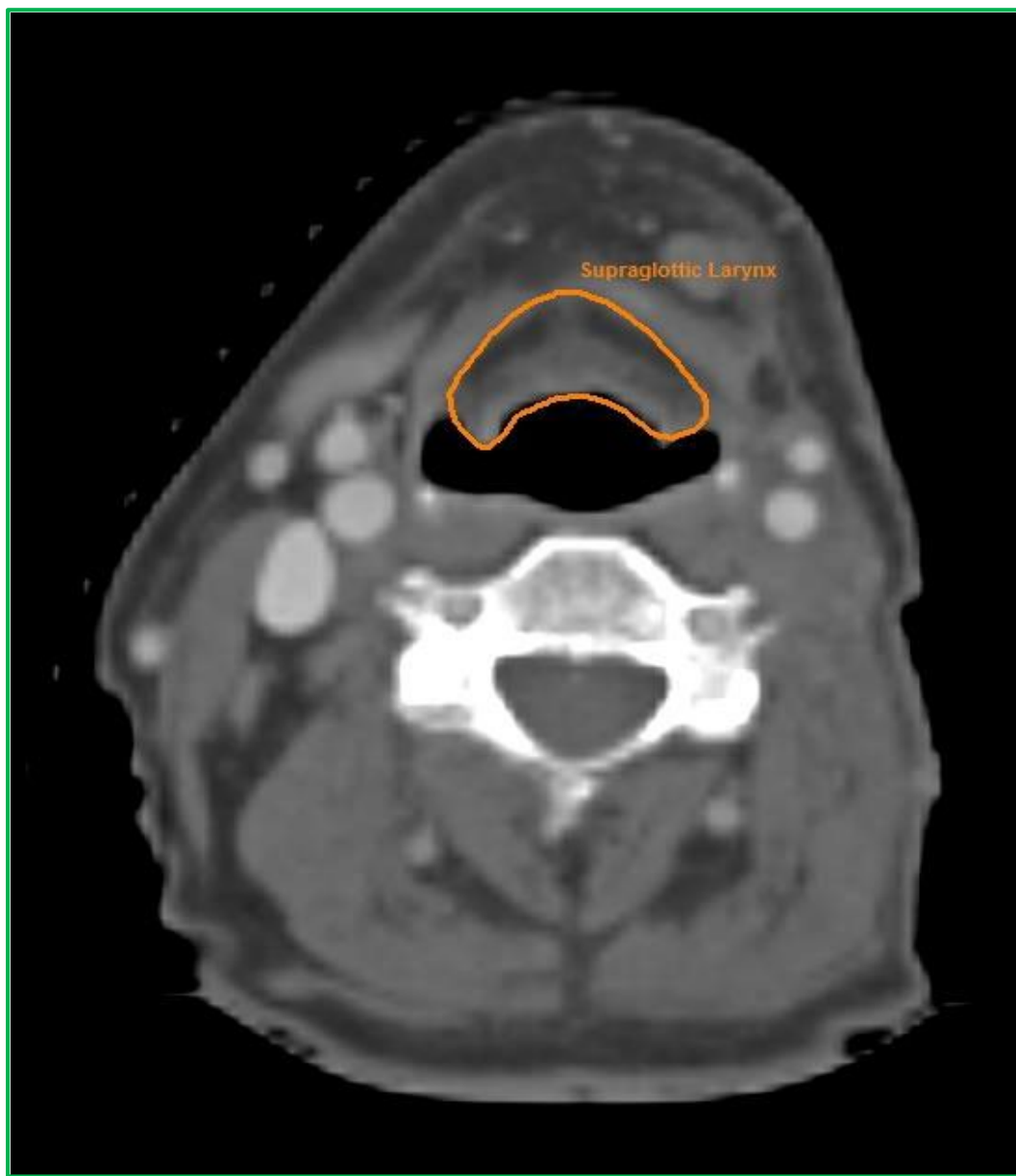


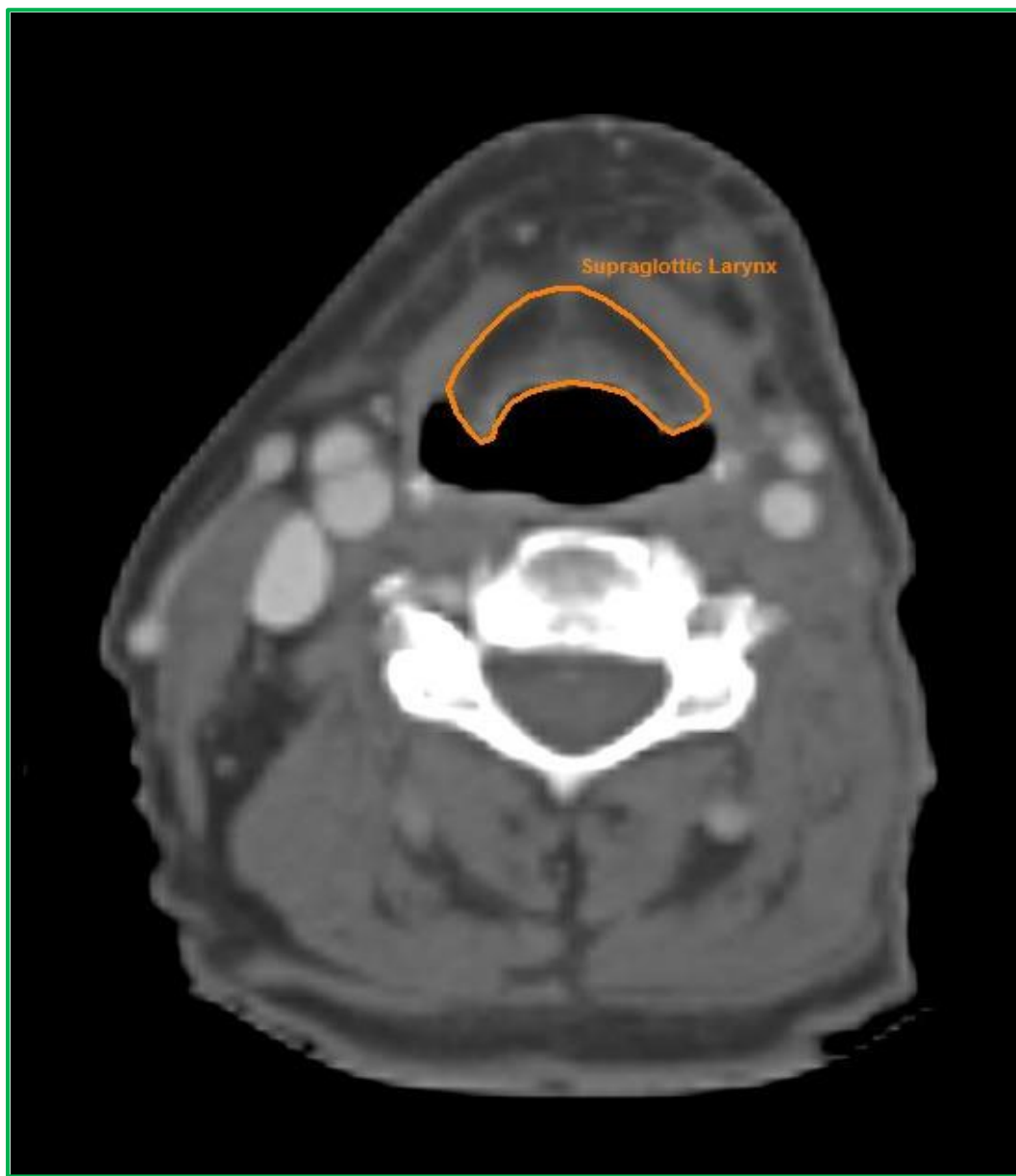


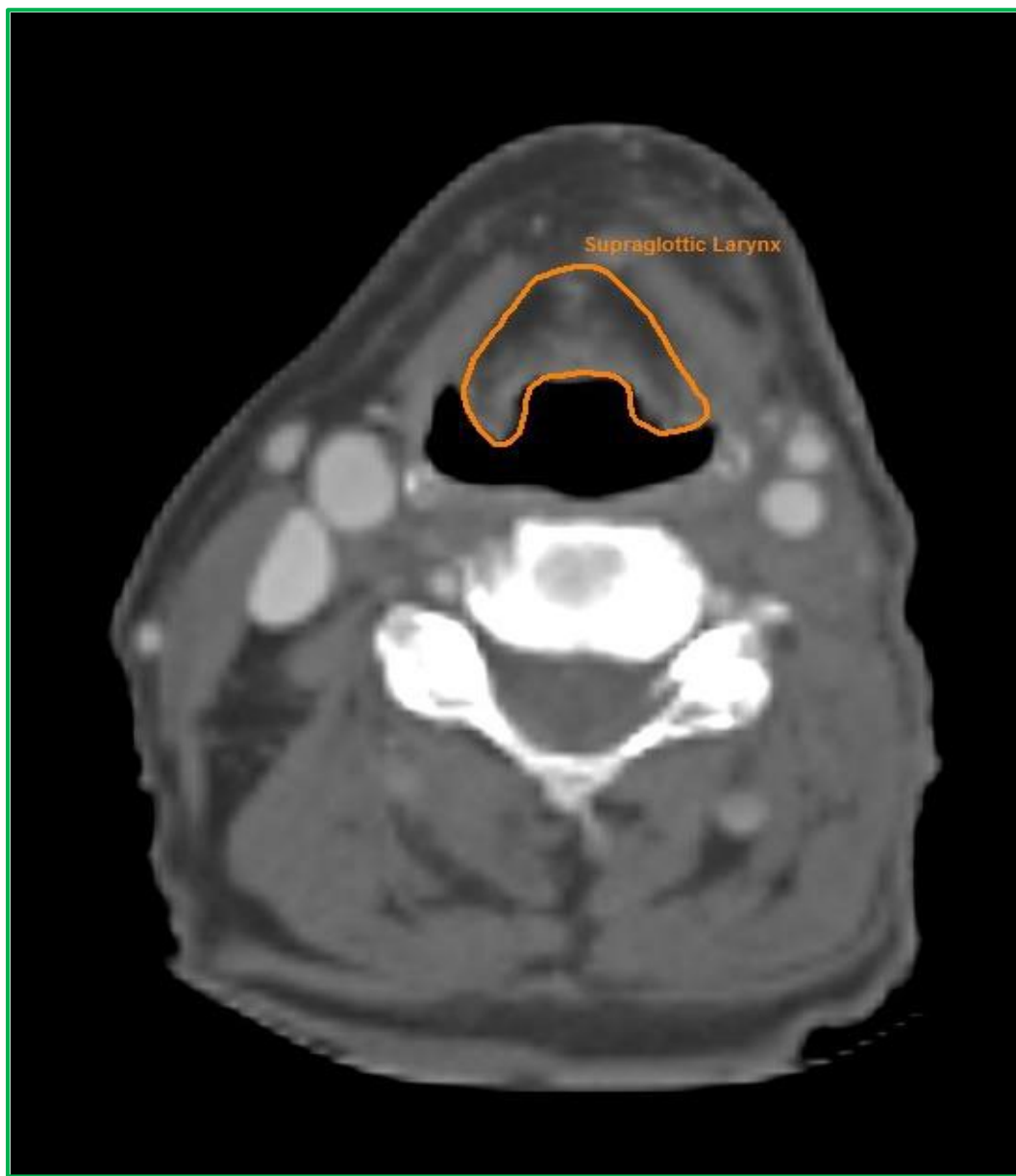


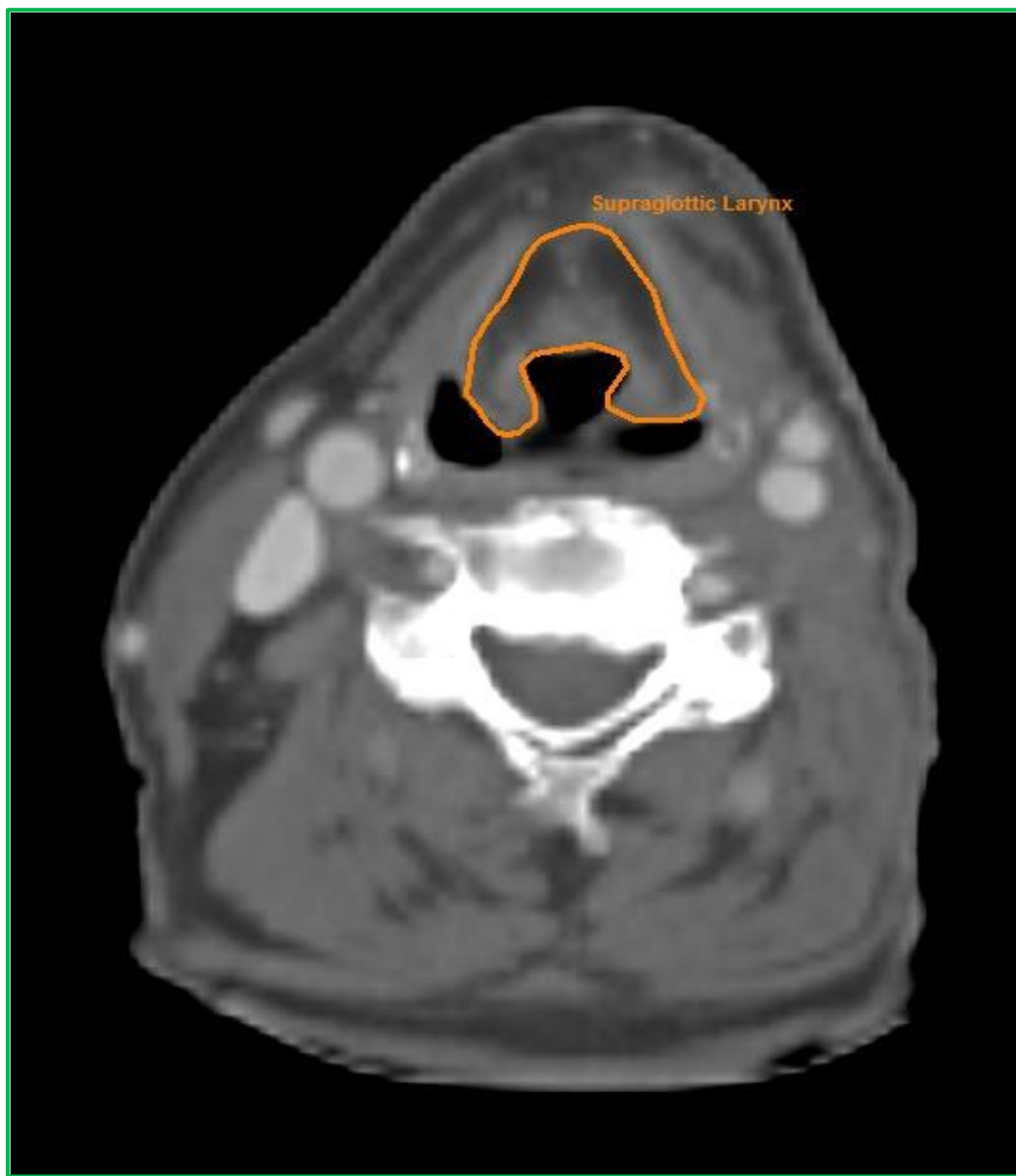




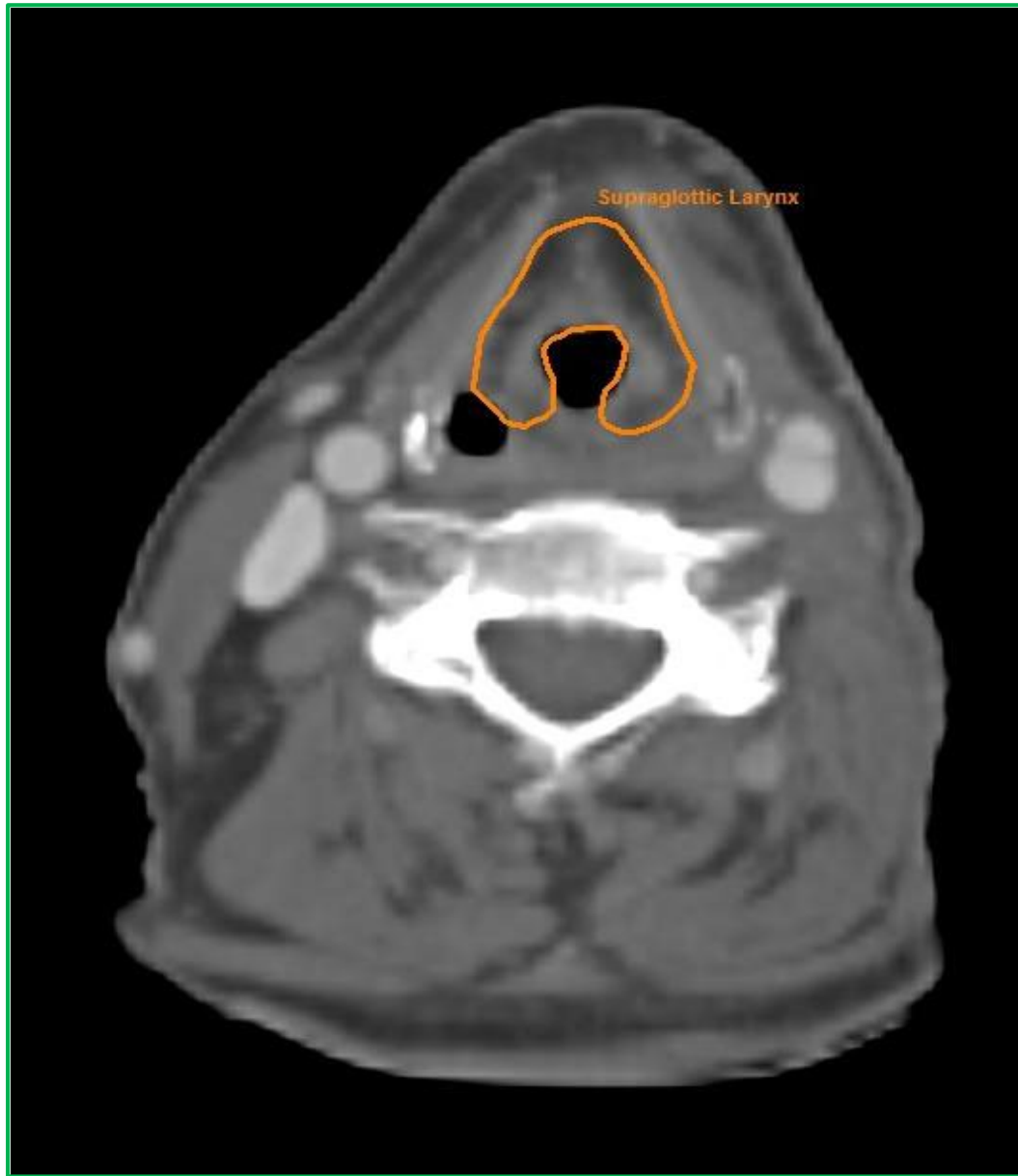






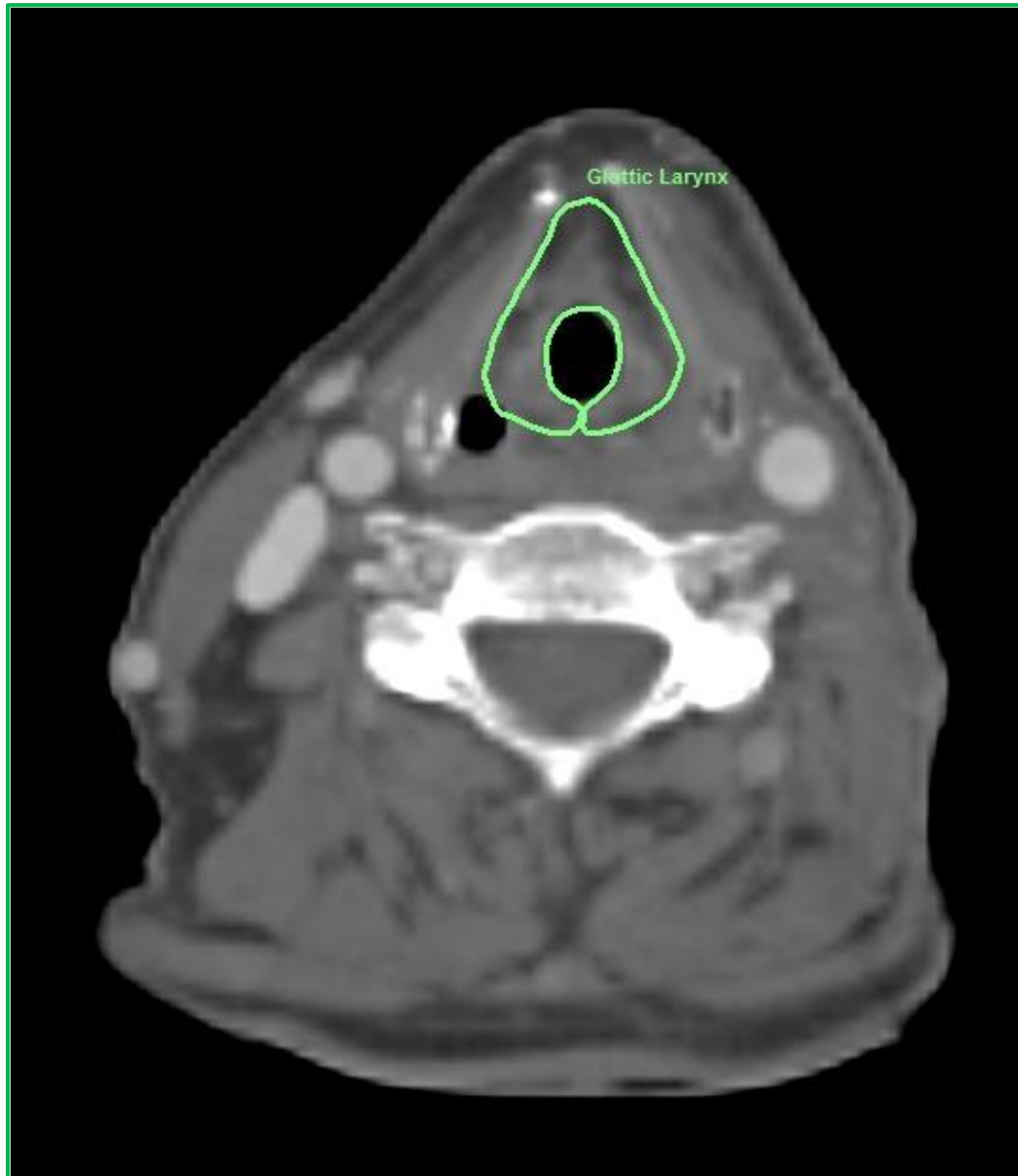


## Supraglottic Larynx - Caudal Boundary



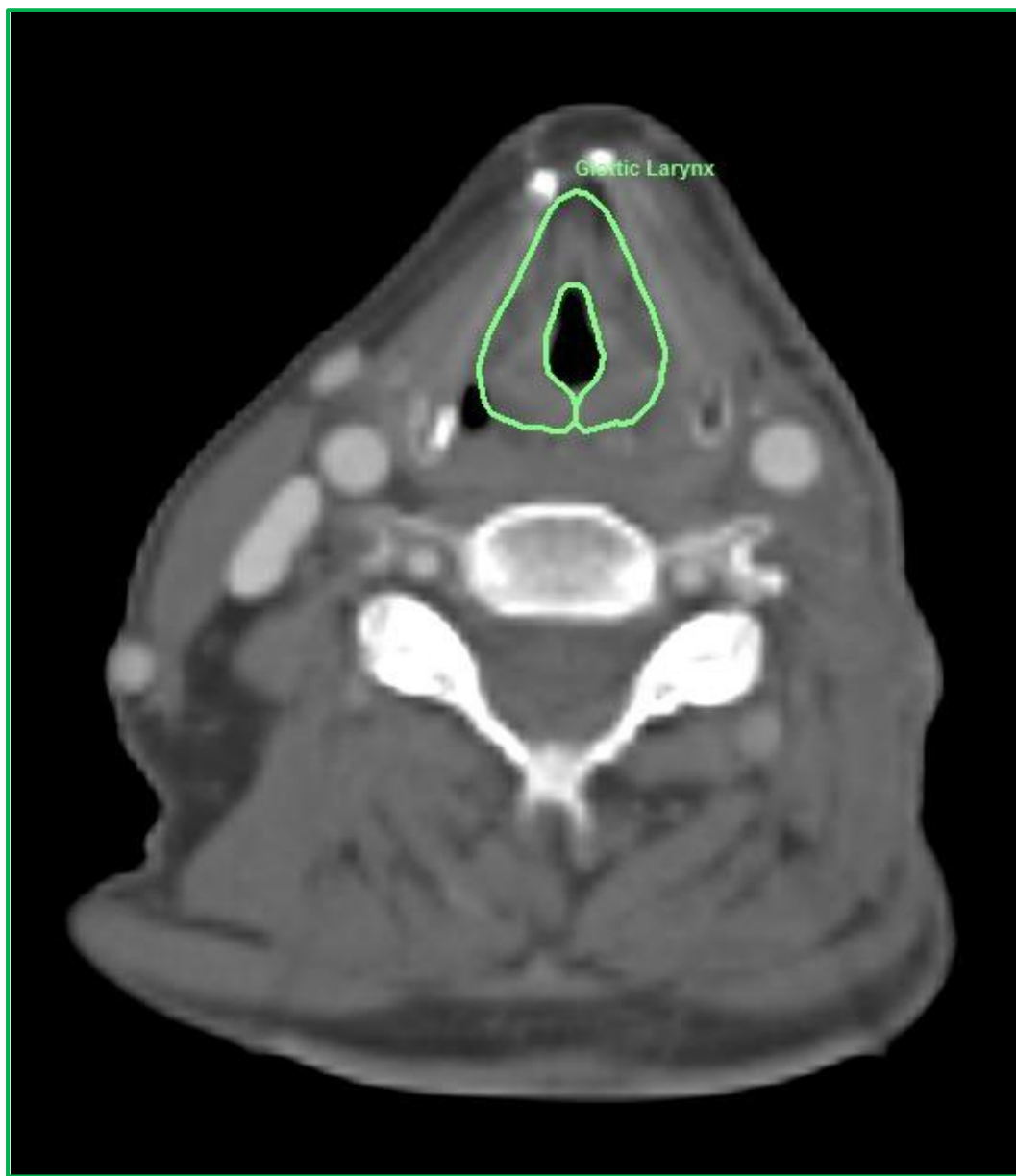


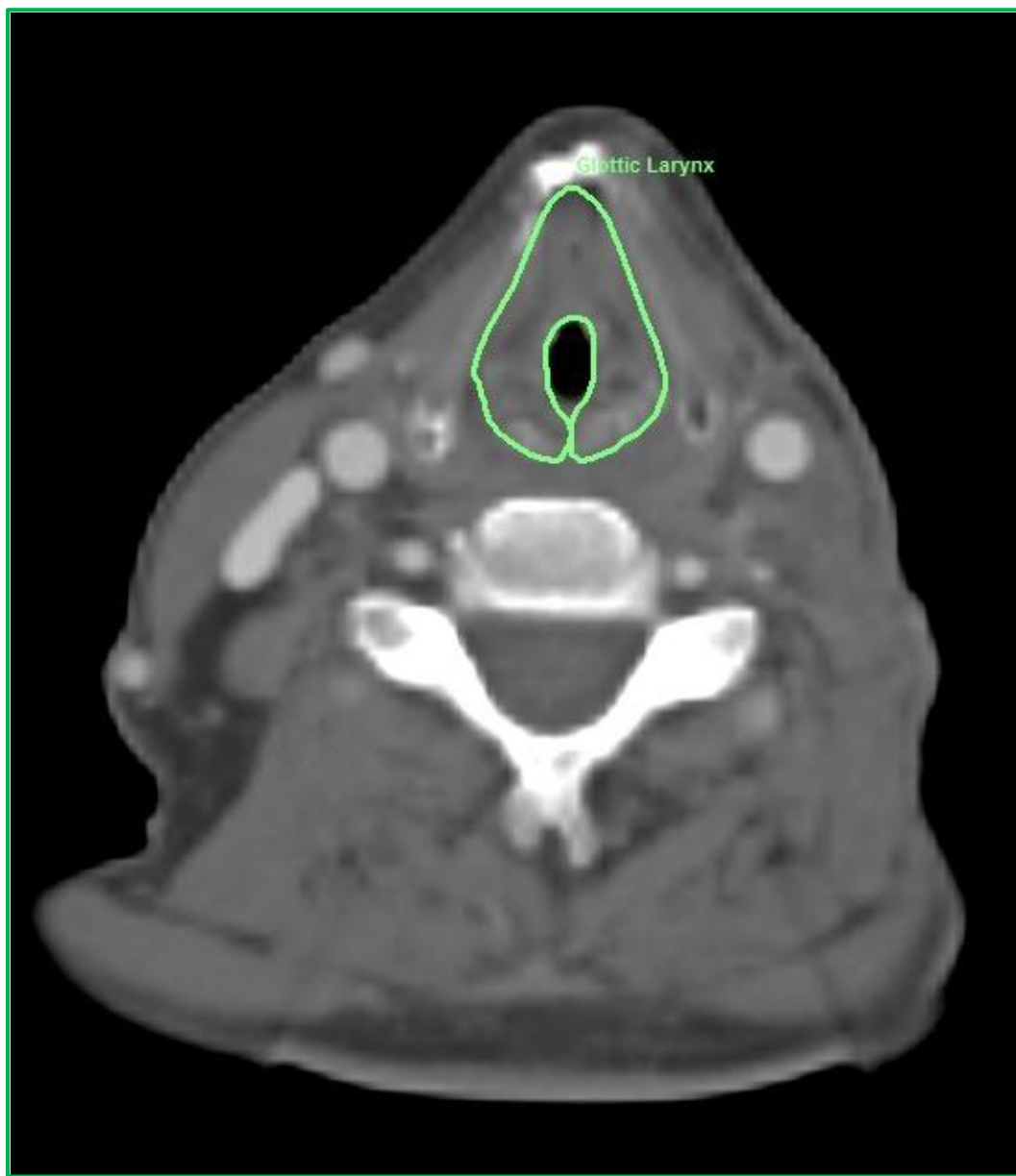# Glottic Larynx - Cranial Boundary

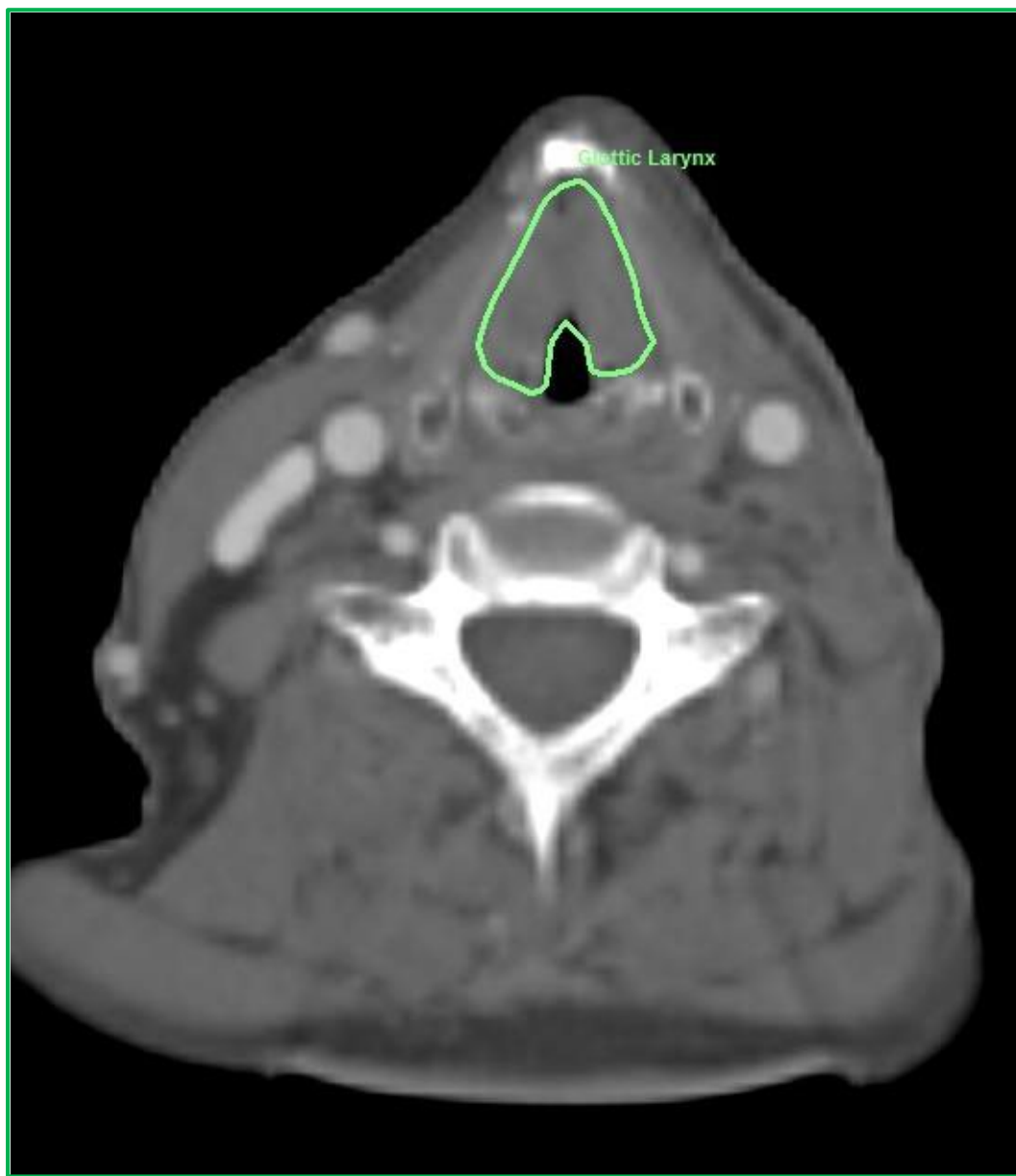


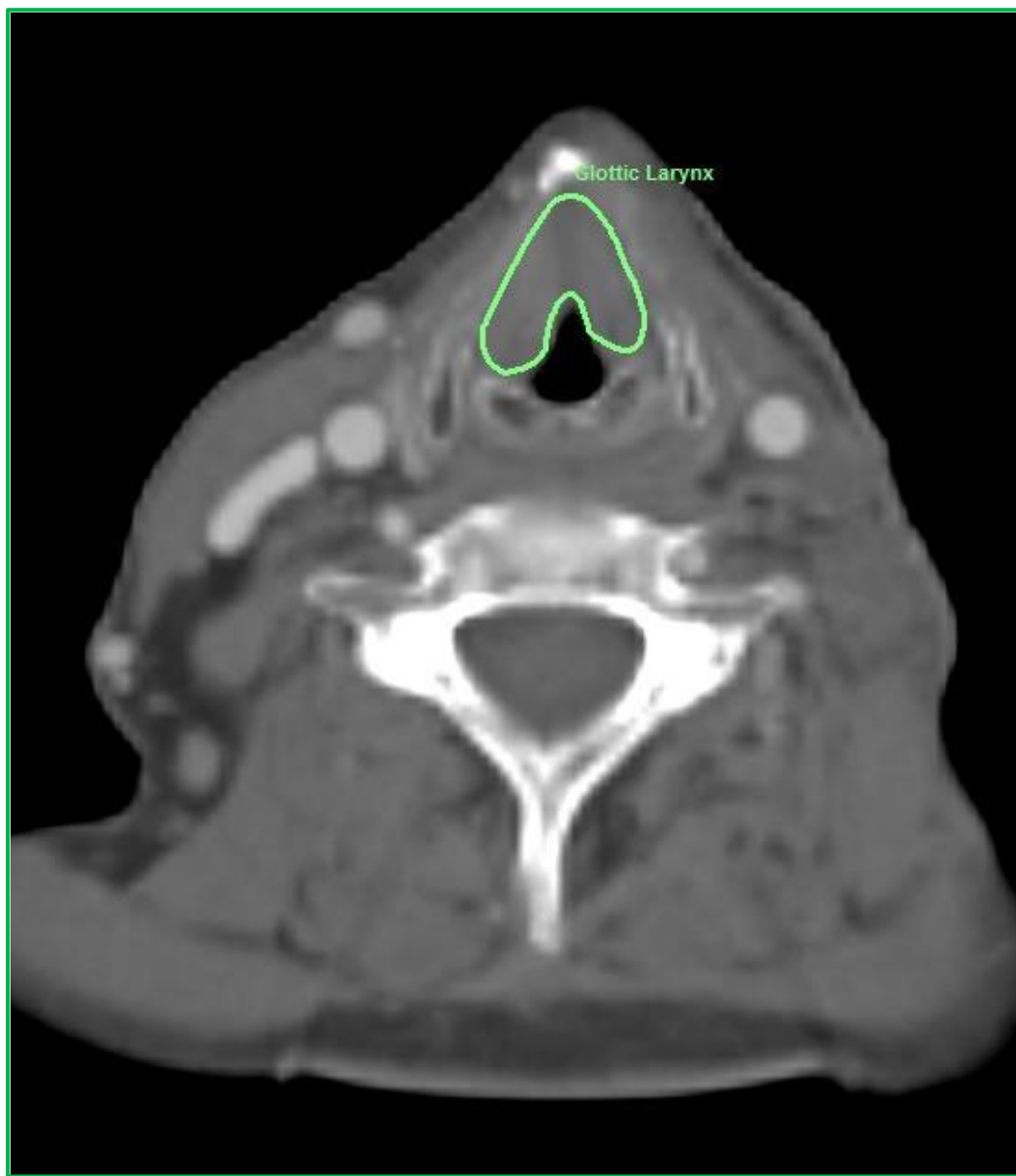
<b>Cranial</b>	<b>Upper edge of arytenoids</b>
<b>Caudal</b>	<b>Lower edge of cricoid if soft tissue present</b>
<b>Anterior</b>	<b>Thyroid cartilage</b>
<b>Posterior</b>	<b>Pharyngeal lumen/ Inferior constrictor/ Cricoid</b>
<b>Lateral</b>	<b>Thyroid cartilage</b>
<b>Medial</b>	<b>Pharyngeal lumen</b>

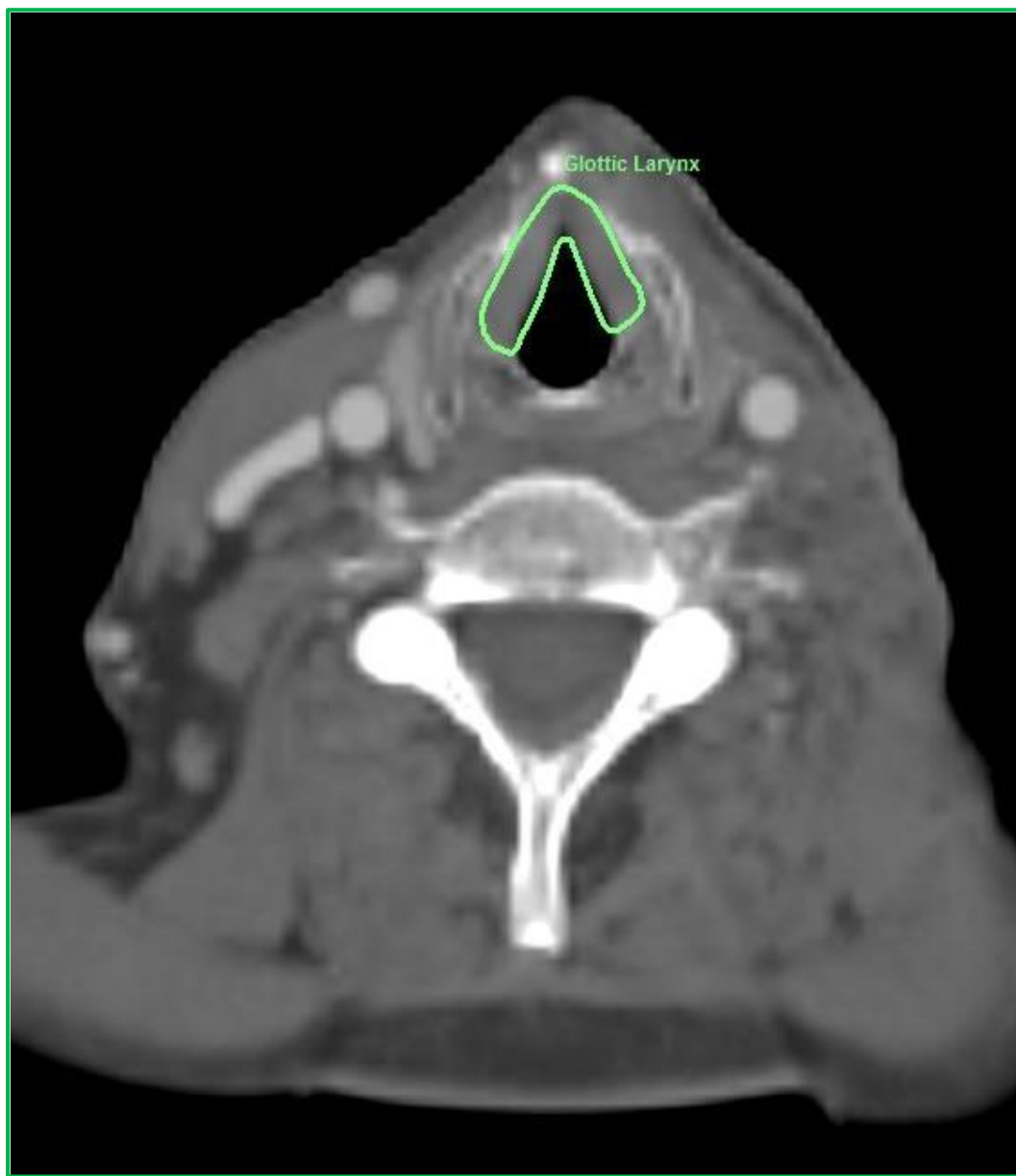
## Glottic Larynx Boundaries



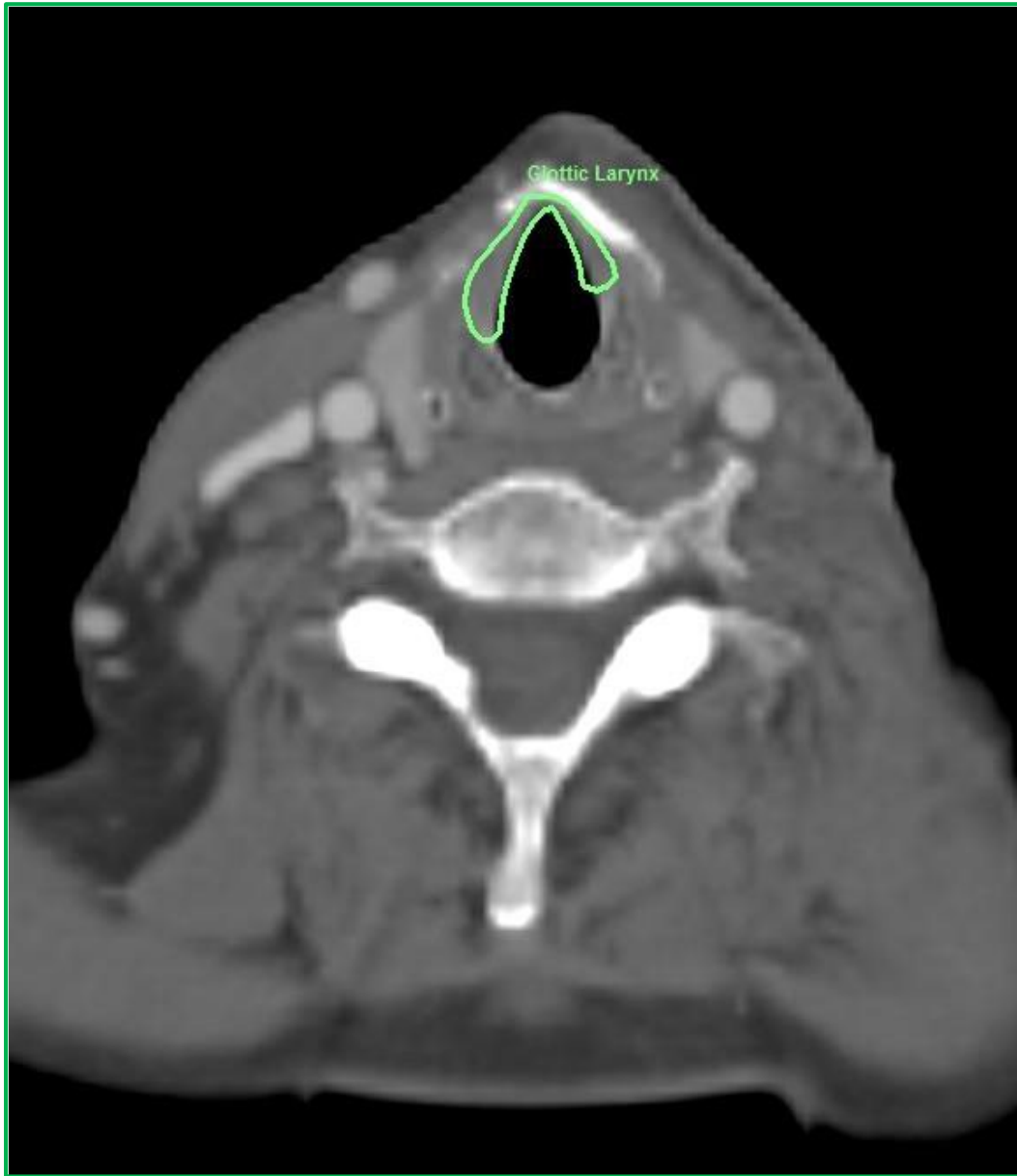




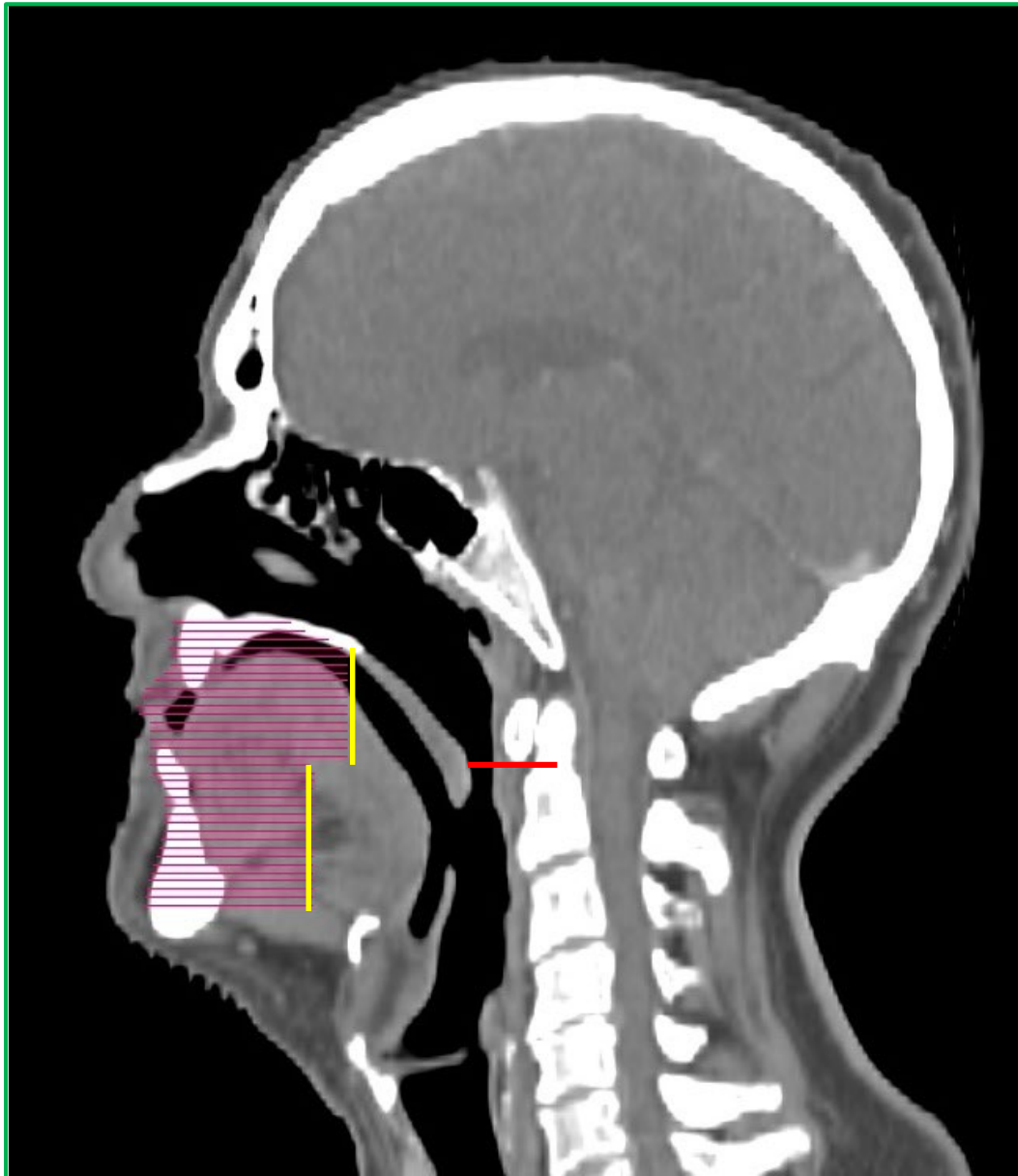




## Glottic Larynx - Caudal Boundary



## Oral Cavity - Posterior Boundary on Sagittal Slice



Posterior border ( Yellow line) is

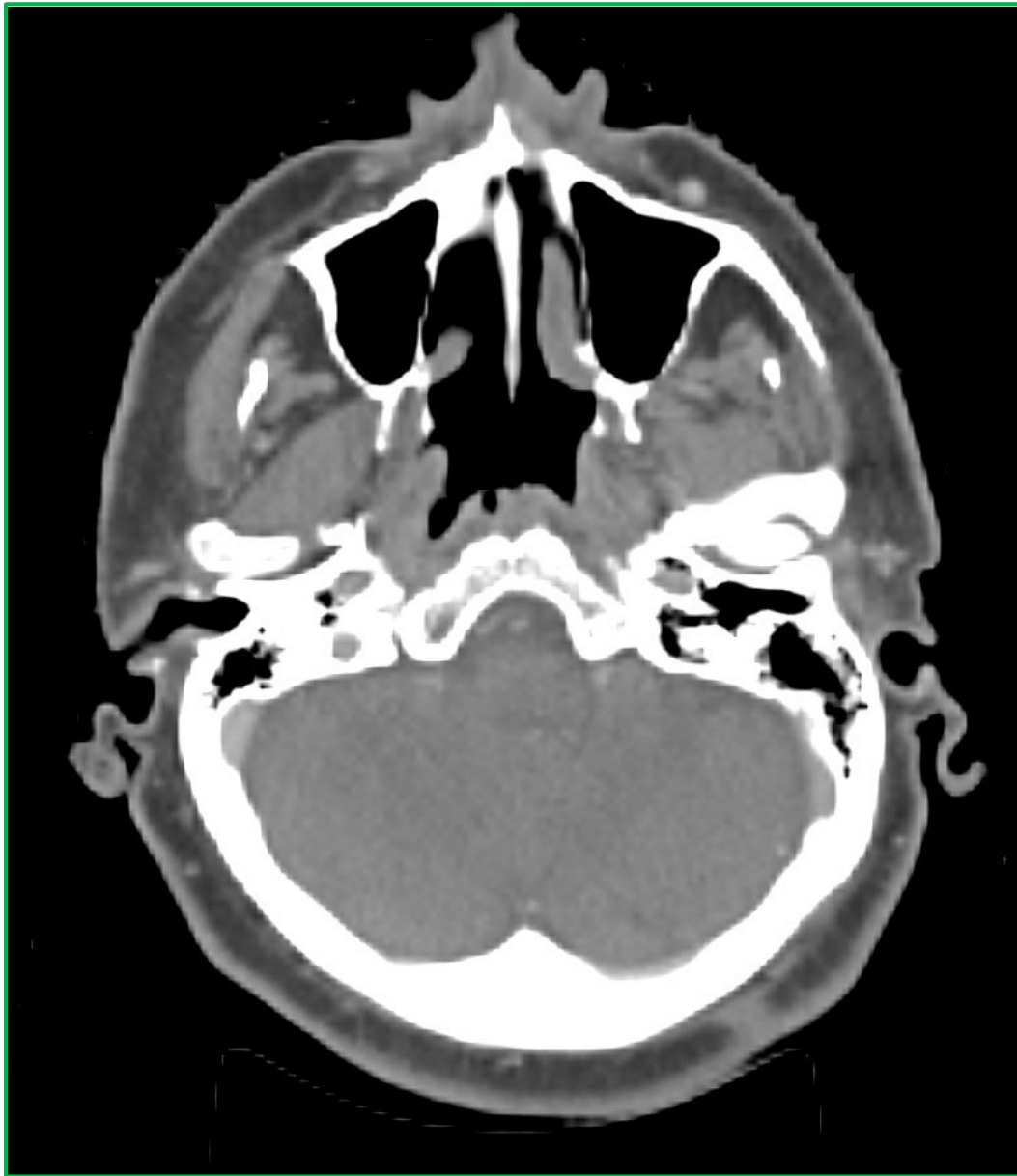1. Anterior to soft palate from superior border of oral cavity to bottom of C1 (Red line)

and

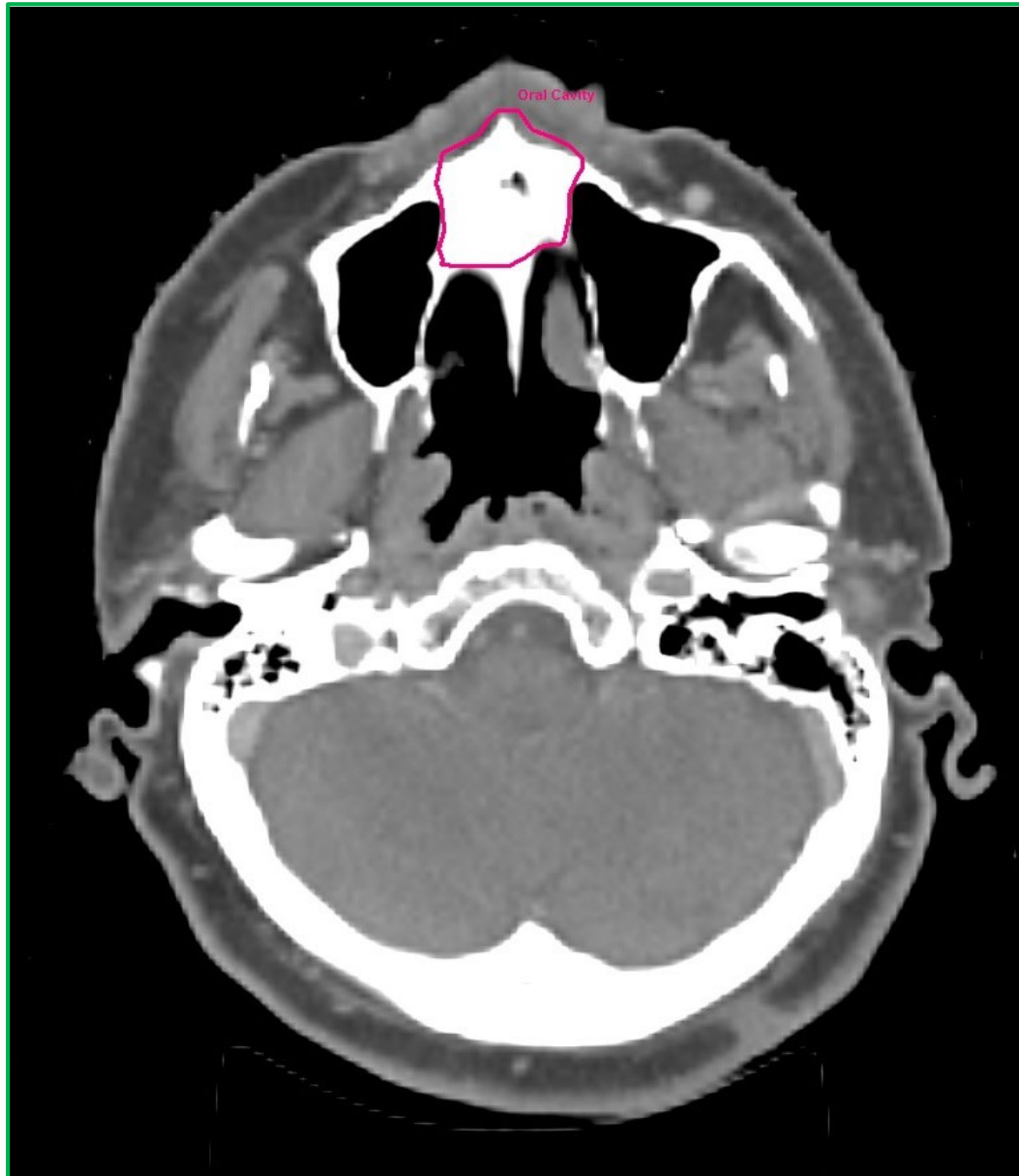2. Anterior to tongue base from bottom of C1 to inferior border of oral cavity



## Slice above Cranial Boundary of Oral Cavity

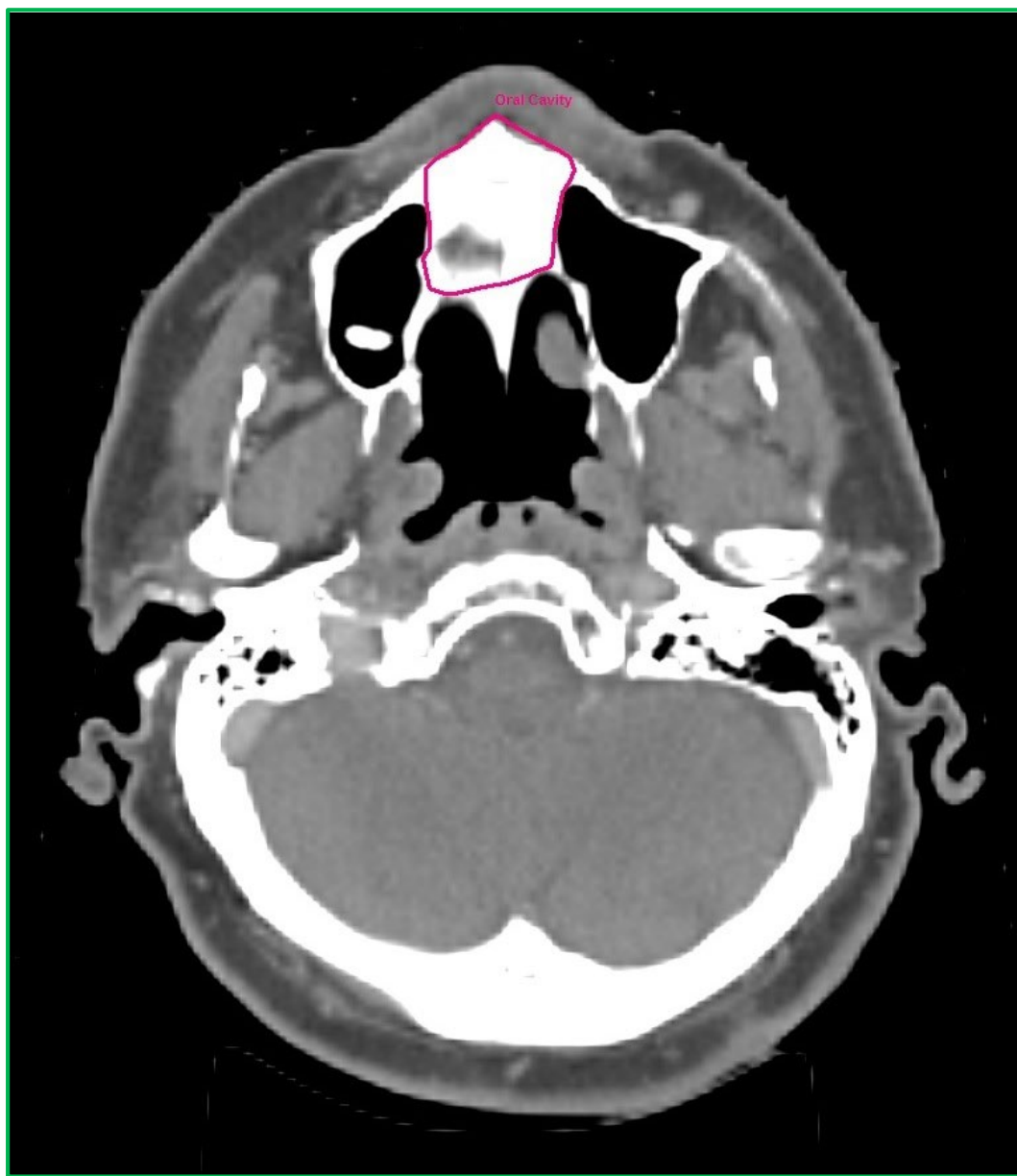

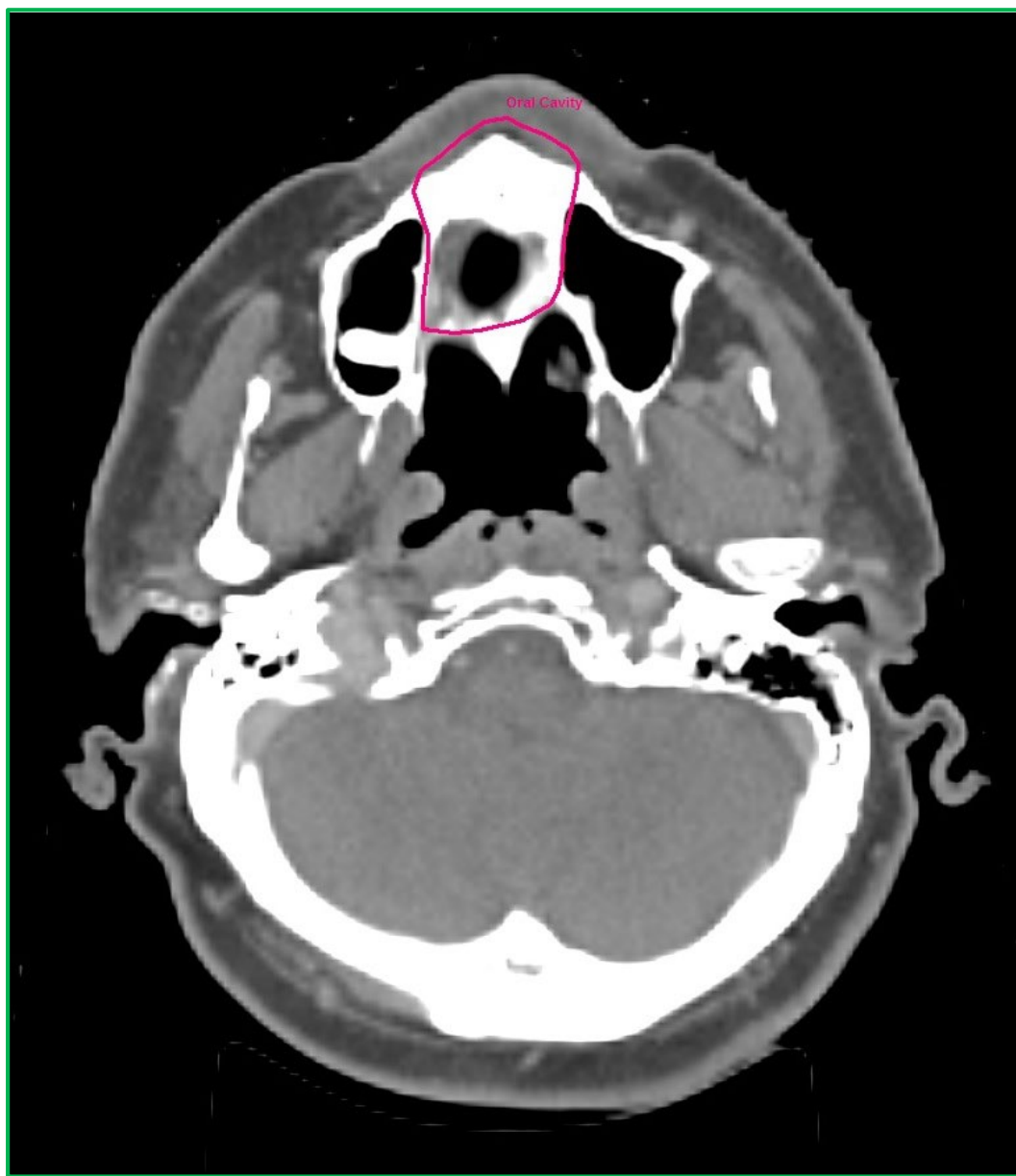
# Oral Cavity - Cranial Boundary

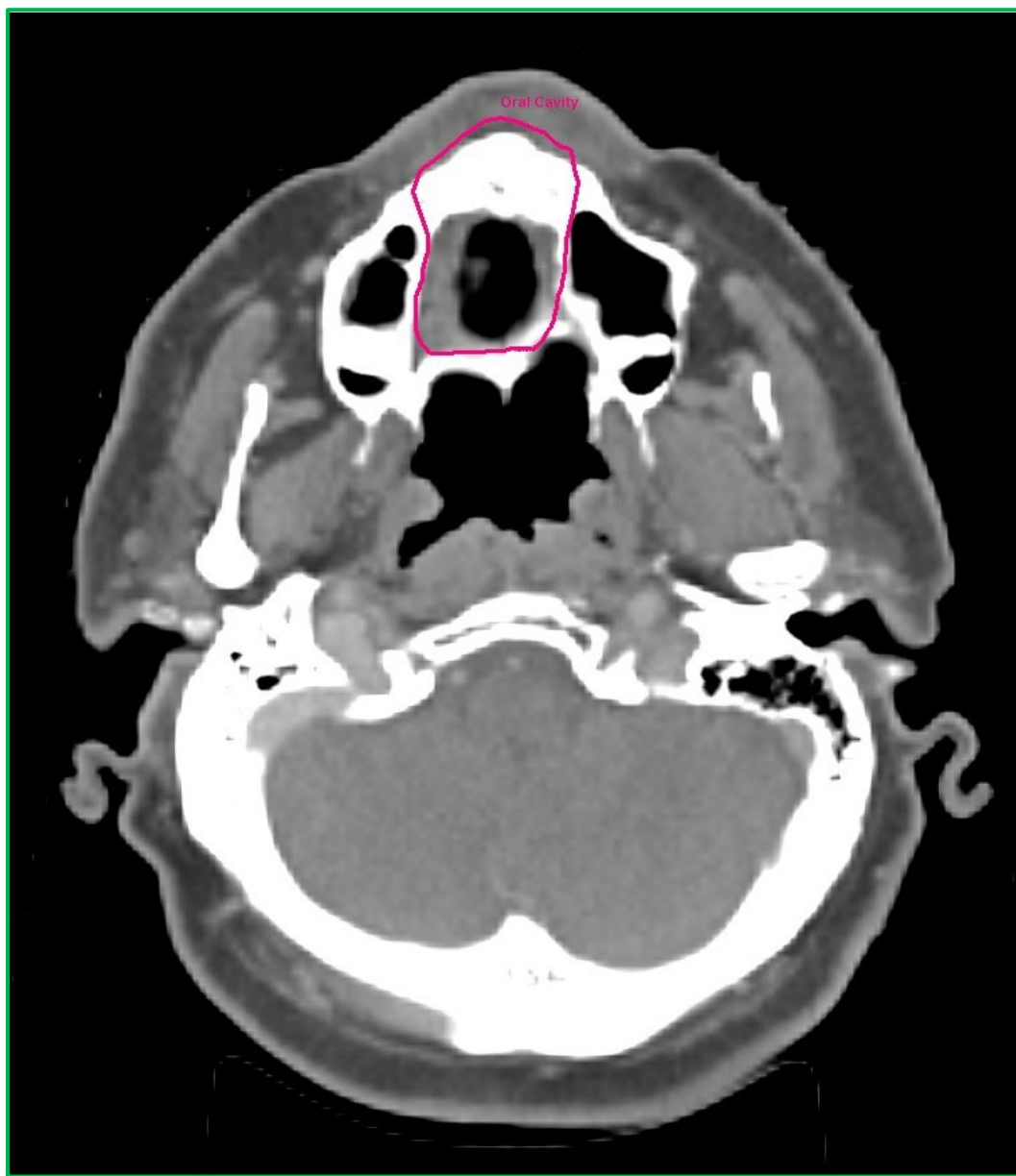


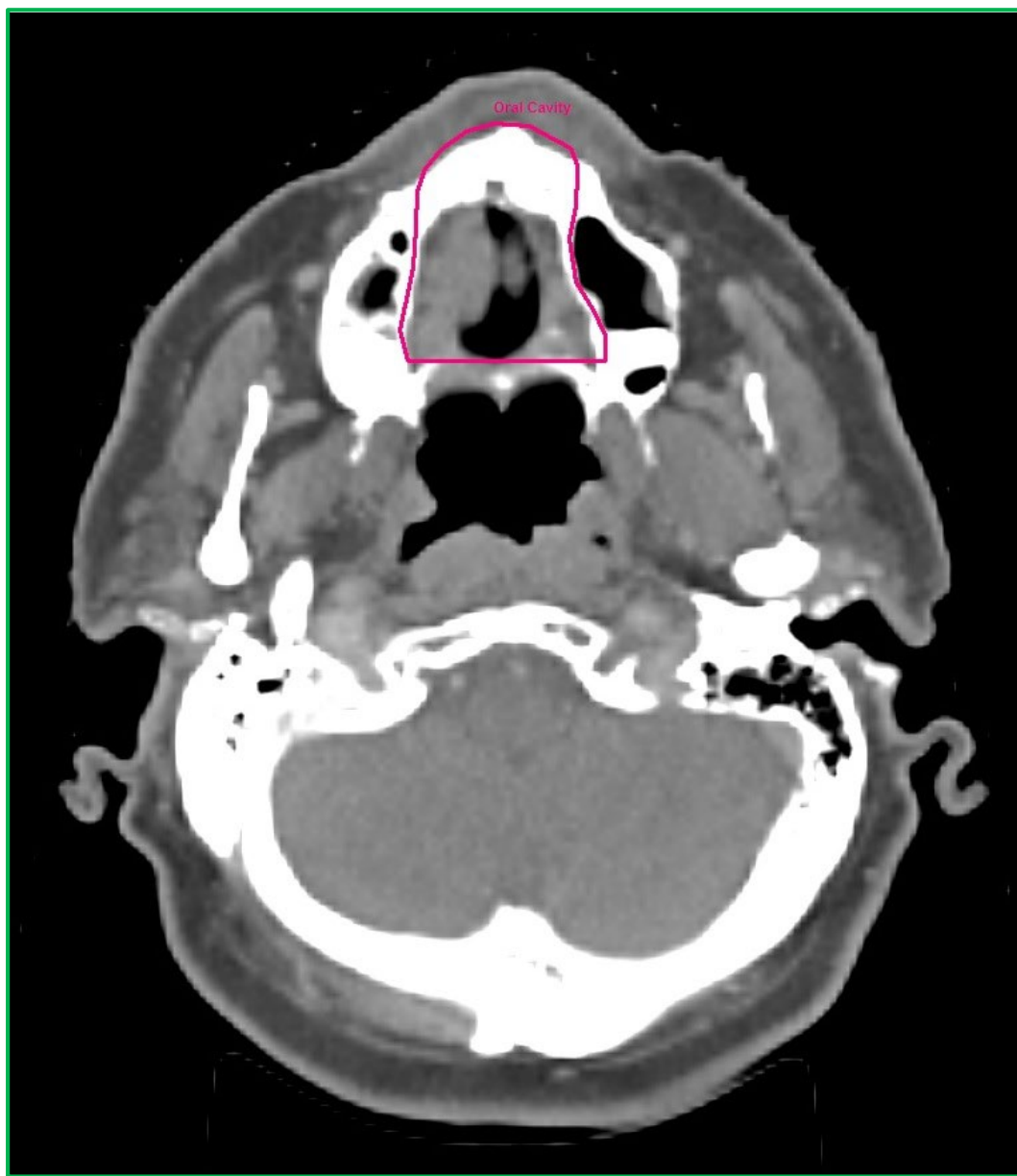
<b>Cranial</b>	<b>Upper edge of hard palate</b>
<b>Caudal</b>	<b>First slice cranial to superior border of Level Ia/ Insertion of Platysma/ First slice of hyoid</b>
<b>Anterior</b>	<b>Buccal surface of Maxilla/ Mandible/ Teeth</b>
<b>Posterior</b>	<b>Anterior to soft palate up to bottom of C1 superiorly &amp; Anterior to tongue base inferiorly</b>
<b>Lateral</b>	<b>Medial edge of maxillary sinus; Medial edge of buccinator; Buccal surface of Maxilla/ Mandible/ Teeth</b>

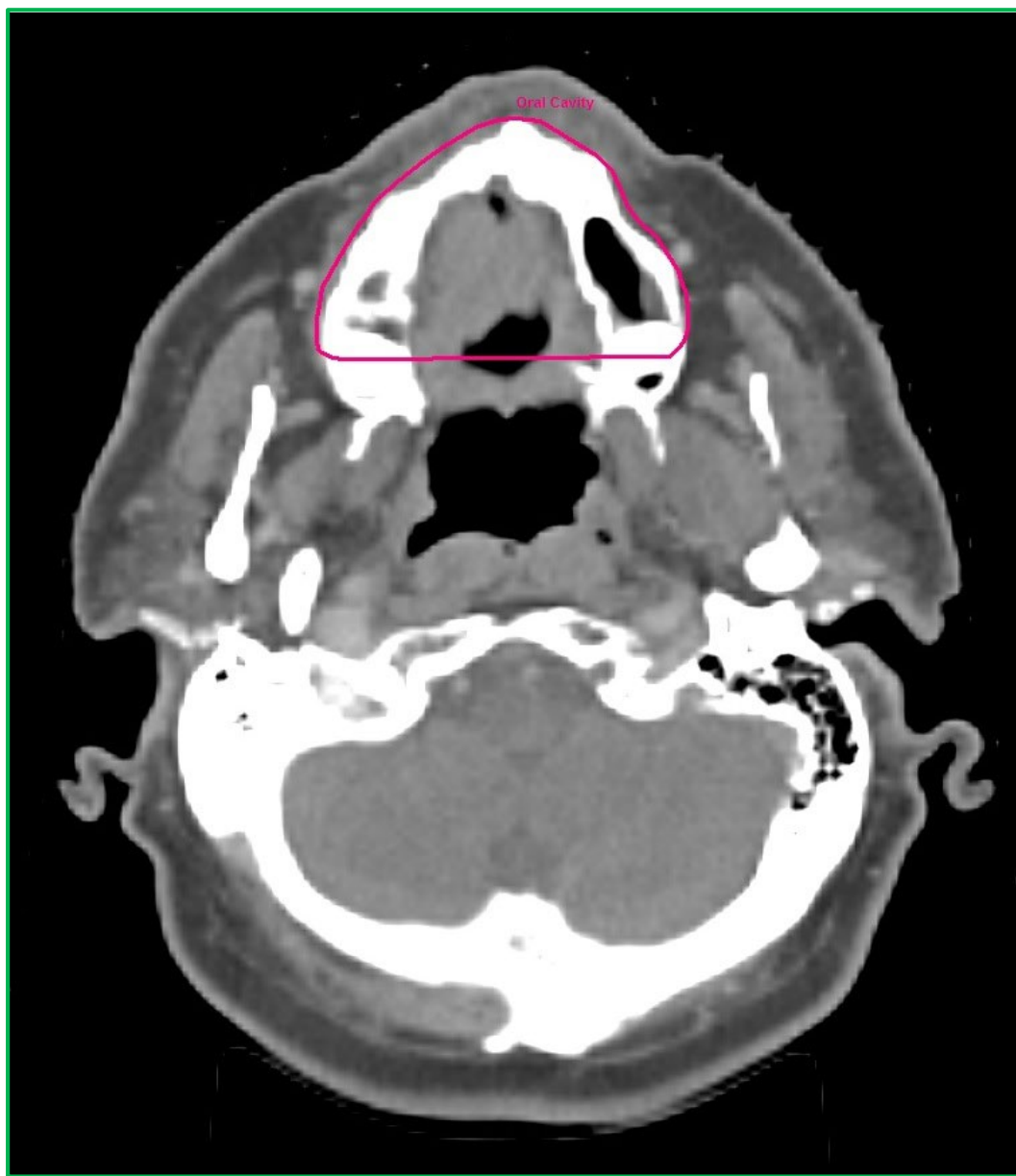
## Oral Cavity Boundaries

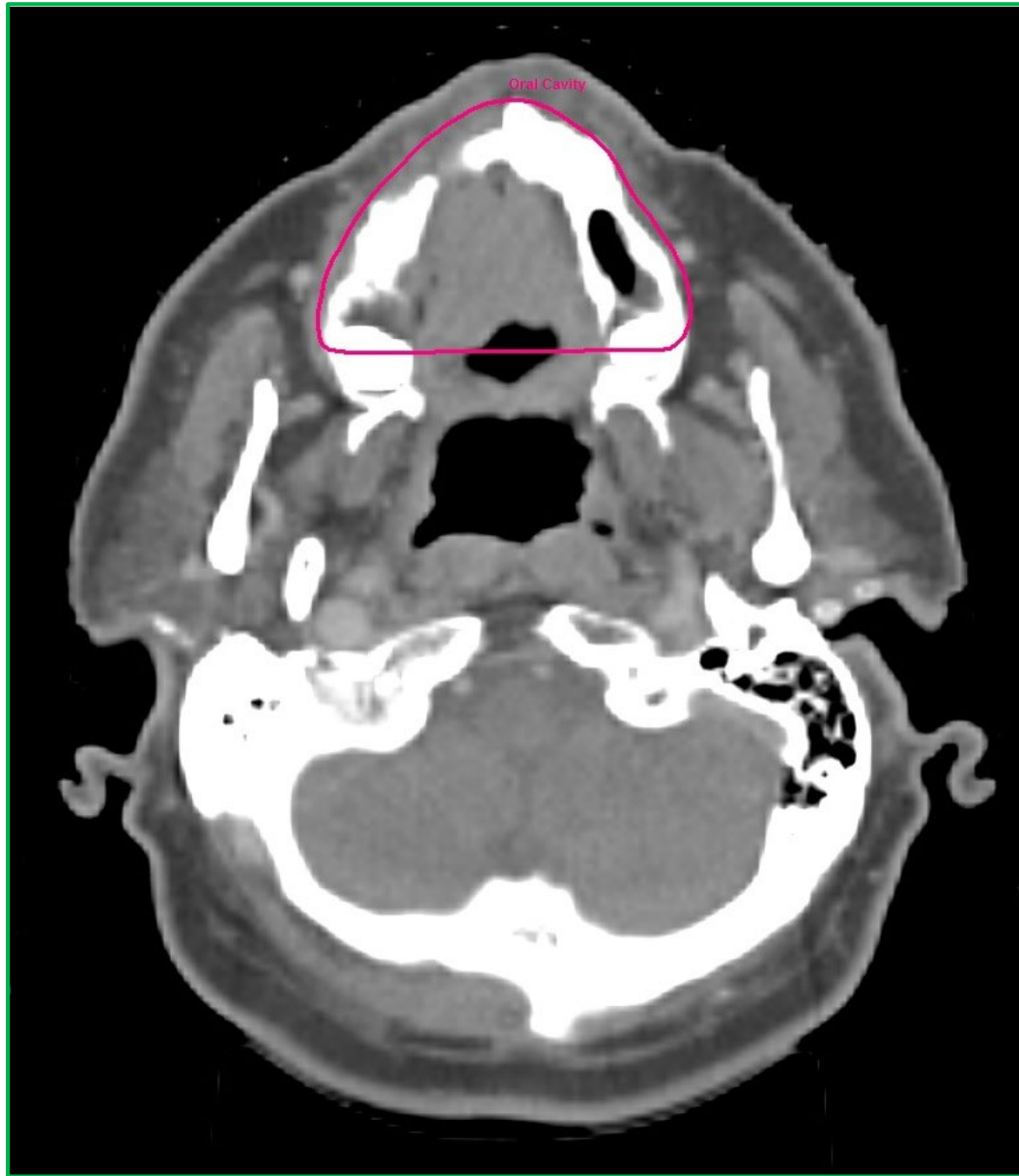




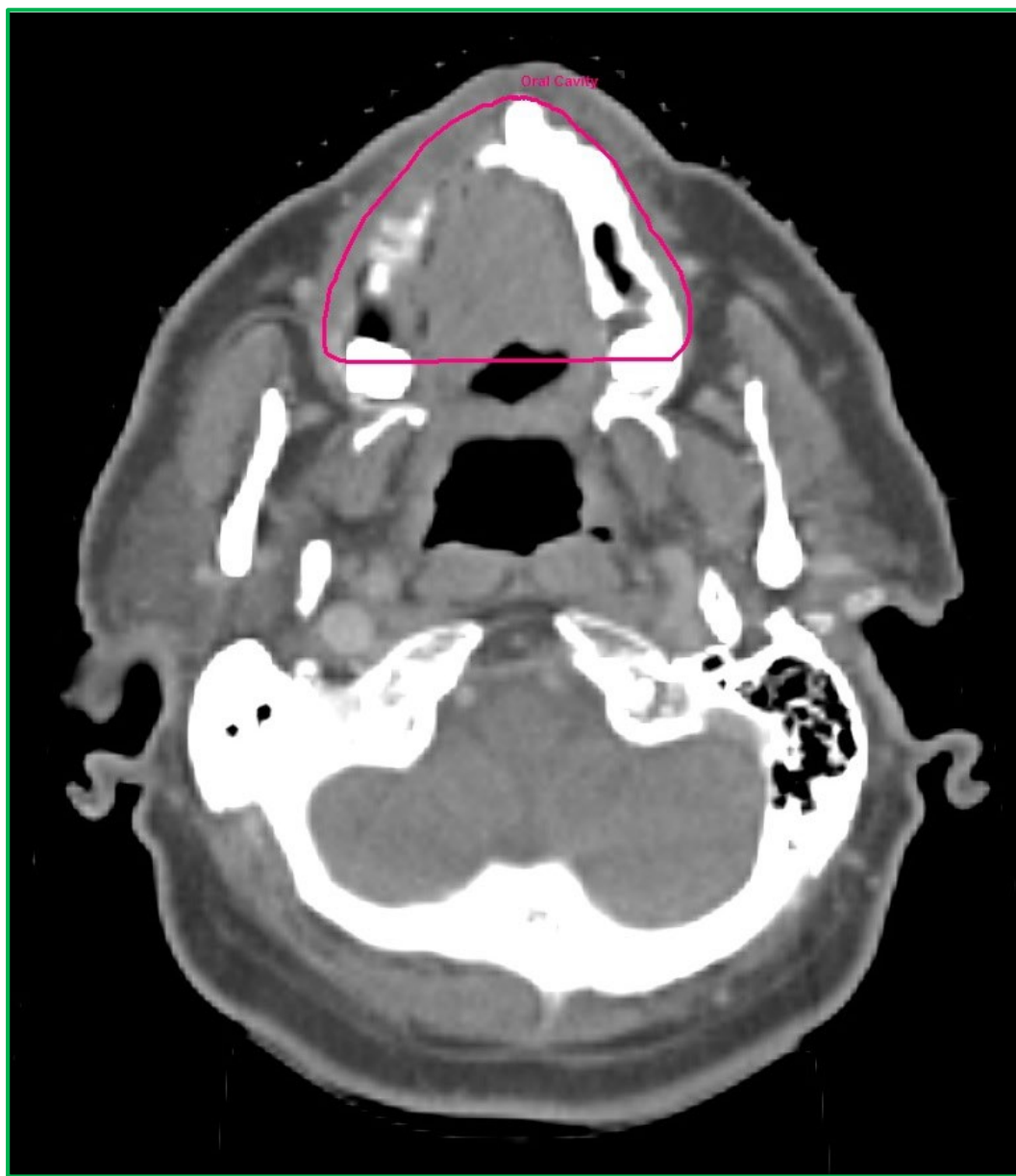




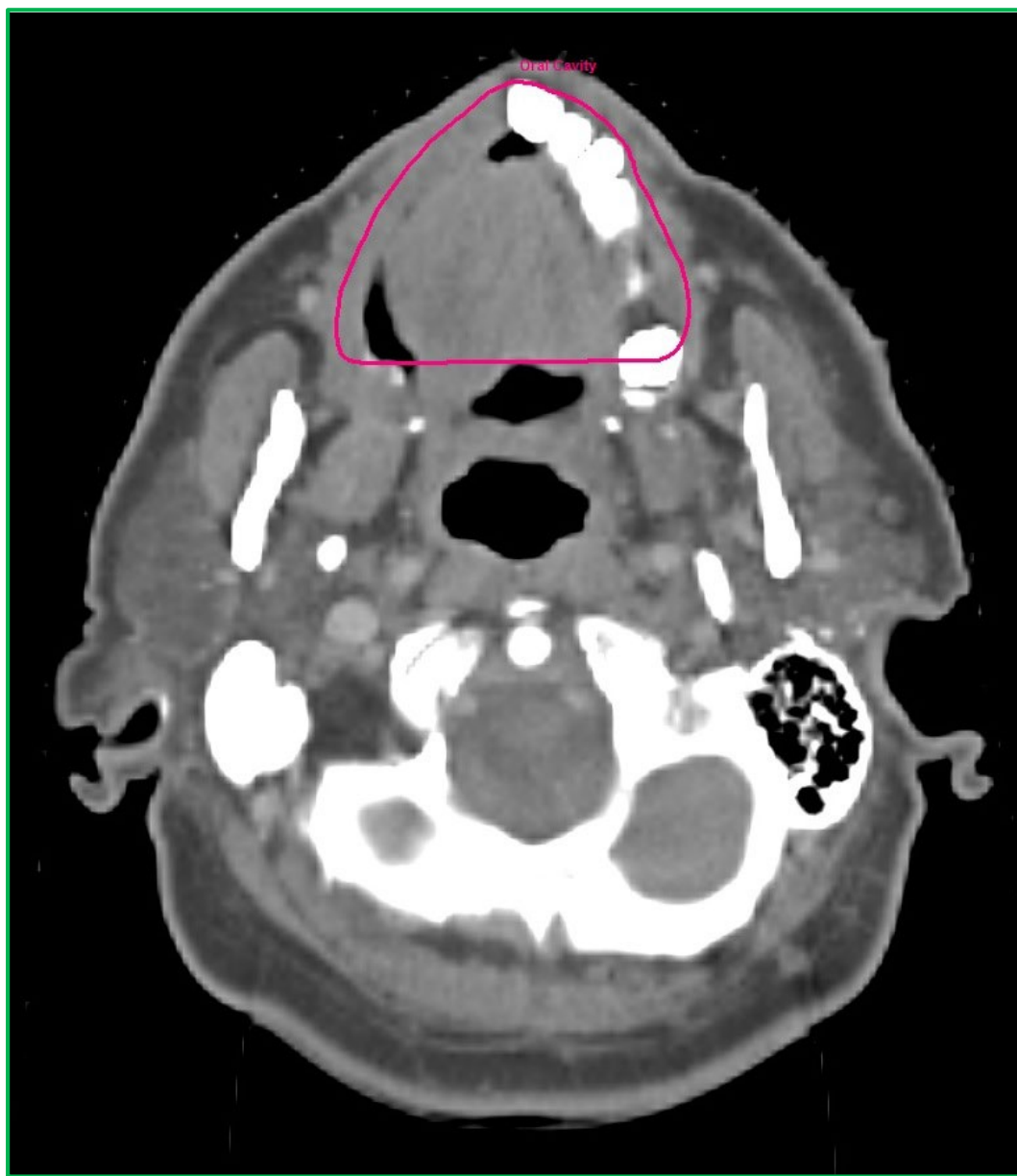


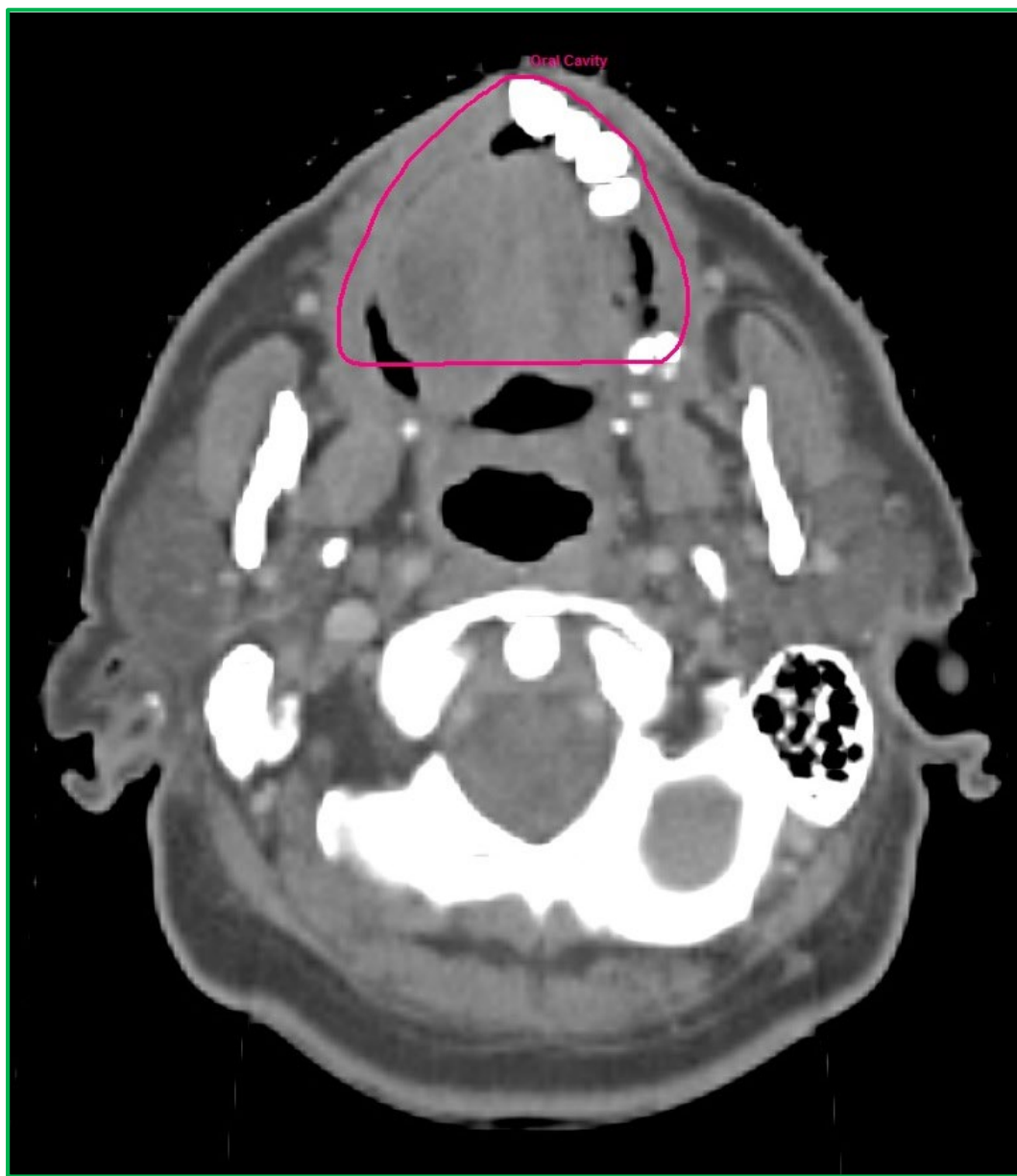


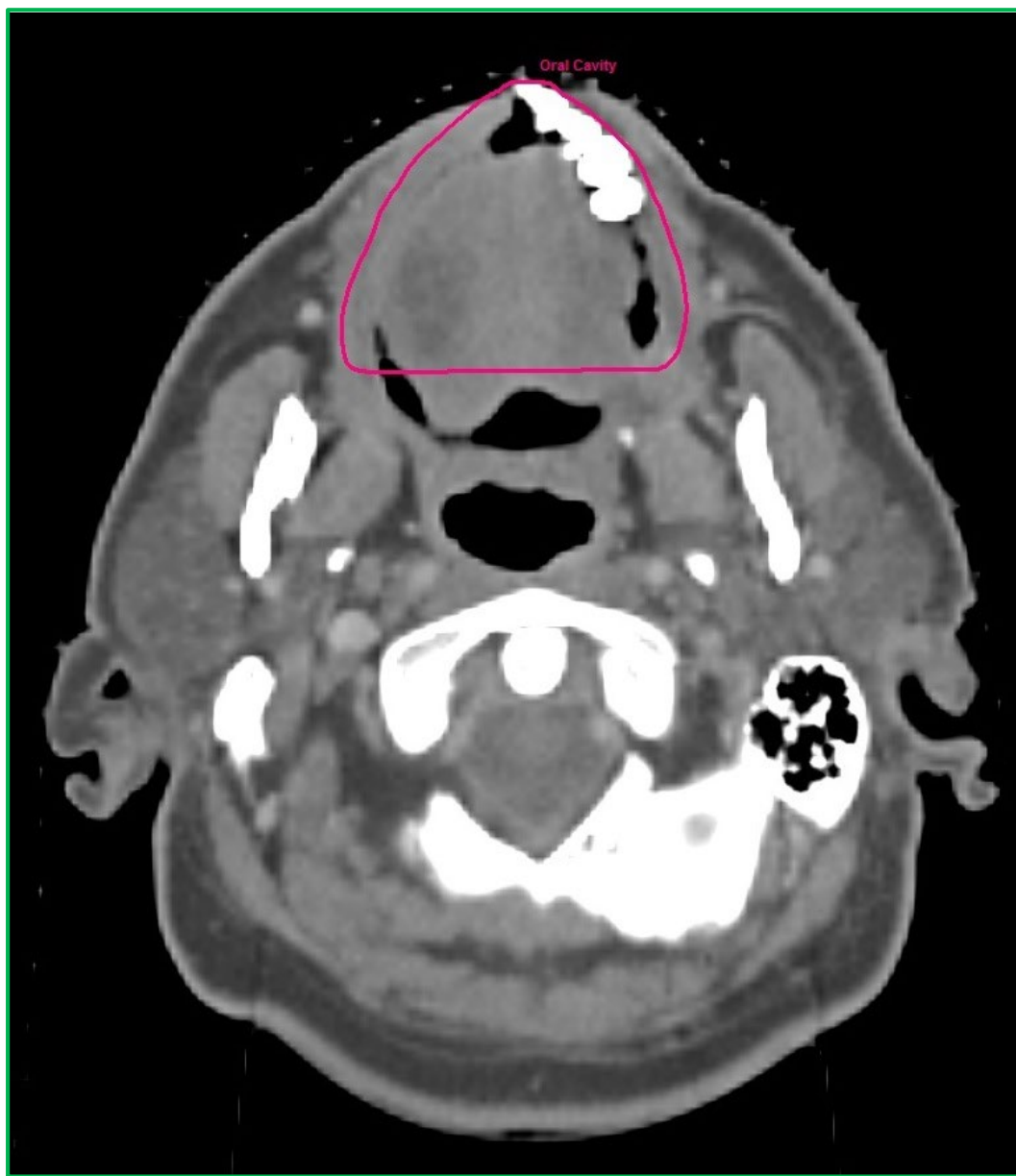


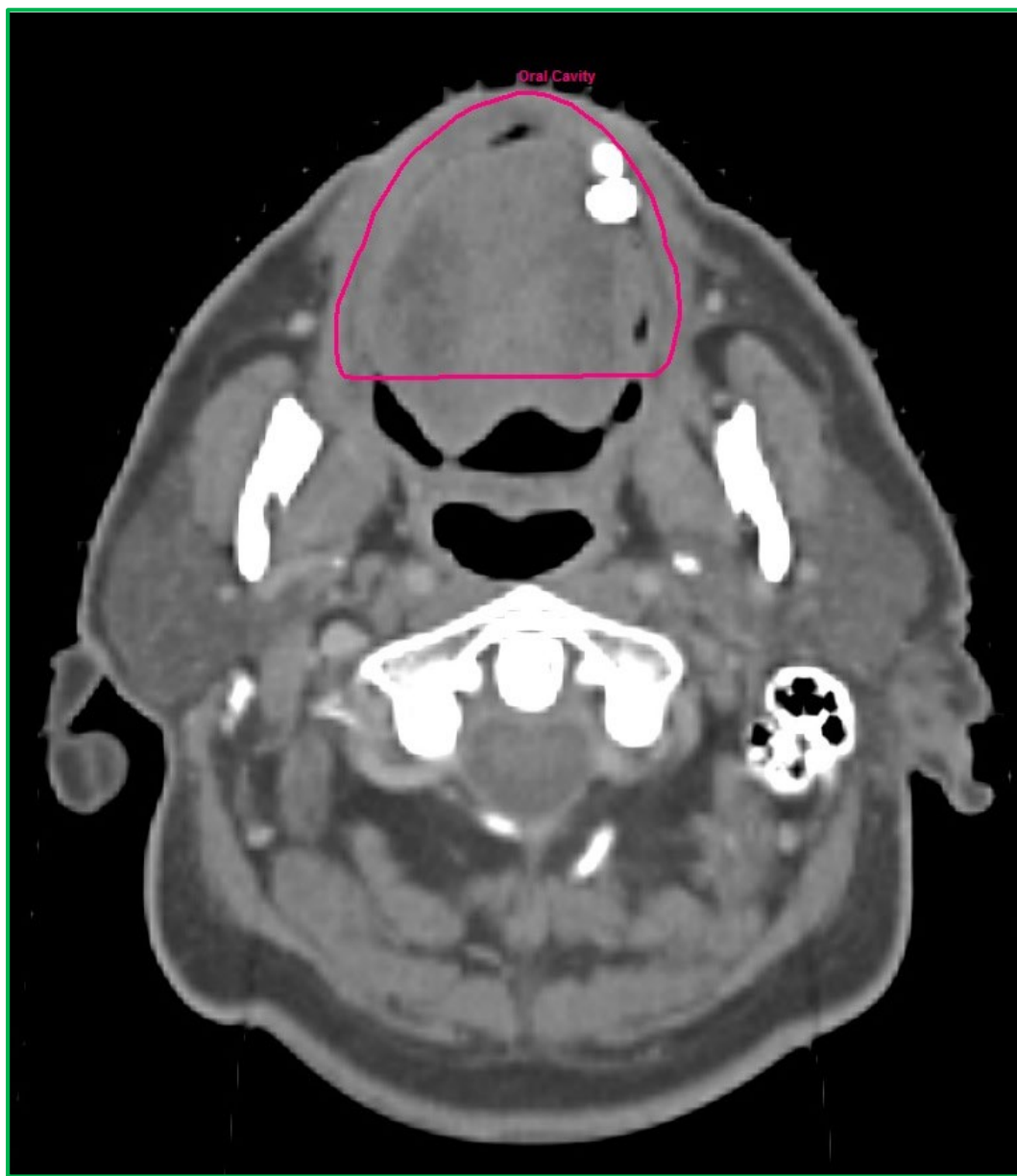


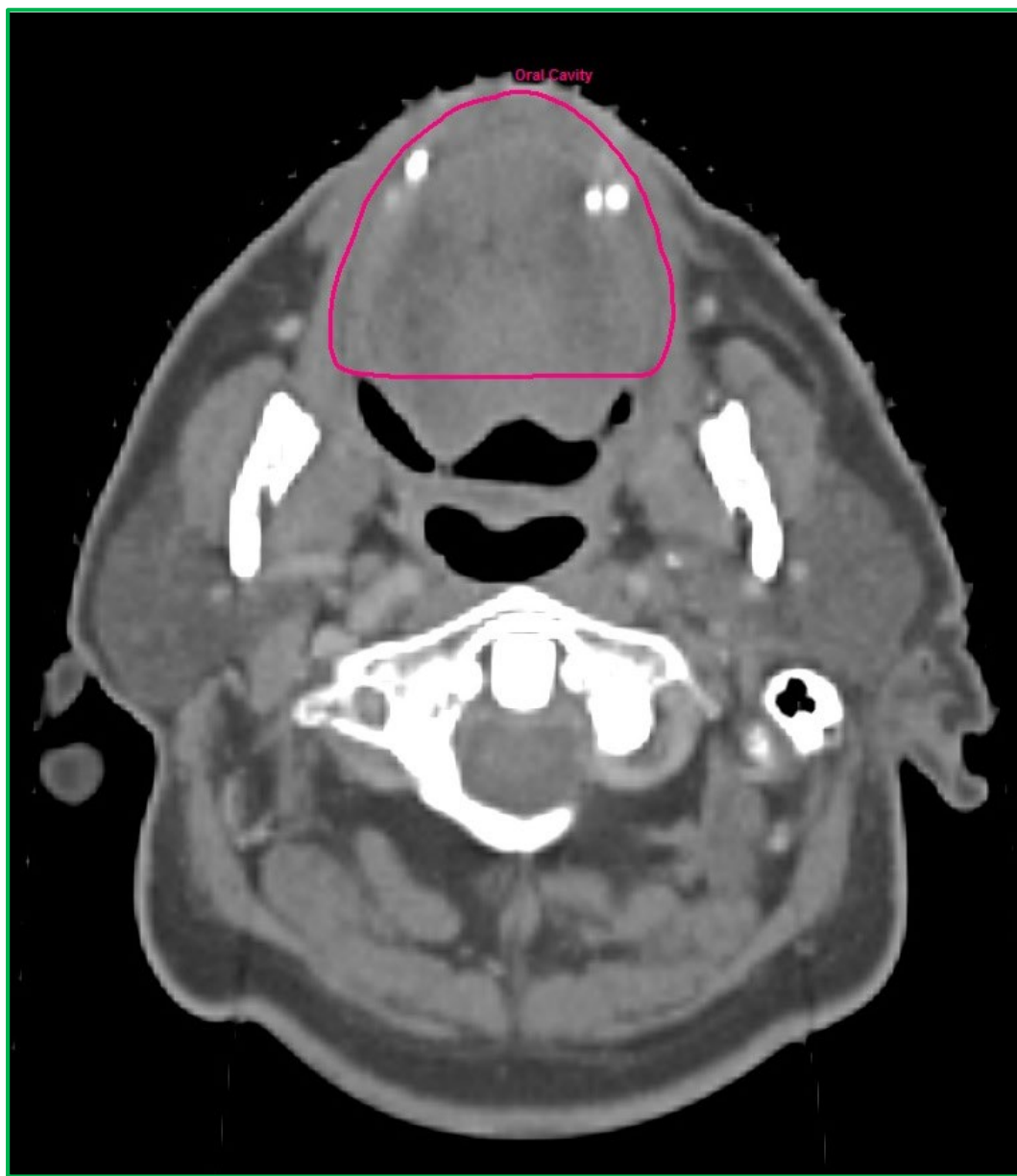
**Red arrow - Buccinator**

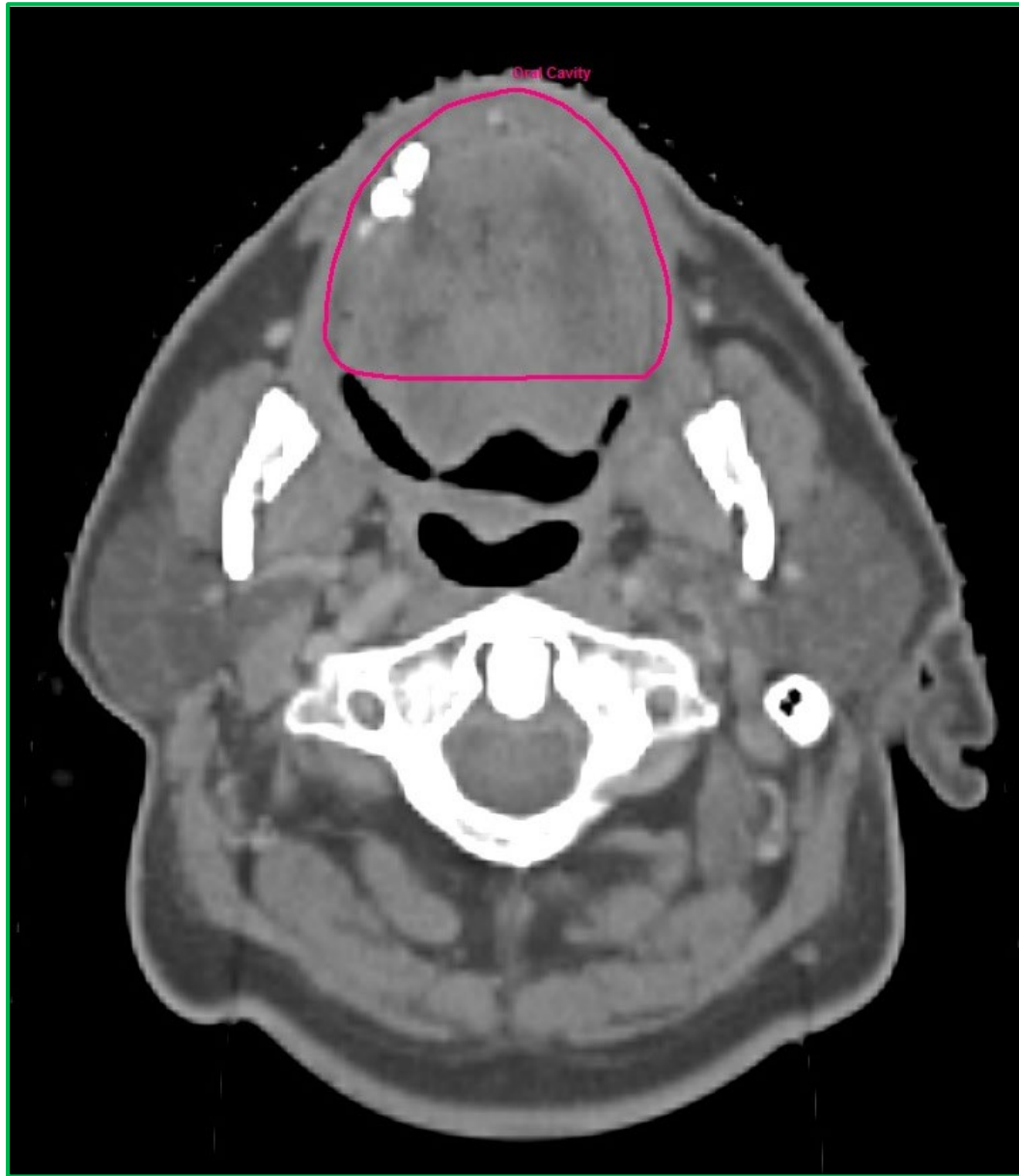




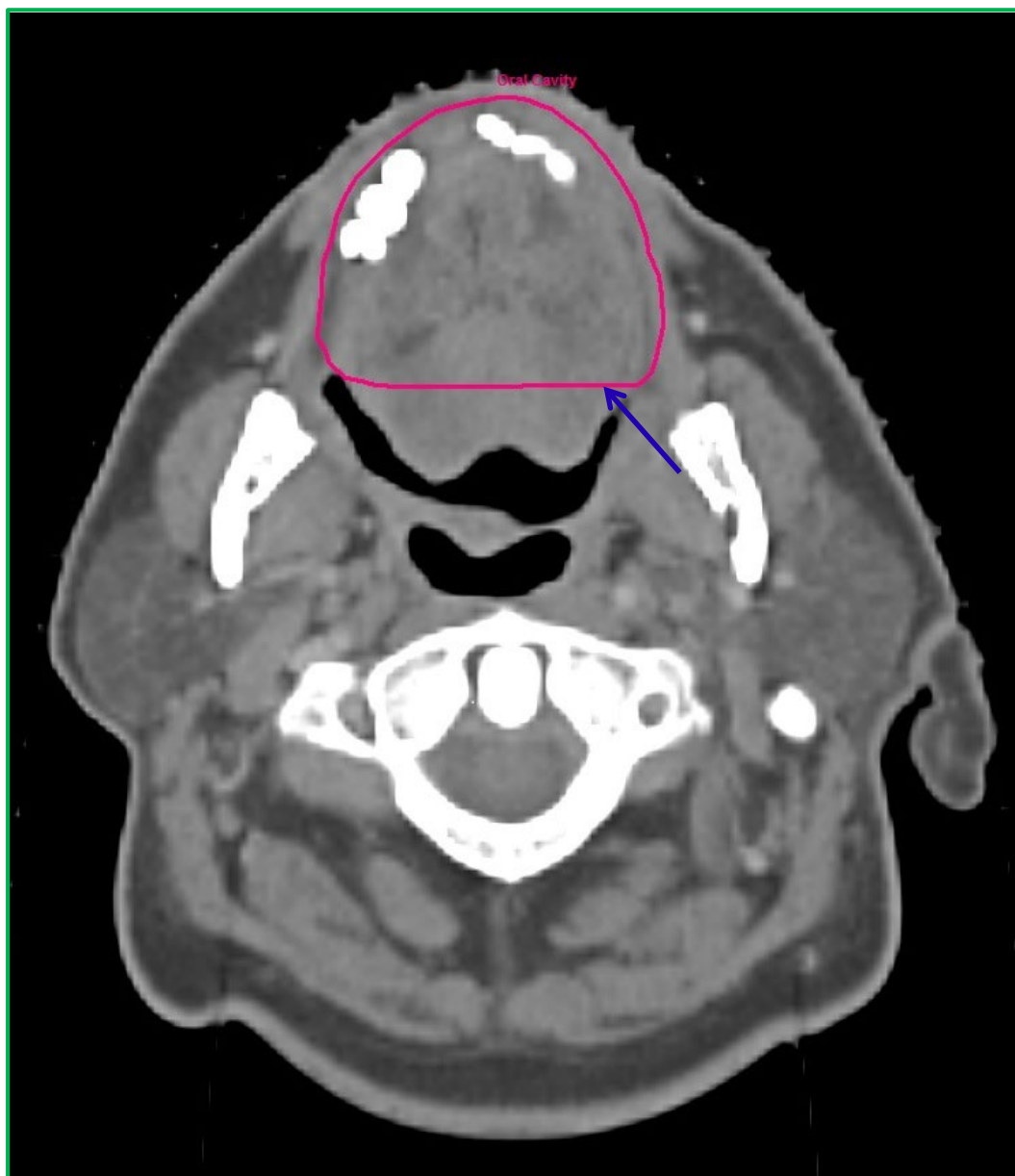




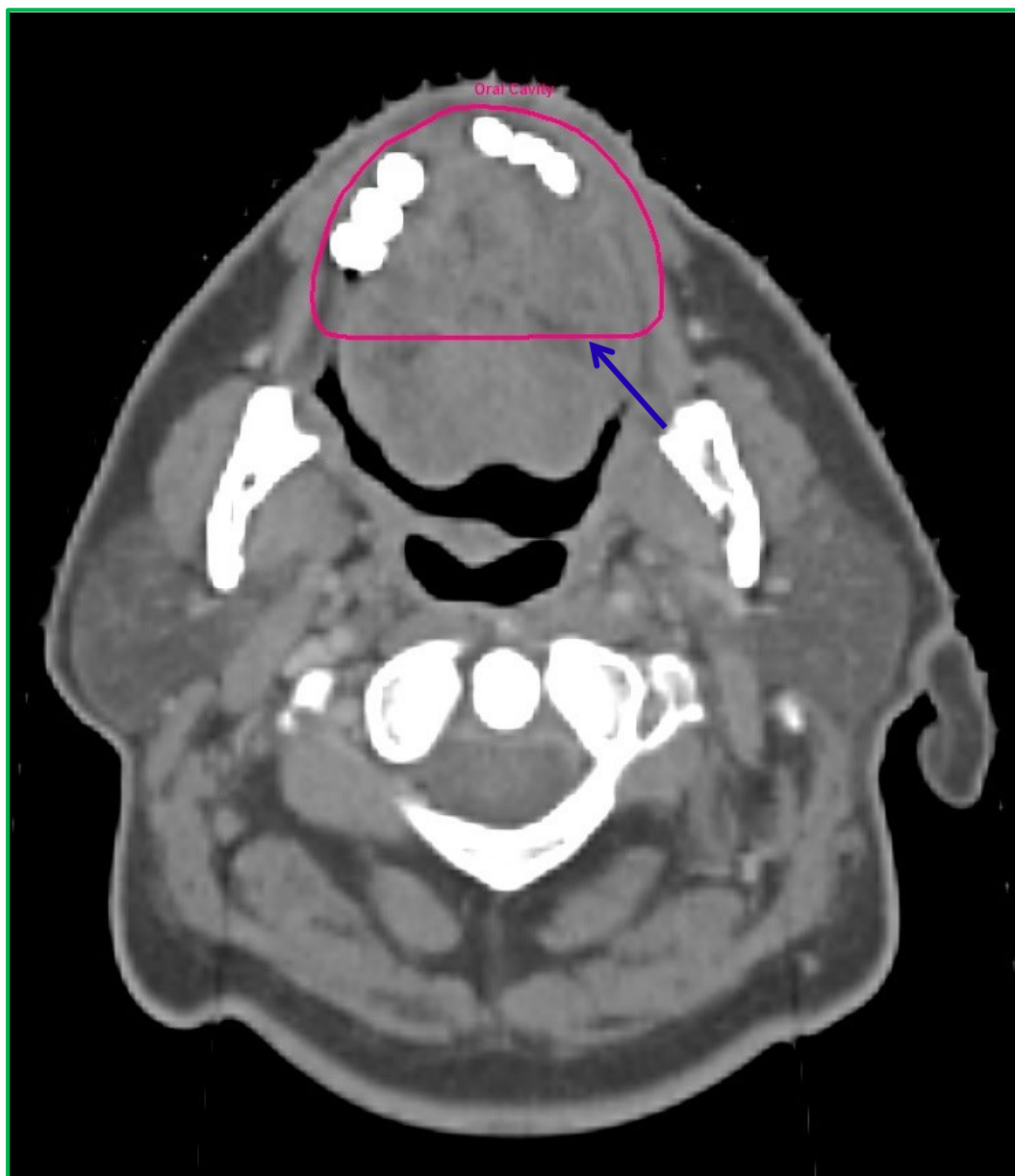




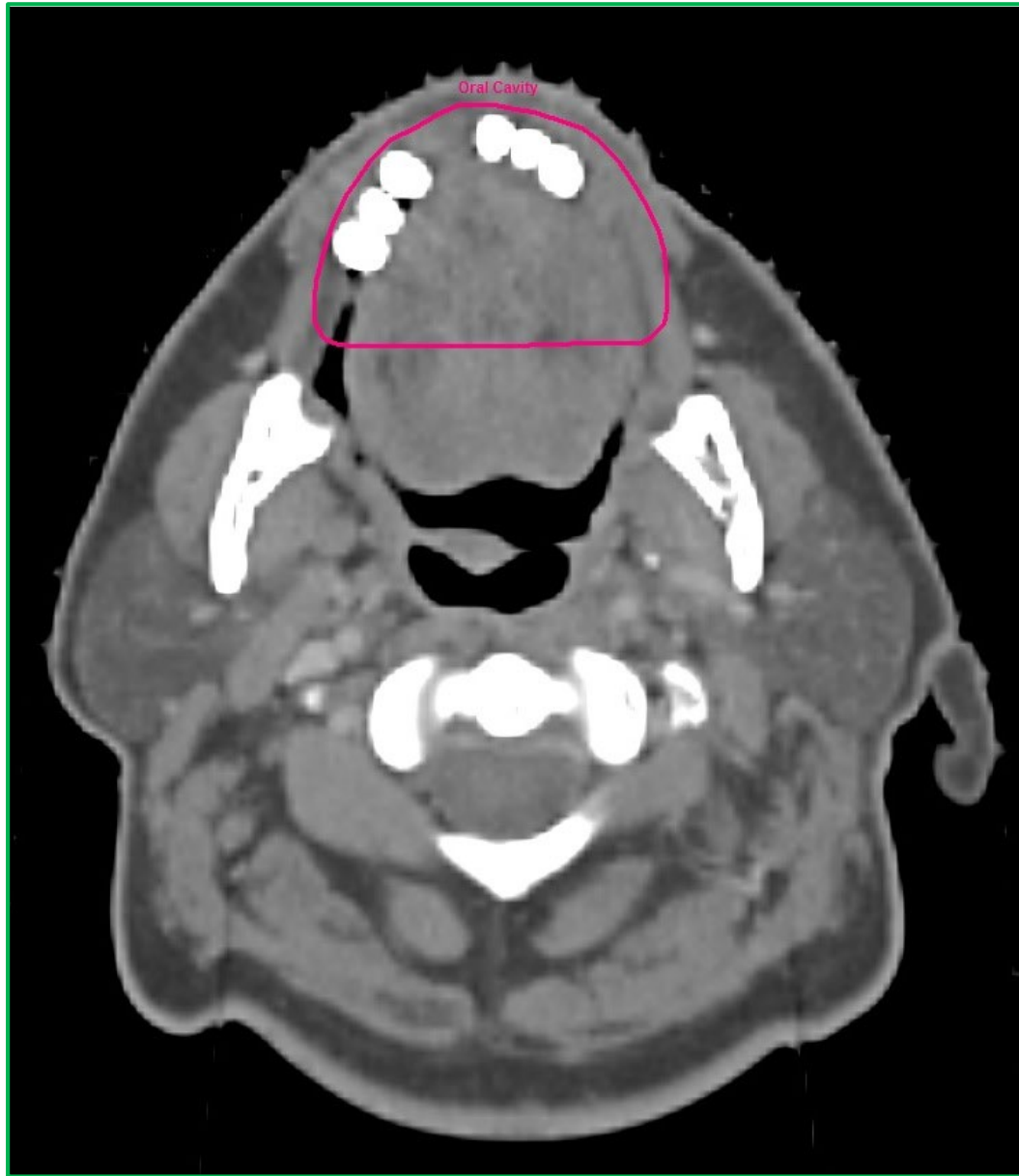


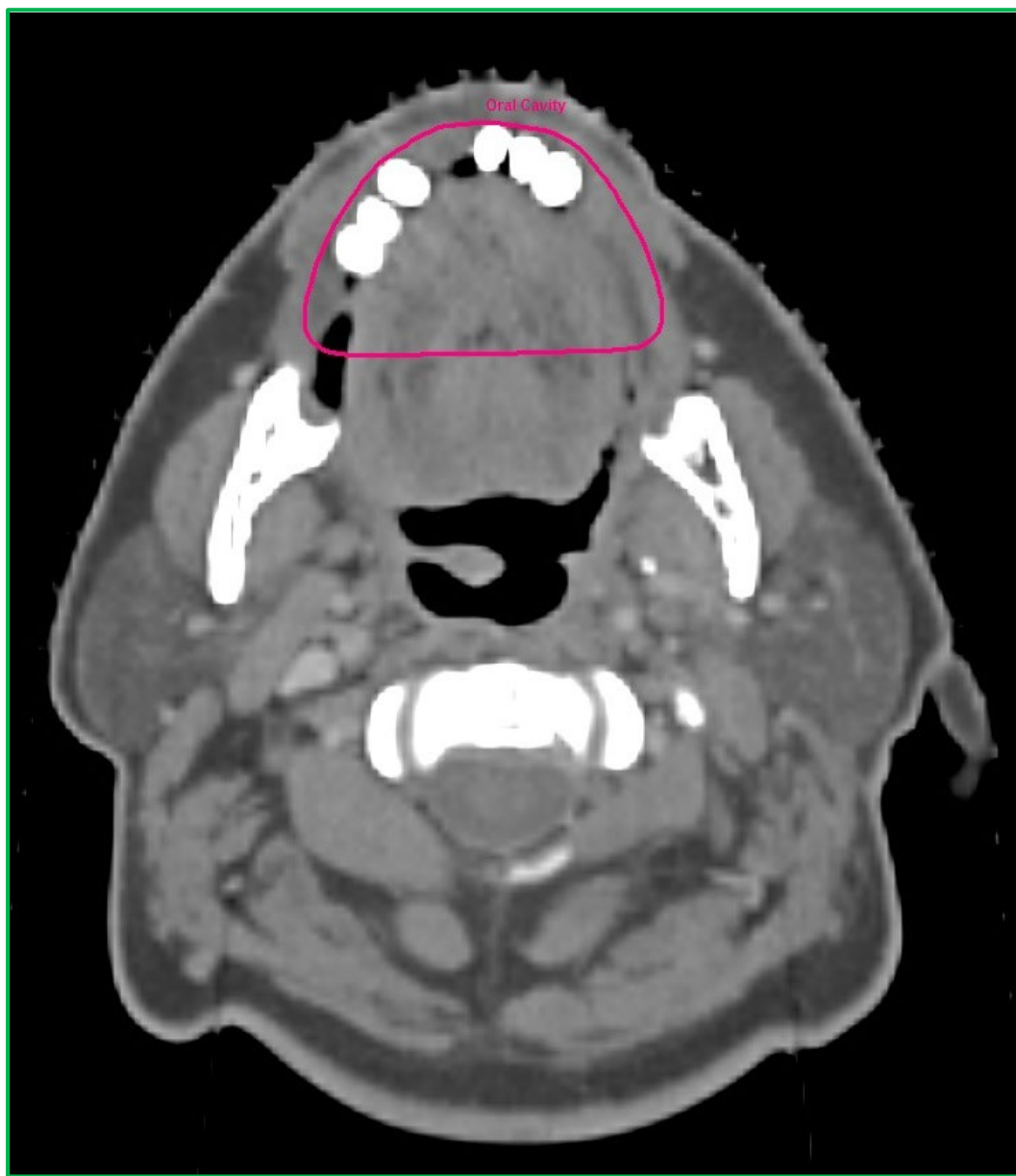


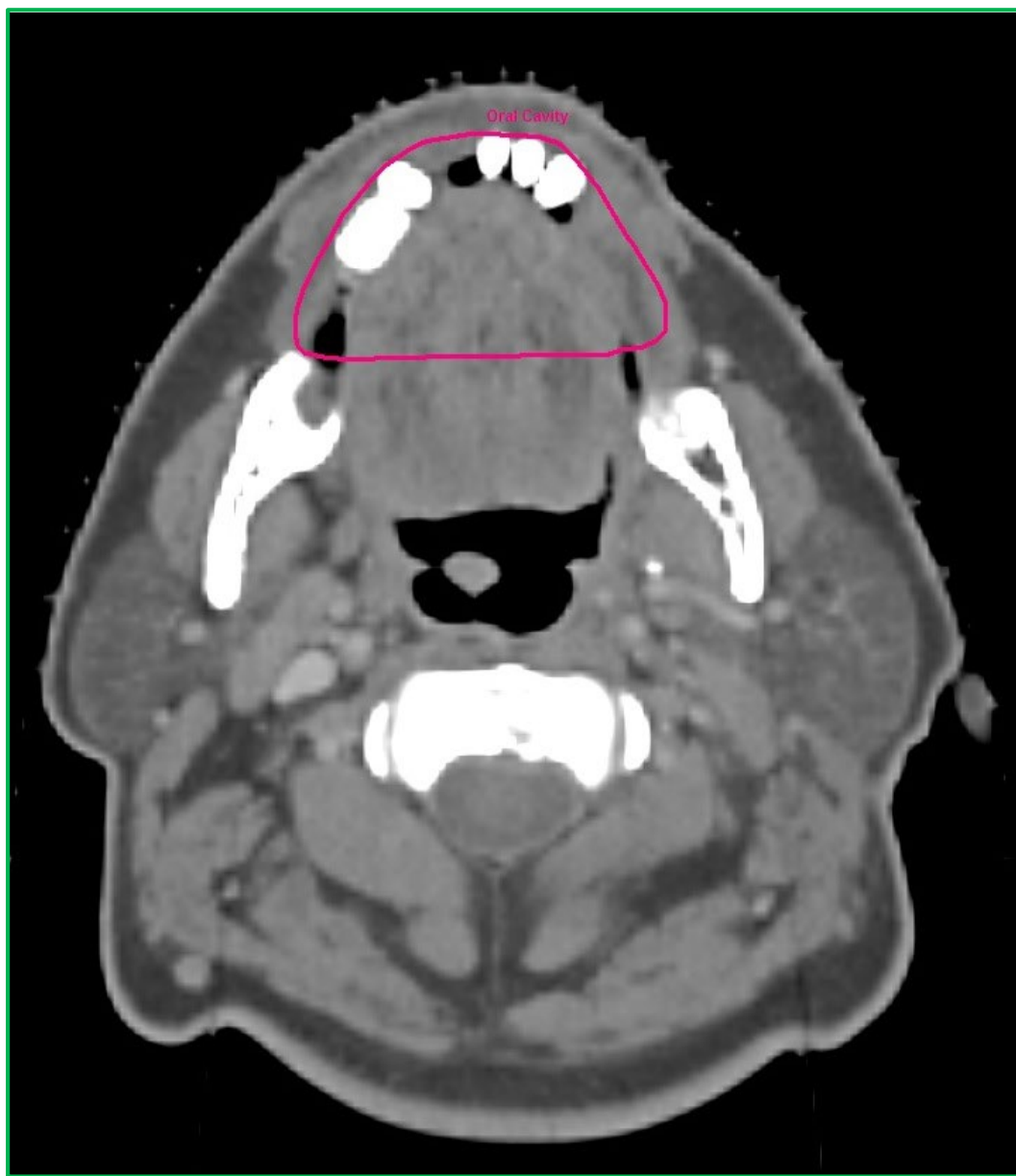
**Blue arrow - Posterior boundary at lower border of C1 is anterior to soft palate**

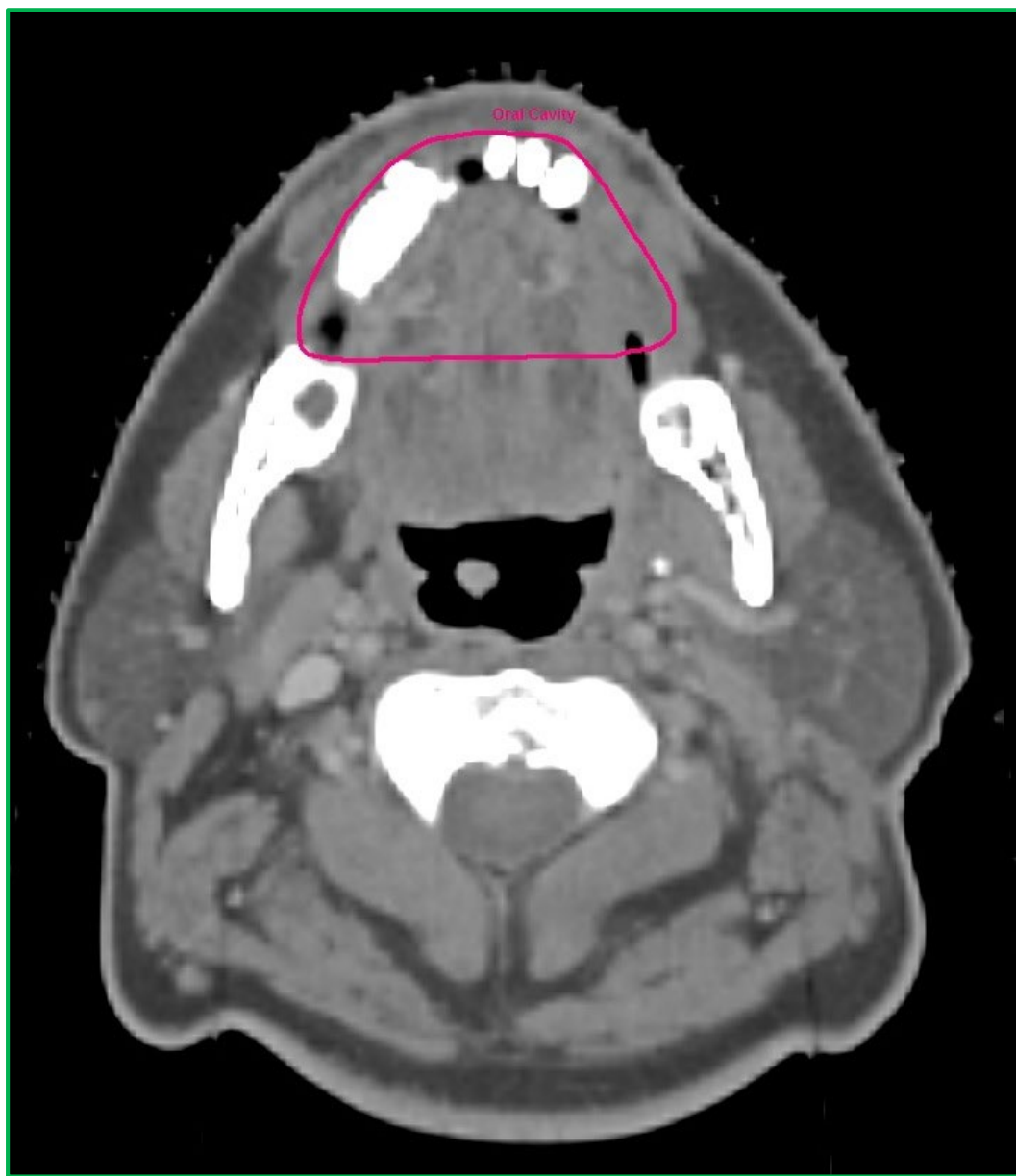


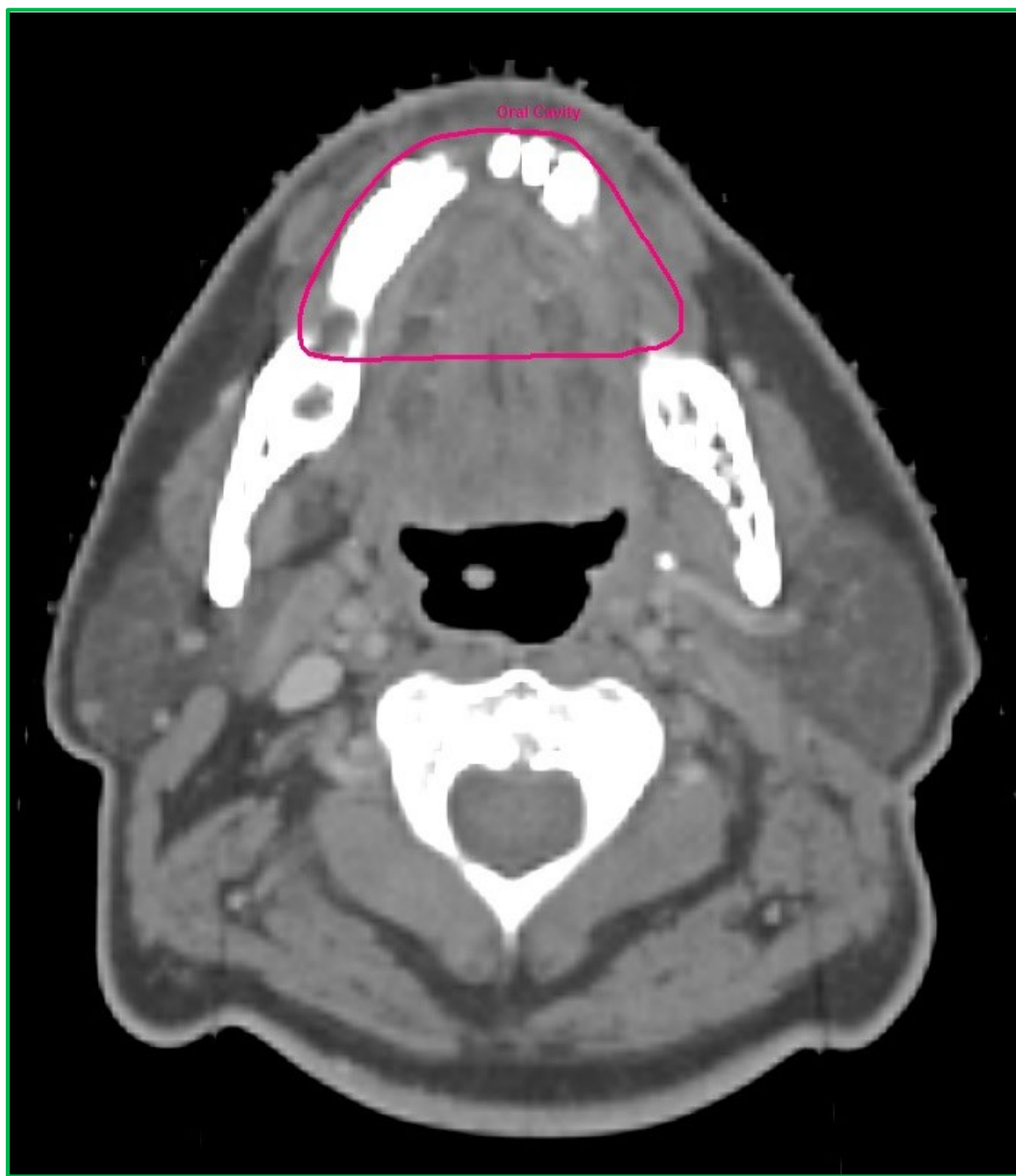
**Blue arrow - Posterior boundary below C1  
is anterior to tongue base**

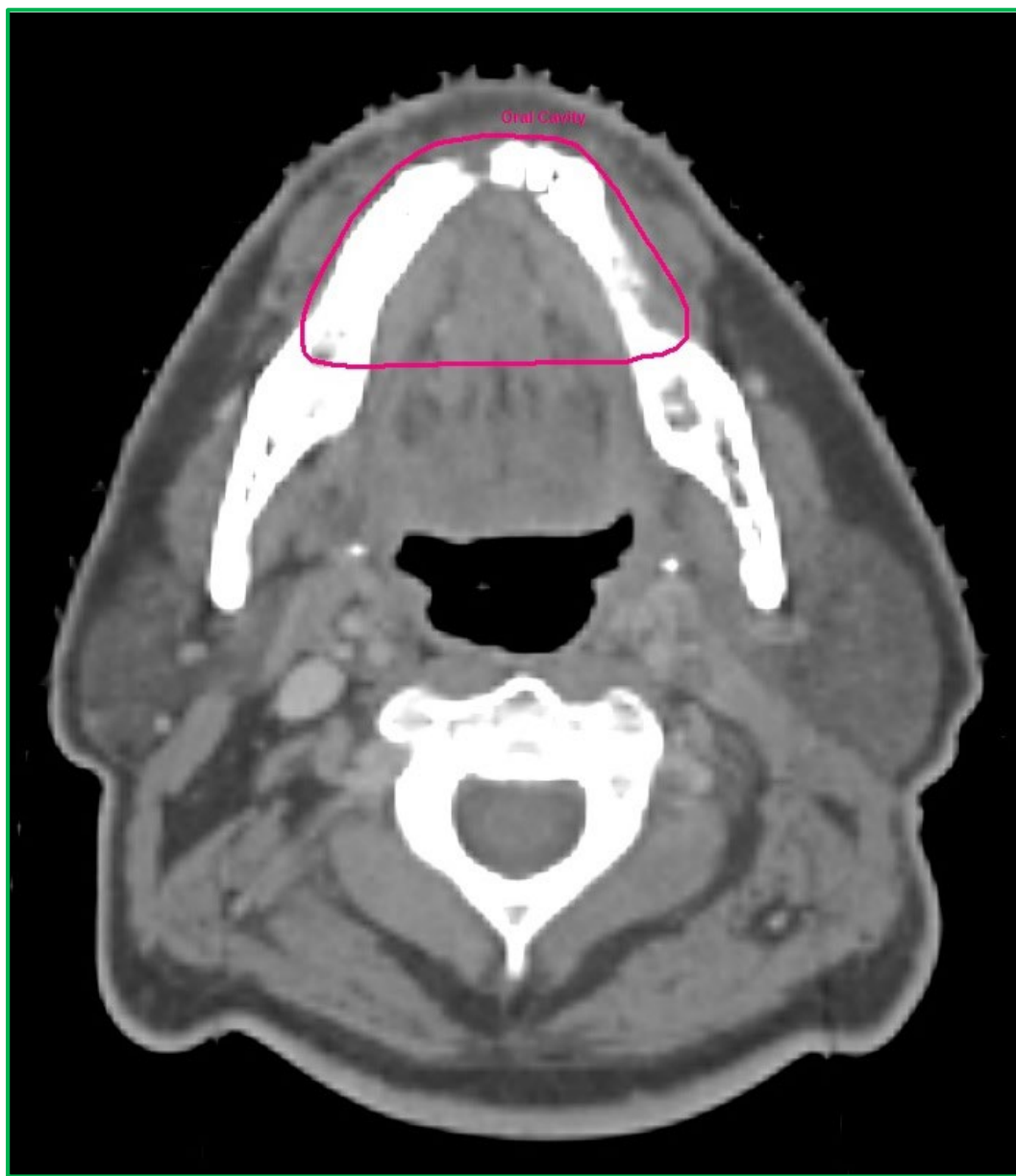



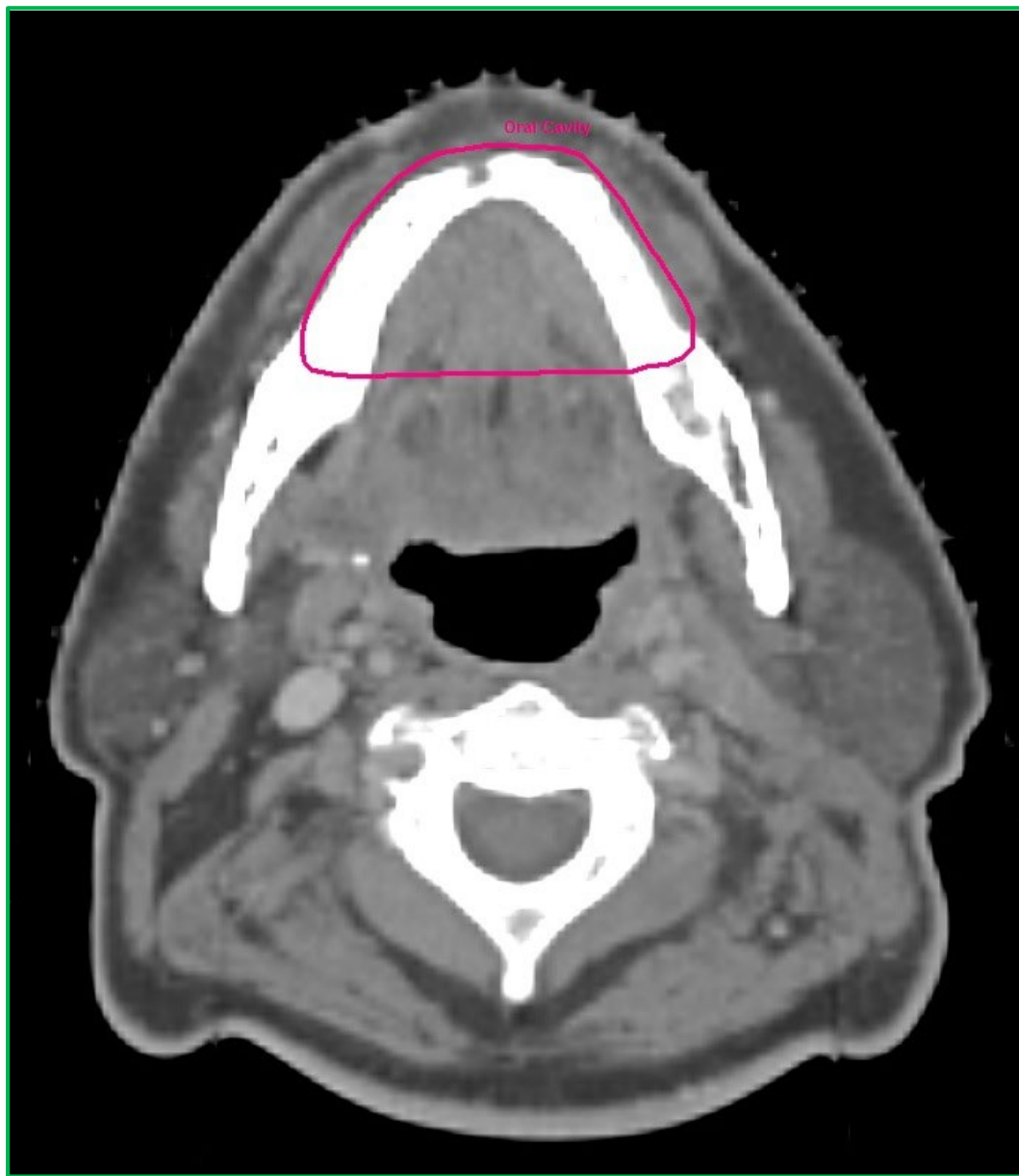


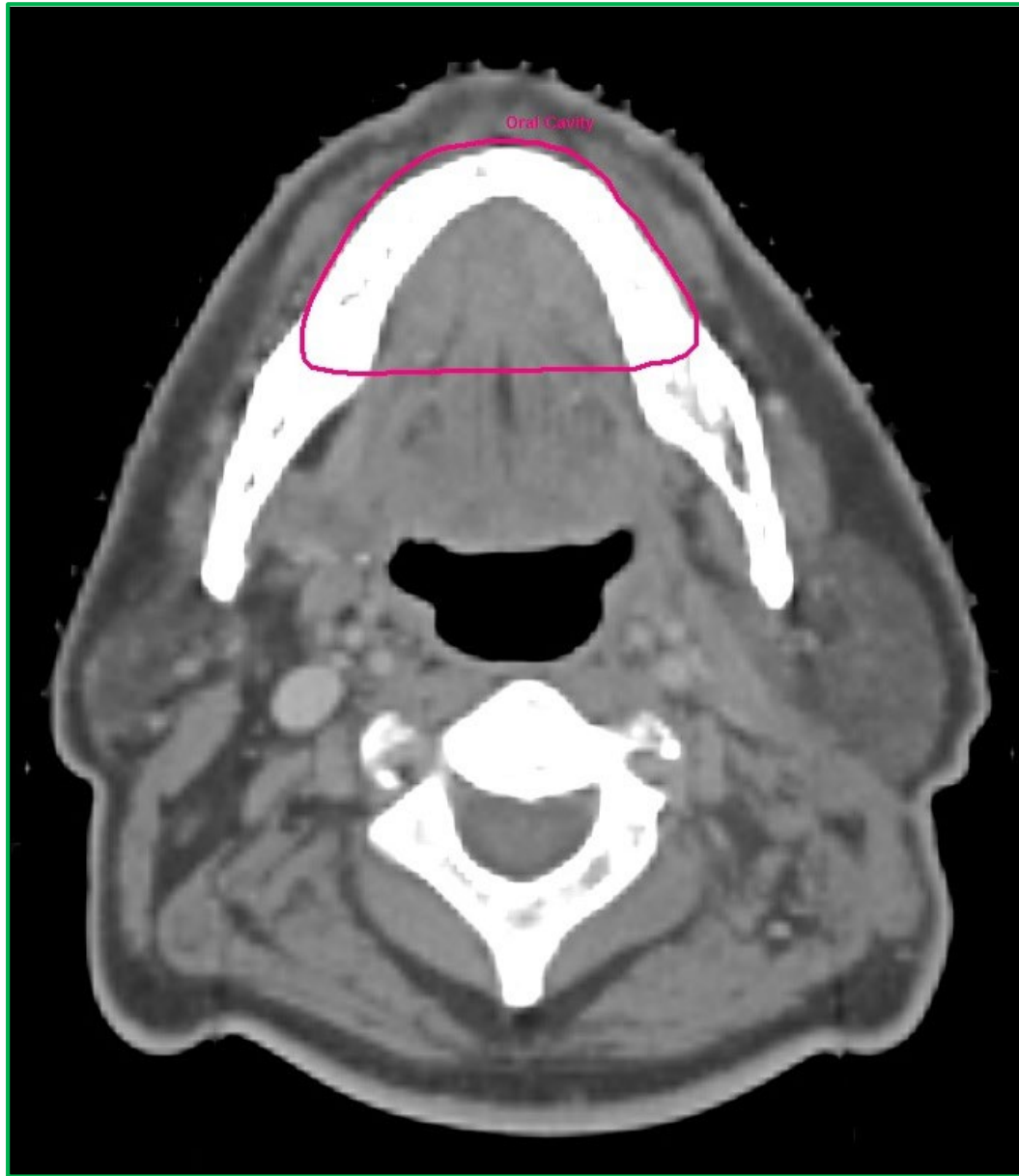


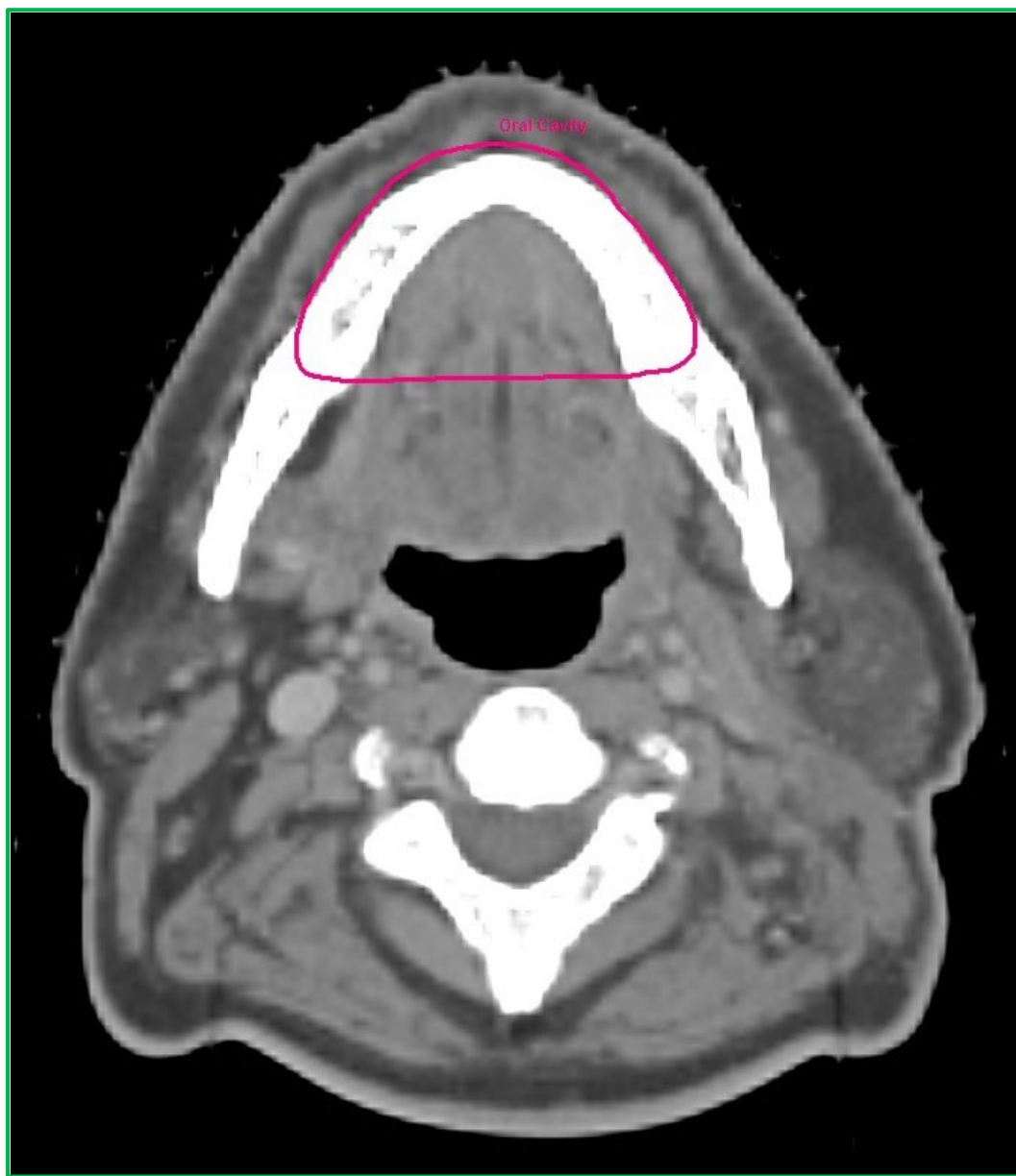



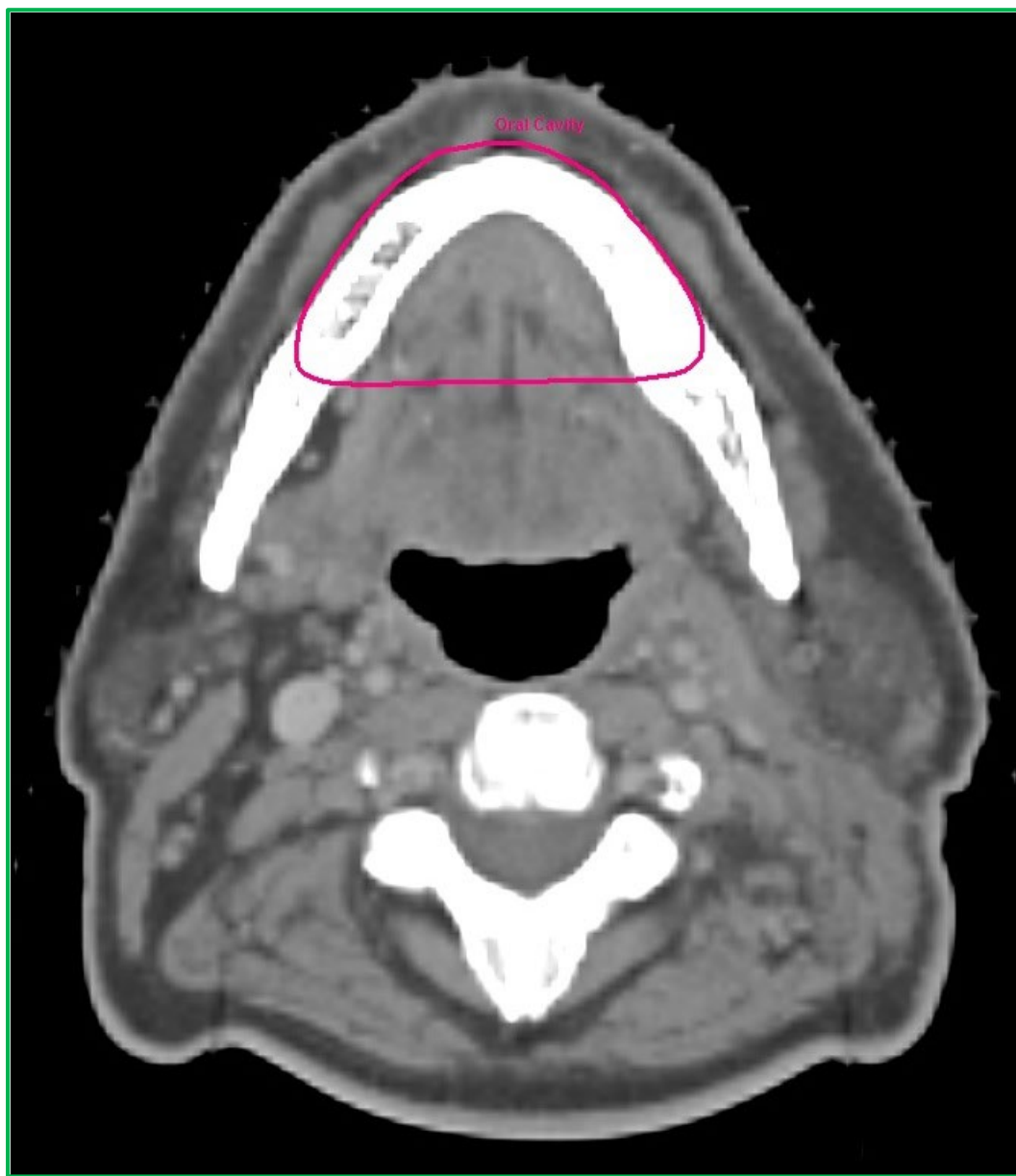


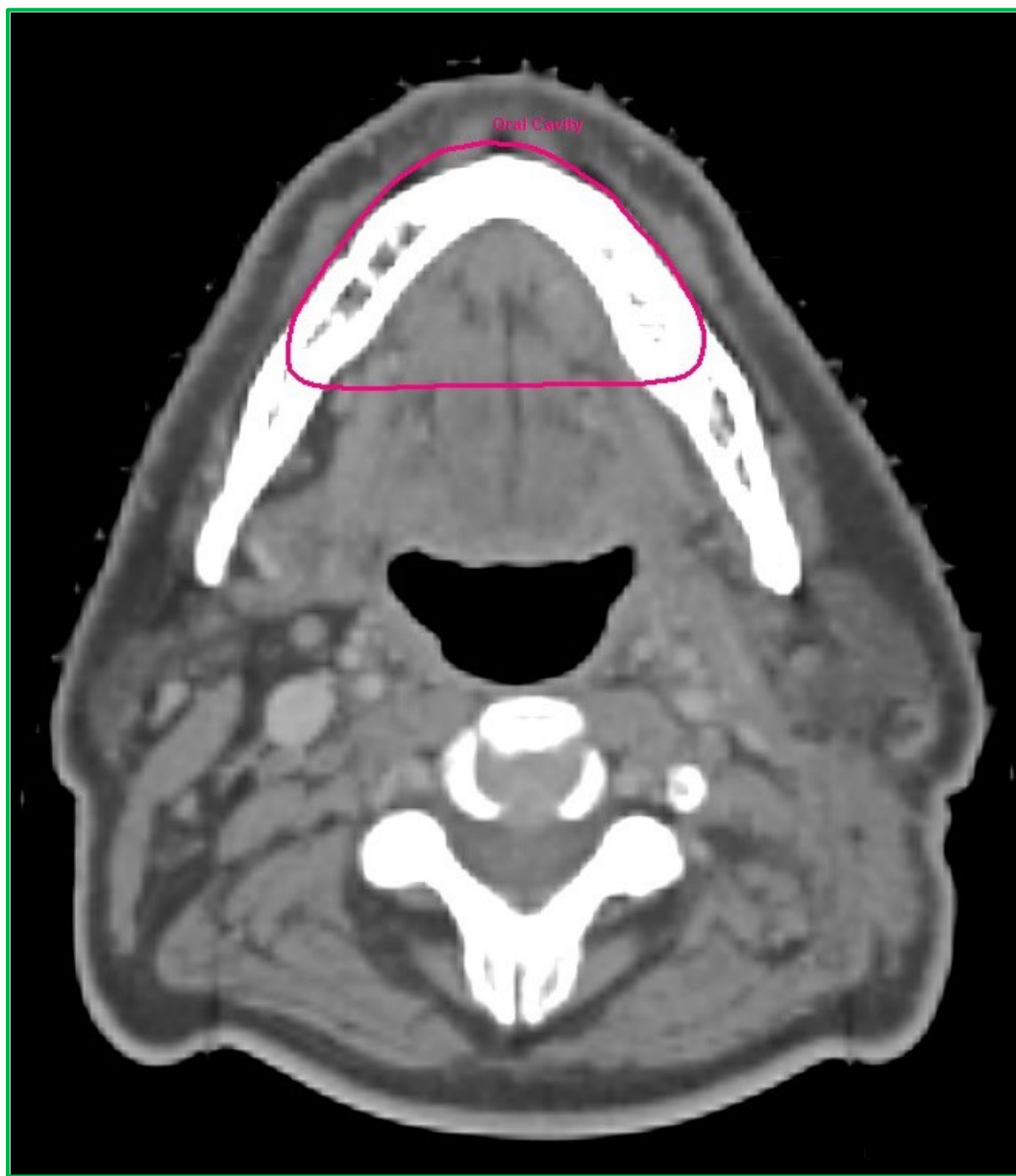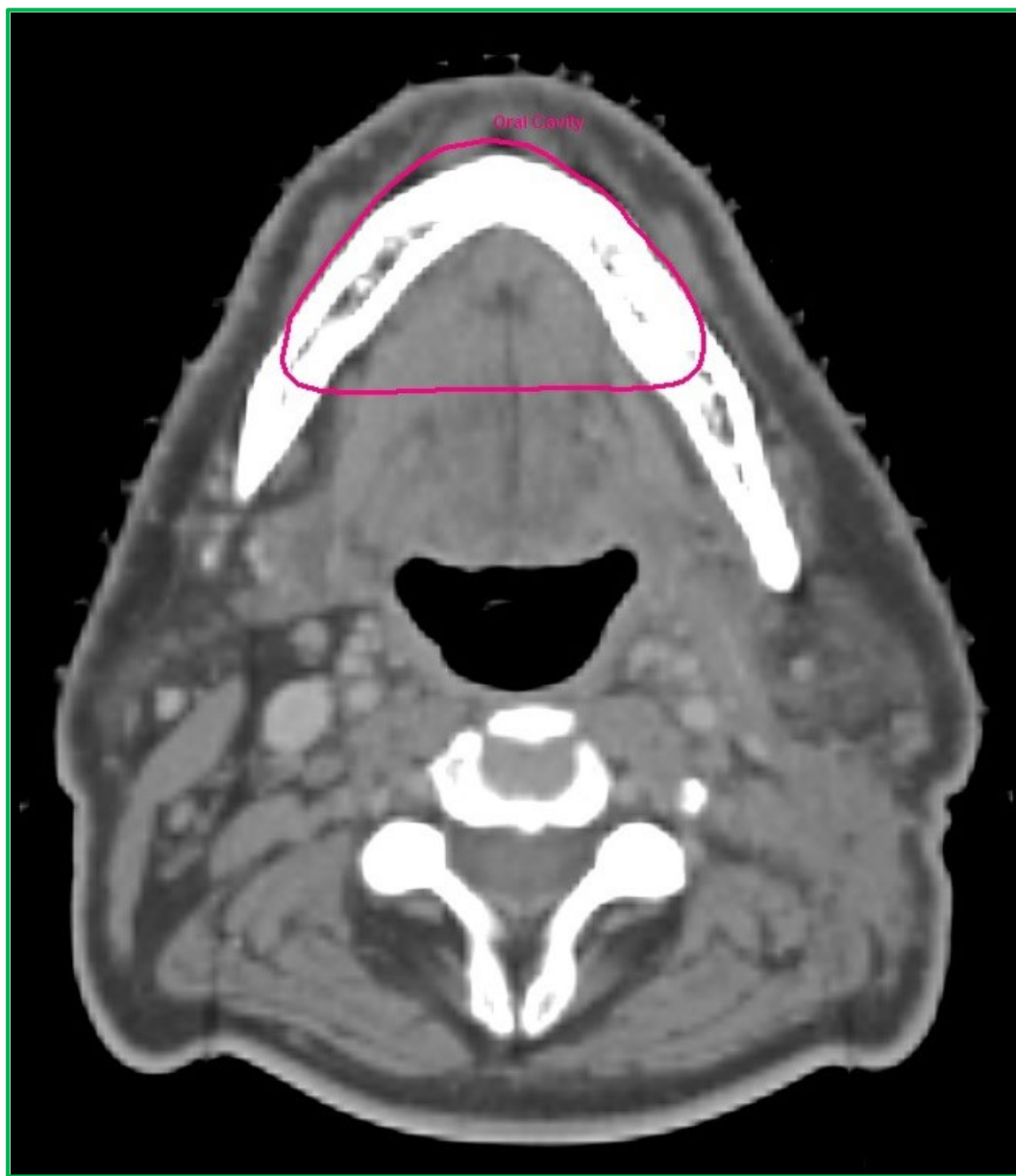


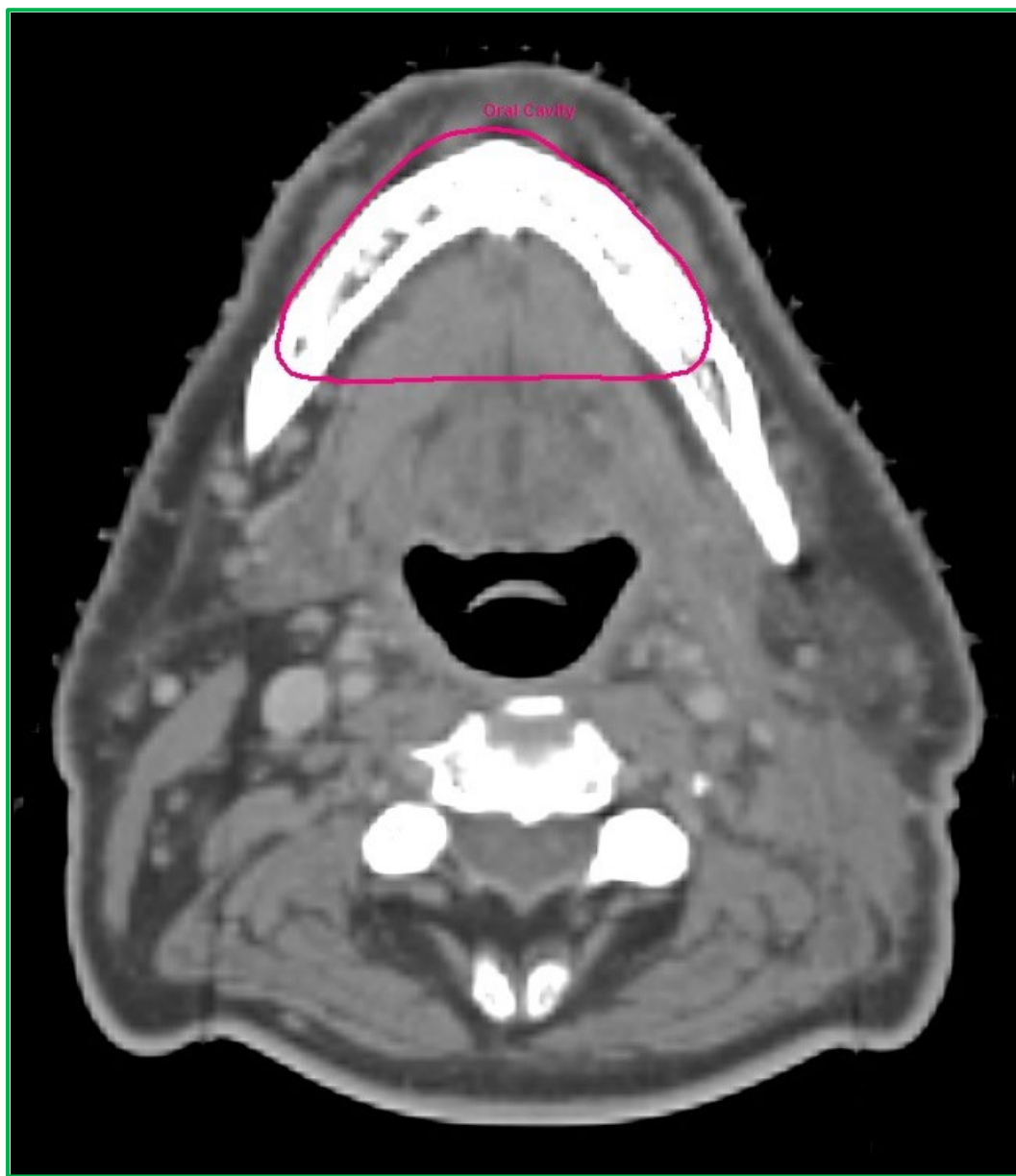


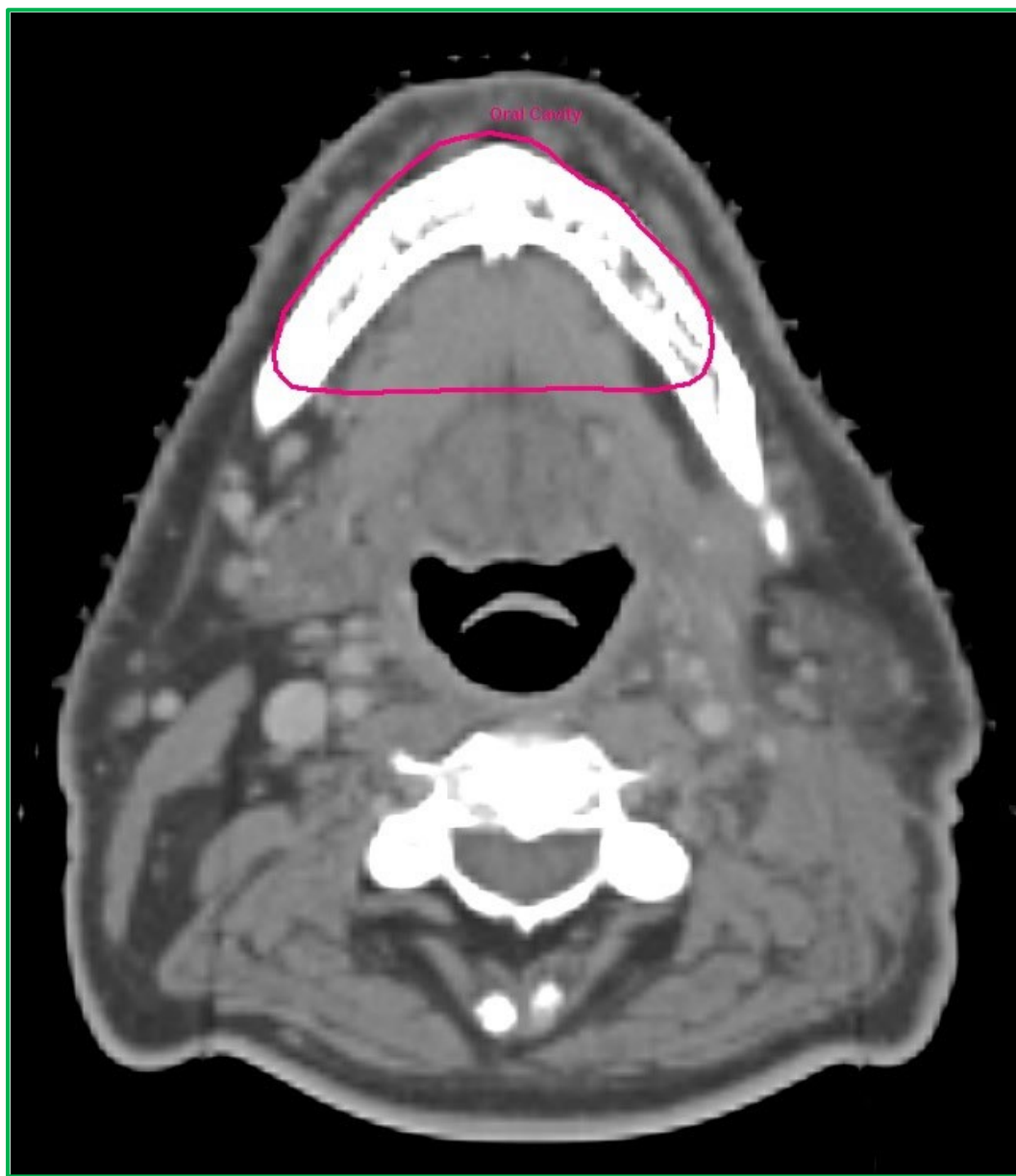




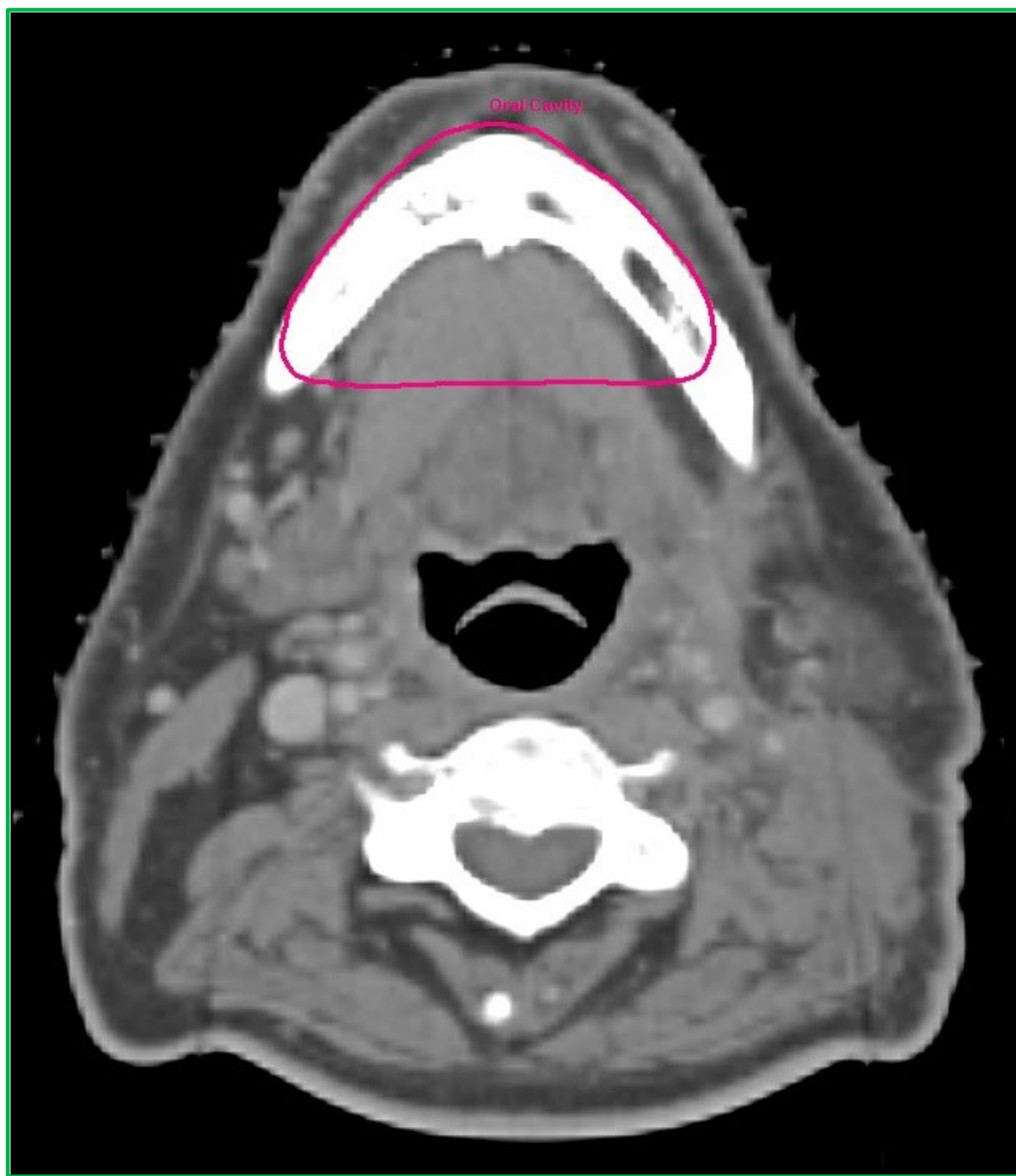


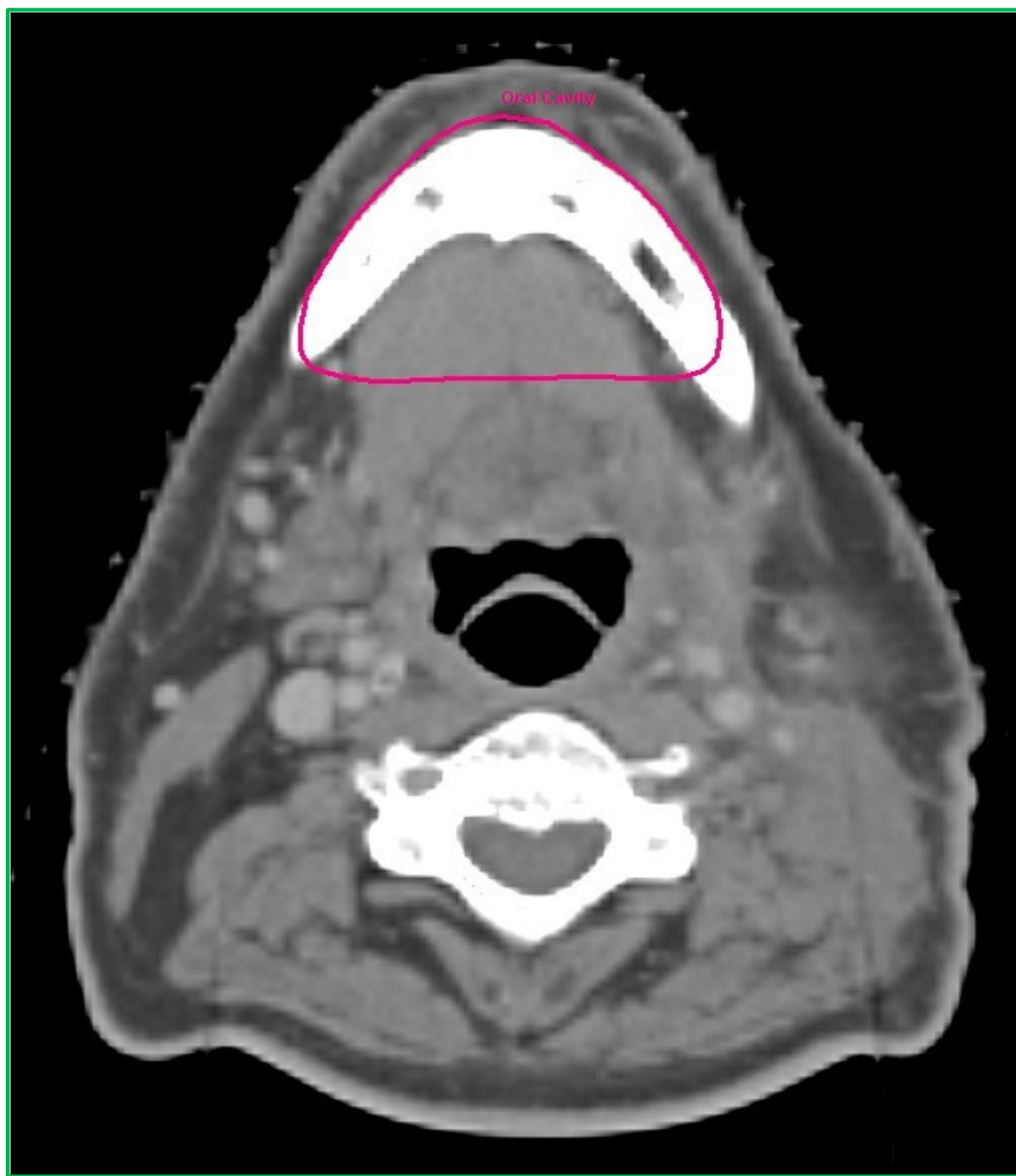




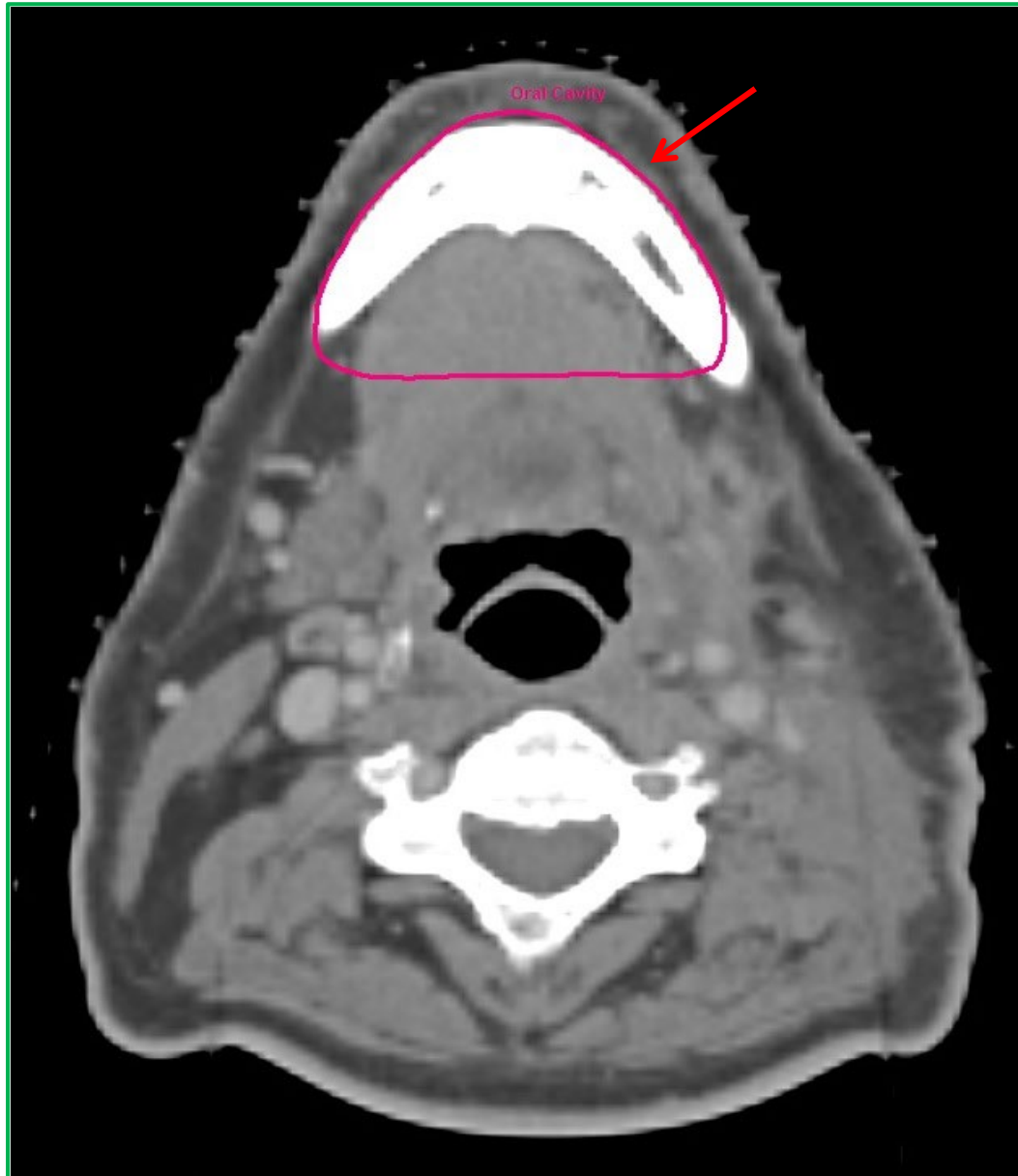








## Oral Cavity - Caudal Boundary



Red arrow - Insertion of Platysma

## Slice below Caudal Boundary of Oral Cavity

