

# The utility of pulse volume waveforms in the identification of lower limb arterial insufficiency

## ABSTRACT

**Background:** The ankle brachial index is widely used for non-invasive assessment of lower limb arterial status, but has recognised limitations. The most significant limitation involves arterial calcification, which results in artefactually raised occlusion pressures and uninformative ankle brachial indices.

**Hypothesis:** Analysis of the pulse volume waveform is useful for identification of lower limb arterial insufficiency in the presence of arterial calcification.

**Method:** Individuals (n = 1101) registered at a Welsh general practice were invited to undergo cardiovascular risk assessment. The ankle brachial index was measured using an automated device utilising volume plethysmography and the traditional Doppler ultrasound method.

**Results:** Eight percent of participants (30/368) had an ankle brachial index  $\geq 1.3$ , suggesting possible arterial calcification; consideration of the pulse volume waveform in these cases identified possible mild peripheral arterial disease in three cases (10%). Furthermore, in one case, the ankle brachial indices were within the normal range, but the pulse volume waveforms suggested a moderate degree of arterial insufficiency; this participant was subsequently diagnosed with bilateral superficial femoral artery stenoses and treated accordingly.

**Conclusion:** Pulse volume waveforms can be easily utilised as an adjunct to ankle brachial index measurement to identify patients who may benefit from further vascular assessment and intervention.

## INTRODUCTION

The use of the ankle brachial index (ABI) dates back to the 1950's when Windsor was the first to compare peripheral systolic pressure with central systolic pressure for the purpose of identifying peripheral arterial disease (PAD)<sup>1</sup>. More than six decades later, the ABI remains the gold standard for non-invasive assessment of the arterial status of the lower limb. However, ABI has limitations, the most prominent of which relates to the artefactual elevation of arterial occlusion pressures in the lower limb, which can result in inaccurate and uninformative ABIs. This elevation can be attributed to factors such as peripheral oedema, lipodermatosclerosis associated with venous insufficiency, and circular arteriosclerotic lesions<sup>2</sup>. However, the most common aetiology relates to the accumulation of calcium and phosphate in the medial layer of the arterial wall, making compression of the vessel difficult. This phenomenon is known as Mönckeberg's medial sclerosis or medial artery calcification (MAC)<sup>3</sup>. MAC is associated with advancing age and hypertension<sup>4</sup> as well as diabetes mellitus<sup>5</sup> and chronic kidney disease<sup>6,7</sup>.

Experienced practitioners are usually alerted to the possibility of a falsely elevated or inaccurate ABI when the clinical presentation of the assessed limb does not correspond with the ABI result or when the audible signal emitted from a Doppler ultrasound device during the ABI measurement procedure does not correspond with the ABI result. A Doppler ultrasound signal indicating healthy or normal lower limb arterial flow has three distinct phases. On the other hand, a low pitched, monophasic sound indicates reduced blood flow and usually represents vessel disease. Some Doppler ultrasound devices also provide visualisation of the Doppler ultrasound waveform, which can also be analysed to determine if the waveform is triphasic, biphasic, or monophasic. ►



Jane H Davies<sup>1</sup>, BN



Jane E A Lewis<sup>2</sup>, PhD



E Mark Williams<sup>1</sup>, PhD

<sup>1</sup>Faculty of Life Sciences and Education, University of South Wales, Pontypridd, UK.

<sup>2</sup>Cardiff and Vale University Health Board, St David's Hospital, Cardiff, UK, Metropolitan University, Cardiff, UK.

Correspondence: jane.davies@southwales.ac.uk

Declared Conflict of Interest: JD's PhD is part sponsored by Huntleigh Healthcare. However, the company had no part in the research reported, nor in the paper presented.

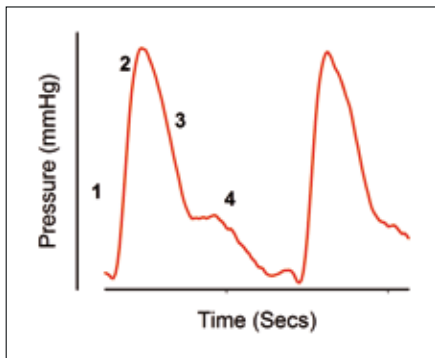


Figure 1: Normal PV waveform:  
1) Brisk systolic upstroke, 2) Sharp systolic peak,  
3) Gradual downslope, 4) Dicrotic notch.

### Pulse Volume Waveform (PVW) Recording

PVW recording constitutes a further non-invasive, diagnostic procedure that can be utilised to evaluate blood flow in the extremities. PVW corresponds to the phases of the cardiac cycle, with a brisk upstroke and sharp peak that occur during systole, followed by a gradual downslope that occurs in diastole (Figure 1). A reflective wave, or dicrotic notch, represents reflected blood flow.

According to Raines and Almeida<sup>8</sup>, two aspects of the PVW require consideration for its qualitative interpretation: the contour and the amplitude of the waveforms. If, at rest, the reflected wave (dicrotic notch) is absent, this implies that the peripheral resistance distal to the point at which the recording is taken has been reduced. Reduction in peripheral resistance is most often caused by proximal arterial obstruction. Waveform amplitude is a function of local pulse pressure and is reduced with arterial occlusion proximal to the point at which the recording is taken. Therefore, the more reduced the amplitude, the greater the proximal obstruction and the poorer the local perfusion. Interpretation of PVWs can be undertaken by visually comparing them to a four-level grading system<sup>9</sup> (Figure 2).

Until recently, PVW recording was confined to the vascular laboratory; however, the development of portable equipment with PVW recording capabilities has made this diagnostic technique much more amenable for use in other, non-specialist settings, such as primary care.

The aim of this study was to assess the utility of PVW recordings undertaken in a primary care setting by comparing simultaneously recorded ABI and PVW data taken during a cardiovascular screening study.

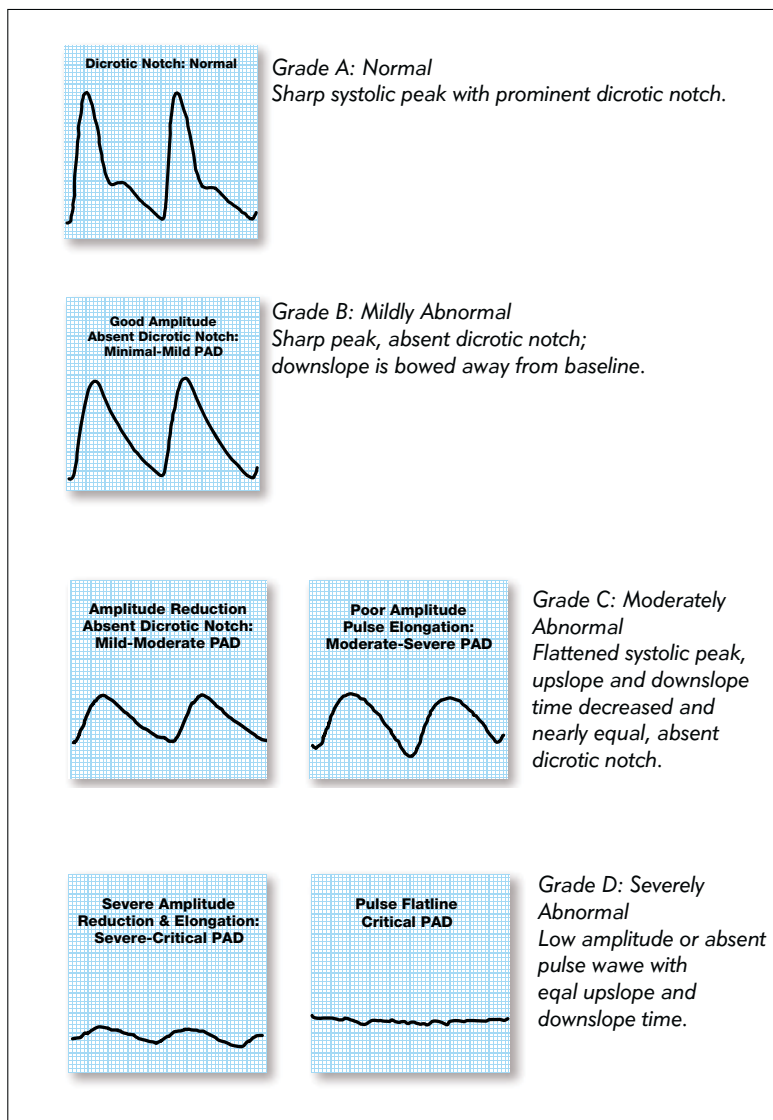


Figure 2: PVW grading system<sup>9</sup>.

### METHODS

As PAD is a marker of systemic atherosclerosis,<sup>10</sup> the primary aim of the PIPETTE (Peripheral Arterial Disease in Primary Care: Targeted screening and subsequent management) study was to assess cardiovascular risk by measuring the ABI. This prospective observational study was based in a South Wales (UK) General Practice. We invited 1101 individuals with at least two pre-identified cardiovascular risk factors without known cardiovascular disease or diabetes mellitus to participate. Ethical approval for this study was granted by the South East Wales Research Ethics Committee (REC No: 12/WA/0075), and all participants (n = 368) provided written consent.

First, while supine, participants underwent ABI measurement using an automated device utilising volume plethysmography\*. The device utilises dual chamber cuffs.

\* dopplex® ABILITY, DA100PB, Huntleigh Healthcare.

\*\* Doppler MD2, 8 MHz, Huntleigh Healthcare.

\*\*\* Aneroid sphygmomanometer, Welch Allyn Inc.

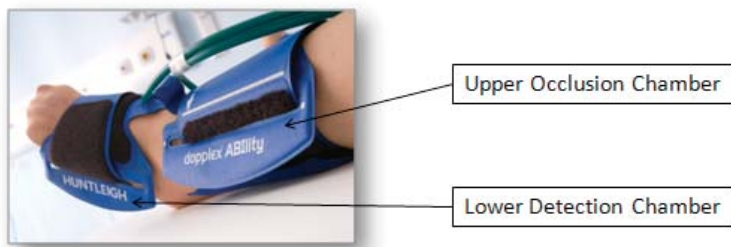


Figure 3: Automated ABI device dual chamber leg cuff

For each limb, an upper chamber occludes arterial blood flow, and the lower chamber utilises pneumoplethysmography to detect returning pulsations as the pressure in the upper chamber is gradually reduced (Figure 3). This technology is used to measure and calculate ABIs for both legs simultaneously. The device also records a 5-second strip of PVWs for each foot (via the lower detection chamber) that are printed out along with ABI results for analysis. Following a 5-minute rest period, the ABI was measured again, this time utilising the traditional manual method of Doppler ultrasound\*\* and sphygmomanometry\*\*\*. The Doppler ultrasound ABI measurement was performed in accordance with the evidence-based procedure recommended by Aboyans et al.<sup>11</sup> All ABI measurements were performed by a qualified nurse with extensive experience in the procedures (JD).

JD subsequently graded the obtained PVW recordings according to Rumwell and McPharlin's grading system<sup>9</sup> (Figure 2). The PVW recordings of all PIPETTE participants were also graded by JL (Clinical Specialist Podiatrist and Therapies, Cardiff and Vale NHS trust), an experienced researcher and practitioner in this field<sup>12</sup>. The review was single-blinded as JL did not have access to participants' clinical data or knowledge of JD's gradings. The subsequent gradings were first reviewed to determine agreement between reviewers, and second to identify cases in which the ABI may have been artefactually raised and potentially uninformative; namely cases with an ABI  $\geq 1.3$  and cases in which the ABI and PVW did not correspond.

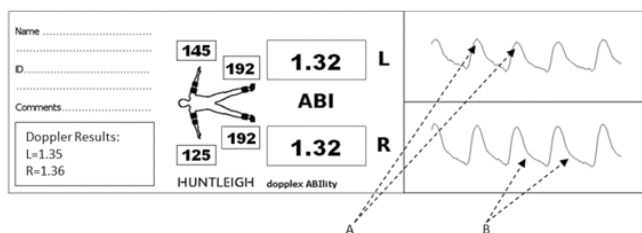


Figure 4: Example of a printout from an automatic ABI device showing an elevated ABI with an abnormal pulse volume waveform. A: rounded systolic peaks, B: absence of defined diastolic notch.

## RESULTS

The variability between the automatic\* and manual\*\* methods of deriving the ABI was 10.1% as defined by the standard deviation of the difference in the results divided by the mean<sup>13</sup>. From 736 PVW recordings ( $n = 368 \times 2$  legs), 680 were suitable for grading. Fifty-eight recordings could not be graded because of poor quality PVW recordings ( $n = 28$ ), failed measurements ( $n = 10$ ), and problems associated with the automated device for various reasons

( $n = 18$ ). For example, participants who had undergone a previous mastectomy could not undergo bilateral brachial blood pressure measurements. Both reviewers reported the same grading for 99% of the PVW recordings ( $n = 673$ ). For the 1% ( $n = 7$ ) of recordings for which the reviewers did not agree, the disagreement always involved one reviewer allocating grade A and the other grade B. Because this difference in grading also equated to disagreement regarding the PAD status of the participants, these cases were excluded from the subsequent results analysis.

An ABI of 1.3 is frequently used as a cut-off point to signify when results may be artefactually high; 8% ( $n = 30$ ) of the ABIs in the PIPETTE study exceeded this value. Analysis of the corresponding PVW recordings suggested that 10% of these participants ( $n = 3$ ) had abnormal waveforms, which were all graded B by both reviewers, suggesting the presence of mild PAD. Figure 4 shows an example of a participant with ABIs  $\geq 1.3$ . However, inspection of the corresponding PVW revealed abnormal waveforms with the absence of the diastolic notch and rounded systolic peaks.

Both reviewers also identified a case in which although both the automatic and manual methods returned ABI results within the normal range (0.91-1.29), inspection of the PVW recordings revealed abnormal waveforms (Figure 5). Based on the abnormal PVWs, this participant was subsequently referred to a vascular surgeon for further

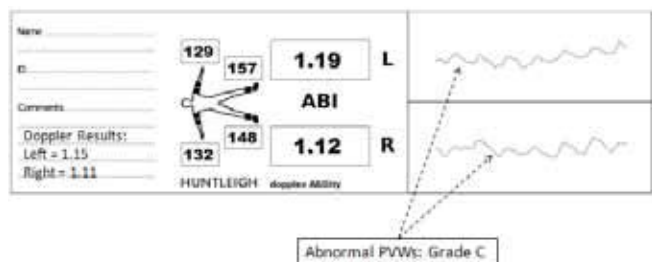


Figure 5: Example showing a normal ABI but abnormal PVW suggesting that this individual may have peripheral arterial disease and that calcification may have artefactually raised the ABI to within the normal range. The PVW shows flattened systolic peaks, and the upstroke and downstroke times are decreased and nearly equal.

investigation and was found to have bilateral superficial femoral artery stenoses and subsequently underwent successful angioplasty.

## DISCUSSION

The 10.1% variability between the ABI measurements in this study matches the inter-observer variability observed between two experts (vascular laboratory technicians) who measured the ABI of 40 participants using Doppler ultrasound (inter-observer variability = 10.1%)<sup>13</sup>. According to Nicolai et al.,<sup>14</sup> variability of  $\leq 10\text{--}15\%$  is regarded as acceptable for clinical tests.

An ABI  $\geq 1.3$  is considered to be artefactually high, and MAC is likely to be a contributing factor. MAC is frequently associated with diabetes. Thus, although diabetics were excluded from the PIPETTE study, the percentage of participants with elevated ABIs was surprisingly high at 8%.

When an ABI exceeds the cut-off point of 1.3, this measurement cannot be relied upon to provide an accurate indication of the arterial status of the limb. Suominen et al.<sup>15</sup> found that a large proportion of individuals with high ABIs actually had PAD. They conducted a retrospective clinical study in which 1762 patients, who were referred to a vascular laboratory with suspicion of PAD, had their ABI and toe pressures measured via photoplethysmography. An ABI  $\geq 1.3$  was considered abnormally elevated, and a toe brachial index  $< 0.6$  was considered diagnostic of PAD. The prevalence of an elevated ABI was 8.4%, and of those, 62% had PAD according to toe pressures and digital subtraction angiography. In comparison, only 10% of PIPETTE participants with an ABI  $\geq 1.3$  were likely to have had PAD as indicated by their corresponding PVW recordings. This lower rate can likely be attributed to the differing study populations. Lilly et al.<sup>16</sup> offer an explanation for this by proposing that some individuals have elevated ABIs due to an increased pulse pressure amplitude rather than MAC; this constitutes a benign form of elevated ABI.

Hence, when the ABI is elevated, practitioners must be able to utilise alternative strategies to determine if the arterial status of the limb is compromised. Experienced practitioners are likely able to make this judgement based on the nature of the audible Doppler signal and the clinical presentation of the patient. However, whether less experienced, non-specialist practitioners, such as novice community nurses, would have the knowledge, skills, and confidence to make such a judgement, is less clear. A study by Davies et al.<sup>17</sup> highlighted that practitioners based in general practices in Wales experience issues with several practical and theoretical aspects of the ABI measurement procedure.

The PIPETTE study also highlighted that MAC can sometimes falsely elevate the ABIs of PAD patients to within the accepted normal range (0.9-1.29). Such patients must be identified promptly to ensure timely referral for further investigation and intervention. Subsequent optimisation of the arterial status of the limb will of course have beneficial effects for wound healing. An inexperienced nurse may have used the normal ABI results in the described case as an indication to apply compression and may have then failed to identify that the patient required further investigation. Inspection of the PVW provides a simple method of identifying such patients. Use of the PVW recording is recommended by both the European Society of Cardiology<sup>10</sup> and the American College of Cardiology/American Heart Association<sup>18</sup> as a second-level assessment tool for patients with suspected PAD. Thus, the PVW can be utilised to establish an initial diagnosis of lower extremity PAD.

### Advantages of PVW recordings

An added advantage of PVW recordings that is particularly pertinent to wound care relates to the fact that these recordings represent the sum of all blood flow through the examined area. Hence, a patient with a significant obstruction to blood flow in one or more arteries, but good collateral blood flow may have a normal waveform. This could be useful in assessing whether a lower extremity wound has sufficient arterial blood supply to facilitate healing. Furthermore, the process of obtaining a PVW does not require operator skill and merely involves the application of a cuff to the foot or ankle; the device then automatically inflates, obtains, and displays the PVW. In contrast, the process of obtaining a Doppler waveform is operator dependent because a Doppler probe must be carefully positioned over an artery at a specific angle and pressure. Results can vary according to the Doppler angle used<sup>19</sup>.

### Limitations of PVW recordings

PVW recording has recognised physiological limitations. First, the PVW depends on peripheral blood flow and thus, may be influenced by factors other than vessel patency such as sympathetic nerve input<sup>20</sup>. Second, severe congestive heart failure may also slow blood flow and mimic inflow disease<sup>8</sup>. Third, the PVW represents the total blood flow through the area being assessed, and therefore, cannot provide accurate diagnostic information regarding where and to what extent a specific artery is diseased. A further limitation of PVW recordings involves susceptibility to interference from factors such as patient movement, which can result in artefact in the detection signal and subsequent poor quality PVW recordings. This can sometimes be addressed with repeated measurements



after repositioning the patient and reminding him or her of the importance of remaining still during the procedure.

### Study Limitations

Although this study demonstrated that reviewers with considerable experience in interpreting PVW recordings agreed on the identification of apparently abnormal PVW recordings, this may not necessarily apply to practitioners less experienced at the task. Furthermore, the majority of obtained PVW gradings were not verified by comparison with a superior diagnostic modality such as Duplex ultrasound scanning.

### CONCLUSIONS

This study highlighted the shortcomings of the ABI as a single diagnostic tool and demonstrated the need for a secondary mode of lower limb arterial assessment that is also easy for non-specialist practitioners to use. PVW recordings may be acceptable for fulfilling this role and may, thus, be particularly useful in the field of wound management.

### Implications for Clinical Practice

This study highlighted that:

- The prevalence of an elevated ABI ( $\geq 1.3$ ) is relatively high even in a population in which diabetics were excluded.
- The ABIs of patients with PAD can sometimes be artefactually raised to within normal limits.
- In such cases, simple analysis of PVW recordings is a useful adjunct for the identification of patients who require further vascular investigation.

### Further Research

Further research should investigate the utility of PVW recordings by examining the associated sensitivity for detecting PAD or specificity for ruling out PAD. Further investigation is also required to determine the ease of use and the cost and training required to achieve reliable results.

### Acknowledgements

This study was undertaken as part of JD's PhD, which is funded by a Knowledge Economy Skills Scholarship (KESS). This is a major European Convergence programme led by Bangor University on behalf of the HE sector in Wales. Benefiting from European Social Funds (ESF), KESS supports collaborative research projects (in this case, University of South Wales and Huntleigh Healthcare).

The research team also acknowledges the support of the National Institute for Health Research through the comprehensive clinical research network.

The authors thank Cwm Taf University Health Board for their support and Professor Jonathan Richards for hosting the study at Morlais Medical Practice, Merthyr Tydfil.

### References

1. Windsor, T. Influence of arterial disease on the systolic blood pressure gradients of the extremity. *Am J Med Sci* 1950;220:117-126.
2. Kröger, K., Stang, A., Kondratieva, J., Moebus, S., Beck, E. et al. Prevalence of peripheral arterial disease - results of the Heinz Nixdorf recall study. *Eur J Epidemiol* 2006;21:279-85.
3. Rocha-Singh, K. J., Zeller, T. & Jaff, M. R. Peripheral arterial calcification: Prevalence, mechanism, detection and clinical implications. *Catheter Cardiovasc Interv* 2014;83(6):e212-20.
4. Hirsch, A. T., Haskal, Z. J., Hertzler, N. R., Bakal, C. W., Creager, M. et al. ACC/AHA 2005 Practice Guidelines for the management of patients with peripheral arterial disease (lower extremity, renal, mesenteric, and abdominal aortic): a collaborative report from the American Association for Vascular Surgery/Society for Vascular Surgery, Society for Cardiovascular Angiography and Interventions, Society for Vascular Medicine and Biology, Society of Interventional Radiology, and the ACC/AHA Task Force on Practice Guidelines (Writing Committee to Develop Guidelines for the Management of Patients With Peripheral Arterial Disease): endorsed by the American Association of Cardiovascular and Pulmonary Rehabilitation; National Heart, Lung, and Blood Institute; Society for Vascular Nursing; TransAtlantic Inter-Society Consensus; and Vascular Disease Foundation. *Circ* 2006;113: e463-e654.
5. Formosa, C., Cassar, K., Gatt, A., Mizzi, A., Mizzi, S. et al. Hidden dangers revealed by misdiagnosed peripheral arterial disease using ABPI measurement. *Diabetes Res Clin Pract* 2013;102:112-16.
6. Nitta, K. Vascular calcification in patients with chronic kidney disease. *Ther Apher Dial* 2011;15:513-21.
7. Mizobuchi, M., Towler, D. & Slatopolsky, E. Vascular calcification: the killer of patients with chronic kidney disease. *J Am Soc Of Nephrol* 2009;20:1453-64.
8. Raines, J. K., Almeida, J. I. Pulse volume recording in the diagnosis of peripheral vascular disease. In: Aburama, A. F. & Bergan, J. J. (eds.). *Noninvasive peripheral arterial diagnosis*. 3rd Ed. London: Springer-Verlag Limited; 2010:39-46.
9. Rumwell, C., Mcpharlin, M. 1998. Arterial evaluation. In: *Vascular Technology*. California: Davies publishing Inc.; 1998:60-9.
10. Tendra, M., Abovans, V., Bartelink, M. L., Baumgartner, I., Clement, D. et al. ESC Guidelines on the diagnosis and treatment of peripheral artery diseases: Document covering atherosclerotic disease of extracranial carotid and vertebral, mesenteric, renal, upper and lower extremity arteries \* The Task Force on the Diagnosis and Treatment of Peripheral Artery Diseases of the European Society of Cardiology (ESC). *Eur Heart J* 2011;32(22):2851-906.
11. Abovans, V., Criqui, M. H., Abraham, P., Allison, M. A., Creager, M. A. et al. Measurement and interpretation of the ankle-brachial index: a scientific statement from the American heart association. *Circ* 2012;126:2890-2909.
12. Lewis, J. E. A. & Owens, D. R. The pulse volume recorder as a measure of peripheral vascular status in people with diabetes mellitus. *Diabetes Technol & Ther* 2010;12:75-80.
13. Van Langen, H., Van Gorp, J. & Rubbens, L. Interobserver variability of ankle-brachial index measurements at rest and post exercise in patients with intermittent claudication. *Vasc Med* 2009;14:221-26.
14. Nicolai, S. P., Kruidenier, L. M., Rouwet, E. V., Bartelink, M. L., Prins, M. H. et al. Ankle brachial index measurement in primary care: are we doing it right? *Br J of Gen Pract* 2009;59:422-27.
15. Suominen, V., Rantanen, T., Venermo, M., Saarinen, J. & Salenius, J. Prevalence and risk factors of PAD among patients with elevated ABI. *Eur J Vasc Endovasc Surg* 2008;35:709-14.
16. Lilly, S. M., Jacobs, D. R., Jr., Kronmal, R., Bluemke, D. A., Criqui, M. et al. Arterial compliance across the spectrum of ankle-brachial index: the multiethnic study of atherosclerosis. *Atherosclerosis* 2014;233:691-6.
17. Davies, J. H., Kenkre, J. & Williams, E. M. Current utility of the ankle-brachial index (ABI) in general practice: implications for its use in cardiovascular disease screening. *BMC Fam Pract* 2014;15:69.
18. Anderson, J. L., Halperin, J. L., Albert, N. M., Bozkurt, B., Brindis, R. G. et al. Management of patients with peripheral artery disease (compilation of 2005 and 2011 ACCF/AHA guideline recommendations): a report of the American College of Cardiology Foundation/American Heart Association Task Force on Practice Guidelines. *Circulation* 2013;127:1425-43.
19. Aburama, A. F., Jarrett, K. S. Segmental Doppler pressures and Doppler waveform analysis in peripheral vascular disease of the lower extremities. In: Aburama, A. F. & Bergan, J. J. (eds.). *Noninvasive peripheral arterial diagnosis*. 3rd Ed. London: Springer-Verlag Limited; 2010:25-38.
20. Weinburg, I. 2010. Vascular Medicine. Available at: <http://www.angiologist.com/vascular-laboratory/pulse-volume-recording/> [Accessed 27/03/14].