

This is an Open Access document downloaded from ORCA, Cardiff University's institutional repository: <https://orca.cardiff.ac.uk/id/eprint/103234/>

This is the author's version of a work that was submitted to / accepted for publication.

Citation for final published version:

Kennel, Larissa, Martin, David M. A., Shaw, Hannah and Wilkinson, Tracey 2018. Learning anatomy through Thiel- vs. formalin-embalmed cadavers: student perceptions of embalming methods and effect on functional anatomy knowledge. *Anatomical Sciences Education* 11 (2) , pp. 166-174. 10.1002/ase.1715

Publishers page: <http://dx.doi.org/10.1002/ase.1715>

Please note:

Changes made as a result of publishing processes such as copy-editing, formatting and page numbers may not be reflected in this version. For the definitive version of this publication, please refer to the published source. You are advised to consult the publisher's version if you wish to cite this paper.

This version is being made available in accordance with publisher policies. See <http://orca.cf.ac.uk/policies.html> for usage policies. Copyright and moral rights for publications made available in ORCA are retained by the copyright holders.



# **Learning Anatomy through Thiel vs. Formalin Embalmed Cadavers: Student Perceptions of Embalming Methods and Effect on Functional Anatomy Knowledge**

**Larissa Kennel<sup>1</sup>, David M. A. Martin<sup>2</sup>, Hannah Shaw<sup>3</sup>, Tracey Wilkinson<sup>1</sup>**

<sup>1</sup>Centre for Anatomy and Human Identification, School of Science and Engineering,  
University of Dundee, Dundee, Scotland, United Kingdom

<sup>2</sup>School of Life Sciences, University of Dundee, Dundee, Scotland, United Kingdom

<sup>3</sup>School of Biosciences, Cardiff University, Cardiff, Wales, United Kingdom

Running title: Student perception: Thiel vs formalin cadavers

Correspondence to: Prof. Tracey Wilkinson, Centre for Anatomy and Human  
Identification, School of Science and Engineering, University of Dundee, Dundee DD1  
5EH United Kingdom. E-mail: a.t.wilkinson@dundee.ac.uk

## ABSTRACT

Thiel embalmed cadavers, which have been adopted for use in anatomy teaching in relatively few universities, show greater flexibility and color retention compared to formalin embalmed cadavers, properties which might be considered advantageous for anatomy teaching. This study aimed to investigate student attitudes towards the dissection experience with Thiel compared to formalin/ethanol embalmed cadavers. It also aimed to determine if one embalming method is more advantageous in terms of learning functional anatomy through comparison of student anterior forearm functional anatomy knowledge. Student opinions and functional anatomy knowledge were obtained through use of a questionnaire from students at two medical schools, one using Thiel, and one using more traditional formalin/ethanol embalmed cadavers. Both the Thiel group and the formalin group of students were surveyed shortly after completing an anterior forearm dissection session. Significant differences ( $P$ -values  $< 0.01$ ) in some attitudes were found towards the dissection experience between cohorts using Thiel vs formalin embalmed cadavers. The Thiel group of students felt more confident about recognizing anatomy in the living individual, found it easier to identify and dissect anatomical structures, and indicated more active exploration of functional anatomy due to the retained flexibility of the cadaver. However, on testing, no significant difference in functional anatomy knowledge was found between the two cohorts. Overall, although Thiel embalming may provide an advantageous learning experience in some investigated areas, more research needs to be carried out, especially to establish whether student perception is based on reality, at least in terms of structure identification.

**Key words:** gross anatomy education; medical education; undergraduate education; cadaveric dissection; embalming methods; Thiel embalming; formalin embalming; student perceptions

## INTRODUCTION

The use of human cadavers as a learning and teaching tool is restricted naturally by decomposition. In an educational setting, where dissection lessons are spread across the academic year, preservation of the cadaver is essential to provide optimal teaching conditions and facilitate efficient utilization of this limited and valuable resource (Brenner et al., 2003). Preservation for anatomical purposes is considered successful when infection risks are minimized, decomposition is prevented, and softness of tissues and color of muscles and organs resemble unpreserved subjects closely (Brenner, 2014). The earliest evidence of deliberate embalming of human remains was documented during the first dynasty in Egypt in approximately 2640 B.C. (Balta et al., 2015a). Later, the practice of embalming was adapted in Europe (Shaffer, 2004), where the advance of embalming techniques accompanied medical developments (Ezugworie et al., 2009). Embalming by injection of the vascular system was first documented during the Renaissance period (Trompette and Lemonnier, 2009), and reports on the effective use of arterial formaldehyde injection followed during the early 20<sup>th</sup> century (Piombino-Mascali et al., 2009). Formaldehyde has remained an essential component of embalming solutions since then (Johnson et al., 2012; Brenner, 2014).

In terms of medical education in the United Kingdom, formalin is at present the most commonly used embalming solution for long-term preservation of cadavers (Benkhadra et al., 2011b), but several limitations are reported in relation to this embalming method (Hauptmann et al., 2009). The chemical is known to influence hydration and color of tissues negatively (Richins et al., 1963), has an overall rigid feel (Eisma et al., 2011),

and is associated with a penetrating odor (Bradbury and Hoshino, 1978). Potential health hazards linked to formalin embalming have been investigated in medical students (Takahashi et al., 2007; Wei et al., 2007; Raja and Sultana, 2012) with short-term exposure to formaldehyde being found to provoke headache, and irritate skin and mucous membranes. It is classified as a carcinogenic substance (Hauptmann et al., 2009; Lunn et al., 2010) and occupational exposure is likely to have significant long-term health impacts (Mirabelli et al., 2011). Hölzele et al. (2012) also suggested that formalin embalmed specimens are unsuitable for reliable practice of surgical procedures due to the numerous associated limitations.

Consequently, alternatives to formalin embalming are being researched extensively. According to Coskey and Gest (2015), the main options to reduce the health hazard imposed by formaldehyde are either the use of alternative embalming solutions with significantly decreased formaldehyde content, the neutralization of formaldehyde after the embalming process, or improvement of laboratory air flow. Cost-effective light embalming techniques, containing low formaldehyde concentrations and preserving cadavers up to several weeks, were recently described (Anderson, 2006; Messmer et al., 2010). Although lifelike retention of tissue quality and an acceptable health and safety standard is reported in both instances, neither method, due to its limited preservation time, is applicable to anatomy courses, which often last for several months. Therefore, the application of lightly embalmed cadavers is in general limited to medical research and the training of surgical skills. Results by Coskey and Gest (2015) endorsed the neutralization of formaldehyde with monoethanolamine after the

embalming process as a cost effective and efficient method to reduce formaldehyde levels in the classroom, while simultaneously embalming cadavers long-term and providing acceptable health and safety standards. The application of InfuTrace™ (American Bio-Safety, Inc., Rocklin CA), and Perfect Solution® (Carolina Biological Supply Company, Burlington, NC) for neutralization of formaldehyde subsequent to traditional embalming has also been discussed (Whitehead and Savoia, 2008; Whitehead, 2009). Coskey and Gest (2015) discussed secondary perfusion with the neutralization agents presently available, and described the resulting white, powdery film on cadaveric tissue from some agents as a significant disadvantage. Whitehead and Savoia (2008) also drew attention to the additional time required to re-embalm a previously fixed cadaver.

Other promising alternatives to formalin embalming, also leading to a reduction of formaldehyde exposure and allowing long-term embalming of specimens, are available. These include, for example, embalming with propylene glycol, ethanol, and phenol (Macdonald and MacGregor, 1997), with phenoxyethanol (Wineski and English, 1989), with ethanol-polyethylene glycol-formalin (Janczyk et al., 2011a), with saturated salt solution (Hayashi et al., 2014; 2016), and ethanol-glycerin fixation with thymol conservation (Hammer et al., 2012). The ethanol and phenol used in many of these alternatives are not without their own hazards. Ethanol is highly flammable, while phenol is corrosive and toxic (Hammer et al., 2012; Brenner 2014).

Thiel (1992; 2002) also developed a new, less hazardous and widely applicable method

of cadaver preservation. Harmful substances, such as formaldehyde, are present in small concentrations; an 8.9% formaldehyde solution is used, with final Thiel solutions containing 1.44% (arterial infusion), 2.43% (venous infusion) and 0.65% (tank fluid) (Eisma et al., 2013) rather than the more standard 37-40% formaldehyde concentration used in formalin embalming, with a final formalin solution of 5% or less being sufficient (Eisma et al., 2013; Brenner 2014). Carcinogenic risks of Thiel embalming fluid are generally considered minimal (Guo et al., 2012). However, the Thiel embalming fluid contains flammable compounds (Janczyk et al., 2011b), as well as boric acid and ethanol, both of which are apparently earmarked for phasing out of embalming solutions by the European Union (Brenner, 2014). Additionally, Brenner (2014) described the Thiel method as being more expensive than other embalming methods; other authors have estimated the cost of embalming a cadaver at ten times (Benkhadra et al., 2011b) or 20 times (Hayashi et al., 2016) that of a formalin cadaver. Some of these extra costs are associated with the necessity of installing large tanks for the submersion step of the embalming process. Other limitations associated with Thiel embalmed specimens have also been discussed in the literature. Benkhadra (2011a) discussed the loss of muscle fiber integrity, while Healy et al. (2015) explained that the availability of relatively few trained experts on this embalming technique, relatively high costs associated with it, and the long preparation time of up to six months might be regarded as a disadvantage by institutions considering investing in this method. Fessel et al. (2011) found that Thiel specimens are not suitable for biomechanical testing, as increased flexibility of tendons was observed after the embalming process. Occasional mummification of the distal limbs was also noted (Healy et al., 2015) and central nervous system structures are not



preserved well (Hammer et al., 2015). Also, 14 surgeons evaluating embalming with Thiel, formalin and saturated salt solution methods in a study by Hayashi et al. (2014) indicated that some areas of the embalmed body, such as the heart and kidney, were perceived as too soft for the practice of surgical procedures.

Thiel embalmed cadavers are, despite their limitations, described as exceptionally lifelike (Groscurth et al., 2001), with a realistic representation of structures (Prasad Rai et al., 2012; Hammer et al., 2015; Rai et al., 2015) almost equivalent to clinical conditions (Wolff et al., 2008). This is due to retained consistency of soft tissues (Fessel et al., 2011), high mobility of joints (Eisma and Wilkinson, 2014; Hayashi et al., 2014), preservation of tissue color compared to unembalmed or formalin specimens (Jaung et al., 2011), and an overall supple and flexible appearance (Benkhadra et al., 2011a). Due to this softness and flexibility, Thiel embalming is reported to have a positive impact on the dissection experience of the musculoskeletal system (Balta et al., 2015b), which suggests its applicability for both identification and appreciation of anatomical structures by dissection, and active exploration of form and function of the human body by manipulation of structures. Additionally, Hayashi et al. (2013) found that ultrasound images of Thiel embalmed cadavers were clear, unlike formalin cadavers, and that there was no fluid accumulation, as seen in cadavers embalmed with saturated salt solution. These results have positive implications for the application of Thiel embalmed specimens for surgical skills training.

As a relatively new method, literature on learning experiences with Thiel embalming is scarce. Data comparing the application of Thiel embalmed with formalin embalmed cadavers is even more limited. Hassan et al. (2015) gathered opinions of nine surgeons on Thiel and formalin models used in a tendon repair workshop. Eisma et al. (2011) asked 12 surgical trainees about their attitudes towards the use of Thiel embalmed compared with formalin embalmed specimens in a thyroid surgery course. In an educational setting, differences in student perception of the dissection experience with formalin and Thiel embalmed cadavers were investigated once only in a pilot study by Balta et al. (2015b). Seven postgraduate and 101 undergraduate anatomical sciences students took part in their survey. Undergraduate students dissected formalin embalmed cadavers and were given the opportunity to view prosected Thiel bodies; postgraduate students dissected Thiel embalmed specimens and either viewed formalin embalmed specimens during their course or had experience with the embalming method from previous degrees. Undergraduate students viewing Thiel cadavers found it easier to identify thoracic, abdominal and pelvic structures in formalin embalmed specimens, whereas they considered Thiel bodies advantageous for the identification of structures in the limbs. The interpretation of postgraduate student perceptions concluded that dissection of structures was considered slightly easier in Thiel cadavers, whereas no significant differences were found for identification. Perceptions of medical students have not been compared in the literature, and studies attempting quantification of differences in knowledge gain between groups engaging with either embalming method have also not been undertaken.

This study aimed to investigate attitudes of medical students towards dissection with Thiel vs formalin embalmed cadavers. It also aimed to determine if one dissection method was more advantageous than the other in terms of learning functional anatomy through comparison of student anterior forearm functional anatomy knowledge.

## METHODS

The study was carried out at two universities in the UK: the University of Dundee, where the Thiel method of embalming is carried out, and Cardiff University, which uses formalin/ethanol embalmed cadavers.

### **Embalming procedures in Dundee and Cardiff**

Cadavers at Cardiff University are embalmed with a pre-prepared solution containing ethanol, phenol and formaldehyde (Embalming Fluid No. 4) (Vickers Laboratories, 2017). The final embalming solution contains a relatively low percentage of formaldehyde: 1.6% formaldehyde, 10% phenol, and 72% ethanol. The properties of the cadavers in terms of color and stiffness are typical of cadavers embalmed with formalin solutions. Cadavers donated to the Centre for Anatomy and Human Identification at the University of Dundee are embalmed according to the method described by Walter Thiel (1992, 2002). The embalming procedure entails vascular perfusion and subsequent immersion for approximately four to six months, as outlined in more detail by Eisma and Wilkinson (2014). Thiel embalming fluid is a water-based solution containing components such as boric acid and a low concentration of formalin: for the vascular perfusion stage, 3.6L of 8.9% formaldehyde solution in 18.5L of Thiel fluid, resulting in a

final concentration of 1.7%; for the tank immersion stage, 125L of 8.9% formaldehyde solution in 1,720L of Thiel fluid, resulting in a final concentration of 0.65% (Eisma et al., 2013). Full details of the embalming solutions are available in the paper by Eisma et al. (2013). The properties of these cadavers in terms of color and flexibility are typical of cadavers preserved through this method.

### **Medical curriculum at Cardiff University and the University of Dundee**

The Dundee medical course follows a systems-based, integrated curriculum, with undergraduate medical students carrying out varied amounts of dissection in their first three years. Although the musculoskeletal system is introduced in Year 1 through 4 hours of lectures and 2 hours of dissection, the bulk of teaching for this system, including dissection of the upper limb, takes place in Year 2. During this block, each student should attend 18 hours of upper limb tuition: 1 hour of lecturing, 14 hours of dissection, and 3 hours of practical (e.g., bone workshops).

Cardiff University follows a Case Based Learning curriculum, but with a concentrated basic science introduction in the first semester of Year 1, where the majority of dissection takes place. During this semester, students should attend 16 hours of upper limb tuition: 1 hour of lecturing and 15 hours of dissection.

## **Data collection**

The study was performed using a custom questionnaire. This captured the students' demographic data and attitudes towards dissection, and evaluated their knowledge of forearm anatomy.

The first section of the questionnaire gathered demographic information on the students. Participants were asked about their age, sex, university affiliation, and degree program. The only exclusion criterion applied was a previous degree qualification related to human anatomy, and data from these participants were disregarded in the evaluation of functional anatomy knowledge. In the second section, Likert-like items with a five point ordinal scale from 'strongly agree' to 'strongly disagree' were used to determine student satisfaction with the embalming method used in their department in areas such as smell, flexibility, and applicability for dissection of different structures. Students were also given the opportunity to comment freely on their attitudes and experiences in a blank space at the end of this section. The final section consisted of a quiz containing twelve single best answer multiple-choice questions (see Supplementary Material: Appendix 1); this aimed to investigate students' anterior forearm functional anatomy knowledge under test conditions immediately after their relevant dissection class. The two student groups consisted of students dissecting with Thiel embalmed cadavers (the 'Thiel group'), and students dissecting with formalin/ethanol embalmed cadavers (for simplicity, named the 'formalin group'). The questionnaires were distributed to the students in both universities as soon as logistically possible after their dissection of the forearm and hand. Since this dissection

is carried out in Year 1 in Cardiff and Year 2 in Dundee, the student cohorts for the groups were different.

Ethical approval for the study was obtained from both participating universities.

Informed consent was obtained from subjects prior to their participation in the study.

### **Statistical Analysis**

To investigate the likelihood of differences in attitudes between both student groups occurring by chance, P-values were calculated; values below 0.05 were considered significant for all statistical tests. Summary statistics on the student demographics were obtained from the first section of the questionnaire. Differences in attitudes towards the dissection experience between the Thiel and formalin groups were analyzed with R statistical package, version 3.3 (R Foundation for Statistical Computing, Vienna, Austria). Data collected with Likert-like scale items are non-parametric and not expected to be distributed normally; the Wilcoxon signed-rank test was therefore used. It is, however, common practice to evaluate the significance of differences between groups in such questions with a t-test. Despite the non-parametric nature of the data, the significance scores obtained with t-tests have been reported to be robust, given a suitably large sample size (Norman 2010; de Winter 2010). To evaluate the reliability of the observed t-statistics when the ordinal scale is transposed to an interval scale, a robustness analysis on the responses was performed. The extreme ordinal points were mapped to either end of an interval scale at 1 and 100, and the mid 3 ordinal points for

each question assigned to random points between 2 and 99. This allowed the estimation of 95% confidence intervals for the t-statistic, and hence the derived P-value. Questions in the second section of the questionnaire were examined for independence by pairwise comparison and calculation of Kendall's tau B. To evaluate anatomical knowledge, the quiz score achieved by each student in the final section of the questionnaire was used. Responses with seven or more unanswered questions of the twelve were discarded. The scores were expressed as a percentage, with mean scores calculated for each student group. Mean scores of the Thiel vs. formalin groups were then compared using a two-tailed t-test. Internal consistency of both the attitudinal questionnaire and the quiz was evaluated using Cronbach's Alpha, implemented as the alpha function in the R package 'psych', version 1.6.9 (Revelle, 2016).

## RESULTS

### **Demographics**

From a total of 432 questionnaires distributed to medical students, 270 (64%) were returned; 97 students (73% return rate) in the Thiel group and 173 students (57% return rate) in the formalin group participated in the study. Questions that were omitted or not appropriately completed were removed from the analysis. Attitudes of 270 students (97 Thiel, 173 formalin) and functional anatomy knowledge of 229 students (92 Thiel, 137 formalin) were evaluated. The mean age of participating students was 20.3 ( $\pm$  2.82) years for the Thiel group and 19.0 ( $\pm$  1.20) years for the formalin group. In total, 173 (64%) female and 97 (36%) male students participated in the study.

## **Student Attitudes**

Significant differences between perception of students in the Thiel and formalin groups towards the embalming method used in their department was found for a number of questions (Table 1). Although no direct comparison was possible, Thiel students found it easier to identify and dissect anatomical structures overall. While no significant differences regarding perception of dissection and identification of the musculoskeletal system were found, dissection of organs, nerves and vessels was perceived as easier in Thiel embalmed cadavers. The smell of formalin embalming seemed to have a greater impact on students' dissection experience than that of Thiel embalming. Most of the students working with Thiel cadavers thought that these retained great flexibility, whereas a larger number of students working with formalin embalmed cadavers disagreed with this statement (Figure 1). Also, the Thiel group of students felt more confident that they would recognize anatomy in the living individual. No correction for multiple hypothesis testing was performed in the analysis of student attitudes. However, the results are clearly significant across multiple questions. Cronbach's Alpha for the questionnaire was 0.70. No question pair showed significant correlation when compared with Kendall's tau B (data not shown), indicating that the questions were being answered honestly by a substantial proportion of the respondents. Likewise, the evaluation of respondents with Cronbach's Alpha (see below) indicated a similar pattern of knowledge amongst the students, though factor analysis did not robustly identify any subgroupings in the data.

<insert Table 1 here>



Several students, especially those in the Thiel group, added comments in the free comments section. One student learning with formalin embalmed cadavers mentioned that the discoloration and stiffening of structures after embalming impacted his/her dissection experience negatively. One medical student in the Thiel group, but holding an undergraduate degree in Anatomical Sciences from a university dissecting with formalin specimens, found that Thiel cadavers were more difficult to dissect in comparison to formalin, but that they were advantageous due to greater color retention and flexibility. This student also found that the representation of anatomical structures in Thiel to be advantageous. Some students from the Thiel group commented that their ability to identify and dissect anatomical structures varied depending on the specific cadaver, while others thought this was highly dependent on the anatomical structure in question: the flexible nature of vessels and nerves in Thiel cadavers was sometimes perceived as confusing, and that identifying neurovascular structures correctly may be especially difficult. One student enjoyed the fact that the retained flexibility of Thiel embalming allowed different texture of structures to be felt, and several students believed that this flexibility would prepare them particularly well for surgical practice. Another student mentioned that manipulating the joints of Thiel embalmed cadavers was helpful for their learning, and contributed to their retention of muscle functions. Several students in the formalin group commented on the odor. While some found the smell of the embalming fluid strong but bearable, others described it as pungent.

## Functional Anatomy Knowledge

No significant difference was found when comparing overall percentages of correct answers to the functional anatomy questions for the Thiel and formalin groups, except for question 12 (Table 2). The percentages of correct quiz answers were 62.9% for the Thiel group and 62.4% for the formalin group ( $t(229) = 0.2$ ,  $P = 0.58$ ), although the spread of marks for individual questions varied across the questionnaire. Cronbach's Alpha for the quiz was 0.66.

<insert Table 2 here>

## DISCUSSION

No publication has yet aimed to determine if Thiel or formalin embalming might be advantageous in terms of learning anatomy. The present study found no significant evidence of either method being more valuable in terms of learning outcome, as measured with a multiple choice quiz; overall scores of both student groups were almost identical, so this result may serve as an indication that performance of students learning through dissecting with either method is similar. Alternatively, it may indicate that the quiz was an inappropriate method for evaluating the students' knowledge and understanding. The Cronbach's Alpha suggests a questionable level of internal consistency for the quiz, probably due to the low number of items included on the test.

In the present study, 92% of Thiel medical students thought that flexibility of Thiel embalmed cadavers was preserved after embalming, while only 34% of formalin

students found formalin embalmed bodies flexible, although it should be recognized that most students in each cohort had presumably little to no experience of the other embalming method. Comments from the Thiel group indicated that they found this flexibility helpful for their learning, whereas students learning with formalin embalmed specimens specifically mentioned the rigidity of specimens as a negative point. It may be argued that student perception of cadaver flexibility was merely subjective, as they had not compared cadaver flexibility before and after the embalming procedure, although some knowledge of 'normal' might have been gained from awareness of their own and others' flexibility in life. In addition, some students may have come to study at Dundee due to the reputation of the flexible Thiel cadavers, which may have influenced their attitude.

These findings support perceptions of professional anatomists and surgeons; participants in studies conducted by Hassan et al. (2015) and Eisma et al. (2011) favored Thiel cadavers over formalin embalmed for their learning due to their retention of flexibility; surgeons commented that the appearance of Thiel bodies was lifelike with 'good tissue quality' (Hassan et al., 2015). Also, clinical staff questioned by Balta et al. (2015b) preferred Thiel cadavers for various teaching purposes due to their realistic appearance and retained flexibility.

The odor of formaldehyde is a feature of formalin embalmed cadavers; comparison of experiences with Thiel bodies is therefore a relevant area of investigation. Only 21% of the Thiel group of students, compared to 33% of the formalin group, found the smell of

the embalming fluid to have a negative impact on their dissection experience, a finding supported by perceptions of staff and students (Balta et al., 2015b) and surgeons (Eisma et al., 2011; Hassan et al., 2015) in previous studies. However, it should be noted that the embalming solution used at Cardiff University contains a relatively high percentage of phenol and low percentage of formalin, so the inclusion of phenol may contribute to the unpleasant odor described.

Comparison of student attitudes suggested that identification and dissection of organs, nerves and vessels were easier in Thiel bodies, but this perception was not empirically tested. No significant differences were found for perceived identification and dissection of the musculoskeletal system, although a more detailed analysis was not undertaken. Overall, identification of anatomical structures was perceived as easier by the Thiel group than the formalin group, which agrees with attitudes gathered during surgical workshops (Eisma et al., 2011; Hassan et al., 2015). Hassan et al. (2015) investigated opinions on the ability of surgeons to identify and work with structures relevant to the trained surgical procedure; Thiel cadavers were rated as advantageous compared with formalin embalmed bodies by all participants. Eisma et al. (2011) obtained similar results; subjects rated their ability to identify muscles, vessels and nerves to be greater when working with Thiel embalmed specimens. In contrast to this and the present study, Balta et al. (2015b) reported that most participants found it easier to identify the majority of investigated structures in formalin embalmed cadavers. A possible reason for this may be the more detailed regions investigated by Balta et al. (2015b). A further factor contributing to these contradictory findings may be that most of their participants

dissected exclusively with formalin embalmed cadavers, but rated their ability to identify structures in both embalming methods. It is likely that these students were more familiar with the appearance of anatomical structures in formalin embalmed cadavers, which might have influenced their embalming method preferences and perceived ability to identify structures. There were no significant differences in terms of perception of ability to identify anatomical structures in Thiel and formalin embalmed specimens by the postgraduate students in Balta et al.'s (2015b) study; this also contradicts findings in the present investigation. Compared with undergraduate science and first and second year medical students, postgraduate students may have gathered relevant experience during previous degree qualifications and might therefore have more advanced anatomy knowledge, allowing them to identify structures in either embalming method equally well. However, due to the small number of relevant studies, their small sample sizes, and disagreement of findings, more research in this area must be undertaken.

As noted by McLachlan (2004), medical education aims to teach students the identification of structures in the living individual. If this is approached through cadaveric dissection, it appears logical that embalming of the cadaver should focus on retention of natural characteristics, although some aspects of the Thiel cadavers may be harder to envisage in the living subject, such as soft organs, whose shape is better retained by formalin cadavers.

Although results of the present study indicated that students dissecting with Thiel embalmed cadavers felt significantly more confident in recognizing and identifying

structures in the living individual, testing their ability was beyond the scope of this study. Some also commented that cadaver flexibility might be a possible advantage in their future surgical careers, but it should be borne in mind that comments from a limited number of students may not reflect the majority opinion of the student cohort.

## **Limitations**

Neither the present study nor the discussed studies provided evidence that opinions of professionals and students are reliable indicators of their ability to identify structures. Conducting anatomy spot tests in the two geographically separated institutions was not possible in the present study due to logistical constraints, but would be a more robust test if these could be overcome. In the meantime, the difference between perceived and actual skill of participants remains uncertain.

The major limitation associated with this study was related to the timing of data collection. Students should ideally have completed questionnaires immediately after their classes on the anterior forearm under test conditions, but due to constraints on travel, timing of classes and ethical approval, this was not possible. Data collection from the formalin group was carried out a few weeks after their forearm dissection, which may have resulted in them forgetting some of the material, or conversely allowed revision of material before completion of the questionnaire. Their test scores may therefore not be accurate representations of their acquired knowledge through the investigated learning method alone. In both groups, only half of the participants had engaged in the relevant dissection, while the second half had learnt from the dissection

of their peers. Although the Thiel group may have experienced an advantage, as their memory of the dissection session and the learnt anatomy was still fresh when completing the questionnaire, they were under time pressure to travel to their next class.

Since forearm anatomy is taught in different year groups in the two participating universities, it was not possible to synchronize cohorts without compromising the immediacy of the quiz post-learning. It therefore might be argued that the Thiel group had an advantage compared to the formalin group in that they had more experience with learning anatomy. This may also have influenced attitudes towards the embalming method in terms of confidence in their abilities; Thiel students were possibly less hesitant to agree or strongly agree on statements investigating their ability to identify and dissect anatomical structures.

It must also be noted that participation in the research project was voluntary and that a considerable proportion of students did not complete the questionnaire. The collected responses may therefore not represent the overall opinion or knowledge of the investigated student groups.

## CONCLUSIONS

Soft fix embalming methods such as Thiel have been adopted by some medical schools, but little investigation of the impact this change has on learning and teaching of anatomy by medical students has been carried out, although it may provide important

direction for future investment. Student attitudes suggested that Thiel embalmed specimens retain greater flexibility than formalin embalmed, and that the odor of the embalming fluid is less penetrating in Thiel embalmed cadavers. Perceived identification of organs, nerves and vessels, but not musculoskeletal structures, was suggested to be easier in Thiel than in formalin embalmed specimens. No significant differences in functional anatomy knowledge between the Thiel and formalin groups were found. Overall, Thiel embalming may provide an advantageous learning experience in some investigated areas, although more research needs to be carried out, especially to establish whether student perceptions are based on reality, at least in terms of structure identification. However, if its accepted advantages in medical and surgical courses are taken into consideration, the results of this study may support Thiel embalming as an attractive investment option for some universities.



## ACKNOWLEDGEMENTS

The authors would like to thank Dr. Alan Watson of Cardiff University for his assistance with this study.

## NOTES ON CONTRIBUTORS

LARISSA KENNEL, B.Sc. (Hons.), is a M.Sc. forensic anthropology student at the Centre for Anatomy and Human Identification at the University of Dundee, Dundee, UK. She graduated with a 1<sup>st</sup> Class Honors degree in anatomical sciences from the University of Dundee. This research study was completed as part of her final year project.

DAVID M.A. MARTIN, Ph.D., F.R.S.B., is a senior lecturer in bioinformatics in the School of Life Sciences at the University of Dundee, Dundee, UK. He is part of the core level 1 and 2 teaching team, delivering a core curriculum across all life sciences degrees and his research interest is focused on high throughput analysis of large data sets.

HANNAH M. SHAW, Ph.D., is a senior lecturer in anatomy in the School of Biosciences and Lead for the Welsh Centre for Anatomical Education at Cardiff University in Cardiff, Wales, UK. She teaches on the undergraduate medical, dental and anatomy programs and her research interests include tendon entheses and digital curation of online resources.

TRACEY WILKINSON, Ph.D., is a professor of anatomy and the Cox Chair of Anatomy at the University of Dundee in Dundee, UK. She has been involved in teaching anatomy for undergraduate and postgraduate medical, dental and anatomy students and her

research interests include biomechanics, functional anatomy, human variation and medical education.

## LITERATURE CITED

Anderson SD. 2006. Practical light embalming technique for use in the surgical fresh tissue dissection laboratory. *Clin Anat* 19:8–11.

Balta JY, Cronin M, Cryan JF, O'Mahony SM. 2015a. Human preservation techniques in anatomy: A 21<sup>st</sup> century medical education perspective. *Clin Anat* 28:725–734.

Balta JY, Lamb C, Soames RW. 2015b. A pilot study comparing the use of Thiel- and formalin-embalmed cadavers in the teaching of human anatomy. *Anat Sci Educ* 8:86–91.

Benkhadra M, Bouchot A, Gérard J, Genelot D, Trouilloud P, Martin L, Girard C, Danino A, Anderhuber F, Feigl G. 2011a. Flexibility of Thiel's embalmed cadavers: The explanation is probably in the muscles. *Surg Radiol Anat* 33:365–368.

Benkhadra M, Gérard J, Genelot D, Trouilloud P, Girard C, Anderhuber F, Feigl G. 2011b. Is Thiel's embalming method widely known? A world survey about its use. *Surg Radiol Anat* 33:359–363.

Bradbury SA, Hoshino K. 1978. An improved embalming procedure for long-lasting preservation of the cadaver for anatomical study. *Acta Anat (Basel)* 101:97–103.

Brenner E. 2014. Human body preservation – Old and new techniques. *J Anat* 224:316–344.

Brenner E, Maurer H, Moriggl B, Pomaroli A. 2003. The human cadaver as an educational tool – Classification and comparison with other educational tools. *Ann Anat* 185:229–230.

Coskey A, Gest TR. 2015. Effectiveness of various methods of formaldehyde neutralization using monoethanolamine. *Clin Anat* 28:449–454.

de Winter JC, Dodou D. 2010. Five-point Likert items: T test versus Mann-Whitney-Wilcoxon. *Pract Assess Rev Eval* 15:1–12.

Eisma R, Lamb C, Soames RW. 2013. From formalin to Thiel embalming: What changes? One anatomy department's experiences. *Clin Anat* 26:564–571.

Eisma R, Mahendran S, Majumdar S, Smith D, Soames RW. 2011. A comparison of Thiel and formalin embalmed cadavers for thyroid surgery training. *Surgeon* 9:142–146.

Eisma R, Wilkinson T. 2014. From “silent teachers” to models. *PLoS Biol* 12:e1001971.

Ezugworie J, Anibeze C, Ozoemena F. 2009. Trends in the development of embalming methods. *Internet J Alternative Med* 7:1540–1584.

Fessel G, Frey K, Schweizer A, Calcagni M, Ullrich O, Snedeker JG. 2011. Suitability of Thiel embalmed tendons for biomechanical investigation. *Ann Anat* 193:237–241.

Groscurth P, Eggli P, Kapfhammer J, Rager G, Hornung JP, Fasel JD. 2001. Gross anatomy in the surgical curriculum in Switzerland: Improved cadaver preservation, anatomical models, and course development. *Anat Rec* 265:254–256.

Guo S, Schwab A, McLeod G, Corner G, Cochran S, Eisma R, Soames R. 2012. Echogenic regional anaesthesia needles: A comparison study in Thiel cadavers. *Ultrasound Med Biol* 38:702–707.

Hammer N, Löffler S, Bechmann I, Steinke H, Hädrich C, Feja C. 2015. Comparison of modified Thiel embalming and ethanol-glycerin fixation in an anatomy environment: Potentials and limitations of two complementary techniques. *Anat Sci Educ* 8:74–85.

Hammer N, Löffler S, Feja C, Sandrock M, Schmidt W, Bechmann I, Steinke H. 2012. Ethanol-glycerin fixation with thymol conservation: A potential alternative to formaldehyde and phenol embalming. *Anat Sci Educ* 5:225–233.

Hassan S, Eisma R, Malhas A, Soames R, Harry L. 2015. Surgical simulation flexor tendon repair using Thiel cadavers: A comparison with formalin embalmed cadavers and porcine models. *J Hand Surg Eur Vol* 40:246–249.

Hauptmann M, Stewart PA, Lubin JH, Beane Freeman LE, Hornung RW, Herrick RF, Hoover RN, Fraumeni JF Jr, Blaire A, Hayes RB. 2009. Mortality from lymphohematopoietic malignancies and brain cancer among embalmers exposed to formaldehyde. *J Natl Cancer Inst* 101:1696–1708.

Hayashi S, Homma H, Naito M, Oda J, Nishiyama T, Kawamoto A, Kawata S, Sato N, Fukuhara T, Taguchi H, Mashiko K, Azuhata T, Ito M, Kawai K, Suzuki T, Nishizawa Y, Araki J, Matsuno N, Shirai T, Qu N, Hatayama N, Hirai S, Fukui H, Ohseto K, Yukioka T, Itoh M. 2014. Saturated salt solution method: A useful cadaver embalming for surgical skills training. *Medicine (Baltimore)* 93:e196.

Hayashi S, Naito M, Kawata S, Qu N, Hatayama N, Hirai S, Itoh M. 2016. History and future of human cadaver preservation for surgical training: from formalin to saturated salt solution method. *Anat Sci Int* 91:1–7.

Healy SE, Rai BP, Biyani CS, Eisma R, Soames RW, Nabi G. 2015. Thiel embalming method for cadaver preservation: a review of new training model for urologic skills training. *Urology* 85:499–504.

Hölzle F, Franz EP, Lehm Brock J, Weihe S, Teistra C, Deppe H, Wolff KD. 2012. Thiel embalming technique: A valuable method for teaching oral surgery and implantology. *Clin Implant Dent Relat Res* 14:121–126.

Janczyk P, Weigner J, Luebke-Becker A, Richardson KC, Plendl J. 2011a. A pilot study on ethanol-polyethylene glycol-formalin fixation of farm animal cadavers. *Berl Munch Tierarztl Wochenschr* 124:225–227.

Janczyk P, Weigner J, Luebke-Becker A, Kaessmeyer S, Plendl J. 2011b. Nitrite pickling salt as an alternative to formaldehyde for embalming in veterinary anatomy – A study based on histo- and microbiological analyses. *Ann Anat* 193:71–75.

Jaung R, Cook P, Blyth P. 2011. A comparison of embalming fluids for use in surgical workshops. *Clin Anat* 24:155–161.

Johnson EC, Johnson GR, Johnson M. 2012. The origin and history of embalming. In: Mayer RG (Editor). *Embalming – History, Theory, and Practice*. 5th Ed. New York, NY: McGraw-Hill. p 467–509.

Lunn R, Jahnke G, Spencer D, Garner S, Atwood S, Carter G, Ewens A, Greenwood D, Ratcliffe J, Desrosiers T, Haseman J, Jameson CW. 2010. Report on Carcinogens Background Document for Formaldehyde. 1<sup>st</sup> Ed. Research Triangle Park, NC: U.S. Department of Health and Human Services, National Toxicology Program. 512 p. URL: [https://ntp.niehs.nih.gov/ntp/roc/twelfth/2009/november/formaldehyde\\_bd\\_final.pdf](https://ntp.niehs.nih.gov/ntp/roc/twelfth/2009/november/formaldehyde_bd_final.pdf) [accessed 5 May 2017].



Macdonald GJ, MacGregor DB. 1997. Procedures for embalming cadavers for the dissecting laboratory. *Proc Soc Exp Biol Med* 215:363–365.

McLachlan JC. 2004. New path for teaching anatomy: Living anatomy and medical imaging versus dissection. *Anat Rec* 281B:4–5.

Messmer C, Kellogg RT, Zhang Y, Baiak A, Leiweke C, Marcus JR, Levin LS, Zenn MR, Erdmann D. 2010. A technique to perfuse cadavers that extends the useful life of fresh tissues: the Duke experience. *Anat Sci Educ* 3:191–194.

Mirabelli MC, Holt SM, Cope JM. 2011. Anatomy laboratory instruction an occupational exposure to formaldehyde. *Occup Environ Med* 68:375–378.

Norman GR. 2010. Likert scales, levels of measurement and the “laws” of statistics. *Adv Health Sci Educ* 15:625–632.

Prasad Rai B, Tang B, Eisma R, Soames RW, Wen H, Nabi G. 2012. A qualitative assessment of human cadavers embalmed by Thiel's method used in laparoscopic training for renal resection. *Anat Sci Educ* 5:182–186.

Piombino-Mascali D, Aufderheide AC, Johnson-Williams M, Zink AR. 2009. The Salafia method rediscovered. *Virchows Arch* 454:355–357.

Rai BP, Stolzenburg JU, Healy S, Tang B, Jones P, Sweeney C, Somani BK, Biyani CS, Nabi G. 2015. Preliminary validation of Thiel embalmed cadavers for laparoscopic radical nephrectomy. *J Endourol* 29:595–603.

Raja DS, Sultana B. 2012. Potential health hazards for students exposed to formaldehyde in the gross anatomy laboratory. *J Environ Health*. 74:36–40.

Revelle W. 2016. Package ‘Psych’; Procedures for Psychological, Psychometric, and Personality Research. 2016 Ed. Evanston, IL: Northwestern University. 383 p. URL: <https://cran.r-project.org/web/packages/psych/psych.pdf> [accessed 27 December 2016].

Richins CA, Roberts EC, Zeilmann JA. 1963. Improved fluids for anatomical embalming and storage. *Anat Rec* 146:241–243.

Shaffer K. 2004. Teaching anatomy in the digital world. *New Engl J Med* 351:1279–1281.

Takahashi S, Tsuji K, Fujii K, Okazaki F, Takigawa T, Ohtsuka A, Iwatsuki K. 2007. Prospective study of clinical symptoms and skin test reactions in medical students exposed to formaldehyde gas. *J Dermatol* 34:283–289.

Thiel W. 1992. The preservation of the whole corpse with natural color. *Ann Anat* 174:185–195.

Thiel W. 2002. Supplement to the conservation of an entire cadaver according to W. Thiel. *Ann Anat* 184:267–269.

Trompette O, Lemonnier M. 2009. Funeral embalming: The transformation of a medical innovation. *Sci Stud* 22:9–30.

Vickers Laboratories. 2017. Embalming Fluid – (No. 4). Vickers Laboratories Ltd., Pudsey, West Yorkshire, UK. URL: <http://www.viclabs.co.uk/anatomical-science/product/embalming-fluid-no-4> [accessed 29 April 2017].

Wei CN, Harada K, Ohmori S, Wei QJ, Minamoto K, Ueda A. 2007. Subjective symptoms of medical students exposed to formaldehyde during a gross anatomy dissection course. *Int J Immunopathol Pharmacol* 2:S23–S25.

Whitehead MC. 2009. Methods to reduce formaldehyde levels of cadavers. *Clin Anat* 22:421.

Whitehead MC, Savoia MC. 2008. Evaluation of methods to reduce formaldehyde levels of cadavers in the dissection laboratory. *Clin Anat* 21:75–81.

Wineski LE, English AW. 1989. Phenoxyethanol as a nontoxic preservative in the dissection laboratory. *Acta Anat (Basel)* 136:155–158.

Wolff KD, Kesting M, Mücke T, Rau A, Hölzele F. 2008. Thiel embalming technique: A valuable method for microvascular exercise and teaching of flap raising. *Microsurgery* 28:273–278.

## FIGURE LEGENDS

Figure 1. Comparison of attitudes of formalin vs. Thiel group of students towards the statement “The embalmed cadaver has retained a great amount of flexibility, which I actively utilize to explore aspects of functional anatomy”. The breakdown of response in each group is shown (Thiel group above the horizontal line at 0 respondents; formalin group below the line). The mean values for each group are shown as black rectangles, and the  $\pm$  standard deviation as a horizontal superimposed line. The mean response for Thiel was  $1.5 \pm 0.7$  and for formalin  $3.1 \pm 1.1$ .

## **Supplementary Material: Appendix 1**

1. The flexion of which muscle aids abduction of the wrist?

- a) Flexor digitorum profundus
- b) Flexor digitorum superficialis
- c) Flexor carpi radialis
- d) Flexor carpi ulnaris
- e) Palmaris longus

2. The flexion of which muscle aids adduction of the wrist?

- a) Flexor digitorum profundus
- b) Flexor digitorum superficialis
- c) Flexor carpi radialis
- d) Flexor carpi ulnaris
- e) Palmaris longus

3. Considering the body in the anatomical position, pronator teres and pronator quadratus assist with which wrist movement?

- a) Abduction
- b) Adduction
- c) Flexion
- d) Rotation of the forearm and wrist so that the palmar surface is facing anteriorly
- e) Rotation of the forearm and wrist so that the palmar surface is facing posteriorly

4. Flexor digitorum superficialis and \_\_\_\_\_ are responsible for the flexion of digits 2-5.

- a) Flexor pollicis longus
- b) Flexor digitorum profundus
- c) Flexor carpi radialis
- d) Flexor carpi ulnaris
- e) Pronator teres

5. Which muscle is responsible for the flexion of digit 1?

- a) Flexor pollicis longus
- b) Flexor digitorum profundus
- c) Flexor carpi radialis
- d) Flexor carpi ulnaris
- e) Pronator teres

6. In regard to flexion of the second to fifth fingers, what is the main difference between flexor digitorum superficialis and flexor digitorum profundus?

- a) Flexor digitorum profundus only flexes the metacarpophalangeal and the proximal interphalangeal joints, while flexor digitorum superficialis flexes the metacarpophalangeal, proximal interphalangeal and distal interphalangeal joints.
- b) Flexor digitorum superficialis flexes the metacarpophalangeal and proximal interphalangeal joints, while flexor digitorum profundus flexes the distal interphalangeal joints.
- c) Flexor digitorum superficialis flexes the metacarpophalangeal and proximal interphalangeal joints, while flexor digitorum profundus only flexes the metacarpophalangeal joints.
- d) Flexor digitorum superficialis flexes the metacarpophalangeal joints, while flexor digitorum profundus flexes the proximal interphalangeal and distal interphalangeal joints.
- e) Flexor digitorum superficialis only flexes the metacarpophalangeal and the proximal interphalangeal joints, while flexor digitorum profundus flexes the metacarpophalangeal, proximal interphalangeal and distal interphalangeal joints.

7. The picture shows the letter 'Y' of the manual alphabet. Which extrinsic flexor muscle is mainly used to perform the sign shown?

- a) Flexor carpi radialis
- b) Flexor carpi ulnaris
- c) Flexor digitorum superficialis
- d) Flexor pollicis longus
- e) Palmaris longus



8. The picture shows the 'thumbs up' sign. Which extrinsic flexor muscles are used to perform the movement?

- a) Flexor digitorum profundus, flexor pollicis longus
- b) Flexor digitorum profundus, palmaris longus
- c) Flexor digitorum superficialis, flexor digitorum profundus
- d) Flexor digitorum superficialis, flexor pollicis longus
- e) Flexor carpi ulnaris, flexor digitorum superficialis



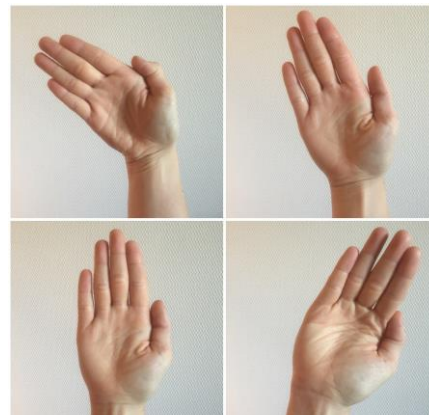
9. The picture shows the letter 'S' of the manual alphabet. Which extrinsic flexor muscles are used to perform the sign shown?

- a) Flexor carpi radialis, flexor carpi ulnaris, flexor pollicis longus
- b) Flexor carpi ulnaris, flexor pollicis longus, flexor digitorum superficialis
- c) Flexor digitorum profundus, flexor digitorum superficialis, flexor carpi radialis
- d) Flexor digitorum profundus, flexor digitorum superficialis, flexor pollicis longus
- e) Flexor digitorum profundus, flexor pollicis longus, palmaris longus



10. Which extrinsic flexor muscles are mainly used to perform the 'waving' movement shown in the picture?

- a) Flexor carpi ulnaris, flexor carpi radialis
- b) Flexor digitorum profundus, flexor carpi radialis
- c) Flexor digitorum superficialis, flexor digitorum profundus
- d) Palmaris longus, flexor carpi radialis
- e) Palmaris longus, flexor carpi ulnaris



11. What nerve(s) running in the forearm would NOT be affected by decreasing the size of the carpal tunnel?

- a) Median nerve
- b) Median nerve and radial nerve
- c) Radial nerve and ulnar nerve
- d) Radial nerve, median nerve and ulnar nerve
- e) Ulnar nerve and median nerve

12. The following muscles contribute the most to wrist flexion:

- a) Flexor carpi radialis and flexor carpi ulnaris
- b) Flexor carpi radialis and flexor digitorum superficialis
- c) Flexor carpi radialis and palmaris longus
- d) Flexor carpi ulnaris and flexor digitorum superficialis
- e) Flexor digitorum superficialis and flexor digitorum profundus