

This is an Open Access document downloaded from ORCA, Cardiff University's institutional repository: <https://orca.cardiff.ac.uk/id/eprint/105962/>

This is the author's version of a work that was submitted to / accepted for publication.

Citation for final published version:

Mahajan, D. and Votruba, Marcela 2017. A novel NR2E3 gene mutation in autosomal recessive retinitis pigmentosa with cystic maculopathy. *Acta Ophthalmologica* 95 (S259) 10.1111/j.1755-3768.2017.02682

Publishers page: <http://dx.doi.org/10.1111/j.1755-3768.2017.02682>

Please note:

Changes made as a result of publishing processes such as copy-editing, formatting and page numbers may not be reflected in this version. For the definitive version of this publication, please refer to the published source. You are advised to consult the publisher's version if you wish to cite this paper.

This version is being made available in accordance with publisher policies. See <http://orca.cf.ac.uk/policies.html> for usage policies. Copyright and moral rights for publications made available in ORCA are retained by the copyright holders.



A NOVEL NR2E3 GENE MUTATION IN AUTOSOMAL RECESSIVE RETINITIS PIGMENTOSA WITH CYSTIC MACULOPATHY

ABSTRACT

NR2E3 is a gene that encodes for photoreceptor cell specific nuclear receptor, which is involved in cone proliferation. The splice site mutation 119-2A>C in NR2E3 (15q23) has been previously reported to underlie recessive enhanced cone S sensitivity syndrome, clumped pigmentary retinal degeneration, Goldman-Favre syndrome and also autosomal dominant and autosomal recessive retinitis pigmentosa (RP). However, the mutation c 571 + 2 T > C in NR2E3 has not been previously reported with retinal disease. We report a 44-year-old male patient who presented with night blindness since birth and acute onset decreased vision, with the compound heterozygous mutation c.119-2A>C and c.571+2T>C in the NR2E3 gene. A diagnosis of retinitis pigmentosa with cystic maculopathy was made and the patient was treated with oral carbonic anhydrase inhibitors, which lead to the partial resolution of foveal cysts and an improvement in visual acuity.

KEYWORDS

NR2E3, gene, mutation, Retinitis Pigmentosa, cystic-maculopathy

INTRODUCTION

NR2E3 is a gene that encodes for photoreceptor cell specific nuclear receptor, which is involved in cone proliferation (Kobayashi M et al. 1999). It targets rhodopsin and several other opsins, which are important for sight (Milam AH et al. 2002). It is predicted to affect normal protein splicing. NR2E3 mutations lead to macular schisis, with an increase in functional S cone-like cells, thickening of retinal layers, loss of retinal lamination, S and L cone function.

CASE

A 44 year-old man presented to the eye clinic with the chief complaint of decreased vision in the right eye for the past 6 months and non-progressive lifelong difficulty of seeing in the dark. His visual acuity was 6/6 in the right eye and hand movement close to face in the left eye. Fundus examination of the right eye revealed a slightly pale tilted optic disc, retinal pigmentary changes in the mid periphery, thin vessels, partial vitreous detachment and cystic changes in the macula (Fig 1.a). Left eye fundus examination revealed vitreous haze, a pigmented macular scar with and long-standing inferior retinal detachment (Fig 1.a). Pattern ERG and oscillatory potentials in the right eye were absent, with reduced flash and flicker amplitude and increased implicit time. Significant reduced 30Hz flicker points to cone loss were present. Flash VEP revealed decreased flicker amplitude and increased implicit throughout the retina time. Full field pattern reversal VEP of the right eye revealed N75 -79 milliseconds and P100 -117 milliseconds. Electro-oculogram revealed an arden index 118% in the right eye and 145 % in the left eye. Fundus fluorescein angiography revealed angiographic evidence of leakage from perifoveal capillaries in both the eyes (Fig 1.a). OCT revealed mild

February 8, 2017

thickening in the right eye with a cystic lesion in the right macula (Fig 1.b). A possible diagnosis of retinoschisis was made and he was screened for mutation in the RSI gene, which turned out to be negative. His visual acuity in the right eye dropped to 6/36. He was prescribed Diamox (500mg po bd). His vision improved to 6/9 with the resolution of cysts after treatment with Diamox for 11 months. 6 months after discontinuing Diamox tablets, cystic spaces in the right macula increased again but the vision was stable and the patient was not keen to take Diamox because of its side effects (Fig 1.b). His present vision in the right eye is 6/9 and perception of light in the left eye. OCT shows minimal residual cysts in the right eye (Fig 1.b).

The results of the retinal panel that was screened for 176 genes associated with retinal dystrophies by next generation sequencing revealed the heterozygous NR2E3 changes,(c.119-2A>C and c.571+2T>C) (OMIM *604485). There was no family history of inherited retinal dystrophy. Mother's DNA had the same mutation but it was heterozygous, suggesting that she was a carrier. The mutation was in the trans form. The father's DNA could not be tested, as he is no longer living. A diagnosis of autosomal recessive retinitis pigmentosa with cystic maculopathy, caused by compound heterozygous mutation in the gene NR2E3 was made.

DISCUSSION

Fifty mutations in NR2E3 have been reported so far. The splice site mutation 119-2A>C in NR2E3 (15q23) has been previously reported to underlie recessive enhanced cone S sensitivity syndrome, clumped pigmentary retinal degeneration, Goldman-Favre syndrome and also

February 8, 2017

autosomal dominant and autosomal recessive retinitis pigmentosa (RP). 0.25% cases of ARRP in Caucasians are ascribed to NR2E3 gene mutations. However, the mutation c 571 + 2 T > C in NR2E3 has not been previously reported with retinal disease. The prevalence of cystoid macular edema is about 10% to 15% in RP (Adackapara CA et al. 2008) and carbonic anhydrase inhibitors enhance sub retinal fluid absorption in macular edema. Their usefulness was proven in the treatment of macular cystoid changes (Nagelhus EA et al. 2005 & Ikeda Y et al. 2012). With the advent of clinical trials for inherited retinal dystrophies, it is important to identify the genes in retinal dystrophies to facilitate the development of new therapeutic interventions.

ACKNOWLEDGEMENTS

The Authors would like to thank the European Vision & Eye Research Foundation Fellowship (EVERf) for support (DM).

BIBLIOGRAPHY

Adackapara CA, Sunness JS, DiBernardo CW, Melia BM, Dagnelie G. Prevalence of cystoid macular edema and stability in OCT retinal thickness in eyes with retinitis pigmentosa during a 48-week lutein trial. *Retina*. 2008 Jan; **28**(1): 103-10.

Ikeda Y, Hisami T, Yoshida N, Notomi S, Murakami Y, Enaida H, Ishibashi T. The clinical efficacy of a topical dorzolamide in the management of cystoid macular edema in patients with retinitis pigmentosa. *Graefes Arch Clin Exp Ophthalmol* 2012; **250**(6): 809–814.

Kobayashi M, Takezawa S, Hara K, Yu RT, Umesono Y, Agata K, Taniwaki M, Yasuda K, Umesono K "Identification of a photoreceptor cell-specific nuclear receptor". *Proceedings of the National Academy of Sciences of the United States of America* 1999; **96** (9): 4814–9.

Nagelhus EA, Mathiesen TM, Bateman AC, Haug FM, Ottersen OP, Grubb JH, Waheed A, Sly WS. Carbonic anhydrase XIV is enriched in specific membrane domains of retinal pigment epithelium, muller cells, and astrocytes. *Proc Natl Acad Sci USA* 2005; **102**(22): 8030–8035.

Milam AH et al. "The nuclear receptor NR2E3 plays a role in human retinal photoreceptor differentiation and degeneration". *Proceedings of the National Academy of Sciences of the United States of America* 2002; **99** (1): 473–8.

A novel NR2E3 gene mutation in a patient with autosomal recessive retinitis pigmentosa

February 8, 2017

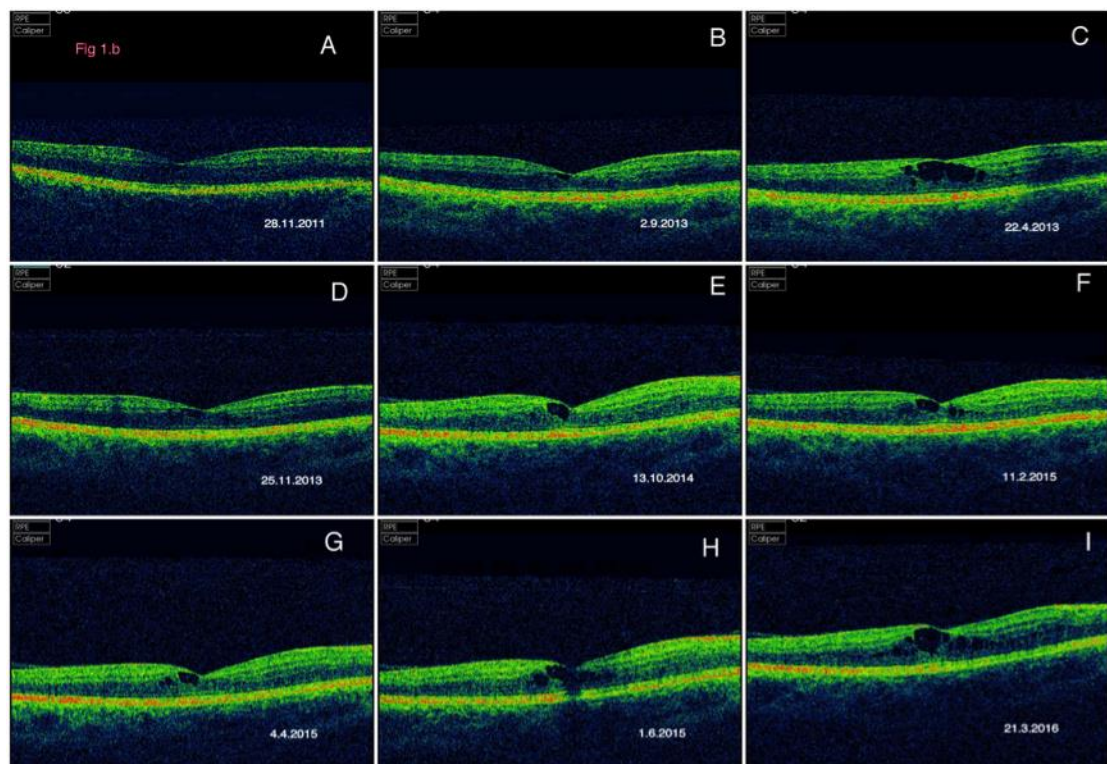
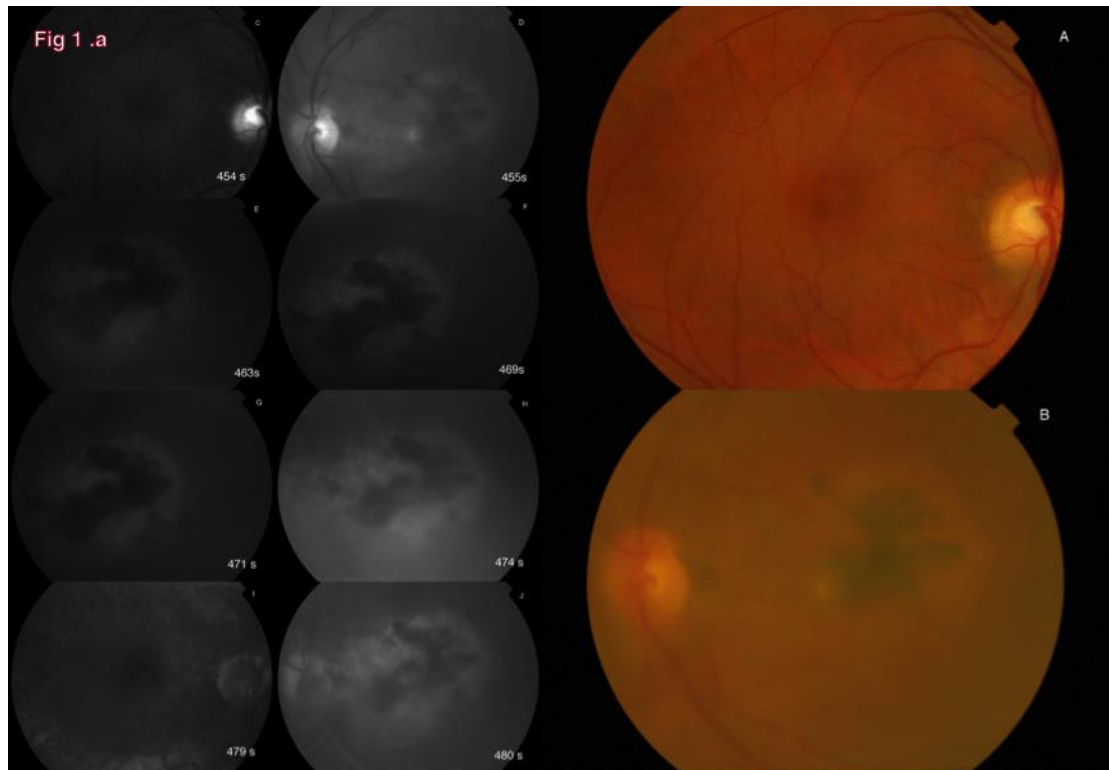


Fig 1.a: Fundus (A,B)and fundus fluorescein images (C-J)of the right and left eye

A novel NR2E3 gene mutation in a patient with autosomal recessive retinitis pigmentosa

February 8, 2017

Fig 1.b: OCT showing the progression of cystic changes at the macula