

This is an Open Access document downloaded from ORCA, Cardiff University's institutional repository: <https://orca.cardiff.ac.uk/id/eprint/108436/>

This is the author's version of a work that was submitted to / accepted for publication.

Citation for final published version:

Tang, Hiu Kwan Carolyn, Lee, Doreen Yin Hui, Thompson, Ian, Ingram, John R. , Stone, Natalie and Patel, Girish K. 2017. Delayed and localized pemphigus vulgaris after breast cancer radiotherapy. *The Breast Journal* 23 (6) , pp. 747-749. 10.1111/tbj.12910

Publishers page: <http://dx.doi.org/10.1111/tbj.12910>

Please note:

Changes made as a result of publishing processes such as copy-editing, formatting and page numbers may not be reflected in this version. For the definitive version of this publication, please refer to the published source. You are advised to consult the publisher's version if you wish to cite this paper.

This version is being made available in accordance with publisher policies. See <http://orca.cf.ac.uk/policies.html> for usage policies. Copyright and moral rights for publications made available in ORCA are retained by the copyright holders.





**Delayed and localised pemphigus vulgaris after breast cancer radiotherapy**

Journal:	<i>The Breast Journal</i>
Manuscript ID	Draft
Manuscript Type:	Case Reports
Date Submitted by the Author:	n/a
Complete List of Authors:	Tang, Hiu Kwan Carolyn; Royal Gwent Hospital Lee, Doreen Yin Hui ; Royal Gwent Hospital Thompson, Ian; Royal Gwent Hospital Ingram, John ; Cardiff University, Division of Infection & Immunity Stone, Natalie; Royal Gwent Hospital Patel, Girish; University Hospital of Wales, Department of Dermatology
Key Words:	radiotherapy, breast cancer, pemphigus

1  
2  
3  
4  
5  
6  
7  
8  
9  
10  
11  
12  
13  
14  
15  
16  
17  
18  
19  
20  
21  
22  
23  
24  
25  
26  
27  
28  
29  
30  
31  
32  
33  
34  
35  
36  
37  
38  
39  
40  
41  
42  
43  
44  
45  
46  
47  
48  
49  
50  
51  
52  
53  
54  
55  
56  
57  
58  
59  
60

## Delayed and localised pemphigus vulgaris after breast cancer radiotherapy

**Hiu Kwan Carolyn Tang<sup>1</sup>, Doreen Yin Hui Lee<sup>1</sup>, Ian  
Thompson<sup>2</sup>, John R Ingram<sup>3</sup>, Natalie Stone<sup>4</sup>, Girish K Patel<sup>5</sup>**

(1) Departments of Care of the Elderly, (2) Pathology and (4)  
Dermatology, Royal Gwent Hospital, Cardiff Road, Newport  
NP22 2UB.

(3) Division of Infection & Immunity, Cardiff University, Heath  
Park, Cardiff CF14 4XN.

(5) Welsh Institute of Dermatology, Glamorgan House, Heath  
Park, Cardiff CF14 4XN.

Correspondence:

Dr Girish K Patel

Consultant Dermatologist,

Welsh Institute of Dermatology,

Glamorgan House,

Heath Park,

Cardiff CF14 4XN.

Tel: 02920 20747747

Email: girish.patel@wales.nhs.uk

Word Count: 1004

Figures and tables: 1

Conflicts of interests: None declared.

## Abstract

Breast cancer treatment involving ionizing radiation causes characteristic radiation dermatitis in the majority of patients. The DNA damaging effects of radiation can rarely predispose to primary inflammatory dermatoses, such as pemphigus vulgaris. In such cases the disease presents with all the hallmarks of the primary dermatosis, but the eruption is limited to the field of irradiation and is often amenable to treatment. In contrast, occurrence of generalised pemphigus vulgaris in this setting may mean cancer recurrence. The mechanism by which radiotherapy induces localised disease remains unknown, but there is likely a loss of self-tolerance which maybe coupled to antigen exposure.

## Introduction

Breast cancer treatment with external beam ionizing radiation is associated with a defined pattern of overlying skin changes, occurring in 95% of individuals, characterised by acute (within weeks), sub-acute and chronic (months to years)

radiation dermatitis. Rarely radiotherapy may exacerbate or predispose to primary localised inflammatory dermatoses, which may develop after months or years.

### Case

An 84-year-old female had undergone right sided breast cancer resection followed by regional radiotherapy (total of 60Gy). After 8 months follow-up without disease recurrence, she presented with sudden onset oral ulceration followed within days by right side of the chest erosions within the confines of the original radiotherapy field (figure 1a-c). Full blood count, urea and electrolytes, liver function tests, anti-nuclear antibody and extra-nuclear antibody titres were all normal or negative. Breast mammogram was normal. A punch biopsy from the erosion and surrounding skin demonstrated intraepidermal acantholysis, with “tombstoning”, associated with a mild dermal mixed perivascular inflammatory cell infiltrate (figure 1d). A clinical diagnosis of pemphigus vulgaris was confirmed by direct and indirect immunofluorescence as well as the presence of anti-desmoglein 3 antibodies in serum. Direct immunofluorescence demonstrated intracellular binding of IgG, but not IgA or complement. Serum immunoglobulins bound monkey oesophagus tissue at a titre of 1 in 800. Enzyme-linked immunosorbent assays demonstrated the presence of antibodies that bound desmoglein 3 but not desmoglein 1. The patient responded to initial treatment with oral hygiene, topical clobetasol 17-proprionate ointment and oral prednisolone 1mg/kg. After two weeks, azathioprine 2.5mg/kg was initiated after determining a normal thiopurine methyl transferase enzyme level. Combined therapy for 6 weeks, despite reduction in the oral prednisolone dose led to complete resolution, and subsequent remission was maintained with azathioprine only.

## Discussion

The primary dermatoses such as pemphigus vulgaris can be associated with underlying malignancy. All pemphigus variants have been associated with underlying internal malignancy.<sup>1</sup> Pemphigus vulgaris is mostly linked to lymphoreticular cancers and is rarely associated with breast cancer.<sup>2</sup> Thus all patients presenting with pemphigus vulgaris should be screened for internal malignancy.

Pemphigus vulgaris autoantibodies recognise the extracellular domain of desmoglein 3, a 130kd cadherin polypeptide localised to the keratinocyte desmosome. The pemphigus vulgaris autoantibodies are released by circulating B cells, predominantly an IgG<sub>4</sub> subclass, which are directly pathogenic.<sup>3</sup> More than 50% of patients sera also contain autoantibodies to desmoglein 1 which are associated with the development of more generalised cutaneous disease. Thus patients, as in our case, with only desmoglein 3 autoantibodies can present with limited disease; in the absence of radiotherapy, 4 cases have been reported involving just the head.<sup>4-7</sup> It remains to be determined whether these presentations are attributable to a local B cell proliferation and if they would then go on to more widespread disease. In all cases of localised pemphigus vulgaris, in the absence of prior radiotherapy, remission was achieved with topical or oral glucocorticosteroids and in one case the addition of azathioprine.

Of the 17 previously reported cases of cancer radiotherapy associated pemphigus vulgaris, 6 had had breast cancer.<sup>8</sup> The mean time to onset of pemphigus vulgaris post-radiotherapy was 3 months (range 1 week to 12 months) and the mean age was 64 years (range 45-92 years), irrespective of the underlying cancer. In contrast to

1  
2  
3 classical pemphigus vulgaris, patients with radiotherapy induced pemphigus tend to  
4  
5 respond well to corticosteroids and steroid sparing agents, with rapid resolution of the  
6  
7 clinical disease. Together these findings suggest that radiotherapy promotes antigen  
8  
9 expression that is able to elicit autoimmunity that is localised to the radiotherapy field,  
10  
11 in susceptible individuals with loss of self-tolerance.  
12  
13  
14  
15  
16  
17  
18  
19  
20  
21  
22  
23  
24  
25  
26  
27  
28  
29  
30  
31  
32  
33  
34  
35  
36  
37  
38  
39  
40  
41  
42  
43  
44  
45  
46  
47  
48  
49  
50  
51  
52  
53  
54  
55  
56  
57  
58  
59  
60

For Peer Review

1  
2  
3 **Figure legends**  
4

5  
6 ***Figure 1. Localised pemphigus vulgaris after breast cancer radiotherapy.***  
7

8  
9 Characteristic features include: (a) oral ulceration, (b and c) erosions within the  
10  
11 previous radiotherapy field, and (d) epidermal suprabasal acantholysis and dermal  
12  
13 perivascular lymphohistiocytic infiltrate.  
14  
15  
16  
17  
18  
19  
20  
21  
22  
23  
24  
25  
26  
27  
28  
29  
30  
31  
32  
33  
34  
35  
36  
37  
38  
39  
40  
41  
42  
43  
44  
45  
46  
47  
48  
49  
50  
51  
52  
53  
54  
55  
56  
57  
58  
59  
60

For Peer Review

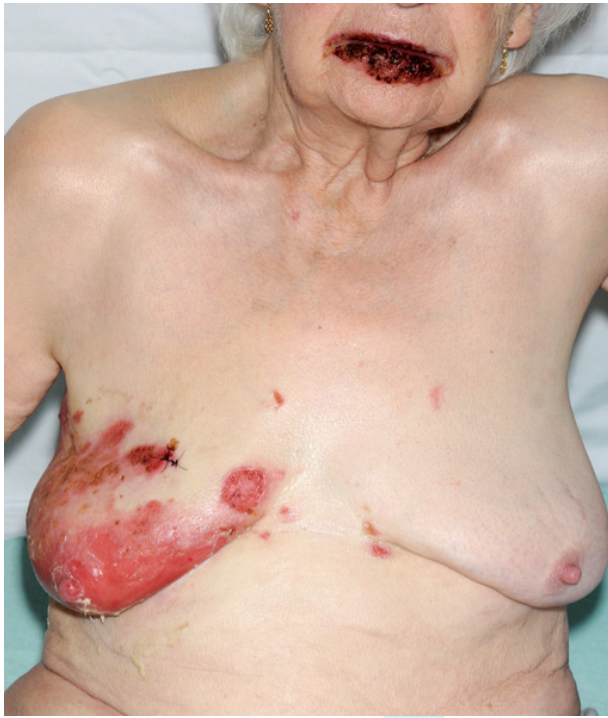

**References**

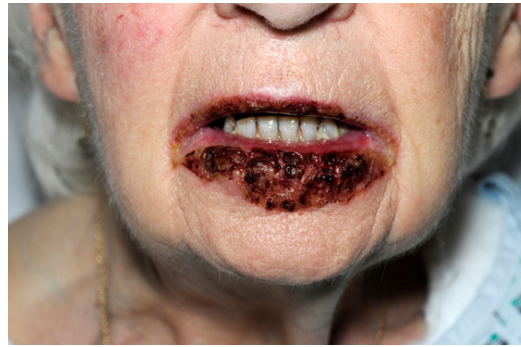1. Fried R, Lynfield Y, Vitale P, Anhalt G. Paraneoplastic pemphigus appearing as bullous pemphigoid-like eruption after palliative radiation therapy. *J Am Acad Dermatol.* 1993; 29: 815-7
2. Younus J, Ahmed AR. The relationship of pemphigus to neoplasia. *J Am Acad Dermatol.* 1990; 23: 498-502.
3. Amagai M. Towards a better understanding of pemphigus autoimmunity. *Br J Dermatol* 2000; 143: 237-8
4. Egan CA, Zone JJ. An isolated scaling plaque on the scalp. *Arch Dermatol* 1997; 133: 1304-5.
5. Lapiere K, Caers S, Lambert J. A case of long standing pemphigus vulgaris on the scalp. *Dermatology* 2004; 209: 162-3.
6. Baykal C, Azizlerli G, Thoma-Uszynski S, Hertl M. Pemphigus vulgaris localized to the nose and cheeks. *J Am Acad Dermatol* 2002; 47: 875-80.
7. Singal A, Pandhi D. Localized pemphigus vulgaris on cheeks responding to topical steroids. *Indian J Dermatol Venereol Leprol* 2009; 75: 80-1.
8. Badri T, Hammami H, Lachkham A, Benmously-Mlika R, Mokhtar I, Fenniche S. Radiotherapy-induced pemphigus vulgaris with autoantibodies targeting a 110 kDa epidermal antigen. *Int J Dermatol.* 2011; 50: 1475-9.

Figure 1

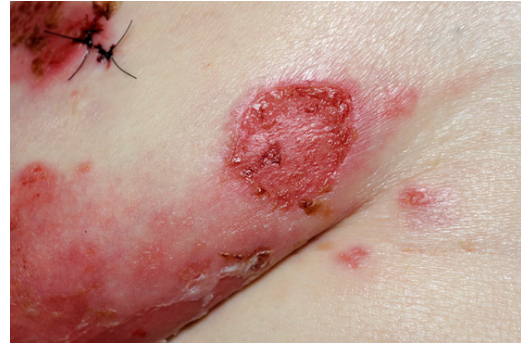A



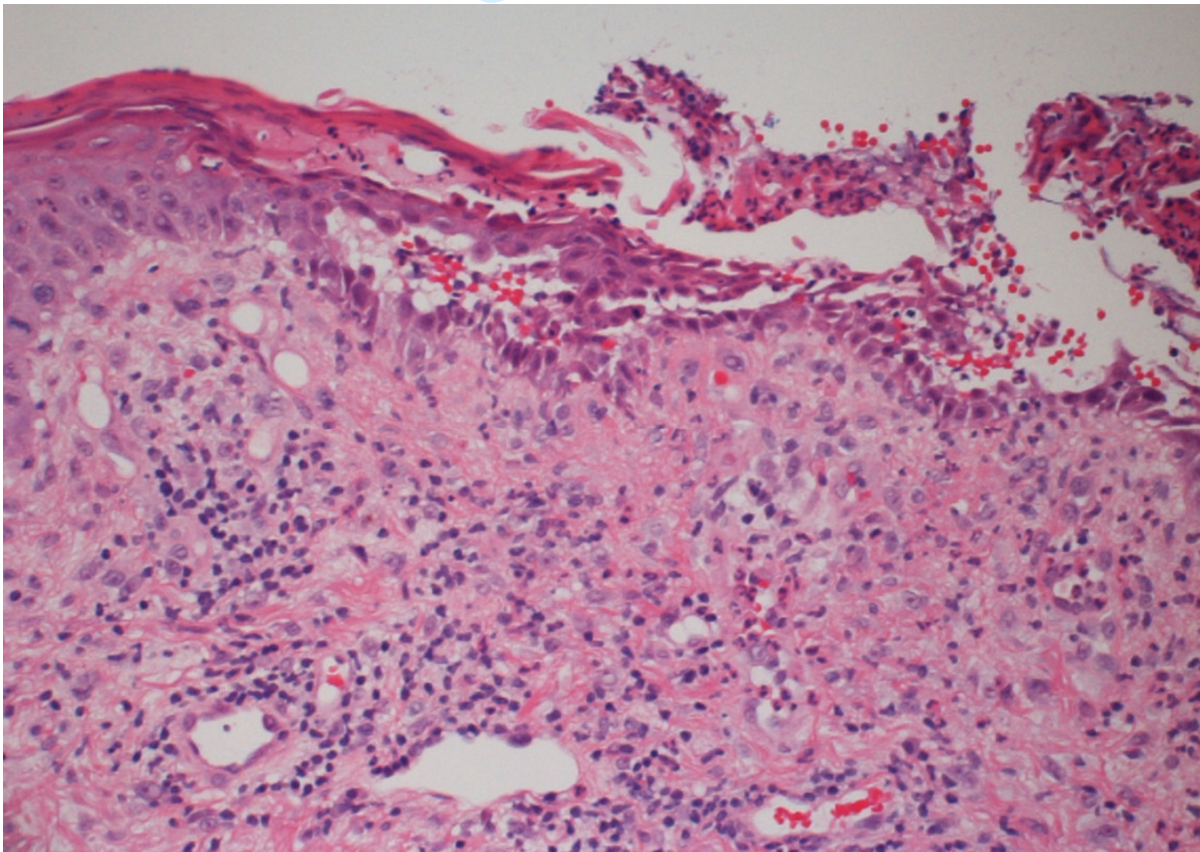
B



C



D



1  
2  
3  
4  
5  
6  
7  
8  
9  
10  
11  
12  
13  
14  
15  
16  
17  
18  
19  
20  
21  
22  
23  
24  
25  
26  
27  
28  
29  
30  
31  
32  
33  
34  
35  
36  
37  
38  
39  
40  
41  
42  
43  
44  
45  
46  
47  
48  
49  
50  
51  
52  
53  
54  
55  
56  
57  
58  
59  
60