

This is an Open Access document downloaded from ORCA, Cardiff University's institutional repository:<https://orca.cardiff.ac.uk/id/eprint/114051/>

This is the author's version of a work that was submitted to / accepted for publication.

Citation for final published version:

Tan, D., Playle, Rebecca , Harris, A., Tredwin, C. and Addy, Liam 2018. Does the gender of the subject affect perceived smile aesthetics when varying the dimensions of maxillary lateral incisors? *British Dental Journal* 225 , pp. 235-240.
10.1038/sj.bdj.2018.543

Publishers page: <http://dx.doi.org/10.1038/sj.bdj.2018.543>

Please note:

Changes made as a result of publishing processes such as copy-editing, formatting and page numbers may not be reflected in this version. For the definitive version of this publication, please refer to the published source. You are advised to consult the publisher's version if you wish to cite this paper.

This version is being made available in accordance with publisher policies. See <http://orca.cf.ac.uk/policies.html> for usage policies. Copyright and moral rights for publications made available in ORCA are retained by the copyright holders.



Does the gender of the subject affect perceived smile aesthetics when varying the dimensions of maxillary lateral incisors?

Lead author

David Tan

DF1

Cardiff University School of Dentistry

Heath Park, Cardiff, CF14 4XY

tan_david@hotmail.co.uk

Rebecca Playle

Senior Lecturer in Medical Statistics

Cardiff University School of Dentistry

Heath Park, Cardiff, CF14 4XY

playlera@cardiff.ac.uk

Andrew Harris*

Clinical Lecturer in Undergraduate Dental Studies

Plymouth University Peninsula School of Dentistry

John Bull Building

Research Way

Plymouth

PL6 8BU

Andrew.harris@plymouth.ac.uk

Christopher Tredwin

Head of school

Plymouth University Peninsula School of Dentistry

John Bull Building

Research Way

Plymouth

PL6 8BU

christopher.tredwin@pcmd.ac.uk

Last author

Liam Addy BDS MFDS MPhil FDS (REST DENT)

Consultant in Restorative Dentistry

Cardiff University School of Dentistry

Heath Park

Cardiff

CF14 4XY

addyld@cardiff.ac.uk

*Author for correspondence

Does the gender of the subject affect perceived smile aesthetics when varying the dimensions of maxillary lateral incisors?

ABSTRACT

Objective: To assess whether subject gender influences aesthetic opinion when altering the width of maxillary lateral incisors.

Method: Photographs of a male and a female smile, displaying only the lips and teeth, were digitally altered to produce images where the maxillary lateral incisor was proportioned 52%, 57%, 62%, 67%, 72% and 77% in relation to the width of the maxillary central incisor. The image was then made symmetrical. One hundred participants (50 male and 50 female) were asked to rank each set of photographs from “most” to “least attractive”.

Result: The 57% lateral incisor was considered the “most attractive” with the 77% lateral incisor the “least attractive” however no statistically significant difference existed with relation to subject or rater gender.

Conclusion: Neither the “golden proportion” nor the Recurrent Aesthetic Dental (RED) proportion was deemed the most attractive. As subject gender did not have a significant effect, dentists should work to create aesthetic results on an individual basis, operating within a so-called “golden range”.

INTRODUCTION

Clinicians are acutely aware of the psychological importance of dental aesthetics on their patient's sense of wellbeing⁽¹⁾. Numerous studies have determined a link between dental aesthetics and facial attractiveness⁽²⁻⁴⁾ as well as others' perception of intelligence and successfulness⁽⁵⁾. Klages and Zentner⁽⁶⁾ described how the perception of another's dental condition may "guide the observers to making conclusions about that person's social competence." Whether in the field of removable prosthodontics (choosing teeth for a complete denture)^(7, 8); restorative dentistry (peg laterals and tooth surface loss of the anterior dentition)^(9, 10) or orthodontics (congenitally missing maxillary lateral incisors)⁽¹¹⁾ the dentist may be required to alter the anterior dentition with the aim of achieving an aesthetic result.

What constitutes an aesthetic result remains one of the most subjective aspects of dentistry. Many attempts have been made over the years to quantify beauty and relate this to the proportions of the anterior dentition. The "golden proportion" was first described by Greek philosopher Euclid in 300 BC and since then this theory has been applied to the maxillary anterior dentition. Described as a means for arranging teeth in complete dentures by Lombardi⁽¹²⁾, and subsequently adapted by Levin⁽¹³⁾ the theory states that when viewed from the front the apparent width of the maxillary lateral incisor should be 62% of the width of the central incisor. Although used extensively, this tooth-tooth ratio is not without criticism⁽¹⁴⁻¹⁶⁾ and other approaches such as the Recurring Aesthetic Dental (RED) proportion have also been described^(15, 17, 18) as an alternative method of deciding tooth proportions. Viewed from the front, this principle is based on a linear coefficient in which the width of each successive tooth is determined by the width-height ratio of the central incisor. For a normally proportioned central incisor (78% width/height ratio) the width of the lateral incisor should be 70% of the central incisor.

Preston⁽¹⁴⁾ reported that for 58 orthodontic casts, the "golden proportion" was only found between the central and the lateral incisor in 17% of cases. Moreover, a more recent study of the "golden proportion" by Ward⁽¹⁹⁾ also queried its validity, stating that it only appears to be the most aesthetic result when applied to abnormally long teeth. Ward concluded that the golden proportion was preferred to the Preston proportion by 58% of participants for long teeth; but for normal size teeth, the Preston proportion and the Recurring Aesthetic Dental (RED) proportion were preferred to the golden proportion by 70% and 75% of assessors respectively.

Bukhary et al⁽¹¹⁾ edited photographs of a female smile, altering the widths of the maxillary lateral incisor in order to ascertain which proportion, with regards to the maxillary central incisor, was deemed the most aesthetic. Bukhary ⁽¹¹⁾ reported that the lateral incisor that appeared to be 67% of the width of the central incisor was deemed the most aesthetic, followed by the 72% proportioned lateral incisor.

Although there have been many studies both searching for and evaluating proportions within the anterior dentition, comparatively few have studied the role of subject gender in perceived aesthetics.

This study aimed to expand on the work by Bukhary⁽¹¹⁾ by evaluating whether there is variation in the perceived ideal width of the lateral incisor, depending on the gender of the subject.

MATERIALS AND METHOD

Ethical approval for this study was sought and granted by the Cardiff Dental School Research Ethics Committee.

A photograph of a male and female smile displaying only the lips, teeth and surrounding face were taken using a digital SLR camera in the Clinical Photography Department of Cardiff University Dental Hospital under the same lighting conditions. The subjects were of similar age and the only make-up worn was lipstick applied to the female model.

The images were digitally altered using Photoshop[®] (Adobe[®] Photoshop[®] CS4 Software, Adobe Systems Inc, San Jose, California). For each subject, the width of the maxillary left lateral incisor was altered at 5% intervals (52%, 57%, 62%, 67%, 72% and 77%) in relation to the subjects' maxillary left central incisor (**Figure 1**). The photographs were then altered to produce bilaterally symmetrical images. Both sets of images fulfilled the majority of the objective dental and gingival criteria of aesthetic principles⁽²⁰⁻²²⁾. Care was taken to keep the dimensions of the mouth and lips the same, only the proportions of the teeth were altered. The photographs were professionally printed on satin effect matt paper at the dimension of 10.16 x 15.24cm. Each photograph was marked with an exclusive symbol on the posterior surface as a code for identification and recording of the results, which was blinded from the participants.

Two groups were recruited from individuals attending the University Dental Hospital as either patients or dentists. Each participant consented to the study and was unpaid. All participants remained anonymous but their gender was recorded. The first group contained 34 non-dentists (17 females and 17 males). The second group contained 66 individuals, a mixture of dentists and dental students (33 females and 33 males). The ages for both groups ranged from 19 years-old to those in their 7th decade.

Each participant acted individually and was given a set of male and a set of female digitally altered photographs. This included 6 male and 6 female photographs that had been shuffled within their gender groups. The participants were asked to rank each set of photographs from the “most attractive” to the “least attractive” within each gender group. The task was completed on the same clinic over the course of a week in June, and each participant experienced similar lighting conditions. Participants were allowed 15 seconds for each photograph and an additional 30 seconds at the end to verify their choices. Participants were instructed to organise the photographs until they had achieved a definite order, provided they had not exceeded the assigned time limit. The participants were then asked if they could identify any difference between the images, recorded as “Yes” or “No”.

Data collected

The group that the rater belonged to was recorded (dentist/non-dentist') along with their gender, whether they could tell the difference between the images, the gender of the model in the photograph (subject gender) and the rank given to each photograph.

Statistical methods

The aim of this study was to assess whether the gender of the subject in the photograph played a role in governing which width of lateral incisor was considered most aesthetic. Therefore, the percentage of times an image was ranked in 1st place was compared in relation to rater group (dentist/non-dentist) and gender graphically. Summary data are also provided for the least attractive ranked photograph. Since the data are repeated assessments of the same set of photographs, subject gender was entered into a generalised linear mixed model for binomial outcomes (a repeated measures logistic regression model) to assess significant association with being ranked the most attractive. This model also included covariates for rater group

(dentist/non-dentist) , width of lateral incisor and gender of the rater. All analyses were carried out using IBM SPSS Statistics version 23 (SPSS Inc, Chicago, IL, USA).

RESULTS

The 66 dentists and dental students (66%) of the total sample of 100 raters were denoted 'dentists' with the remainder denoted 'non-dentists'. The raters were evenly split 50% males and 50% females. All one hundred raters individually assessed 12 separate photographs (6 male and 6 female), 82% said that they were able tell a difference between the images, 92.4% of dentists compared to 61.8% of non-dentists.

Figure 2 shows the distribution of photographs ranked as the most attractive for male and female photos separately. It can be seen that, regardless of subject gender, the lateral incisor that was 57% of the width of the central incisor was deemed the most aesthetic, and was ranked first by 38% of participants for the female smile and 28% for the male smile. The next preferred lateral incisor width was 52% in the female smile (25% of participants). In the male smile, it was the 62% lateral incisor (25% of the participants).

The width of the lateral incisor deemed least attractive was more consistent with regard to subject gender (**Figure 3**). The lateral incisor that was 77% of the width central incisor was ranked least attractive in 75% of male photos and 77% of female photos.

Figure 4 shows that the 57% lateral was favoured by both male and female raters, and the next preferred lateral incisor was wider when chosen by males (62% width) than females (52% width). Both male and female raters ranked the 77% lateral incisor the least attractive, with 76% of males and females ranking it last (**Figure 5**).

The width of the lateral incisor preferred by dentists and non-dentists was different (**Figure 6**). Dentists who participated in the study ranked the 57% lateral incisor first in 42.4% of cases, however the non-dentists chose the 52% lateral incisor. The variation between what was deemed the most aesthetic lateral incisor proportion was much greater in the non-dentists group. The 77% lateral incisor which was chosen first the least number of times in all previous analysis was chosen 13.3% of times, compared to only 1.5% of times by the dentists group. Although considered the least

attractive by both groups, **Figure 7** shows that the 77% lateral incisor was ranked last by 85.6% of dentists and only 57.4% of non-dentists.

A repeated measures analysis was carried out to assess if the gender of the subject was significantly associated with the ranking for attractiveness.

Neither rater gender nor the gender of the photo were statistically significant factors in determining the rank position of 1 when all other factors were accounted for. Whether raters were a dentist or not, also did not have a statistically significant effect. The only effect that was significant was the width of the lateral incisor tooth. All widths were compared to the reference width (77%). Narrower lateral incisors (52 – 62%) were significantly more likely to be selected as the most preferred rank than the wider teeth, with width 57% being the most likely to be chosen (the largest odds ratio) (**Table 1**).

DISCUSSION

The format of this study was based on the work of Bukhary et al⁽¹¹⁾ with the aim of expanding the research question to assess the impact of gender. The decision to choose 5% increments in width between the photographs was a result of the Bukhary⁽¹¹⁾ study where this value was found to be a detectable increment of change for 10 out of 12 of the participants. The narrowest width of lateral incisor was set as 52% by Bukhary⁽¹¹⁾ “to avoid bias in the lower range and to check if there are other preferred proportions lower than 62%.” In the current study the lateral incisors 57% the width of the central incisors was deemed the most attractive, therefore a range of 47% to 72% may have been more suitable. Using this range would have included significantly smaller widths of lateral incisors, perhaps representative of peg laterals – a dental malformation often considered aesthetically problematic⁽²³⁾.

When conducting the study, participants were asked if they could tell a difference between the images. The results showed that a higher percentage of dentists could tell the images apart, compared to non-dentists.

With only 61.8% of non-dentists able to tell the images apart, this meant that nearly 40% of the non-dentists ranked the images randomly. Although one is able to draw the conclusion that dentists are better able to notice subtle differences in a smile than

lay-people, it is clear that this negatively affects the validity of the results obtained from the non-dentist group.

In this study, the “golden proportion” width of lateral incisor was not deemed the most attractive for either males or females. This disagrees with studies produced by Levin⁽¹³⁾, Lombardi⁽¹²⁾, Qualtrough and Burke⁽²⁴⁾ which described the lateral incisor with 62% of the width of the central as the desired aesthetic proportion. The 62% lateral incisor was the next most popular for male subjects, which may lend support to the argument for the “golden proportion”. However, this was not the case for the female model where whilst there appeared to be a preference towards narrower lateral incisors, this was not statistically significant.

Our results were also very different to those described by Bukhary⁽¹¹⁾ where the 57% lateral incisor was only chosen by 11.4% of participants. Moreover, when one compares the data from the female photographs of this current study with Bukhary’s⁽¹¹⁾ findings it is apparent that the results show further differences. The 67% lateral incisor as described by Bukhary⁽¹¹⁾ was chosen as most attractive by 37.7% of their participants, but only by 9% of participants in the current study.

One possible reason for this stark difference may be due to the way in which the photographs were edited to create the different widths of the lateral incisor. Bukhary⁽¹¹⁾ achieved this by simply stretching or compressing the image distal to the centrals. This meant that the entire mouth (including the soft tissues of the lips) changed dimensions between the photographs. As the research question asks whether the smile aesthetics are influenced by varying the dimensions of the lateral incisor, altering the entire mouth may introduce confounding variables. The approach taken by this current study ensured that participants ranked the smiles only on the changing proportion of the teeth. Moreover, as dentists are unable to alter the musculature of the face when restoring the anterior dentition, it was thought more representative if only the teeth themselves were adjusted. This was not without drawbacks. This meant that for the current study, as the width of the lateral incisors increased, their shape became more rounded with the rest of the buccal corridor compressed. This distortion of the teeth, although more realistic to dental restorative manipulation, may have accounted for the preference towards narrower lateral incisors in the current study. It should also be noted that whilst symmetrical editing techniques employed both with the current study and by Bukhary have been shown to influence aesthetic opinion, it does not address the potential beneficial aspects to

asymmetry. It has been shown that minor asymmetries are found in even the most aesthetic smiles ⁽²⁵⁾.

The outcome of this study showed a preferred lateral incisor width of 57% of the width of the central incisor. This was different to other studies that argue against the “golden proportion”. Ward⁽¹⁹⁾ showed preference for the Recurring Aesthetic Dental (RED) proportion rather than the “golden proportion” and described how a lateral incisor 70% the width of the central was considered most attractive. Seventy-three percent (73%) of the participants in his study were male and the data from the current study suggested that males may show preference towards wider lateral incisors, perhaps accounting for the difference between these two studies. However, generalised linear modelling demonstrated that there is no evidence for a statistical difference between the width of incisors deemed most attractive by male and female assessors. It is clear, therefore, that the narrower 57% lateral incisor preferred in this study neither conforms to the “golden proportion” nor the Recurring Aesthetic Dental (RED) proportion.

The results, however, do conform to those described by Wolfart et al⁽¹⁶⁾. Their study gave a range of widths of lateral incisor (56-68%) considered most appealing as perceived by dentists. This so-called “golden range” includes the most attractive value of 57% from the current study. Likewise, this conforms to the range deduced by Ker et al ⁽²⁶⁾ (53%-76%). Although Ker only surveyed non-dentists, the current study has concluded that there is no significant difference in lateral incisor width preferred between dentists and non-dentists. However, Wolfart⁽¹⁶⁾ only used a female model and Ker a gender-neutral image. Therefore, no direct comparisons can be made between these studies with relation to gender.

The main aim of this study was to assess whether the width of lateral incisor deemed most aesthetic was different for males and female subjects. The general linear mixed model indicated that there was no statistically significant difference between which lateral incisors were preferred for male and female subjects. No statistical difference was found between preferred lateral incisor widths and whether the person ranking the photographs was male or female, or whether they were a dentist or non-dentist.

Few studies have focussed on the role of gender of the subject in dental or facial aesthetics. Khan and Abbas⁽²⁷⁾ showed that there is a significant difference between males and females, with females showing greater length of all maxillary anterior teeth

at rest. Their study did not measure differences during smiling; perhaps due to a lack of reproducibility, with other studies having described a difference between posed and spontaneous smiles⁽²⁸⁾. However, a study²² that looked at lengths of incisors during smiling found no differences between genders. This would suggest that despite this gender difference at rest; during smiling, there is little difference between length of incisors shown, or the width of lateral incisor that was considered most attractive between males and females. Indeed, Hyde et al⁽²⁹⁾ showed that experts cannot distinguish the gender of the subject from casts of the upper anterior dentition alone. Eleven experts were asked to determine the gender of 46 casts, with a 55% success rate; no better than chance. This would suggest that there is little difference between the shape and size of anterior teeth between males and females. This may account for the fact that there was no statistical difference between the preferred width of lateral incisor between male and female smiles in the current study.

One reason there may have been no statistical difference between which lateral incisor was considered most attractive may be due to a small sample size. With only 100 participants, this meant the confidence intervals were large and the sample size possibly too small to detect the effect of either the gender of the subject or the assessor. Although the data suggested a difference of opinion between dentists and non-dentists there was no statistically significant difference. This is due to the combination between a small sample size (only 34 non-dentists participated), and the inability for 38.2% of the non-dentist group to notice a difference between the images. It could therefore be surmised that it may be of benefit to repeat the study with a greater sample size. Reliability was not tested following the same methodology as Bukhary et al⁽¹¹⁾. In hindsight, considering the potential effect of this study's approach to editing the photographs, it may have been beneficial to assess reliability in a more comprehensive manner. It may also be of benefit to repeat the study with the photographs edited in the same way as Bukhary⁽¹¹⁾ to allow the studies to be more readily compared.

CONCLUSION

Neither the 62% “golden proportion” nor the 70% Recurring Aesthetic Dental (RED) proportion was deemed the most attractive in the current study. Instead the lateral incisor that was 57% the width of the central was deemed the most aesthetic. This highlights the subjectivity of the notion of attractiveness and reinforces the idea of a “golden range” in which the most attractive proportions lie.

There was no statistical difference between the preferred width of lateral incisor and whether the subject was male or female, whether the assessor was male or female or whether they were a dentist or non-dentist.

Further studies involving larger sample sizes and standardised images would prove valuable in assessing whether the smile aesthetics influenced by varying the dimensions of the maxillary lateral incisor are different in males and females.

Therefore, dentists should work with patients on an individual basis to create the most aesthetic result rather than on assumptions based on the patient’s gender.

REFERENCES

1. Davis LG, Ashworth PD, Spriggs LS. Psychological effects of aesthetic dental treatment. *J Dent.* 1998;26(7):547-54.
2. Janson G, Branco NC, Morais JF, Freitas MR. Smile attractiveness in patients with Class II division 1 subdivision malocclusions treated with different tooth extraction protocols. *Eur J Orthod.* 2014;36(1):1-8.
3. Lauria A, Rodrigues DC, de Medeiros RC, Moreira RW. Perception of oraland maxillofacial surgeons, orthodontists and laypersons in relation to the harmony of the smile. *J Craniomaxillofac Surg.* 2014;42(8):1664-8.
4. Van der Geld P, Oosterveld P, Van Heck G, Kuijpers-Jagtman AM. Smile attractiveness. Self-perception and influence on personality. *Angle Orthod.* 2007;77(5):759-65.
5. Dion K, Berscheid E, Walster E. What is beautiful is good. *J Pers Soc Psychol.* 1972;24(3):285-90.
6. Klages U, Zentner A. Dentofacial aesthetics and quality of life. *Seminars in Orthodontics* 2007. p. 104-15.
7. Vasantha Kumar M, Ahila SC, Suganya Devi S. The science of anterior teeth selection for a completely edentulous patient: a literature review. *J Indian Prosthodont Soc.* 2011;11(1):7-13.

8. Kurt A, Isik-Ozkoh G. Conventional methods for selecting form, size, and colour of maxillary anterior teeth: review of the literature.: *Eur J Prosthodont*; 2015. p. 57-63.
9. Berkowitz GS, Silver J, Widman A. Interdisciplinary approach for the management of peg lateral incisors in adolescents. *J Mass Dent Soc*. 2012;61(2):40-1.
10. Qureshi T. Composite edge bonding- the reverse triangle technique. *Dent Update*; 2016. p. 95-7.
11. Bukhary SM, Gill DS, Tredwin CJ, Moles DR. The influence of varying maxillary lateral incisor dimensions on perceived smile aesthetics. *Br Dent J*. 2007;203(12):687-93.
12. Lombardi RE. The principles of visual perception and their clinical application to denture esthetics. *J Prosthet Dent*. 1973;29(4):358-82.
13. Levin EI. Dental esthetics and the golden proportion. *J Prosthet Dent*. 1978;40(3):244-52.
14. Preston JD. The golden proportion revisited. *J Esthet Dent*. 1993;5(6):247-51.
15. Ward DH. Proportional smile design using the recurring esthetic dental (red) proportion. *Dent Clin North Am*. 2001;45(1):143-54.
16. Wolfart S, Thormann H, Freitag S, Kern M. Assessment of dental appearance following changes in incisor proportions. *Eur J Oral Sci*. 2005;113(2):159-65.
17. Pini NP, de-Marchi LM, Gribel BF, Ubaldini AL, Pascotto RC. Analysis of the golden proportion and width/height ratios of maxillary anterior dentition in patients with lateral incisor agenesis. *J Esthet Restor Dent*. 2012;24(6):402-14.
18. Raj V. Esthetic paradigms in the interdisciplinary management of maxillary anterior dentition-a review. *J Esthet Restor Dent*. 2013;25(5):295-304.
19. Ward DH. A study of dentists' preferred maxillary anterior tooth width proportions: comparing the recurring esthetic dental proportion to other mathematical and naturally occurring proportions. *J Esthet Restor Dent*. 2007;19(6):324-37; discussion 38-9.
20. Ahmad I. Anterior dental aesthetics: Dental perspective. *Br Dent J*. 2005;199(3):135-41;quiz 74.
21. Ahmad I. Anterior dental aesthetics: gingival perspective. *Br Dent J*. 2005;199(4):195-202.
22. Bhuvaneshwaran M. Principles of smile design. *J Conserv Dent*. 2010;13(4):225-32.

23. Hua F, He H, Ngan P, Bouzid W. Prevalence of peg-shaped maxillary permanent lateral incisors: A meta-analysis. *Am J Orthod Dentofacial Orthop.* 2013;144(1):97-109.
24. Qualtrough AJ, Burke FJ. A look at dental esthetics. *Quintessence Int.* 1994;25(1):7-14.
25. Peck S, Peck L. Selected aspects of the art and science of facial esthetics. *Semin Orthod.* 1995;1(2):105-26.
26. Ker AJ, Chan R, Fields HW, Beck M, Rosenstiel S. Esthetics and smile characteristics from the layperson's perspective: a computer-based survey study. *J Am Dent Assoc.* 2008;139(10):1318-27.
27. Khan F, Abbas M. The mean visible labial length of maxillary and mandibular anterior teeth at rest. *J Coll Physicians Surg Pak.* 2014;24(12):931-4.
28. Mishima K, Nakano A, Umeda H, Shiraishi R, Ueyama Y. Gender differences in posed smiles using principal component analysis. *J Craniomaxillofac Surg.* 2015;43(1):144-8.
29. Hyde TP, McCord F, Macfarlane T, Smith J. Gender aesthetics in the natural dentition. *Eur J Prosthodont Restor Dent.* 1999;7(1):27-30.

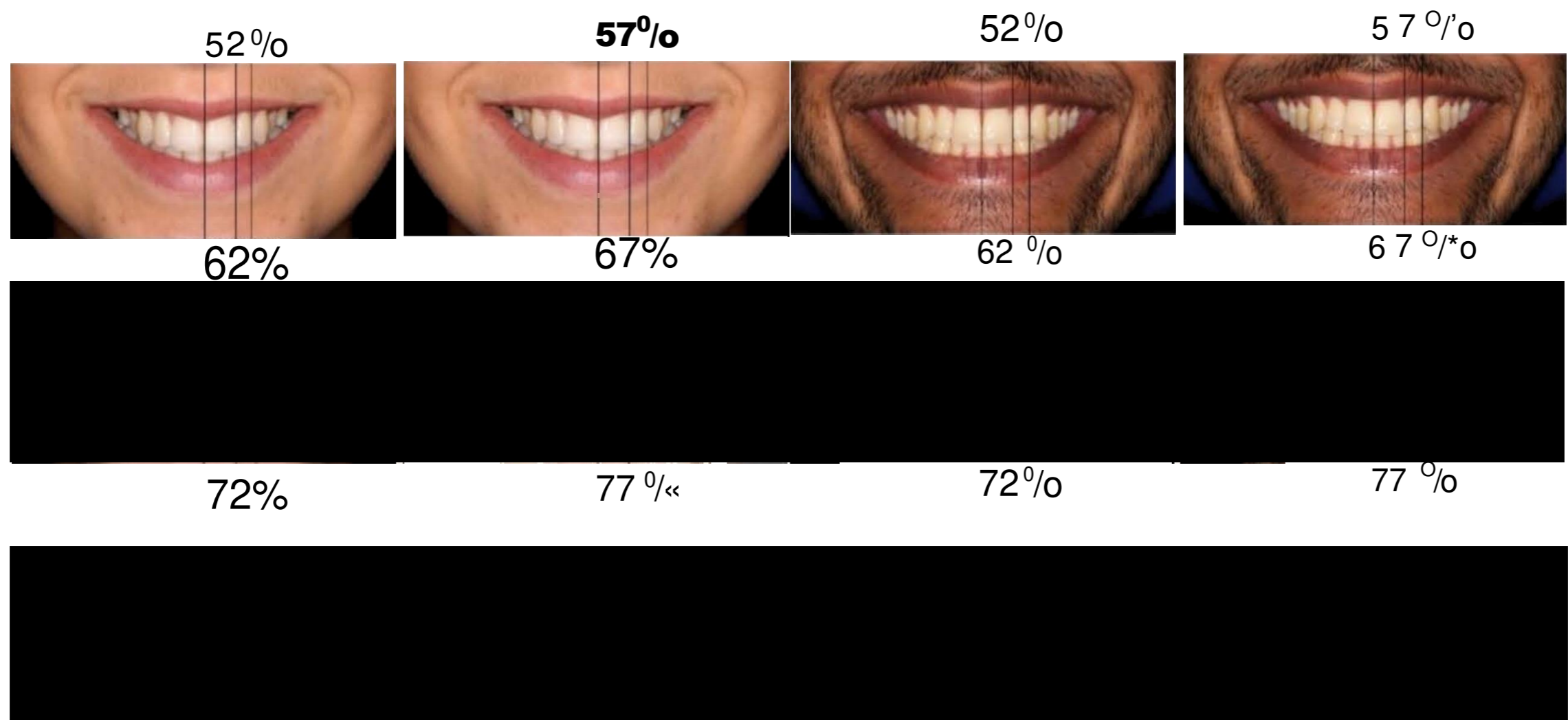


Figure 1. Female and male photographs with measurements for display purposes only. The percentages are of the increasing width of the lateral incisors relative to the central incisors.

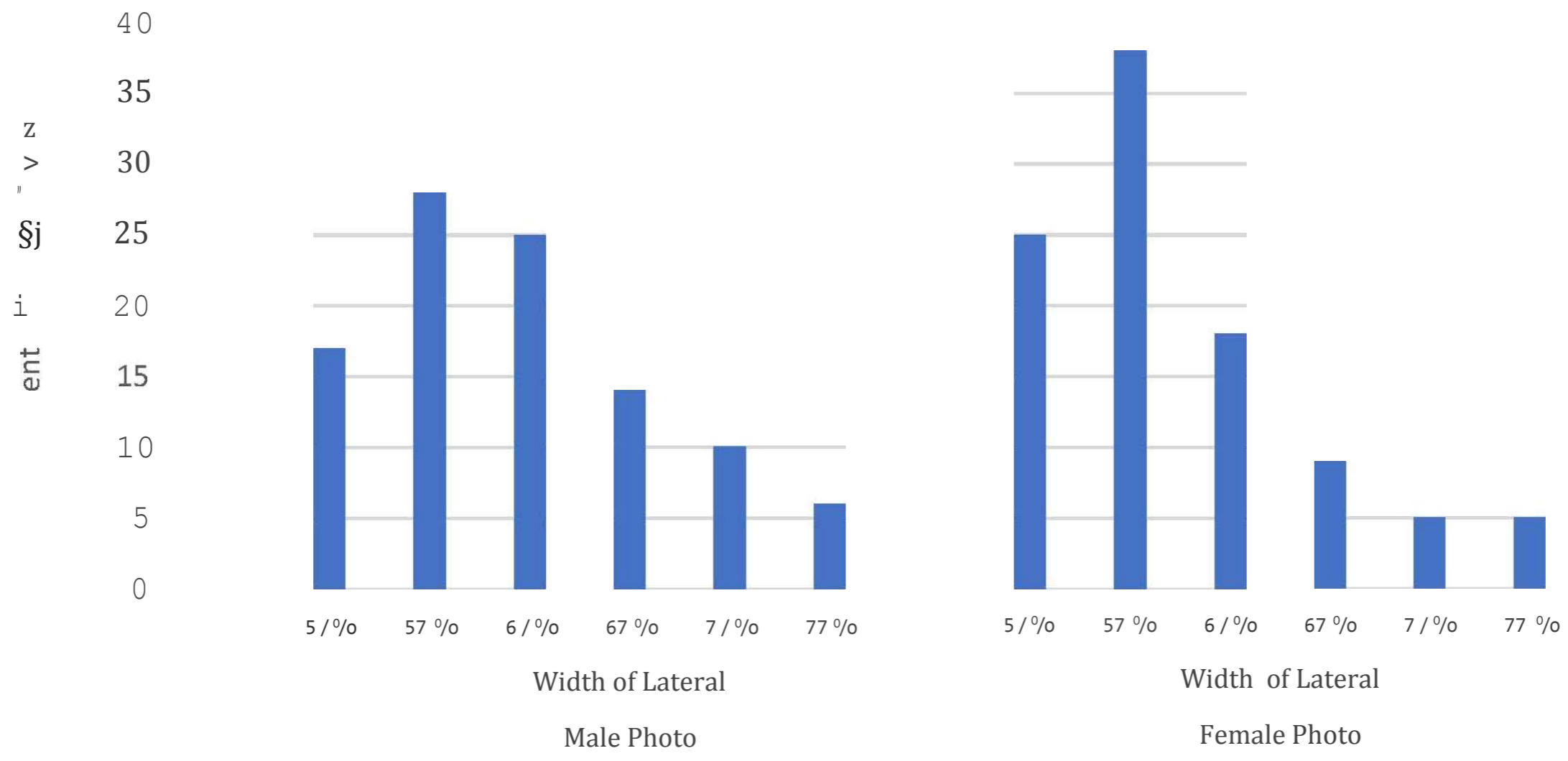


Figure 2 Lateral incisor width ranked the most attractive by subject gender

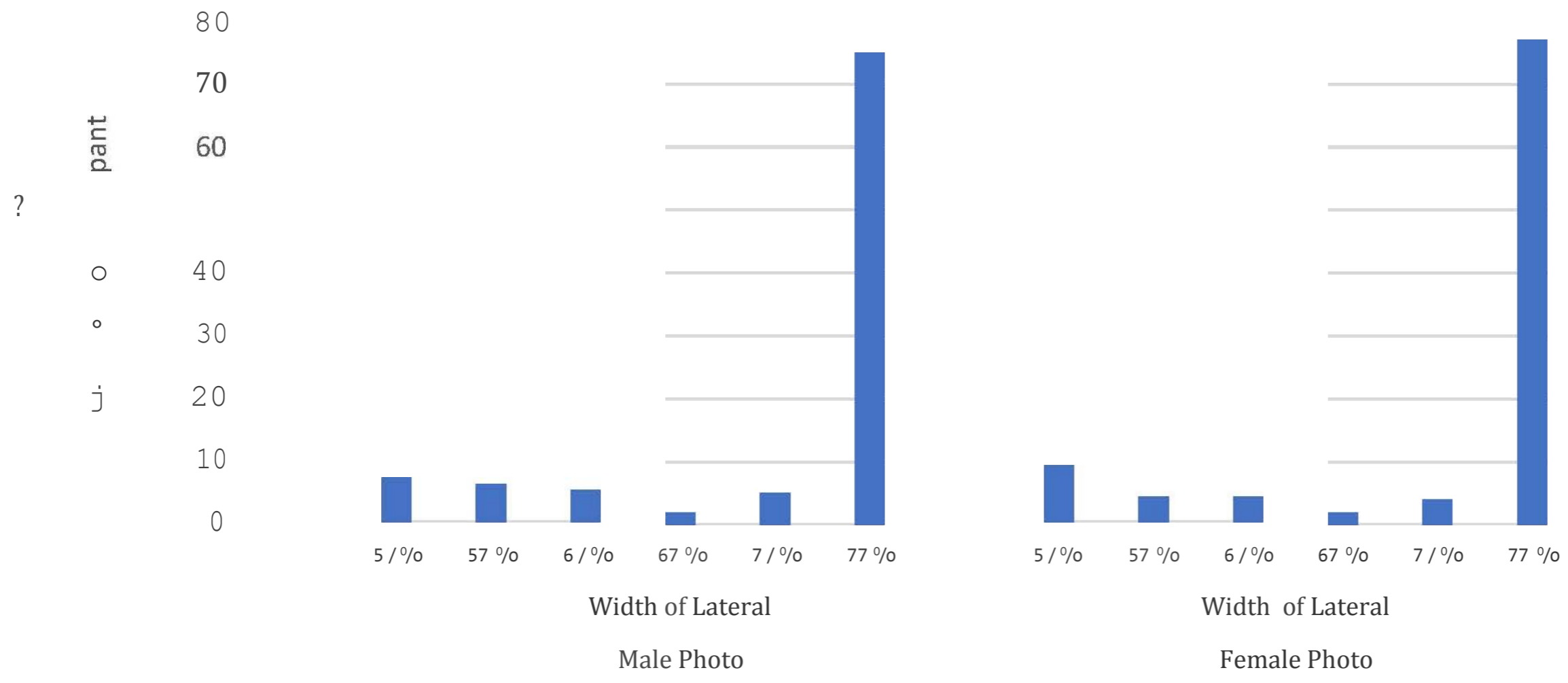


Figure 3 Lateral incisor width ranked the least attractive by subject gender

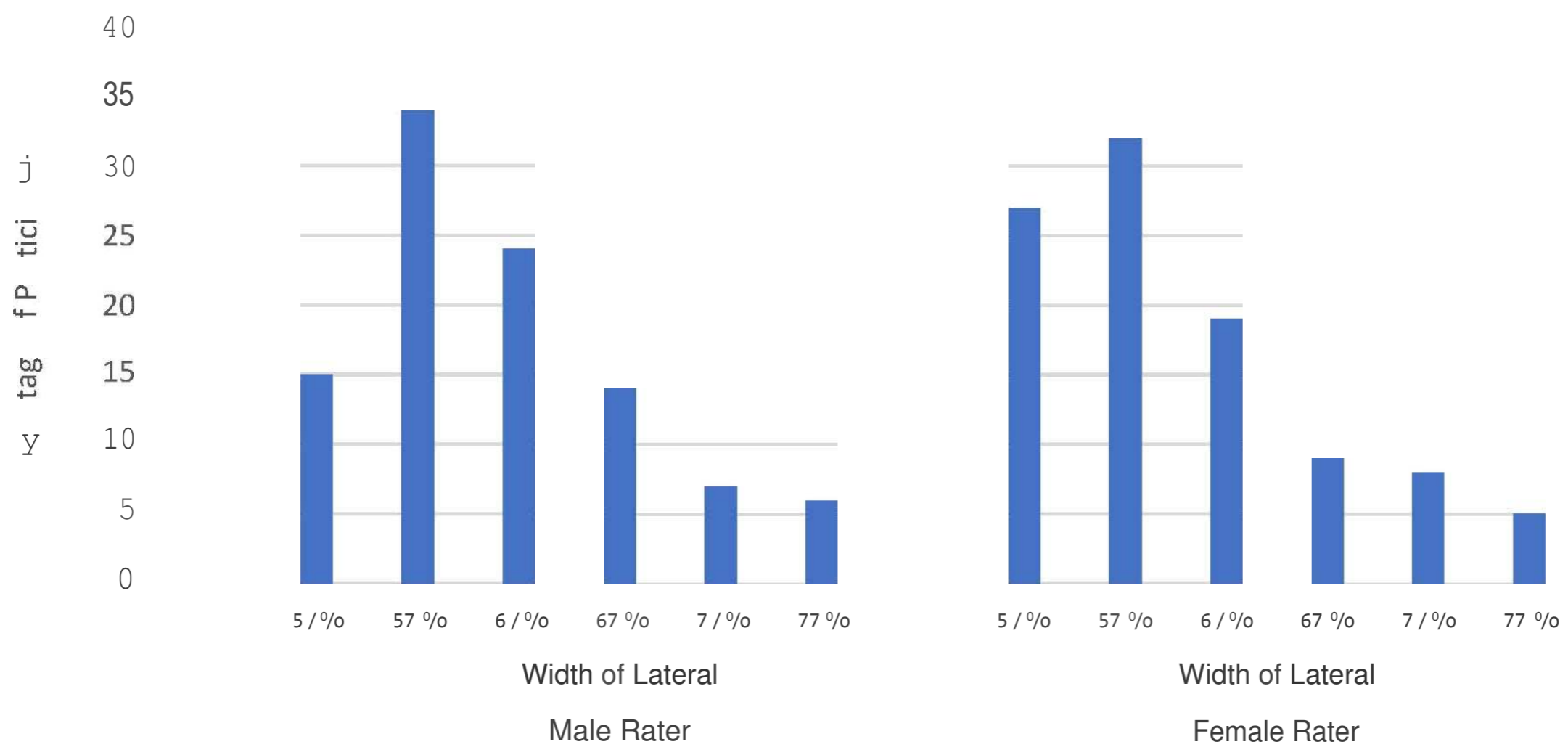


Figure 4 Lateral incisor width ranked the most attractive by rater gender

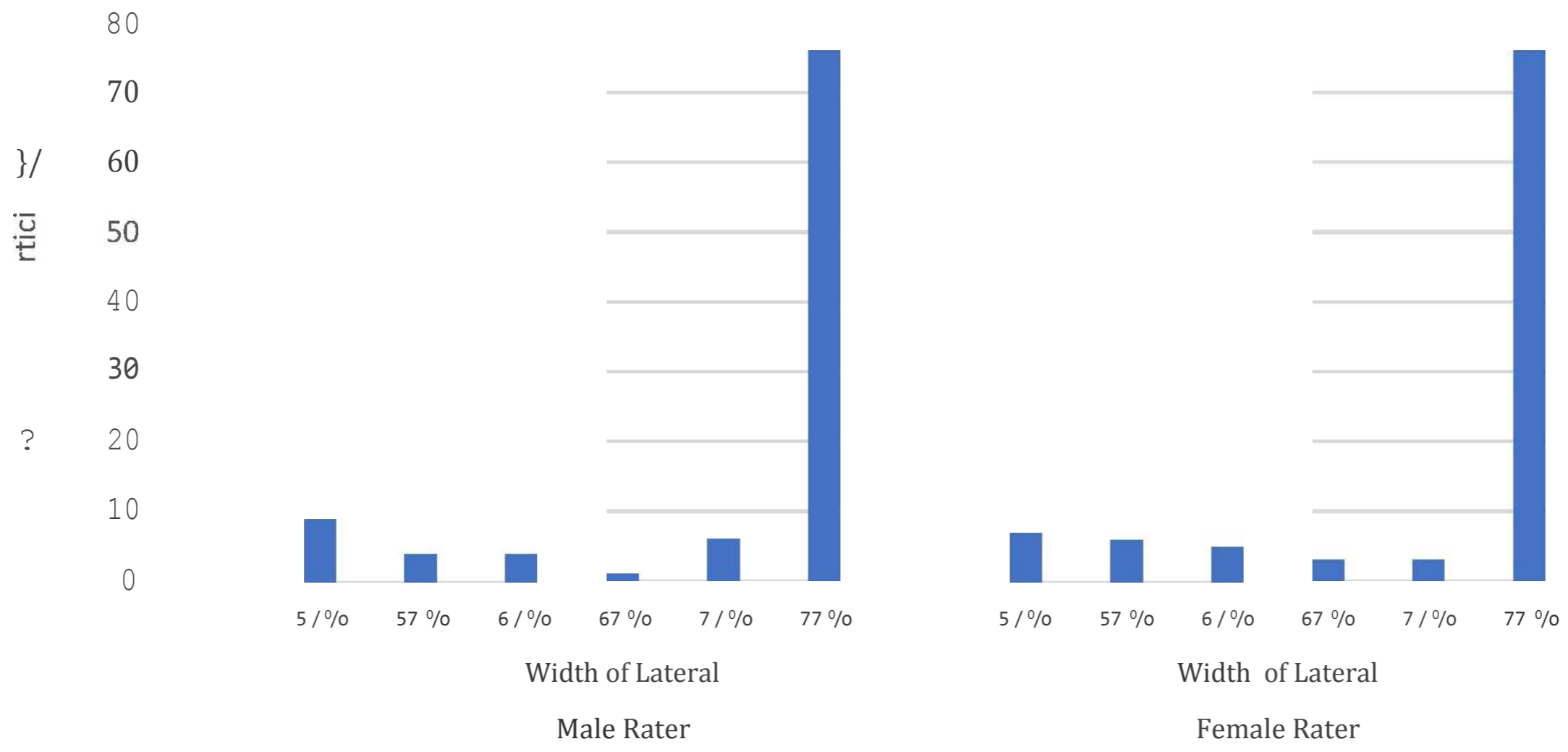


Figure 5 Lateral incisor width ranked the least attractive by rater gender

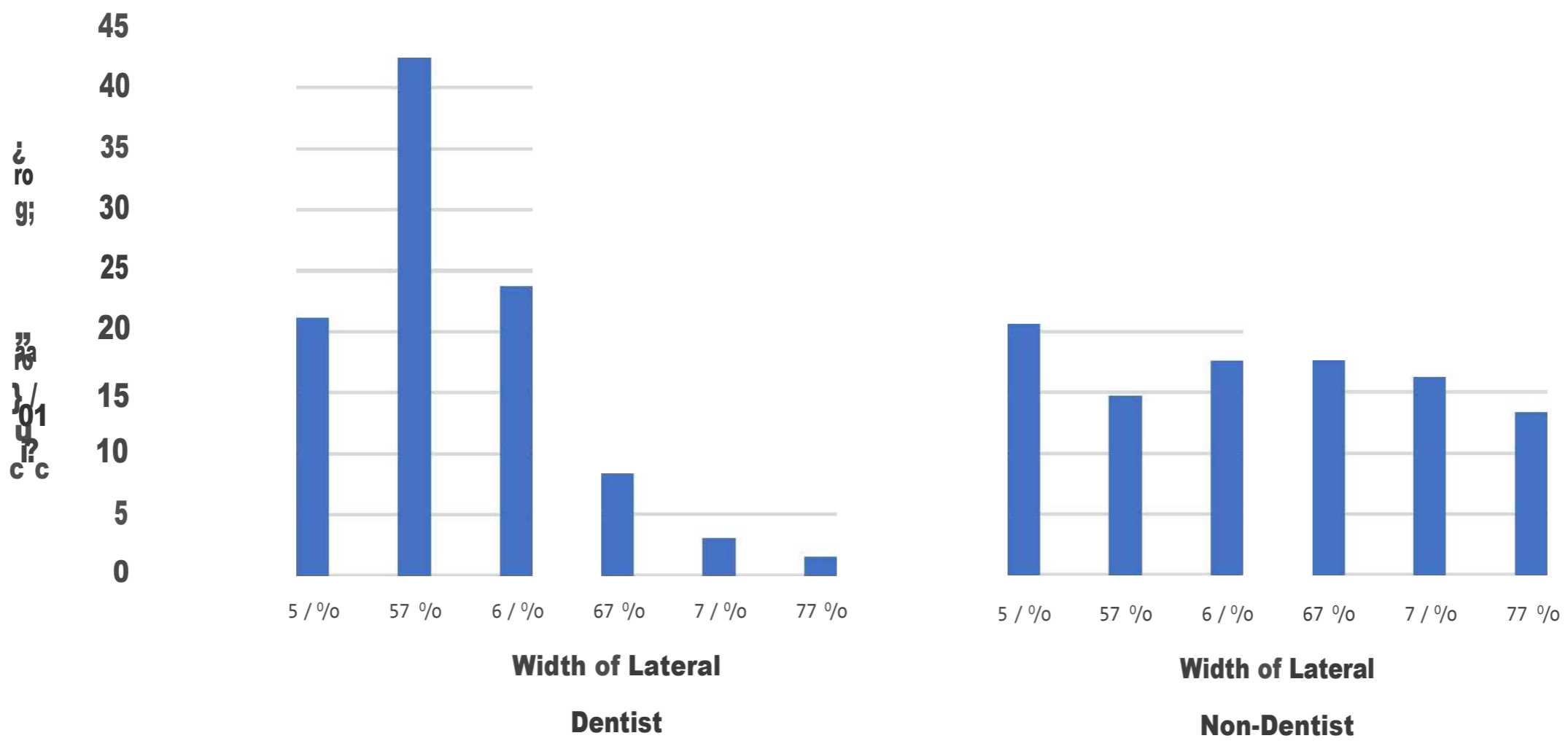


Figure 6 Lateral incisor width ranked the most attractive by rater profession

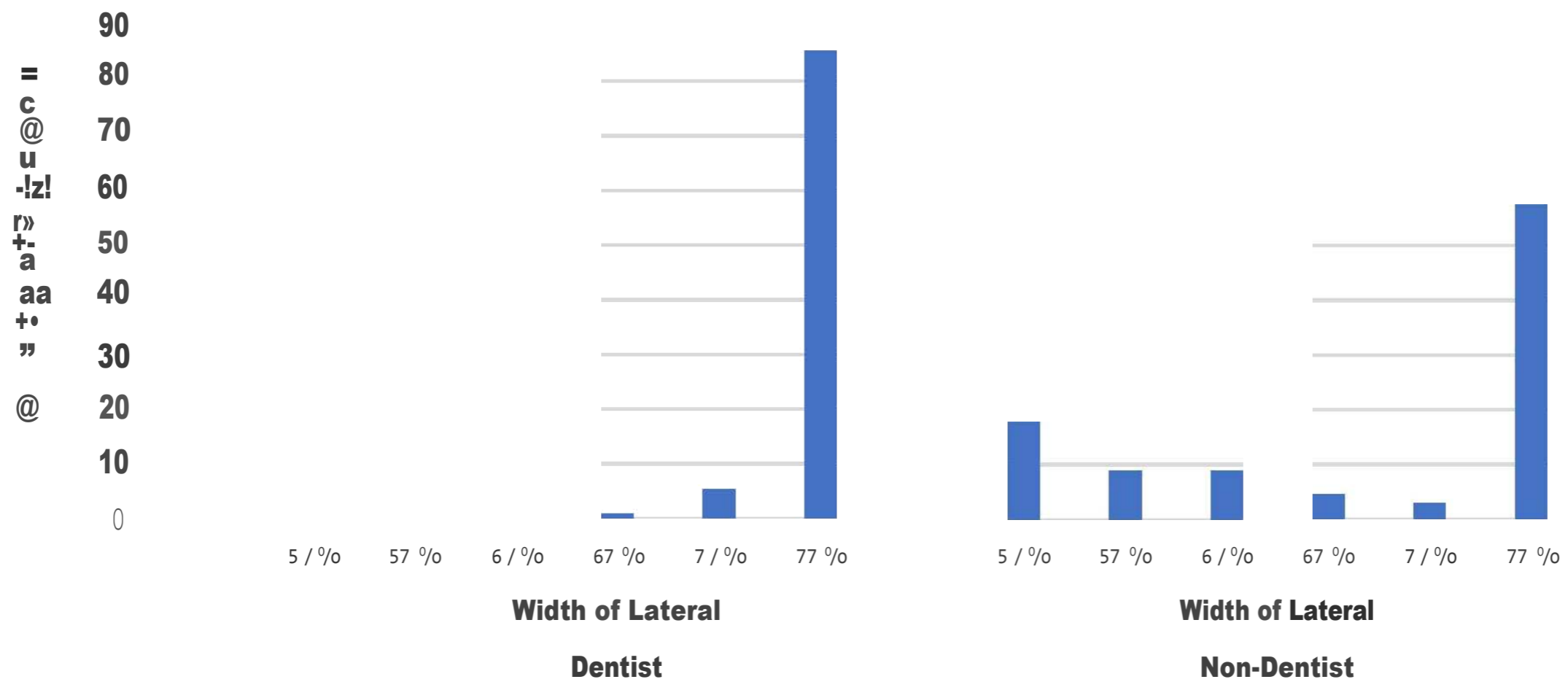


Figure 7 Lateral incisor width ranked the least attractive by rater professions

	Odds ratio	95 %o(/l	P-value
Assessor gender (reference is female)			
Female	1.003	(0.732 to 1.374)	0.986
Photo gender (reference is female)			
Female	1.068	(0.686 to 1.664)	0.770
Profession (reference is non-dentist)			
Dentist	1.003	(0.720 to 1.398)	0.985
Width			
52	4.556	(1.923 to 10.796)	0.001
57	8.451	(3.628 to 19.685)	<0.001
62	4.690	(4.690 to 11.100)	<0.001
67	2.223	(0.900 to 5.490)	0.083
72	1.384	(0.534 to 3.585)	0.504
77 (reference)			

Table 1 Generalised linear model of most attractive ranking