

This is an Open Access document downloaded from ORCA, Cardiff University's institutional repository: <https://orca.cardiff.ac.uk/id/eprint/120737/>

This is the author's version of a work that was submitted to / accepted for publication.

Citation for final published version:

Hadjivassiliou, Marios, Croall, Iain D., Zis, Panagiotis, Sarrigiannis, Ptolemaios G., Sanders, David S., Aeschlimann, Pascale, Grunewald, Richard A., Armitage, Paul A., Connolly, Daniel, Aeschlimann, Daniel and Hoggard, Nigel 2019. Neurological deficits in patients with newly diagnosed coeliac disease are frequent and linked to TG6 autoimmunity. *Clinical Gastroenterology and Hepatology* 17 (13) , 2678-2686.e2. 10.1016/j.cgh.2019.03.014

Publishers page: <https://doi.org/10.1016/j.cgh.2019.03.014>

Please note:

Changes made as a result of publishing processes such as copy-editing, formatting and page numbers may not be reflected in this version. For the definitive version of this publication, please refer to the published source. You are advised to consult the publisher's version if you wish to cite this paper.

This version is being made available in accordance with publisher policies. See <http://orca.cf.ac.uk/policies.html> for usage policies. Copyright and moral rights for publications made available in ORCA are retained by the copyright holders.



Neurological deficits in patients with newly diagnosed Coeliac Disease are frequent and linked to TG6 autoimmunity

Short Title: neurological deficits in patients with CD

Marios Hadjivassiliou MD, Iain D Croall PhD^{*}, Panagiotis Zis MD,

Ptolemaios G Sarrigiannis MD, David S Sanders MD^{*},

Pascale Aeschlimann BSc^{*},

Richard A Grünewald DPhil, Paul A Armitage MD^{*},

Daniel Connolly MD^{*}, Daniel Aeschlimann PhD^{*\$}, Nigel Hoggard MD^{*\$}

Academic Department of Neurosciences, Departments of Gastroenterology^{*}
and Neuroradiology^{*}, Sheffield Teaching Hospitals NHS Trust, Sheffield, UK

Matrix Biology and Tissue repair Research Unit, College of Biomedical and
Life Sciences^{*}, School of Dentistry, Cardiff University, Cardiff UK.

\$ = contributed equally to this work.

Grant Support: Coeliac UK and Bhardan Research and Education Trusts
(BRET) for their financial support

Abbreviations: CD coeliac disease, GFD gluten-free diet

Author for correspondence: Marios Hadjivassiliou

Academic Department of Neurosciences, Sheffield Teaching Hospitals NHS
Trust, Sheffield, S10 2JF, UK m.hadjivassiliou@sheffield.ac.uk

[tel +44 114 2712502](tel:+441142712502), [fax +44 114 2711901](tel:+441142711901)

Disclosures: The authors have nothing to disclose; DA serves as a scientific
advisor / collaborator to Zedira (without financial incentives) but receives
royalties from Zedira for patents

Author contributions: MH, DA, DSS and NH were involved in the conception and design of the study. All authors were involved in the data acquisition and analysis. All authors contributed to data interpretation and drafting portions of the manuscript. MH wrote the first draft and all authors were involved in the critical revision and production of the final manuscript. All authors have seen and approved the final version of the manuscript.

Abstract

Background & aims: Coeliac disease (CD) is an autoimmune disorder triggered by the ingestion of gluten, affecting 1% of the population and presenting with gastrointestinal symptoms, weight loss and anemia. We evaluated the presence of neurological deficits and investigated if the presence of TG6 autoantibodies increases the risk of neurological involvement in patients with newly diagnosed CD presenting to gastroenterologists.

Methods: Prospective cohort study at a secondary care gastroenterology centre. Neurological evaluation included neurological history, examination, MRI brain, MR spectroscopy of the cerebellum and serological measurements for TG6 autoantibodies. The first half of patients recruited underwent repeat MR spectroscopy at one year after gluten-free diet (GFD).

Results: 100 patients with newly diagnosed CD were recruited. Gait instability was reported in 24%, persisting sensory symptoms in 12%, and frequent headaches in 42% of patients. Gait ataxia was found in 29%, nystagmus in 11% and distal sensory loss in 10%. 60% had abnormal MRI with abnormal MR spectroscopy of the cerebellum in 47%, and/or brain white matter lesions above what is expected from age in 25%. 40% of patients had circulating TG6 autoantibodies and displayed significant atrophy of subcortical brain regions, when compared to patients without TG6 autoantibodies. In those patients with abnormal spectroscopy, repeat MR spectroscopy of the cerebellum at 1 year revealed improvement following GFD.

Conclusions: In newly diagnosed patients with CD presenting to gastroenterologists, neurological deficits are common as are autoantibodies to TG6. The significantly reduced regional brain volume in patients with TG6 autoantibodies provides evidence for a direct link between autoimmunity to TG6 and brain atrophy in CD.

Keywords: coeliac disease; neurological dysfunction; TG6 antibodies; brain imaging

What You Need to Know

Background: Patients with CD can sometimes present exclusively with neurological dysfunction but little is known of any neurological involvement at the time of diagnosis of classic CD in patients presenting to gastroenterologists.

Findings: In adult patients with CD presenting to gastroenterologists, neurological deficits are very common at the time of diagnosis. The presence of TG6 autoantibodies (a neuronal expressed transglutaminase) in these patients is associated with regional brain atrophy.

Implications for patient care: These findings further emphasize the need for early diagnosis of CD and strict adherence to a gluten-free diet in order to avoid permanent neurological disability.

Introduction

Coeliac Disease (CD) is an autoimmune disorder triggered by the ingestion of gluten in genetically susceptible individuals. It affects 1% of the population.¹

CD belongs to the spectrum of gluten-related disorders that encompass diverse manifestations including Dermatitis Herpetiformis (DH), and neurological dysfunction, the commonest of which is gluten ataxia (GA).²

It remains unclear as to why in some patients the initial presentation is with gastrointestinal symptoms of bloating, abdominal pain, diarrhea, and weight loss, whilst in others it is primarily or exclusively with an itchy vesicular skin rash (as in DH) or with neurological manifestations such as GA.^{3,4,5}

One possible explanation may lie in the primary immunological response targeting different potential auto-antigens (transglutaminases) and thus driving the respective type of primary clinical manifestation. This would be in keeping with the discovery of TG2 being the autoantigen in CD, TG3 the autoantigen in DH and TG6 the autoantigen in neurological manifestations.^{6,7,8,9}

The degree of overlap between CD and extraintestinal clinical manifestations remains unknown, as does the potential for future development of such manifestations with continuous exposure to gluten.

It is generally assumed that neurological symptoms and dysfunction in patients with newly diagnosed classical CD presenting to gastroenterologists are rare. To our knowledge, no study has utilized both detailed neurological examination and brain imaging with MR spectroscopy to systematically

evaluate large numbers of patients with classical CD presenting to the gastroenterologists for any neurological dysfunction.

The primary aim of this study was therefore to establish if TG6 autoimmunity in the context of newly diagnosed CD patients is a marker of current neurological dysfunction. Secondly to establish the true prevalence of neurological involvement as identified by detailed brain imaging and neurological clinical history and examination at the time of diagnosis of CD, in patients presenting to gastroenterology clinics. Thirdly to prospectively study any changes on neuroimaging 12 months after the diagnosis of CD and the introduction of gluten-free diet (GFD).

Methods

Patient selection and clinical assessments

This was a 3-year prospective study based at the Department of Gastroenterology, Academic Department of Neurosciences and Academic Department of Neuroradiology, Sheffield Teaching Hospitals NHS Trust, Sheffield, UK. The study (STH18452) was approved by the South Yorkshire Research Ethics Committee and informed consent was obtained from all participants. All patients were referred by their General Practitioners for investigation of possible CD to a dedicated gastroenterology clinic run by one of the authors (DSS). All patients were from the catchment area of the Sheffield Teaching Hospitals NHS Trust.

Consecutive patients with newly diagnosed CD following gastroscopy and duodenal biopsy were approached for participation during their gastroenterology appointment immediately after the biopsy results confirming

CD became available. A history of previous neurological diagnosis was an exclusion criterion for enrollment into the study, although none of the patients that agreed to participate had a prior history of any secondary care neurological consultation or diagnosis.

Neurological history and clinical examination

All patients were clinically assessed by Consultant Neurologists, including detailed neurological history and examination. The Neurologists were blinded to the neuro-radiological findings and to the serological results for TG6 autoantibodies (these were performed after the initial clinical assessment). As part of their neurological history patients were specifically asked if they had experienced any balance problems (gait instability, tendency to fall, clumsiness), persisting sensory symptoms (tingling, numbness, peripheral pain in feet and hands) or frequent (weekly) headaches. If there was any clinical evidence of a peripheral neuropathy on clinical examination (distal sensory disturbance and/or areflexia) patients underwent detailed neurophysiological assessments done by 2 of the authors, PZ and PGS, Consultant Neurophysiologists, to verify the presence or not of any neuropathy. The clinical neurological examination included detailed assessment of gait, including ability to tandem walk and stand on each leg in turn.

Brain imaging

Patients underwent MR imaging of the brain, including volumetric T1 weighted and volumetric FLAIR structural imaging, and MR spectroscopy of the

cerebellum (vermis and hemisphere). The methodology of MR imaging, MR spectroscopy and the cut-offs for abnormal spectroscopic measurements of N-Acetyl Aspartate to Creatine ratio (NAA/Cr) have been described previously.¹⁰ The white matter disease on MRI was analysed by 2 of the authors, NH and DC, neuroradiologists with over 10 years' experience at specialist neuroradiology consultant level. Both neuroradiologists were blinded to the TG6 serological status of the patients at the time of reporting. Scans were graded using the Fazekas scoring system and the individual number of white matter hyperintensities recorded from the volumetric FLAIR images, with discrepancies resolved by consensus.¹¹ Imaging data from 525 healthy volunteers (collected by the neuroradiology department) was used to correct for age related changes in morphometric assessments as detailed below. The first 52 patients recruited underwent repeat scanning using the same protocol at 1 year after the initial diagnosis and the introduction of a gluten-free diet.

Volumetry of key grey matter (GM) brain regions was based on processing of T1 images to generate normalized brain volume (NBV; volume as a percentage of total intracranial volume) data sets. Briefly, to obtain cerebral grey matter (GM) volumes the "recon_all" pipeline from Freesurfer (<http://surfer.nmr.mgh.harvard.edu/>) was used.¹² Cerebellar GM volumes were derived using the cerebellum-dedicated "SUIT" pipeline (<http://www.diedrichsenlab.org/imaging/suit.htm>).¹³ All volume measures were converted to NBV using the eTIV variable from Freesurfer output. Significant findings were further interrogated by age-controlled volumetry of sub-regions, and "vertex" shape analysis via "FIRST" (a part of FSL) where appropriate.

Detailed methodology for image processing used is provided in the supplementary material section.

Serology

Serological testing for transglutaminase 2-specific IgA, antigliadin IgG and IgA (Aesku) and endomysium antibodies as well as HLA typing was undertaken in all patients prior to the biopsy at the regional immunology laboratory. None of the CD patients had IgA deficiency. All sera collected at baseline were tested for circulating anti-TG6 antibodies as part of the study using previously described methodology.^{8,9}

Gluten-free diet follow-up

The first 52 patients were re-assessed after 1 year on GFD, including repeat brain imaging, clinical assessment via a telephone interview and serological status (to confirm adherence to diet). Due to limited funding it was not possible to re-assess the entire cohort at 1 year.

Statistical analysis

A database was developed using the Statistical Package for Social Science (version 23.0 for Mac; SPSS). Analyses sought to firstly characterize the significance of different measures at the point of presentation of these newly-diagnosed CD patients, to secondly investigate differences in key MR variables relative to TG6 status, and to finally examine the progression in relation to MR variables in the 1 year follow-up group. Frequencies and descriptive statistics were examined for each variable. Comparisons between

groups were made by using the Student's t-test for the normally distributed continuous variables and by using the Mann-Whitney's U test for the non-normally distributed continuous variables. Categorical variables were compared using the chi square test. Level of significance was set at the 95% confidence level. Statistical models employed to test significance of observed changes on imaging data are given in the Supplemental Materials section.

Results

A total of 100 consecutive newly diagnosed CD patients (60F and 40M) were recruited over an 18 months period. Reasons for referral included: one or more CD related gastrointestinal symptoms (abdominal bloating, abdominal pain, weight loss, diarrhea, pale stools) in 54% of patients, anaemia in 16%, family screening in 14%, persistent fatigue in 6%, irritable bowel syndrome diagnosed in primary care in 5%, osteoporosis in 4%, presence of other autoimmune diseases in 4% and abnormal liver function tests in 3%. The mean age at the time of diagnosis of CD was 43 ± 15 years (range 19 to 77). In line with a CD diagnosis, 97% of patients had circulating IgA TG2 autoantibodies, 90% had endomysium antibodies and 82% had circulating antibodies to gliadins (88% IgG, 75% IgA and 63% both). All patients carried a CD susceptibility class II MHC, either HLA DQ2 (96%) or HLA DQ8 (4%).

Clinical evaluation

Detailed neurological history revealed complaints of gait instability in 24% of patients, persisting sensory symptoms in 12%, and 42% with frequent (weekly) headaches, whereby 21% had more than one of these 3 neurological

symptoms. On clinical examination, gait instability was found in 29% of patients. Sustained gaze-evoked nystagmus on lateral gaze was observed in 11% (all apart from 1 of these 11 patients also had gait instability), and distal sensory loss and/or areflexia suggestive of peripheral neuropathy in 10%. A neurophysiological assessment of all 10 patients with clinically suspected peripheral neuropathy indicated that one had evidence of large fiber neuropathy and another had a small fiber neuropathy. In total 67/100 (67%) patients had symptoms and/or signs of neurological dysfunction (Table 1). Excluding headache, which as a sole neurological symptom was present in 17% of patients, 50% of patients had symptoms and/or signs (balance problems, gait instability, sensory symptoms and sensory loss) of neurological dysfunction. We did not identify any other contributory factors that could potentially explain the above findings other than the presence of CD.

Brain imaging

MRI and MR spectroscopy was performed in 96 patients. Four patients did not have imaging, 2 due to claustrophobia, 1 was pregnant and one had a recent coronary stent insertion. In one patient the spectroscopy was unsuccessful for technical reasons. MR spectroscopy of the cerebellum was abnormal in 45/95 (47%) patients, in 36 the abnormality was in the vermis (NAA/Cr ratio ≤ 0.95), in 25 in the hemisphere (NAA/Cr ratio ≤ 0.99) and in 16 in both. The prevalence of abnormal MR spectroscopy was not significantly different in patients with clinically overt balance problems and those without (53.1% vs 42.2%; $p=0.311$). The number of patients with white matter lesions over and above what is expected from age was 24/96 (25%). This compared to 18/525

(3%) in healthy volunteers ($p < 0.001$). There was no difference in the vascular risk factors or age between the group of patients with white matter changes and those without.

Stratification for TG6 autoantibodies

Serological testing for circulating TG6 antibodies was done in 98 patients and antibodies were present in 39 (40%) patients (TG6 IgA : 28, TG6 IgG: 22, and both:11), which is in line with previous cross-sectional cohort data from the UK.⁹ This compares to 4% in the healthy population.⁹

Combined MR imaging and TG6 serology was available in 95 participants of which 37 (40%) had circulating autoantibodies to TG6. Patients with TG6 antibodies (TG6+) were significantly older than those without (TG6-): 46.7 ± 14.8 vs 40.3 ± 14.8 (t -test, $p = 0.043$). Abnormal imaging alone was not significantly linked to the presence of TG6 antibodies (26/38 [68.4%] in TG6+ vs 29/57 [50.9%] in TG6-, $p = 0.09$). However, 28/38 (73.7%) of TG6+ patients had abnormal MRS of the cerebellum and/or balance problems compared to 26/57 (45.6%) of TG6- patients (chi square, $p = 0.007$). Table 2 summarizes these findings.

To investigate in detail more specific imaging changes between the 2 groups we carried out a normalized brain volume (NBV) analysis for key regions. This revealed TG6+ patients to have significantly reduced cerebellar gray matter (GM) ($NBV_{TG6+} / NBV_{TG6-} = 7.554 \pm 0.808 / 7.869 \pm 0.718$; independent t -test $p = 0.050$), and subcortical GM ($NBV_{TG6+} / NBV_{TG6-} = 3.403 \pm 0.193 / 3.503 \pm 0.192$; $p = 0.016$), but not cortical GM ($NBV_{TG6+} / NBV_{TG6-} = 27.286 \pm 1.823 / 27.793 \pm 1.632$; $p = 0.168$) (Fig. 1). Given these findings, further

analysis that controlled for age and included sub-regions was undertaken. This revealed that, for the TG6+ group, NBV remained significantly reduced in the primary subcortical GM region, and was also significantly reduced in the thalamus, but not in any other comparison (Table 3). However, there was also a trend for abnormal atrophy in the TG6+ group in three further cerebellar regions of interest (VIIb, VIIIa and Crus II, $p < 0.07$).

FIRST “vertex” analysis was used to further investigate the significant finding in the thalamus. Models that did not control for age were first used to visualise the overall spatial pattern of atrophy between the two groups (Fig. 2a), showing a broad pattern of GM loss, with relative sparing of the anterior and pulvinar nuclei. With age correction applied (Fig. 2b), a significant locus of atrophy around the lateral / ventral posterior nuclei became evident.

Follow-up after 1 year of GFD

At one year, during telephone consultation with the first 52 patients recruited 20/24 (83.3%) indicated that their headaches had significantly improved (in 15) or completely resolved (in 5) following the introduction of GFD.

All 52 patients underwent repeat brain imaging at one year (11.6 ± 1 month following baseline scan). Of the 23/52 patients who had abnormal NAA/Cr baseline vermian spectroscopy values, 12 (52.2%) improved to within the normal range after adoption of GFD. In 15 patients (29%) there was an increase in the number of white matter lesions on the second scan. All apart from one of these patients already had white matter abnormalities at baseline. It should be noted that at the time of their second scan, 20 (47%) out of 43 patients that had repeat serological testing still had positive serology (all had

reduced levels compared to baseline but still positive for one or more of antigliadin, endomysium and TG2 antibodies; anti-TG6 antibody analysis was not performed at one year), suggesting inadequate compliance with GFD. We found no correlation between increased white matter lesions or change in MR spectroscopy and serological status at one year. The numbers however were very small.

Discussion

To our knowledge this is the largest prospective study to perform detailed neurological evaluation in patients with newly diagnosed CD presenting to gastroenterologists, using both clinical assessments and brain imaging including MR spectroscopy. The study suggests that a large proportion of patients with CD already have neurological symptoms and/or signs of neurological dysfunction at the time of diagnosis of CD: gait instability in 24% of patients, persisting sensory symptoms in 12%, and 42% with frequent headaches. Particularly notable was the presence of gait ataxia in 29% of CD patients on clinical examination.

In addition 46% of patients had abnormal MR spectroscopy of the cerebellum and 25% had abnormal white matter lesions over and above what is expected from age (3% in healthy population). Such neurological involvement often fails to be identified as it is unreported by patients and not questioned by gastroenterologists. As all of these patients were from the local catchment area and referred by their local General Practitioners we believe that these

findings are representative for adult patients with CD presenting to gastroenterologists.

TG6 autoantibodies have been proposed as an early marker for neurological involvement in gluten-related diseases, particularly ataxia.⁹ In addition to TG6 autoimmunity, mutations of the TGM6 gene have also been linked to ataxia.^{14,15,16} Our data provide further support for the utility of this marker in newly-diagnosed CD patients as a surrogate for brain involvement, as TG6 antibody positive patients displayed significant atrophy of subcortical brain regions, particularly the thalamus. TG6 is expressed in a subset of neurons in the cerebellar cortex (Purkinje cells) and cerebellar nuclei but also in the thalamus amongst other subcortical locations.^{16, 17} The thalamus is involved in motor control in terms of acting as a relay centre between the cerebellum and the motor cortex.¹⁸ The observed significant thalamic atrophy and tendency towards cerebellar atrophy are therefore in line with loss or impairment of TG6+ neurons, potentially affecting GABA-ergic inhibitory pathways. This is in keeping with recent publications demonstrating brain hyper-excitability in patients with CD.^{19, 20}

We have previously demonstrated that the prevalence of circulating TG6 antibodies in CD patients presenting with ataxia is much higher than in those presenting to gastroenterologists (73% vs 40%), whereas the prevalence of TG6 antibodies in paediatric CD patients presenting to gastroenterologists was found to be 25%.²¹ The TG6 antibody prevalence in these 3 groups is analogous to what is observed in patients with DH where circulating TG3 antibodies (antibodies against DH-specific epidermal autoantigen) are found in up to 71% of patients with DH but in only 50% and 11% of adult and

pediatric CD patients, respectively.²² It is noteworthy that in patients with DH, not all patients have circulating TG3 antibodies, yet 100% have IgA-TG3 deposits in the papillary dermis, the site of the primary manifestation.²³ Therefore, while the presence of these antibodies (TG2, TG3 and TG6) in the serum is diagnostically helpful, their absence in the serum does not preclude a localized response at the level of the target tissue (gut, skin and brain). This observation may explain why some of the patients from this study who had neurological symptoms and signs and/or abnormal imaging were negative for TG6 antibodies as measured in the serum. Such patients may still be positive for TG6-specific plasma cells and have deposition of TG6 antibodies locally in the brain tissue which can only be assessed retrospectively, post-mortem. Indeed, the presence of such TG6 antibody deposits was demonstrated in the brain of gluten ataxia patients.²⁴ Data on the serological prevalence of TG6 in different gluten sensitivity-related populations are sparse and have been collected by mainly using customized in-house TG6 antibody assays. One such study found the prevalence to be just 10% amongst a cohort of a mixture of neurology patients with CD or with just AGA positivity without enteropathy.²⁵ Until such time as the widespread availability of a reliable and standardized commercial TG6 assay in everyday clinical practice becomes a reality, it is difficult to draw any major conclusions on the differences in prevalence between published studies.

The prevalence of peripheral neuropathy in the current cohort was low at 2%. A Finnish study demonstrated evidence of peripheral neuropathy, using neurophysiology, in 23% of patients with established CD.²⁶ A population

based epidemiological study from Sweden on 28,232 patients with CD showed a 2.5-fold increased risk for peripheral neuropathy.²⁷ The low prevalence of peripheral neuropathy in our cohort suggests that gluten neuropathy may be a late manifestation of CD (the mean age at diagnosis of neuropathy in the Finish cohort was 51 compared to 43.8 in the cohort studied here). This is consistent with our observation that for patients with CD presenting with neuropathy the average age at diagnosis of CD was 67.

Twenty five percent of patients had significantly increased number of white matter abnormalities on MR imaging corrected for age, when compared to healthy controls. Headaches, which subside with adherence to a GFD, and white matter abnormalities, which do not resolve, in CD have been previously reported and the term gluten encephalopathy has been used to describe such cases.²⁸ The largest population study on CD and headache has shown a significantly increased risk of headache-related visits in patients with CD.²⁹ The majority of patients with CD and headache studied here indicated that their headache had improved or disappeared (80%) after a year on a strict gluten free diet. Similar percentage improvement (75%) has been reported in a recent systematic review of headache in the context of CD.³⁰ This is consistent with an aetiological link between headache and CD. The observation of high prevalence of white matter abnormalities in patients with CD has also been reported in a smaller study of 17 patients who were on GFD.³¹ The concern over the white matter abnormalities on MR imaging is their potential contribution to cognitive decline. A large population study from Sweden has suggested that there is an increased risk of vascular dementia in

patients with CD.³² The aetiology of the headache in CD patients remains unclear but an interesting study demonstrated regional cerebral blood flow alteration (hypoperfusion) in patients with CD not on GFD when compared to healthy controls and patients with CD on GFD.³³

There are also some limitations as to what can be extrapolated from this study. We did not include a healthy control population to study alongside the CD group as the primary aim was to investigate differences between CD patients positive or negative for TG6 antibodies. It is therefore difficult to know how the prevalence of the clinical findings would compare to a healthy population examined in the same setting. However, the literature provides some guidance in this regard. A previous smaller cross-sectional study in patients with established CD (mean age 51 years), demonstrated clinical evidence of stance and gait instability in 33% of the patients, a figure similar to what we found.³⁴ A study assessing the prevalence of gait instability in 115 healthy volunteers with the same mean age as our group found that none of them had any evidence of gait instability.³⁵ Another study in untreated patients with CD showed the presence of neurological symptoms to be 15% compared to 0% in the control group.³⁶

Only half of the cohort of patients neurologically assessed at baseline underwent repeat imaging at 1 year. This was due to limited funding. However the beneficial effect of GFD in patients with GA, using MR spectroscopy as the outcome measure has already been reported in a much larger cohort of 117 patients.¹⁰ All aspects of the primary aim of this study encompassed relevant controls including TG6 serology and brain imaging, where data was

available from healthy controls both in terms of MR spectroscopy and white matter abnormalities and therefore no such limitations apply.

In conclusion neurological dysfunction in patients with newly diagnosed CD presenting to the gastroenterologist is common but overlooked. TG6 antibodies are prevalent amongst patients with newly diagnosed CD and are associated with regional brain atrophy. Given the early presence of neurological dysfunction including brain atrophy there is a need for increased awareness of the neurological manifestations amongst clinicians and reinforcement of adherence to a strict GFD by patients in order to avoid the potential of permanent neurological disability.

Figure legends

Fig. 1 Brain atrophy in patients with TG6 autoantibodies.

Box plots visualising normalized brain volumes (NBVs) for cerebral cortical (top left), subcortical (top right), and cerebellar cortical (bottom) GM for TG6 antibody positive or negative CD patients (asterisk: $p < 0.05$, independent t -test).

Fig. 2 Visualisation of TG6 antibody-related atrophy in the thalamus.

TFCE-corrected output from FIRST “vertex” analysis of the thalamus before (A) and after (B) correction for age-related changes. *A.* Red locations highlight areas which have significantly ($p \leq 0.05$) atrophied in the TG6+ group compared to the TG6- group. *B.* Red areas as above while blue areas identify locations where ($p \leq 0.1$) for reference (top & middle); differences only reached significance in the left thalamus (middle). However, when reducing the threshold for red areas to $p \leq 0.06$ in the right thalamus, a very similar pattern to the left is revealed (bottom).

References

- 1 Sanders DS, Patel D, Stephenson TJ, et al. A primary care cross-sectional study of undiagnosed adult coeliac disease. *European J Gastro Hepat* 2003;15:407-413.
- 2 Sapone A, Bai JC, Ciacci C, et al. Spectrum of Gluten-Related Disorders: Consensus on Nomenclature and Classification. *BMC Medicine* 10 (1):13 Feb 2012.
- 3 Ludvigsson JF, Leffler DA, Bai J, et al. The Oslo definitions of coeliac disease and related terms. *Gut*, February 16, 2012 10.1136/gutjnl-2011-301346.
- 4 Reunala T, Salmi TT, Hervonen K. Dermatitis herpetiformis: Pathognomonic transglutaminase IgA Deposits in the skin and excellent prognosis on a Gluten-free Diet. *Acta Derm Venereal* 2015;95:917-922.
- 5 Hadjivassiliou M, Grünewald RA, Chattopadhyay AK, et al. Clinical, radiological, neurophysiological and neuropathological characteristics of gluten ataxia. *Lancet* 1998;352:1582-1585.
- 6 Dieterich W, Ehnis T, Bauer M, et al. Identification of tissue transglutaminase as the autoantigen of celiac disease. *Nat Med* 1997;3:797-801.
- 7 Sardy M, Karpati S, Merkl B, et al. Epidermal transglutaminase (TGase 3) is the autoantigen of dermatitis herpetiformis. *J Exp Med* 2002;195:747-757.

- 8 Hadjivassiliou M, Aeschlimann P, Strigun A, et al. Autoantibodies in gluten ataxia recognise a novel neuronal transglutaminase. *Ann Neurol* 2008;64:332-343.
- 9 Hadjivassiliou M, Aeschlimann P, Sanders DS, et al. Transglutaminase 6 antibodies in the diagnosis of gluten ataxia. *Neurology* 2013;80:1-6.
- 10 Hadjivassiliou M, Grunewald RA, Sanders DS, et al. Effect of gluten free diet on cerebellar MR spectroscopy in gluten ataxia. *Neurology* 2017;89:1-5.
- 11 Fazekas F, Chawluk JB, Alavi A, et al. MRI signal abnormalities at 1.5 T in Alzheimer's dementia and normal aging. *American Journal of Roentgenology* 1987;149:351-356.
- 12 Fischl B, Salat DH, Busa E, et al. Whole brain segmentation: Automated labeling of neuroanatomical structures in the human brain. *Neuron*. 2002;33(3):341-355. doi:10.1016/S08966273(02)00569-X.
- 13 Diedrichsen J. A spatially unbiased atlas template of the human cerebellum. *Neuroimage* 2006;33(1):127-138. doi:10.1016/j.neuroimage.2006.05.056.
- 14 Wang JL, Yang X, Xia K, et al. TGM6 identified as a novel causative gene of spinocerebellar ataxias using exome sequencing. *Brain*. 2010 Dec;133(Pt 12):3510-8.
- 15 Tripathy D, Vignoli B, Ramesh N, et al. Mutations in TGM6 induce the unfolded protein response in SCA35. *Hum Mol Genet* 2017;26(19):3749-3762.

- 16 Thomas H, Beck K, Adamczyk M, et al. Transglutaminase 6: A protein associated with central nervous system development and motor function. *Amino Acids*. 2013;44(1):161-177. doi:10.1007/s00726-011-1091-z.
- 17 Liu YT, Tang BS, Lan W, et al. Distribution of transglutaminase 6 in the central nervous system of adult mice. *Anat Rec*. 2013;296(10):1576-1587. doi:10.1002/ar.22741.
- 18 Sommer MA. The role of the thalamus in motor control. *Curr Opin Neurobiol* 2003;13(6):663-670. doi:10.1016/j.conb.2003.10.014.
- 19 Sarrigiannis PG, Hoggard N, Aeschlimann D, et al. Myoclonus ataxia and refractory coeliac disease. *Cerebellum & Ataxias* 2014
<https://doi.org/10.1186/2053-8871-1-11>
- 20 Pennisi M, Lanza G, Cantone M, et al. Cortical involvement in celiac disease before and after long-term gluten-free diet: A Transcranial Magnetic Stimulation study. *PLoS ONE* 2017;12(5):e0177560.
- 21 De Leo L, Aeschlimann D, Hadjivassiliou M, et al. Anti Transglutaminase 6 antibody development in children with celiac disease correlates with duration of gluten exposure. *J Pediatric Gastroenterol Nutrition* 2017 DOI:10.1097/MPG.0000000000001642.
- 22 Jaskowski TD, Hamblin T, Wilson AR, et al. IgA anti-epidermal transglutaminase antibodies in Dermatitis Herpetiformis and pediatric Celiac Disease. *Journal of Investigative Dermatology* 2009;129:2728-2730.
- 23 Collin P, Salmi TT, Hervonen K, et al. Dermatitis Herpetiformis: a cutaneous manifestation of Coeliac Disease. *Annals of Medicine* 2017;49:23-31.
- 24 Hadjivassiliou M, Sanders DS, Grunewald RA, et al. Gluten sensitivity:

from gut to brain. *Lancet Neurol* 2010;9:318-330.

25 McKeon A, Lennon VA, Pittock SJ, et al. The neurologic significance of celiac disease biomarkers. *Neurology* 2014;83:1789-1796.

26 Luostarinen L, Hinamen SL, Luostarinen M, et al. Neuromuscular and sensory disturbances in patients with well-treated coeliac disease. *J Neurol Neurosurg Psychiatry* 2003;74:490-494.

27 Thawani SP, Brannagan TH, Lebwohl B, et al. Risk of Neuropathy Among 28,232 Patients With Biopsy-Verified Celiac Disease. *JAMA Neurol.* 2015 Jul;72(7):806-11.

28 Hadjivassiliou M, Grünewald RAG, Lawden M, et al. Headache and CNS white matter abnormalities associated with gluten sensitivity. *Neurology* 2001;56:385-388.

29 Lebwohl B, Roy A, Alaedini A, et al. Risk of Headache-Related Healthcare visits in patients with Celiac disease: A population-based observational study. *Headache* 2016;DOI:10.1111/head.12784.

30 Zis P, Thomas J, Hadjivassiliou M. Headache associated with coeliac disease: A systematic review and meta-analysis. *Nutrients* 2018;10/1445.doi:10.3390/nu10101445.

31 Bilgic B, Aygun D, Arslan AB, et al. Silent neurological involvement in biopsy-defined coeliac patients. *Neurol Sci* 2013;34:2199-2204

32 Lebwohl B, Luchsinger JA, Freedberg DE, et al. Risk of dementia in patients with celiac disease: a population-based cohort study. *J Alzheimers Dis* 2016;49:179-85.

33 Addolorato G, Di Giuda D, De Rosi G, et al. Regional cerebral hypoperfusion in patients with celiac disease. *Am J Med* 2004;116:312-

317

34 Burk K, Farecki ML, Lamprecht G, et al. Neurological symptoms in patients with biopsy proven Celiac disease. *Movement Disorders*

2009;24:2358-2362.

35 Notermans NC, Van Dijk GW, Van der Graaf Y, et al. *J Neurol*

Neurosurg Psychiatry 1994;57:22-26.

36 Lindfors K, Koskinen O, Laurila K, et al. IgA-class autoantibodies

against neuronal transglutaminase, TG6 in celiac disease: No evidence for gluten dependency.

Table 1: Neurological assessment of newly diagnosed CD patients

Number of patients with CD presenting to gastroenterologists recruited	100	
Mean age at diagnosis	43±15 years (range 19-77)	
Total number with symptoms and/or signs of neurological dysfunction	67%	
Symptoms	gait instability loss of balance	24%
	persisting sensory disturbance	12%
	frequent headaches	42%
Signs	gait ataxia	29%
	nystagmus	11%
	sensory loss and/or areflexia	10%
Excluding headache, total number with symptoms and signs of neurological dysfunction	50%	
Abnormal MR spectroscopy of the cerebellum	45/95 (47%)	
White matter abnormalities on MR brain imaging (excessive for age)	25% (3% in healthy controls)	
Number of patients undergoing MR imaging at one year	52/100	
Abnormal cerebellar spectroscopy at baseline	23/52 (44.2%)	
Normalization of MR spectroscopy at one year	12/23 (52.2%)	
Number TG6 positive CD patients	40%	

Table 2: Differences between patients with CD positive for TG6 antibodies when compared to those who were negative for TG6 antibodies.

	TG6 +ve	TG6-ve	p value
age	46.7	40.3	0.043*
abnormal imaging	68.4%	50.9%	0.09
abnormal spectroscopy of the cerebellum and gait ataxia	73.7%	45.6%	0.007*

Table 3: Volumetric (NBV) analysis of individual brain regions following stratification of CD patients for TG6 autoantibody positivity revealed significant differences in age-controlled ANOVAs.

		37 patients	58 patients		
	ROI	TG6+ Mean(SD) NBV	TG6- Mean(SD) NBV	<u>TG6</u> <u>positivity</u> <u>p value</u>	Age correct · <i>p</i> value
Freesurfer Volumes	Subcortical GM	3.403(0.193)	3.503(0.192)	.045	.050
	Thalamus	0.928(0.066)	0.973(0.085)	.035	.002
	Caudate	0.397(0.041)	0.400(0.048)	.406	.015
	Putamen	0.581(0.072)	0.604(0.054)	.221	.005
	Globus Pallidus	0.177(0.022)	0.179(0.016)	.823	.025
	Hippocampus	0.519(0.051)	0.523(0.040)	.750	.697
	Amygdala	0.175(0.022)	0.182(0.017)	.096	.752
SUIT Volumes	Cerebellum GM	7.554(0.808)	7.869(0.718)	.110	.097
	I-IV	0.449(0.053)	0.470(0.048)	.121	.027
	V	0.588(0.061)	0.608(0.054)	.154	.266
	VI	1.224(0.126)	1.266(0.114)	.163	.218
	VIIb	0.619(0.063)	0.645(0.057)	.065	.385
	VIIIa	0.589(0.061)	0.615(0.055)	.055	.407
	VIIIb	0.478(0.052)	0.497(0.045)	.118	.161
	IX	0.417(0.051)	0.432(0.043)	.327	.004
	X	0.060(0.011)	0.064(0.010)	.209	<.001
	Vermis	0.351(0.041)	0.364(0.037)	.259	.024

Crus I	1.625(0.180)	1.700(0.163)	.103	.027
Crus II	1.155(0.120)	1.207(0.110)	.064	.222

Fig. 1

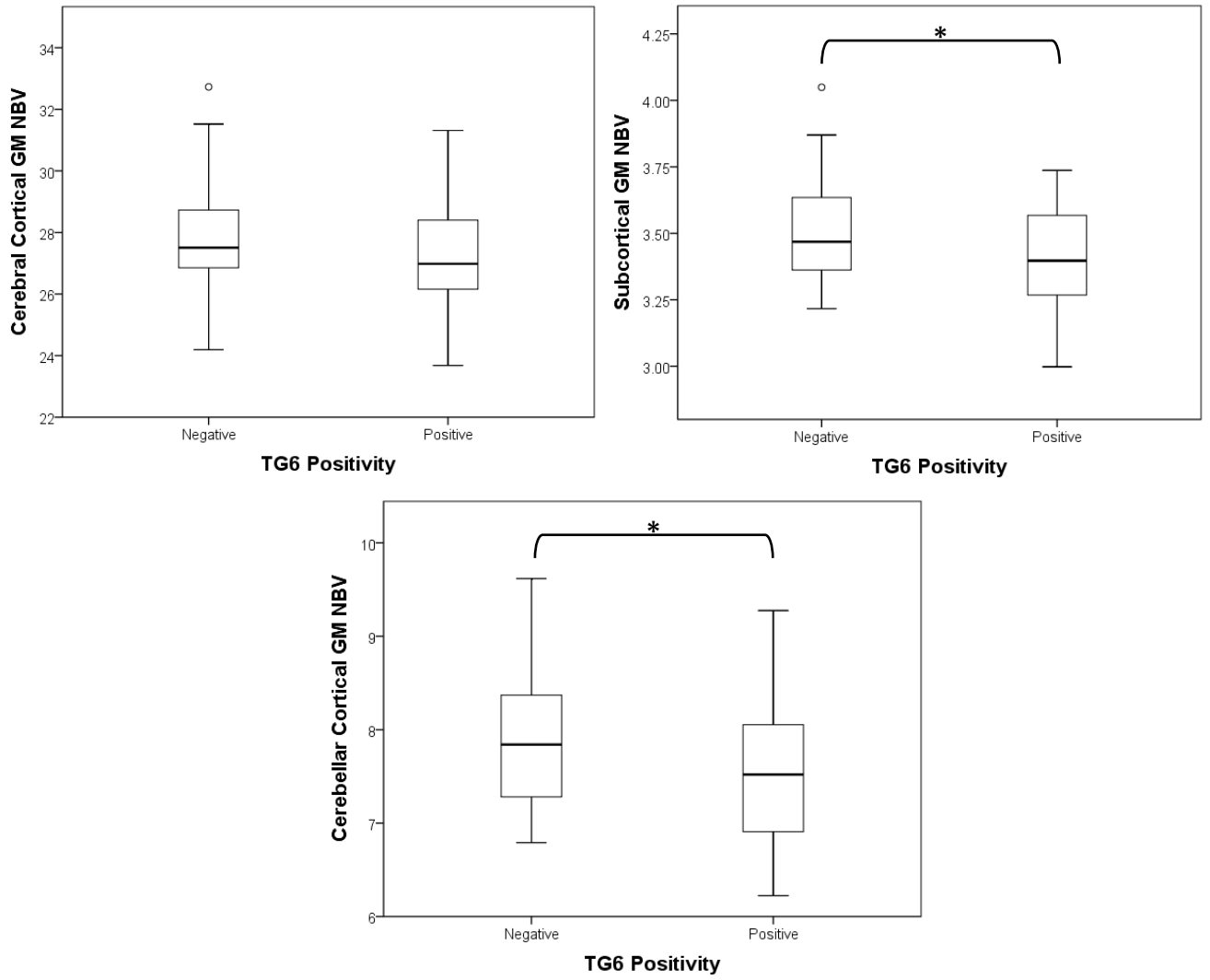


Fig 2

