

This is an Open Access document downloaded from ORCA, Cardiff University's institutional repository: <https://orca.cardiff.ac.uk/id/eprint/124822/>

This is the author's version of a work that was submitted to / accepted for publication.

Citation for final published version:

Hasan, S.B., Ali, F.M. and Ingram, J.R. 2020. Cholinergic pruritus responding to Omalizumab. *Clinical and Experimental Dermatology* 45 (2), pp. 264-266. 10.1111/ced.14052

Publishers page: <http://dx.doi.org/10.1111/ced.14052>

Please note:

Changes made as a result of publishing processes such as copy-editing, formatting and page numbers may not be reflected in this version. For the definitive version of this publication, please refer to the published source. You are advised to consult the publisher's version if you wish to cite this paper.

This version is being made available in accordance with publisher policies. See <http://orca.cf.ac.uk/policies.html> for usage policies. Copyright and moral rights for publications made available in ORCA are retained by the copyright holders.



Cholinergic Pruritus responding to Omalizumab: a case report

Authors: S.B. Hasan ¹, F.M. Ali ¹, J.R. Ingram ¹

1. Department of Dermatology & Wound Healing, Division of Infection and Immunity, Cardiff University, University Hospital of Wales, 3 rd Floor Glamorgan House, Heath Park, Cardiff CF14 4XN, U.K.

-<https://orcid.org/0000-0002-3265-4530> (S.B. Hasan)

-<http://orcid.org/0000-0002-4184-2023> (F.M. Ali)

-<http://orcid.org/0000-0002-5257-1142> (J.R. Ingram)

Corresponding author: J.R. Ingram

Email: ingramjr@cardiff.ac.uk

Telephone: +44 (0)742190

Fax: +44 (0)2920745161

Address: 3rd Floor Glamorgan House, University Hospital of Wales, Heath Park, Cardiff CF14 4XN

Keywords: cholinergic pruritus, cholinergic urticaria, omalizumab

Word count: 580

Figure count: 1

Table count: 0

Conflicts of interest: None

Funding: None

Cholinergic Pruritus responding to Omalizumab: a case report

Cholinergic pruritus is a rare condition characterised by generalised itch provoked by sweating without an associated rash. It is exacerbated by heat, exercise, emotion or activities of daily living.(1) The pruritus can be severe and have a considerable impact on the patient's life.

A 60 year old gentleman presented to our clinic in 2012 with a 9-month history of severe pruritus and a burning sensation that was induced by exercise and heat and relieved by cooling. The symptoms were not associated with a skin rash. His Dermatology Life Quality Index (DLQI) score of 23/30 indicated an extremely large effect on his quality of life. The pruritus impacted many of his regular daily activities like housework and shopping, including sexual activity. The patient had a history of asthma and depression for which he was taking fluticasone salmeterol and sertraline. On examination, there were a few patches of vitiligo covering around 2% of his BSA but no other skin lesions and no dermatographism. A blood test screen (complete blood count, lactate dehydrogenase, liver, renal and thyroid function test, HbA1c, IgA anti-tissue transglutaminase antibody and pemphigoid antibody) for systemic causes of pruritus without rash yielded negative results.

Initial treatment for the cholinergic pruritus included a trial of several antihistamines including fexofenadine 180 mg BD, in addition to ranitidine 150 mg BD and montelukast 10 mg OD. Increasing the doses of antihistamine was not possible due to sedation on higher doses. Danazol 200 mg TDS, subsequently tapered down to 100 mg OD, was added to his treatment regimen based on case report evidence in cholinergic pruritus.(2) His symptoms improved but after 2 years of therapy the patient developed tenderness in the left breast and mild gynaecomastia and danazol was discontinued. As a result, a trial of monthly subcutaneous injections of omalizumab 300 mg was initiated.

Prior to initiating omalizumab, the patient reported a DLQI score of 19/30 and Itch numeric rating scale (NRS) score of 8/10. Three months after starting omalizumab the patient experienced a dramatic improvement in his symptoms with a DLQI score of 3/30 and Itch NRS score of 0-1/10 (Figure.1). His scores in regards to itching, interference with regular chores, choice of clothes, sports and work were reduced with the disease having very little or no impact at all on these areas. The patient initially reported that there was complete resolution of his symptoms in the 2 weeks after receiving the omalizumab injection, and mild pruritus in the following 2 weeks. This has gradually improved and the patient reports that he no longer has any symptoms in between the injections. The slight increase in the patient's DLQI score in April 2019 to 8/30 was probably due to incorrect administration of omalizumab injection intramuscularly that month because the patient reported the injection was more painful than usual.

Cholinergic pruritus is a rare disease that may go undiagnosed due to the lack of physical signs or misdiagnosed as cholinergic pruritus.(3) In our patient danazol somewhat alleviated his pruritus but led to the development of breast tenderness and gynecomastia. The patient was started on omalizumab based on reports of its benefit in treating cholinergic urticaria.(4, 5) Omalizumab was effective in controlling the patient’s symptoms and he was able to resume his regular physical activities including physiotherapy sessions for a shoulder injury. To our knowledge, this is the first report of cholinergic pruritus being treated with omalizumab, which is a treatment option worth considering for severe refractory cholinergic pruritus.

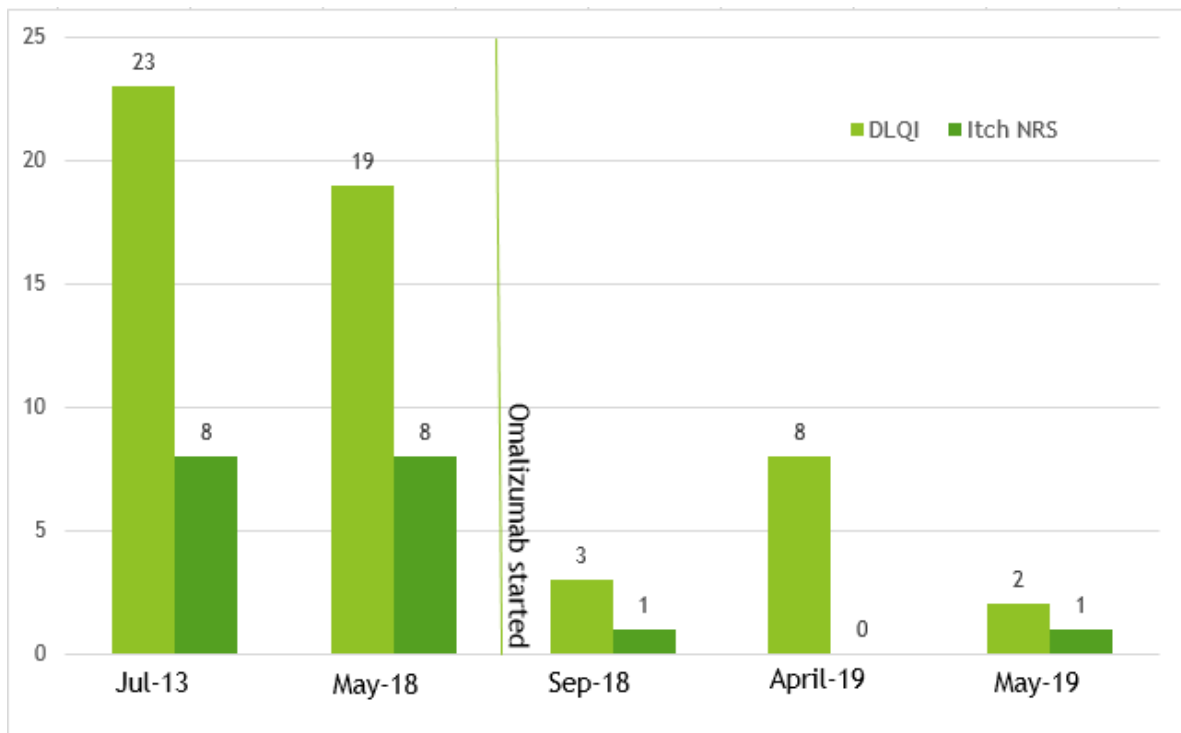


Figure1. Figure outlining DLQI* and Itch NRS** scores over time. Omalizumab was commenced in June 2018.

***DLQI** Dermatology Life Quality Index

****Itch NRS** Itch Numerical Rating Scale

References

1. Grattan CEH, Lawlor F. Physical urticarias, aquagenic pruritus, and cholinergic pruritus. In: Lebowitz M, Heymann WR, Berth-Jones J, Coulson I (eds). *Treatment of skin disease: comprehensive therapeutic strategies*. 4th edition. Oxford: Elsevier Saunders. 2014; p 570.
2. Berth-Jones J, Graham-Brown RAC. Cholinergic pruritus, erythema and urticaria: a disease spectrum responding to danazol. *Br J Dermatol*. 1989; 121: 235-7.
3. Kim HJ, Lee MG. Cholinergic urticaria: More than a simple inducible urticaria. *Australasian Journal of Dermatology* 2017; 58: e193-e8.
4. Altrichter S, Chuamanochan M, Knoth H, Asady A, Ohanyan T, Metz M, et al. Real-life treatment of cholinergic urticaria with omalizumab. *The Journal of Allergy and Clinical Immunology* 2019; 143: 788-91.
5. Koumaki D, Seaton ED. Successful treatment of refractory cholinergic urticaria with omalizumab. *International Journal of Dermatology*. 2018; 57: 114.