

This is an Open Access document downloaded from ORCA, Cardiff University's institutional repository: <https://orca.cardiff.ac.uk/id/eprint/127594/>

This is the author's version of a work that was submitted to / accepted for publication.

Citation for final published version:

Richmond, Stephen , Zhurov, Alexei , Bin Mohd Ali, Azrul, Pirttiniemi, Pertti, Heikkinen, Tuomo, Harila, Virpi, Silinevica, Signe, Jakobsone, Gundega and Urtane, Ilga 2020. Exploring the midline soft tissue surface changes from 12 to 15 years of age in three distinct country population cohorts. *European Journal of Orthodontics* 42 (5) , pp. 517-524. 10.1093/ejo/cjz080

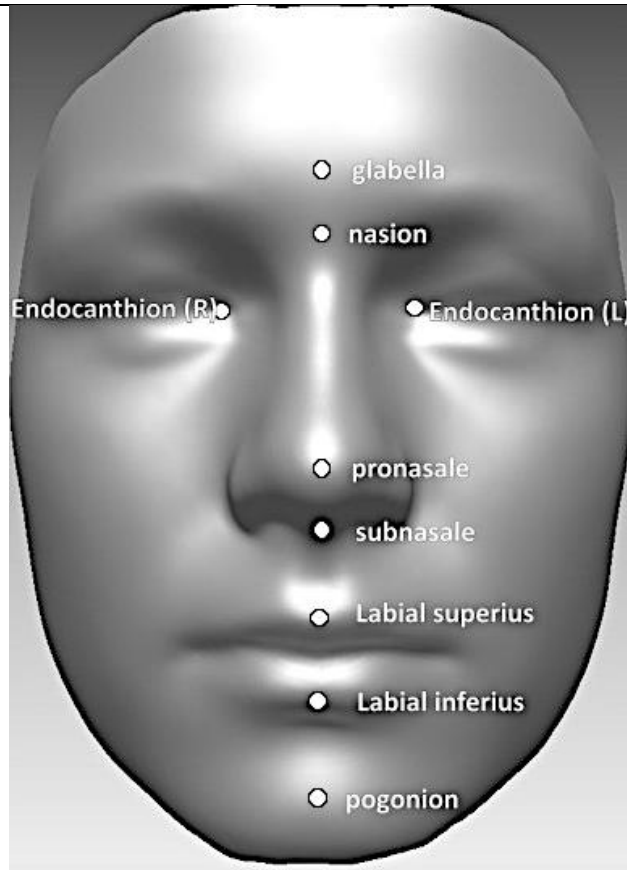
Publishers page: <http://dx.doi.org/10.1093/ejo/cjz080>

Please note:

Changes made as a result of publishing processes such as copy-editing, formatting and page numbers may not be reflected in this version. For the definitive version of this publication, please refer to the published source. You are advised to consult the publisher's version if you wish to cite this paper.

This version is being made available in accordance with publisher policies. See <http://orca.cf.ac.uk/policies.html> for usage policies. Copyright and moral rights for publications made available in ORCA are retained by the copyright holders.





Landmark and abbreviation ()	Definition
glabella (g)	The most prominent midline point between the eyebrows, identical to bony glabella on the frontal bone.
nasion (n)	The point in the midline of both nasal root and fronto-nasal suture, always above the line that connects the two inner canthi, identical to bony nasion.
endocanthion (left and right) (en)	Left and right inner eye commissures. The mid-endocanthion point was constructed (men).
pronasale (prn)	The most protruded point of the apex nasi, identified in lateral view of the rest position of the head.
subnasale (sn)	The midpoint of the angle at the columella base where the lower border of the nasal septum and the surface of the upper lip meet, not identical to bony nasospinale or anterior nasal spine. Identified in the base view of the nose, or from lateral view of the rest position of the head.
labiale superius (ls)	The midpoint of the upper vermilion line.
labiale inferius (li)	The midpoint of the lower vermilion line.
pogonion (pg)	The most anterior midpoint of the chin, identical bony pogonion of the mandible.