

This is an Open Access document downloaded from ORCA, Cardiff University's institutional repository: <https://orca.cardiff.ac.uk/id/eprint/143969/>

This is the author's version of a work that was submitted to / accepted for publication.

Citation for final published version:

Satish, P., Freeman, A., Kelly, D. , Kirkham, A., Orczyk, C., Simpson, B., Giganti, F., Whitaker, H.C., Emberton, M. and Norris, J.M. 2021. Prostate cancer topography and tumour conspicuity on multiparametric magnetic resonance imaging: A systematic review and meta-analysis. *European Urology* 79 , S1274-S1275. 10.1016/S0302-2838(21)01283-5

Publishers page: [http://dx.doi.org/10.1016/S0302-2838\(21\)01283-5](http://dx.doi.org/10.1016/S0302-2838(21)01283-5)

Please note:

Changes made as a result of publishing processes such as copy-editing, formatting and page numbers may not be reflected in this version. For the definitive version of this publication, please refer to the published source. You are advised to consult the publisher's version if you wish to cite this paper.

This version is being made available in accordance with publisher policies. See <http://orca.cf.ac.uk/policies.html> for usage policies. Copyright and moral rights for publications made available in ORCA are retained by the copyright holders.



Relationship of prostate cancer topography and tumour conspicuity on multiparametric magnetic resonance imaging: a systematic review and meta-analysis

Pranav Satish,^{1,2} Alex Freeman,³ Daniel Kelly,⁴ Alex Kirkham,⁵ Clement Orczyk,^{2,6} Benjamin S. Simpson,⁷ Francesco Giganti^{2,5}, Hayley C. Whitaker,² Mark Emberton,^{2,6*} Joseph M. Norris,^{2,6*}

¹ UCL School of Medicine, University College London, London, UK

² UCL Division of Surgery & Interventional Science, University College London, London, UK

³ Department of Pathology, University College London Hospitals NHS Foundation Trust, London, UK

⁴ School of Healthcare Sciences, Cardiff University, Wales, UK

⁵ Department of Radiology, University College London Hospitals NHS Foundation Trust, London, UK

⁶ Department of Urology, University College London Hospitals NHS Foundation Trust, London, UK

⁷ UCL Cancer Institute, University College London, London, UK

** joint-senior authors*

Introduction & Objectives

Multiparametric magnetic resonance imaging (mpMRI) has improved the triage of men with suspected prostate cancer. Multiple factors influence cancer conspicuity on mpMRI, however, the implications of tumour location are not fully understood. Identifying topographical correlates that influence mpMRI conspicuity may improve outcomes. Here, we present the first systematic review and meta-analysis describing the effect of tumour location on prostate cancer conspicuity on mpMRI.

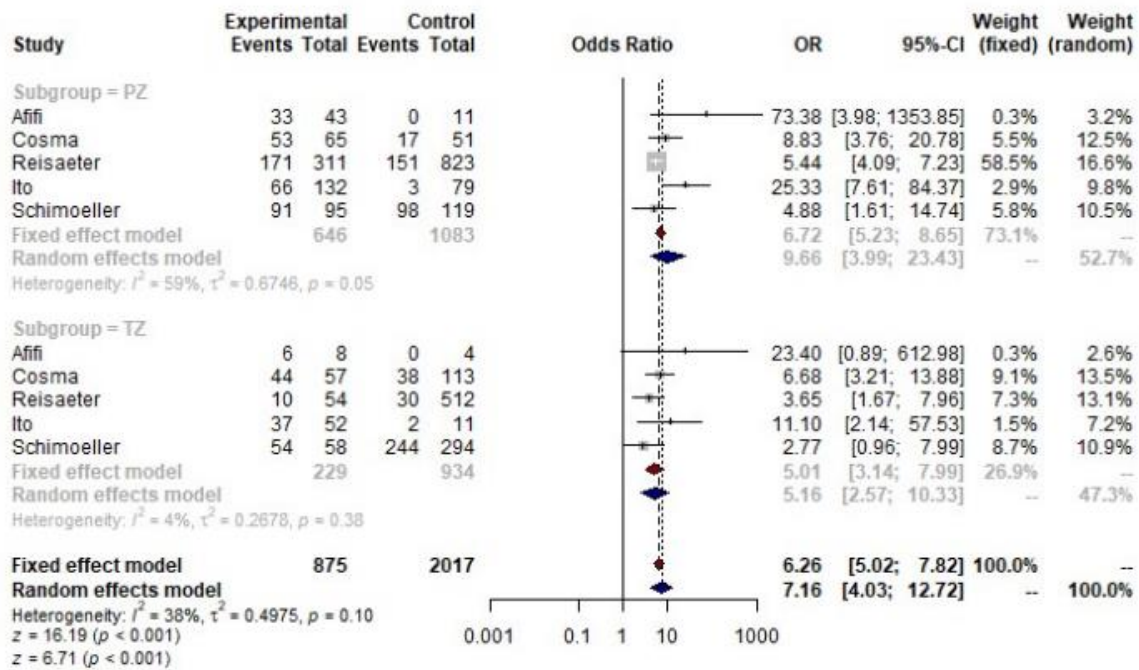
Materials & Methods

We systematically searched Medline, PubMed, Embase and Cochrane databases up to January 2021, and results were assessed as per the PRISMA statement. Tumour conspicuity on mpMRI was compared between cancers in the peripheral zone (PZ), transitional zone (TZ), base, apex, anterior and posterior. Meta-analysis was conducted to compare the diagnostic odds ratios (DOR) of detection for tumours in the PZ and TZ. Five studies had suitable data, so a random-effects model was fit and DOR compared. Risk of bias was measured via a modified Newcastle-Ottawa score (NOS). The review was prospectively registered with PROSPERO: CRD42021228087.

Results

We screened 960 articles, 17 of which fulfilled the inclusion criteria. Our NOS deemed the quality of inclusions was generally high. Thematic synthesis showed apical and basal tumours had reduced conspicuity on mpMRI, whilst mid-gland tumours had higher detection rates. TZ cancer displayed increased conspicuity on T2-weighted imaging, whilst PZ cancers were higher on diffusion-weighted imaging and dynamic contrast enhancement. With few exceptions, mpMRI had better overall diagnostic accuracy for PZ lesions, albeit higher specificity for TZ lesions. Meta-analysis showed an

increased DOR for PZ tumours on mpMRI (OR:9.7 [95% CI:4.0-23], compared to TZ (OR:5.2 [95% CI:2.6-10]). However, no significant differences between subgroups were observed ($p=0.27$). The model showed 38% heterogeneity ($I^2=38\%$, $p=0.10$).



Conclusions

Tumour location appears to influence prostate cancer conspicuity on mpMRI. Apical or basal tumours may be less conspicuous on mpMRI than mid-gland tumours. Similarly, TZ cancer appears to have reduced conspicuity compared to PZ cancer, however, meta-analysis did not show a significant difference in DOR. Future studies with robust, prospective data-sets are required to clarify the relationship between tumour position and conspicuity.