

Is postoperative high dependency care really needed for children undergoing supratentorial brain tumour surgery?

Iris-Elena Feodor, Ronak Ved, Anthony Jesurasa, Chirag Patel & Paul Leach

To cite this article: Iris-Elena Feodor, Ronak Ved, Anthony Jesurasa, Chirag Patel & Paul Leach (23 Aug 2024): Is postoperative high dependency care really needed for children undergoing supratentorial brain tumour surgery?, British Journal of Neurosurgery, DOI: [10.1080/02688697.2024.2391867](https://doi.org/10.1080/02688697.2024.2391867)

To link to this article: <https://doi.org/10.1080/02688697.2024.2391867>



© 2024 The Author(s). Published by Informa UK Limited, trading as Taylor & Francis Group.



Published online: 23 Aug 2024.



Submit your article to this journal [↗](#)



Article views: 216

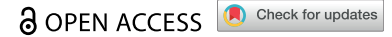


View related articles [↗](#)



View Crossmark data [↗](#)

RESEARCH ARTICLE



Is postoperative high dependency care really needed for children undergoing supratentorial brain tumour surgery?

Iris-Elena Feodor^a, Ronak Ved^{a,b}, Anthony Jesurasa^b, Chirag Patel^b and Paul Leach^b

^aCardiff University School of Medicine, Cardiff University, Cardiff, Wales; ^bDepartment of Neurosurgery, University Hospital of Wales, Cardiff, Wales

ABSTRACT

Purpose: We present our analysis of the existing Paediatric High Dependency Unit (HDU) admission policy at our institution and discuss our thoughts for its revision in the context of paediatric supratentorial tumour surgery.

Materials and methods: We screened our prospectively maintained database of all children undergoing supratentorial craniotomy for resection of paediatric brain tumours over a fifteen-year period. The post-operative course of each patient was reviewed, assessing the number of patients who had true HDU needs in the immediate post-operative period, and the relative depth of input from paediatric HDU specialists that each patient received.

Results: Forty-three patients underwent craniotomy for supratentorial tumour resections during the study period. The median age of the children was 8 years old. Forty-two patients in the study cohort did not require any HDU-level monitoring or treatment post-operatively; all these patients were able to be discharged from HDU to a standard ward bed very rapidly post-operatively. Only one patient (2%) from the study cohort had any tangible HDU needs in the acute post-operative period, comprising of invasive cardiovascular monitoring and repeated blood transfusions. This child's tumour was known to be large, highly vascular, and invasive pre-operatively.

Conclusions: We would advocate a rational and nuanced approach with regards to predicting which children are most likely need paediatric HDU care following supratentorial craniotomy for resection of a brain tumour. This rationalisation could improve resource availability and reduce financial burdens upon paediatric neurosurgical units.

ARTICLE HISTORY

Received 1 July 2024
Revised 24 July 2024
Accepted 8 August 2024

KEYWORDS

Paediatric; craniotomy; HDU; PICU; supratentorial

Introduction

Children undergoing neurosurgical procedures for brain tumours are routinely admitted to the High Dependency Unit (HDU) postoperatively at the University Hospital of Wales (UHW). This strategy of booking HDU care postoperatively is in view of the potential complications of intracranial surgery in these children, such as haemorrhage, seizure, hydrocephalus, and metabolic derangements. This practice, while aiming to ensure optimal postoperative care, imposes constraints on the availability of HDU beds for other patients and carries higher financial costs compared to cases where a standard ward bed is adequate post-operatively.¹

Our clinical observations, and reports by others have suggested variations in the postoperative care requirements among distinct tumour groups. Particularly, tumours located in the posterior fossa, pineal region, as well as intraventricular and pituitary tumours had a clear indication HDU care following surgical intervention.² Conversely, it was less evident that postoperative HDU care for supratentorial hemispheric tumours was imperative. Moreover, adult studies have shown that routine ICU admission does not affect clinical outcomes after elective craniotomies in previously healthy patients.³ We did not identify any

studies describing the benefits of HDU/ICU admission after elective paediatric craniotomies.

We therefore designed the present study to review supratentorial hemispheric tumour operations performed in the last fifteen years at a single paediatric neurosurgical unit, with a specific focus on evaluating the requirement for postoperative HDU care.

Materials and methods

We retrospectively reviewed a prospectively maintained database of all paediatric brain tumours operated on in our institution. Children who had surgery for tumours located in the posterior fossa, pineal region, sellar, and intraventricular regions were excluded. Burr hole biopsies were also excluded from the study. After interrogating the patients' medical files, we extracted demographic information such as sex, date of surgery, age at surgery, relevant medical history, anatomical site and intraoperative events. We then looked closely at their post-operative course with a view to identifying which patients clinically benefitted from being on HDU.

CONTACT Ronak Ved  vedr@cardiff.ac.uk  University Hospital of Wales, 4th Floor Academic Offices, Cardiff CF14 4XW, Wales

© 2024 The Author(s). Published by Informa UK Limited, trading as Taylor & Francis Group.
This is an Open Access article distributed under the terms of the Creative Commons Attribution-NonCommercial-NoDerivatives License (<http://creativecommons.org/licenses/by-nc-nd/4.0/>), which permits non-commercial re-use, distribution, and reproduction in any medium, provided the original work is properly cited, and is not altered, transformed, or built upon in any way. The terms on which this article has been published allow the posting of the Accepted Manuscript in a repository by the author(s) or with their consent.

Results

We identified forty-three children who underwent fifty-nine craniotomies for a supratentorial hemispheric tumour between December 2008 and November 2023. The cohort comprised of twenty-four females and nineteen males. The age of the children ranged from 6 months old to 16 years old, with a median age of 8.

Of the forty-three patients, forty-two (98%) did not have any HDU-level needs post-operatively. All of these patients were fit to step-down to a standard ward bed upon review on the morning following surgery. No further complications requiring re-admission to HDU occurred in these patients.

Only one child required HDU-specific care post-operatively. This patient was a six-month-old who had a large left sided hemispheric ependymoma. At the first operation, complete resection was not achievable due to extensive intraoperative blood loss, and the child required invasive cardiovascular monitoring and blood products on HDU post-operatively. The patient underwent a second and third operation to achieve complete resection and required ongoing invasive monitoring and HDU level care during much of the admission.

Discussion

This study identified that most children who underwent a supratentorial craniotomy for a tumour resection did not require any HDU-specific care postoperatively. Furthermore, the single child who did require post-operative HDU-specific care had numerous features pre-operatively, (young age, large tumour size, marked vascularity, brain parenchymal invasion) which highlighted the potential for this individual child to have a challenging intraoperative and postoperative course.

This observation suggests that the HDU admission criteria for paediatric patients undergoing supratentorial hemispheric operations may need to be re-evaluated and individualised, based on specific patient characteristics and intraoperative factors, rather than following a blanket policy to admit all cases to HDU post-operatively. *Badenes et al.*⁴ proposed a comprehensive evaluation protocol in adults, to aid in decision making regarding intensive care admission post-neurosurgery. They present rationale based on preoperative, intraoperative, and postoperative factors, which can inform the need for HDU care. These include the American Society of Anaesthesiologists (ASA) physical status, the type and location of tumour, intraoperative bleeding, seizures, and metabolic complications. In the case of the six-month-old patient discussed, this model could have been applied pre-operatively to anticipate the need for HDU admission after surgery.

We acknowledge that the present work is a relatively small single centre study, and thus that HDU admission may still be required for some supratentorial craniotomy patients, (which would also support the ongoing experience and training of HDU staff in providing care to these patients). Therefore, we suggest the implementation of a more tailored and risk dependent approach to weighing-up the need for HDU admission for children undergoing supratentorial craniotomy for resection of a brain tumour. We consider that children under one year should

routinely be admitted to HDU postoperatively, as brain tumour surgery in children this age has an increased risk of morbidity and mortality.⁵ We also suggest that the identification of highly vascular neoplasms on pre-operative imaging should be a consideration when assessing the need for post-surgery HDU admission, as they are associated with a higher risk of extensive blood loss. Other pre-operative and intraoperative complications, such as metabolic derangements, fluid balance issues, and pre-operative medical co-morbidities should also be evaluated when considering the need for HDU admission on a child-by-child basis.⁶

Select craniotomy patients, and patients undergoing other cranial surgeries such as foramen magnum decompressions and advanced CSF diversion procedures, are already cared for on the ward after surgery in our unit. The nursing staff in our department therefore support the notion that patients undergoing a supratentorial craniotomy for a tumour can be managed on the paediatric ward post-operatively. Utilising the experience of clinical nurse specialists could help support ward nursing staff who are caring for craniotomy patients.

In summary, this study proposes the need for a nuanced approach to postoperative HDU admission in the cases of supratentorial brain tumour resections in children. Factors such as patient age, co-morbidities, lesion size, tumour vascularity, and estimated time under anaesthetic should all be considered on an individual patient basis when evaluating the necessity of a post-op HDU admission. We believe that an assessment considering the individual risk profiles of patients would result in a more efficient utilisation of HDU resources, and this will ultimately improve the accessibility of HDU beds for all paediatric patients.

Acknowledgements

The authors report that there are no competing interests, nor any sources of funding, to declare. This study was performed in line with the principles stated in the Declaration of Helsinki. The study unit's local neurosciences research ethics committee and directorate have approved the service evaluation design used by this study, and all their requests regarding data collection and participant consent were adhered to.

References

1. Crispi V, Bolton W, Town R, Anderson I. Effect of neurosurgical high observation beds (HOBs) on service provision: a single-centre experience and cost analysis. *BMJ Open* 2023;13:e073461.
2. Anetsberger S, Mellal A, Garvayo M, et al. Predictive factors for the occurrence of perioperative complications in pediatric posterior fossa tumors. *World Neurosurg* 2023;172:e508–16.
3. Hanak BW, Walcott BP, Nahed BV, et al. Post-operative intensive care unit requirements following elective craniotomy. *World Neurosurg* 2014;81:165–72.
4. Badenes R, Prisco L, Maruenda A, Taccone FS. Criteria for intensive care admission and monitoring after elective craniotomy. *Curr Opin Anaesthesiol* 2017;30:540–5.
5. Lundar T, Due-Tønnessen BJ, Egge A, et al. Neurosurgical treatment of brain tumors in the first 6 months of life: long-term follow-up of a single consecutive institutional series of 30 patients. *Childs Nerv Syst* 2015;31:2283–90.
6. Goobie SM, Haas T. Bleeding management for pediatric craniotomies and craniofacial surgery. *Paediatr Anaesth* 2014;24:678–89.