



# ‘The Stegosaurus Appearance’ on ultrasound to assist in identifying the correct spinal level for primary lumbar spinal surgery

Ronak Ved<sup>1,2</sup>, Isobel Hatrick<sup>1</sup>, Kate Gregory<sup>1</sup>, Sanjeevan Yoganathan<sup>1</sup>, Ravindra Nannapaneni<sup>2</sup>

<sup>1</sup>School of Medicine, Cardiff University, Cardiff, Wales, UK; <sup>2</sup>Department of Neurosurgery, University Hospital of Wales, Cardiff, Wales, UK

*Contributions:* (I) Conception and design: R Ved, I Hatrick, K Gregory, S Yoganathan; (II) Administrative support: R Nannapaneni, K Gregory; (III) Provision of study materials or patients: R Ved, R Nannapaneni; (IV) Collection and assembly of data: I Hatrick, K Gregory, S Yoganathan, R Ved; (V) Data analysis and interpretation: I Hatrick, K Gregory, S Yoganathan, R Ved; (VI) Manuscript writing: All authors; (VII) Final approval of manuscript: All authors.

*Correspondence to:* Dr. Ronak Ved, MBBCh, BSc (Hons), MRCS(Ed), PGCert. School of Medicine, Cardiff University, Cardiff, Wales, UK; Department of Neurosurgery, University Hospital of Wales, 4<sup>th</sup> Floor Academic Offices, Cardiff CF14 4XW, Wales, UK. Email: vedr@cardiff.ac.uk.

**Abstract:** Lumbar spinal surgery relies on palpation of anatomical landmarks and X-ray imaging confirmation to identify the correct spinal level, therefore exposing patients and staff to radiation, and increasing intraoperative time and cost. Ultrasound (US) assistance is being used to visualise spinal anatomy by many specialities, such as neurology and anaesthetics, and can be used intraoperatively in selected spinal surgery cases. However, its potential use to check spinal levels prior to surgery remains understudied. This prospective, pilot study screened all patients requiring a primary elective or emergency lumbar discectomy, under the supervision of a single consultant neurosurgeon, over an 8-month period at a single neurosurgical unit. US assistance was used to identify and mark the proposed spinal level prior to skin incision. The resemblance of the parasagittal lumbar US images to the back of the dinosaur Stegosaurus aided users in identifying the relevant anatomical structures necessary to mark the desired spinal level, (e.g., lumbar laminae, intervertebral spaces, sacrum). This inspired our description of the US images of the lumbar spine as ‘The Stegosaurus Appearance’. The spinal level marked by US was then confirmed in the standard fashion using intraoperative X-ray imaging. In 100% of cases (12/12), the desired spinal level was correctly identified using US, confirmed by the subsequent intraoperative X-ray images. US assistance appears to be a safe, quick, and accurate tool for identifying the correct lumbar spinal level prior to skin incision, and could therefore represent a useful adjunct to supplement level checking in lumbar spinal surgery.

**Keywords:** Ultrasound (US); spinal; level; check; discectomy

Submitted May 15, 2024. Accepted for publication Aug 29, 2024. Published online Nov 27, 2024.

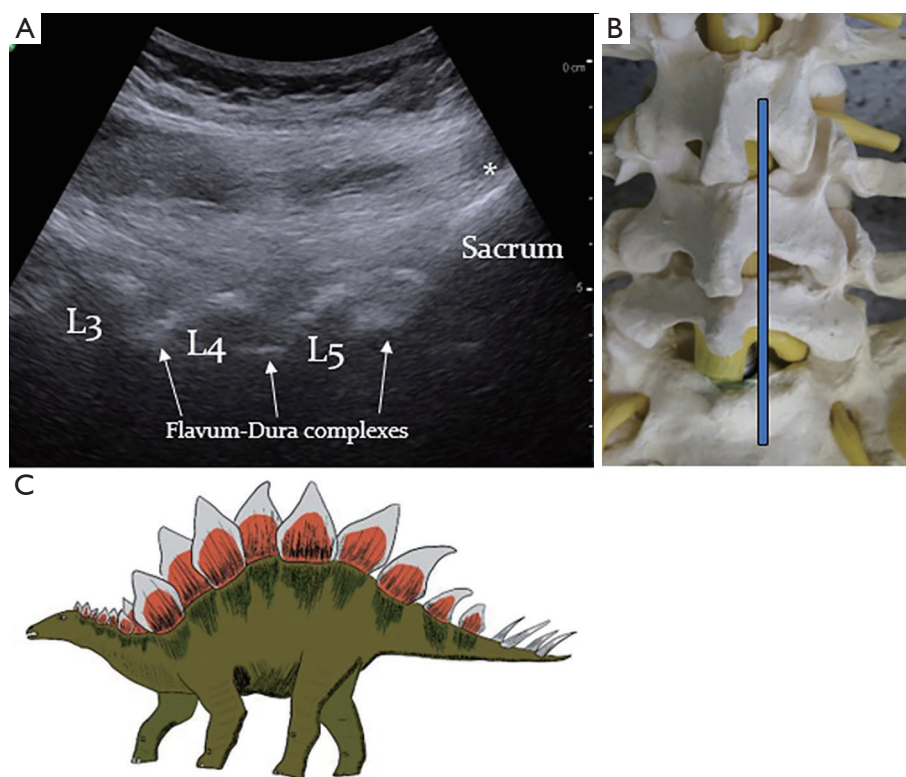
doi: 10.21037/jss-24-61

**View this article at:** <https://dx.doi.org/10.21037/jss-24-61>

A lumbar discectomy is one of the most performed spinal surgeries and is a common surgical treatment for discogenic radiculopathy causing leg pain, weakness, and cauda equina syndrome (1). Accessing the correct spinal level is a unique challenge in all spinal surgery, including lumbar operations (2). A retrospective analysis over a 6-and-half-year period found that ~0.02% cases of spinal surgery occurred at the wrong level (3); whilst the risk appears to be low, a ‘wrong level’

complication is often described as a ‘never event’, and a target of 0% should be the standard goal (2,3). Palpation of anatomical landmarks to identify the correct spinal levels alone is known to be inaccurate (4). Therefore, verification of spinal level in the form of X-ray imaging is, at present, the gold standard to confirm that the correct level is operated on (2,5).

However, intraoperative X-ray use imparts a small, yet



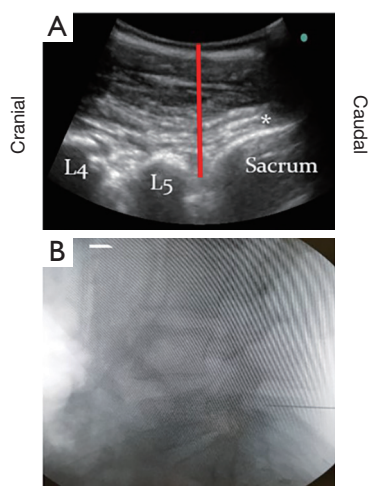
**Figure 1** ‘The Stegosaurus Appearance’ of the lumbar spine on US. (A) An US scan of the lumbar spine in the parasagittal plane. The sacrum is readily identifiable (asterisk), above which the acoustic shadows caused by the L3–L5 laminae are clearly visible. From these landmarks, the lumbar intervertebral spaces can be easily discerned and marked on the skin, and/or with insertion of a fiducial under direct US visualisation. (B) The position to place the curvilinear probe (blue line) to obtain the view in (A). (C) There is a similarity in the appearances of the lumbar laminae and sacrum on US with the plates (laminae) and tail (sacrum) of the dinosaur Stegosaurus. This inspired our description of these features as ‘The Stegosaurus Appearance’ of the lumbar spine on US. Figure (C) was redrawn under an open access Creative Commons CC BY License. Proietti A., Stegosaurus Species, Wikimedia Commons, 2023. Available online: [https://commons.wikimedia.org/wiki/File:Stegosaurus\\_species.jpg](https://commons.wikimedia.org/wiki/File:Stegosaurus_species.jpg). US, ultrasound.

well-established, risk to health of patients and staff, due to the introduction of genetic mutations (6,7). Repeated exposure to even low-dose radiation results in an increased risk of malignancy, such as thyroid cancer and leukaemias, fertility issues in young patients and staff, increased risk of inflammatory diseases, and may put those with unknown pregnancies at greater risk of complications to the unborn foetus (7,8). Furthermore, use of intraoperative X-ray imaging requires specialist radiographer presence in theatre and the use of, often cumbersome, X-ray equipment. This can increase time under anaesthetic and operative costs. Therefore, an imaging system that does not rely on radiation, specialist staff, nor the purchase of new hardware, could prove a useful adjunct to spinal level checking.

Ultrasound (US) assistance for locating and accessing

spinal anatomical structures is well described; it has been shown to aid diagnostic lumbar punctures, minimally invasive spinal procedures, and in neuraxial anaesthesia (9–12). US has excellent reliability in these contexts, improving clinical outcomes and optimising procedure efficiency (10,11). *Figure 1* illustrates the typical view of lumbar spine anatomy one can obtain in the prone or lateral position with a standard curvilinear abdominal US probe. These probes are readily available in most hospitals, and thus there is unlikely to be any need to purchase new hardware or software to utilise US in spinal anatomy assessment (9,11,12).

The accuracy of US in identifying the correct spinal level, compared to the palpation and X-ray confirmation, has not been directly studied in the context of lumbar surgery (9–13). We hypothesised that US assistance could



**Figure 2** Identification of lumbar spinal level using ‘The Stegosaurus Appearance’ on US. (A) Example US image of the lumbar spine of a patient prior to an L5/S1 discectomy. The desired spinal level, (vertical red line) can be calculated using ‘The Stegosaurus Appearance’ of the L4 and L5 laminae and the hyperechoic sacrum (asterisk). (B) Following skin marking and needle fiducial placement using US guidance, an X-ray-based image intensifier snapshot of the lumbar spine confirmed that the spinal level for this patient was indeed L5/S1. US, ultrasound.

be used as an adjunct to accurately identify the desired spinal level prior to virgin lumbar decompression surgery. If proven to be accurate, the use of US in these operations could reduce radiation exposure to patients and staff, optimise operative time, and reduce costs.

This prospective proof-of-concept study was conducted over an 8-month period at a single neurosurgical institution. All emergency and elective primary lumbar discectomies performed under the supervision of a single consultant neurosurgeon during this period were screened for inclusion in the study. Any patients with previous spinal procedures or atypical spinal anatomy would have been excluded from the study. However, no patients with these factors were identified during the study period.

The study was conducted in accordance with the Declaration of Helsinki (as revised in 2013). The study was approved by the Department of Neurosurgery, University Hospital of Wales, Wales, UK research and audit ethics committee and directorate (No. #46997/9338) and informed consent was obtained from all individual participants.

After the induction of anaesthesia and positioning of the patient prone on a Wilson Frame, a neurosurgical registrar or consultant attempted to identify the correct

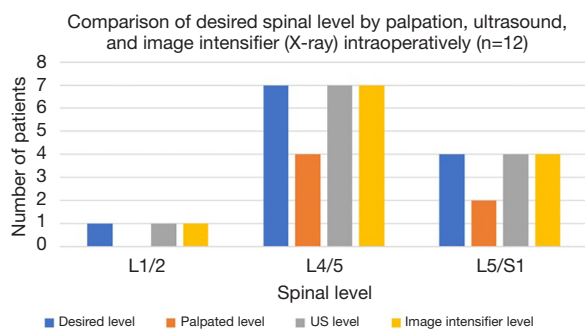
spinal level by palpation, marking the skin at the level they felt represented the target disc space. A standard abdominal curvilinear US probe (frequency 2–5 MHz) connected to either a Sonosite™ or BK™ Ultrasound System, was then used to image the lumbar spine in the parasagittal plane (Figure 1B). This was performed by one of three junior doctors who had been trained in bedside spinal US imaging. The gain and depth on the US system were easily adjustable to optimise image quality for each individual patient; high-quality images were therefore achievable in all cases, even in patients with a high body mass index (Figures 1,2). The time required to obtain the US images is 30–60 seconds, and does not require sterilisation of any hardware (11,12).

First, the sacrum was identified, readily visible via its hyperechoic sloped horizontal line (Figure 1A, asterisk). The acoustic shadows of the spinal laminae are prominent, which resemble a ‘saw-tooth’ appearance. When combined with the elevated linear hyperechoic signal from the sacrum, a perhaps more easily recalled analogy is that the laminae resemble the posterior plates protruding from the back the popular dinosaur Stegosaurus, with the sacral signal mimicking the creature’s tail (Figure 1C). We therefore described these features as ‘The Stegosaurus Appearance’ of the lumbar spine on parasagittal US imaging.

Adjacent to the acoustic signals of the laminae lie depressions, both cranially and caudally. The deep hyperechoic signals within these depressions represent the posterior soft tissues (ligamentum flavum & dura; Figure 1A). The intervertebral spaces can thus be counted in a caudo-cranial direction, using the easily identifiable ‘Stegosaurus Appearance’ of the vertebral laminae and sacrum (Figure 1A). When the desired spinal level was identified on US, the skin was re-marked, and a radiopaque fiducial was placed at the re-marked level. Following this, X-ray imaging was performed as per the usual protocol prior to skin incision.

Any discrepancies between the three methods of spinal level assessment were noted. The operation then proceeded as per normal practise in the study unit. Further intraoperative X-ray images were obtained after skin incision as required, on a case-by-case basis. The utility of US to reliably assess spinal bony anatomy after skin incision is unknown, so its use in the present study was limited to pre-incision level checking.

Twelve patients undergoing primary lumbar discectomy were included in the study. Ten patients underwent elective surgery, and two underwent emergency surgery for cauda equina syndrome. An example of one patient’s pre-incision



**Figure 3** Comparison of the desired spinal level with the level marked via palpation, US, and the level confirmed via X-ray image intensifier. Half of the patients had the incorrect level marked when palpation alone was used (n=6/12). In all twelve operations, the level identified by US correlated exactly with the desired level on X-ray imaging confirmation. US, ultrasound.

US and intraoperative X-ray images are provided in *Figure 2*, prior to the patient's L5/S1 lumbar discectomy. All patients in this study cohort achieved good surgical outcomes, and to date there have been no cerebrospinal fluid leaks, infective complications, recurrent disc prolapses, or spondylolistheses.

Half of the patients in the cohort (6/12) had the incorrect spinal level marked using palpation alone (*Figure 3*). One patient had an L1/2 discectomy, and had the L2/3 level marked upon an attempt to identify the correct level by palpation alone. Three of the seven patients who had L4/5 discectomies had their 'palpation alone level' marked incorrectly as L5/S1 or L3/4. Half of the L5/S1 discectomy patients (2/4) had their level marked incorrectly as L4/5 when assessed by palpation alone (*Figure 3*).

In 100% of cases (12/12), the 'US marked level' was found to successfully identify the desired spinal level after confirmation with intraoperative X-ray images (*Figures 2B,3*).

The utility of US to delineate spinal anatomy was first described over 20 years ago (9). The accuracy of US at identifying spinal levels in that initial study was suboptimal, (approximately 70% accuracy). However, there have been significant advances in US image quality, and in the availability and portability of US machines in healthcare settings, in the years since this study (13,14). The non-invasive, time-efficient, and radiation-free nature of US has driven its burgeoning use as a guidance tool in multiple specialties, including cranial and spinal surgery (15,16).

The use of US for intraoperative assessment of the spinal canal following completion of a laminectomy in

spinal tumour surgery is well described (14), and US guidance during lumbar spinal injections and percutaneous microdiscectomy has also been studied (10,15). More recently, others have reviewed its potential for intraoperative confirmation of neural decompression (17). Incorporating US into lumbar percutaneous discectomy surgery did not influence operation time, but did significantly reduce the number of fluoroscopy shots required during the operation (10). Whilst that study and numerous others have demonstrated the utility of intraoperative US in cranial and spinal surgery, the paradigms described often require procedure-specific software add-on purchases, and the maintenance of sterilisable US hardware (10,14), which can increase operative costs (10,14). The present study describes repurposing hardware and software that is readily available in most, if not all, operating theatres (12,18) to potentially reduce operative time, cost, and radiation exposure in primary lumbar spinal surgery.

We do not envisage that US will be a replacement for intraoperative X-ray-based level check imaging, which will likely remain the gold standard to confirm which spinal level is being operated on for the foreseeable future (19). The use of US is probably, for example, limited to virgin procedures, where the ultrasonographic bony spinal anatomy is well described (11,12). In addition, 'The Stegosaurus Appearance' of the lumbar laminae and sacrum is vital in permitting accurate level counting using US imaging, and so its use is also likely to be restricted to lumbar procedures; thoracic and cervical anatomy on US scans is less distinct, and thus is unlikely to be as reliable for counting spinal levels (9,11-15). We would also advise users to be aware that if atypical spinal anatomy is identified on pre-operative magnetic resonance imaging (e.g., spina bifida, transitional vertebrae) US may then not be reliable for lumbar level checking either.

Concerns over inter-user reliability also represent a barrier to widespread use of US-assisted procedures (15,18). In the present study, the US images were obtained by three separate operators, who were all junior doctors in surgical or foundation training, (of note, they were not radiology trainees). All three operators were equally successful in identifying the desired spinal level using US. This is likely due to: (I) the restriction of the study to primary lumbar procedures, where spinal anatomy was undistorted; and (II) the standardised and easily recognisable anatomical landmarks used to count spinal levels using US (i.e., 'The Stegosaurus Appearance' of the laminae and sacrum). Data from this study therefore imply that inter-user variability



may not be as significant a factor in US-assisted spinal level checking as it can be for other, more complex, US imaging (15-17). This also means that presence of specialised ultrasonographers or radiologists was not required in theatre to perform these US scans, and no new equipment purchases were required. Therefore, utilising US-assisted spinal level checking would not hamper hospitals with new financial or workforce planning stresses.

US level checking could thus play a role in certain circumstances to help optimise care in primary lumbar spine operations. For instance, in some cases there can be delays in the availability of intraoperative X-ray imaging, such as emergency cases for cauda equina syndrome out-of-hours, or delayed availability of a trained radiographer to operate the portable X-ray image intensifier machine. Proceeding with the lumbar surgery using palpation alone, whilst waiting for X-ray imaging to become available, has been shown in our study and others to be inaccurate, and is not recommended (2,3,19). However, the use of US to identify the desired spinal level may permit the surgeon to proceed with the lumbar soft tissue approach stage of the operation with confidence, whilst waiting for intraoperative X-ray imaging equipment and/or staff to become available, which would then permit confirmation of the spinal level by X-ray radiograph, prior to starting the bony decompression. This may help shorten patients' time-under-anaesthetic, improve operating room efficiency, and partially alleviate person-power burdens upon radiography departments.

Since this was a proof-of-concept study we did not assess the number of X-ray images taken in each case. It is thought that the use of 2-4 images per case is common, although this may be higher for new/inexperienced surgeons (10). Our goal was to confirm the accuracy of US for spinal level checking; we were not comparing US level marking plus X-ray imaging versus X-ray imaging alone. Notwithstanding this, our demonstration of the accuracy of pre-incision US level checking implies that utilising US in this context may help reduce radiation exposure to patients and staff during these surgeries. Incorporating US as the tool of choice for the pre-incision level-check could reduce the necessity for pre-incision X-ray imaging; this reduction in the total number of X-rays passing through the abdominopelvic region may be of particular benefit in pregnant patients, (in whom radiation exposure is recommended to be 0 mSv) requiring emergency lumbar surgery. Whilst the absolute radiation exposure per image intraoperatively is small (~1.5 mSv), it is known that even small doses of radiation

can summate to a significant cancer risk, particularly if patients have been exposed to higher dose radiation to the abdominopelvic region previously (e.g., previous abdominal computed tomography scans or previous abdominal/lumbar radiographs) (7). Over longer time periods, more common use of US could also significantly reduce radiation exposure to staff who perform or assist with lumbar surgeries regularly (6,7). Spinal/orthopaedic surgeons have a cancer risk up to 2-3 times that of background population, due to regular exposure to small doses of radiation via intraoperative X-rays, and thus reducing radiation exposure, even the relatively small reductions that could be imparted through more common use of US, remains desirable (20,21).

A study incorporating multiple operators of US across multiple units may be helpful to: (I) validate the findings (regarding the accuracy of US for spinal level checking) of the present study on a larger scale; (II) compare X-ray exposure when US is used to support X-ray-based level checking versus X-ray imaging in isolation; and (III) help alleviate concerns about inter-user variability with US imaging. As the image quality of affordable, portable US systems now rivals that of larger, conventional US machines (17), with some systems becoming even more accessible by projecting their images directly to clinicians' smartphones, the utility of US in pre-incision spinal level checking may become even more appealing over coming years (10-13,15). Furthermore, recent work has demonstrated that US can be integrated with robotic surgery systems to define lumbar spine anatomy, further emphasising the potential need for current and future spinal surgeons to be made aware of, and comfortable with, the use and interpretation of US images in lumbar spine surgery (22).

In conclusion, whilst studies have described the use of US in nerve injection procedures, and to assess the adequacy of spinal decompression intraoperatively (17,21), this proof-of-concept study demonstrates that US could also help surgeons confidently identify the correct spinal level prior to primary lumbar spinal operations. 'The Stegosaurus Appearance' of the virgin lumbar spine on US provides a simple paradigm to standardise counting of spinal levels using US prior to skin incision. US use in level checking might reduce radiation exposure for patients and theatre staff, has the potential to optimise the time interval between the anaesthetic room and 'knife-to-skin', and could reduce operative costs. US level checking may thus represent a useful adjunct to conventional X-ray imaging to confirm the spinal level prior to primary lumbar spinal surgeries.

## Acknowledgments

*Funding:* None.

## Footnote

*Peer Review File:* Available at <https://jss.amegroups.com/article/view/10.21037/jss-24-61/prf>

*Conflicts of Interest:* All authors have completed the ICMJE uniform disclosure form (available at <https://jss.amegroups.com/article/view/10.21037/jss-24-61/coif>). The authors have no conflicts of interest to declare.

*Ethical Statement:* The authors are accountable for all aspects of the work in ensuring that questions related to the accuracy or integrity of any part of the work are appropriately investigated and resolved. The study was conducted in accordance with the Declaration of Helsinki (as revised in 2013). The study was approved by the Department of Neurosurgery, University Hospital of Wales, Wales, UK research and audit ethics committee and directorate (No. #46997/9338) and informed consent was obtained from all individual participants.

*Open Access Statement:* This is an Open Access article distributed in accordance with the Creative Commons Attribution-NonCommercial-NoDerivs 4.0 International License (CC BY-NC-ND 4.0), which permits the non-commercial replication and distribution of the article with the strict proviso that no changes or edits are made and the original work is properly cited (including links to both the formal publication through the relevant DOI and the license). See: <https://creativecommons.org/licenses/by-nc-nd/4.0/>.

## References

- Blamoutier A. Surgical discectomy for lumbar disc herniation: surgical techniques. *Orthop Traumatol Surg Res* 2013;99:S187-96.
- Longo UG, Loppini M, Romeo G, et al. Errors of level in spinal surgery: an evidence-based systematic review. *J Bone Joint Surg Br* 2012;94:1546-50.
- Stahel PF, Sabel AL, Victoroff MS, et al. Wrong-site and wrong-patient procedures in the universal protocol era: analysis of a prospective database of physician self-reported occurrences. *Arch Surg* 2010;145:978-84.
- Broadbent CR, Maxwell WB, Ferrie R, et al. Ability of anaesthetists to identify a marked lumbar interspace. *Anaesthesia* 2000;55:1122-6.
- Zhang MB, Yan LT, Li SP, et al. Ultrasound guidance for transforaminal percutaneous endoscopic lumbar discectomy may prevent radiation exposure: A case report. *World J Clin Cases* 2019;7:1161-8.
- Tough IM, Buckton KE, Baikie AG, et al. X-ray-induced chromosome damage in man. *Lancet* 1960;2:849-51.
- Brenner DJ, Doll R, Goodhead DT, et al. Cancer risks attributable to low doses of ionizing radiation: assessing what we really know. *Proc Natl Acad Sci U S A* 2003;100:13761-6.
- Di Martino A, Russo F, Denaro L, et al. How to treat lumbar disc herniation in pregnancy? A systematic review on current standards. *Eur Spine J* 2017;26:496-504.
- Furness G, Reilly MP, Kuchi S. An evaluation of ultrasound imaging for identification of lumbar intervertebral level. *Anaesthesia* 2002;57:277-80.
- Zhang M, Yan L, Li S, et al. Ultrasound-guided transforaminal percutaneous endoscopic lumbar discectomy: a new guidance method that reduces radiation doses. *Eur Spine J* 2019;28:2543-50.
- Olowoyeye A, Fadahunsi O, Okudo J, et al. Ultrasound imaging versus palpation method for diagnostic lumbar puncture in neonates and infants: a systematic review and meta-analysis. *BMJ Paediatr Open* 2019;3:e000412.
- Oh TT, Ikhsan M, Tan KK, et al. A novel approach to neuraxial anesthesia: application of an automated ultrasound spinal landmark identification. *BMC Anesthesiol* 2019;19:57.
- Carvalho JC. Ultrasound-facilitated epidurals and spinals in obstetrics. *Anesthesiol Clin* 2008;26:145-58, vii-viii.
- Ganau M, Syrmos N, Martin AR, et al. Intraoperative ultrasound in spine surgery: history, current applications, future developments. *Quant Imaging Med Surg* 2018;8:261-7.
- Gofeld M, Bristow SJ, Chiu SC, et al. Ultrasound-guided lumbar transforaminal injections: feasibility and validation study. *Spine (Phila Pa 1976)* 2012;37:808-12.
- Sastry R, Bi WL, Pieper S, et al. Applications of Ultrasound in the Resection of Brain Tumors. *J Neuroimaging* 2017;27:5-15.
- Tat J, Tat J, Yoon S, et al. Intraoperative Ultrasound in Spine Decompression Surgery: A Systematic Review. *Spine (Phila Pa 1976)* 2022;47:E73-85.
- Schmidt GA, Blaivas M, Conrad SA, et al. Ultrasound-guided vascular access in critical illness. *Intensive Care Med* 2019;45:434-46.

19. Mody MG, Nourbakhsh A, Stahl DL, et al. The prevalence of wrong level surgery among spine surgeons. *Spine (Phila Pa 1976)* 2008;33:194-8.
20. Jenkins NW, Parrish JM, Sheha ED, et al. Intraoperative risks of radiation exposure for the surgeon and patient. *Ann Transl Med* 2021;9:84.
21. Chua MMJ, Vasudeva VS, Lu Y. Intraoperative Ultrasound in Spinal Surgery. *J Vis Exp* 2022. doi: 10.3791/58080.
22. Zhang W, Ma Z, Wang H, et al. Study on automatic ultrasound scanning of lumbar spine and visualization system for path planning in lumbar puncture surgery. *Math Biosci Eng* 2023;20:613-23.

**Cite this article as:** Ved R, Hatrick I, Gregory K, Yoganathan S, Nannapaneni R. 'The Stegosaurus Appearance' on ultrasound to assist in identifying the correct spinal level for primary lumbar spinal surgery. *J Spine Surg* 2024;10(4):680-686. doi: 10.21037/jss-24-61