

# TFOS DEWS III: Diagnostic Methodology



JAMES S. WOLFFSOHN, JOSÉ M. BENÍTEZ-DEL-CASTILLO, DENISE LOYA-GARCIA, TAKENORI INOMATA, GEETHA IYER, LINGYI LIANG, HEIKO PULT, ALFONSO L. SABATER, CHRISTOPHER E. STARR, JELLE VEHOFF, MICHAEL T.M. WANG, WEI CHEN, JENNIFER P. CRAIG, MURAT DOGRU, VICTOR L. PEREZ, FIONA STAPLETON, DAVID A. SULLIVAN, AND LYNDON JONES, + TFOS COLLABORATOR GROUP\*

AJO.com Supplemental Material available at [AJO.com](https://ajoc.com).

Accepted for publication May 23, 2025.

School of Optometry (J.S.W.), College of Health and Life Sciences, Aston University, Birmingham, UK; Ocumed-Clinica Rementeria (J.B.D.C.), University Complutense, Hospital Clinico San Carlos, Clinica Rementeria, Madrid, Spain; Instituto de Oftalmología Fundación de Asistencia Privada Conde de Valenciana (D.L.G.), I.A.P., Mexico City, Mexico.; Tecnológico de Monterrey (D.L.G.), School of Medicine and Health Sciences, Monterrey, Mexico; Department of Ophthalmology (T.I.), Junendo University Graduate School of Medicine, Bunkyo-ku, Tokyo, Japan; CODE Eye Care (G.I.), Institute of Excellence for Cornea, Ocular Surface and Dry Eye, Chennai, Tamil Nadu, India, Singapore Eye Research Institute; State Key laboratory of Ophthalmology (L.L.), Zhongshan Ophthalmic Center, Sun Yat-sen University, Guangzhou, China; College of Biomedical & Life Sciences (H.P.), Optometry & Vision Sciences, Cardiff University, UK; Dr. Heiko Pult – Optometry and Vision Research (H.P.), Weinheim, Germany; Bascom Palmer Eye Institute (A.L.S., V.L.P.Q.), University of Miami Miller School of Medicine, Miami, FL, USA; Weill Cornell Medicine (C.E.S.), New York-Presbyterian Hospital, New York, NY; Department of Ophthalmology and Epidemiology (J.V.), University of Groningen, Groningen, the Netherlands; Department of Ophthalmology (J.V.), Vestfold Hospital Trust, Tønsberg, Norway; Department of Ophthalmology (M.T.M.W., J.P.C.), Aotearoa New Zealand National Eye Centre, The University of Auckland, Auckland, New Zealand; Eye Hospital of Wenzhou Medical University (W.C.), National Eye Clinic Research Center, People's Republic of China.; Department of Ophthalmology (M.D.), Tokyo Dental College Ichikawa General Hospital, Ichikawa, Chiba, Japan; School of Optometry and Vision Science (F.S.), UNSW Sydney, NSW, Australia; Tear Film & Ocular Surface Society (D.A.S.), Boston, USA; Centre for Ocular Research & Education (CORE)(L.J.), School of Optometry and Vision Science, University of Waterloo, Waterloo, ON, Canada

ABBREVIATIONS: DED, Dry eye disease; DEWS, Dry Eye Workshop; IL, Interleukin; LIPCOF, Lid-parallel conjunctival folds; MGD, Meibomian gland dysfunction; MMP, Matrix metalloproteinase(s); OCT, Optical coherence tomography imaging; OR, Odds ratio; OSDI, Ocular Surface Disease Index; TFOS, Tear Film & Ocular Surface Society.

Corresponding author: James S. Wolffsohn, Vision Sciences, Aston University, Aston Triangle, Birmingham, B4 7ET, United Kingdom.; e-mail: [j.s.w.wolffsohn@aston.ac.uk](mailto:j.s.w.wolffsohn@aston.ac.uk)

\* TFOS Collaborator Group: Reiko Arita, Itoh Clinic, University of Tokyo, Japan; [ritoh@za2.so-net.ne.jp](mailto:ritoh@za2.so-net.ne.jp); Carlos Belmonte, Instituto de Neurociencias, Universidad Miguel Hernández-CSIC, Avda Santiago Ramón y Cajal s/n, Alicante, Spain; [carlos.belmonte@umh.es](mailto:carlos.belmonte@umh.es); Robin L Chalmers, Clinical Trial Consultant, Atlanta, Georgia, USA; [chalmers2097@gmail.com](mailto:chalmers2097@gmail.com); Anat Galor, Miami Veterans Affairs Medical Center Ophthalmology, Bascom Palmer Eye Institute, University of Miami Miller School of Medicine, Florida, USA; [AGalor@med.miami.edu](mailto:AGalor@med.miami.edu); Arkasubhra Ghosh, Molecular Signalling and Gene Therapy, GROW laboratory, Narayana Nethralaya Foundation ([nnf.org.in](http://nnf.org.in)), Bangalore, India; [Arkasubhra@narayananeethralaya.com](mailto:Arkasubhra@narayananeethralaya.com); Marc Labetoulle, Ophthalmology Department, Bicêtre Hôpital, APHP, Paris-Saclay University, Kremlin-Bicêtre, France; Quinze-Vingts Hospital, Paris, France; [marc.labetoulle@aphp.fr](mailto:marc.labetoulle@aphp.fr); Kelly K. Nichols, School of Optometry, The University of Alabama at Birmingham, Alabama, USA; [nicholsk@uab.edu](mailto:nicholsk@uab.edu); Andrew D. Pucker, Eminent Ophthalmic Services, Milledgeville, Georgia, USA; [andrewpucker@hotmail.com](mailto:andrewpucker@hotmail.com); Eduardo M. Rocha, Dept of Ophthalmology, Otorhinolaryngology and Head & Neck Surgery Ribeirao Preto Medical School, University of Sao Paulo,

A standard approach to the diagnosis of dry eye disease across eye care practitioners is critical to reassuring the patient, providing consistency between practitioners and informing governments as to the true prevalence and resulting healthcare needs. The Tear Film & Ocular Surface Society (TFOS) Dry Eye Workshop (DEWS) III has reviewed the evidence-base since their previous reports published in 2017 and revised the definition to “Dry eye is a multifactorial, symptomatic disease characterized by a loss of homeostasis of the tear film and/or ocular surface, in which tear film instability and hyperosmolarity, ocular surface inflammation and damage, and neurosensory abnormalities are etiological factors.” Key features from the definition include that dry eye disease is multifactorial, is a disease and not a syndrome and is always symptomatic. Differential diagnosis and ocular examination guidance is given along with the risk factors that should be discussed with the patient. The recommended screening questionnaire is the OSDI-6 with a cut-off score  $\geq 4$ . A positive result together with a non-invasive breakup time  $< 10$ s or alternatively tear film hyperosmolarity ( $\geq 308$ mOsm/L in either eye or an interocular difference  $> 8$ mOsm/L) or alternatively  $> 5$  corneal fluorescein and/or  $> 9$  conjunctival lissamine green punctate spots and/or lid margin lissamine green staining of  $\geq 2$ mm length &  $\geq 25$  % width, gives a diagnosis of dry eye. Subclassification was separated into tear film deficiencies (lipid, aqueous and mucin/glycocalyx), eyelid anomalies (blink/lid closure and lid margin) and ocular surface abnormalities (anatomical misalignment, neural dysfunction, ocular surface cell damage/disruption and primary inflammation/oxidative stress) components, with appropriate clinical tests and cut-offs provided to identify these etiological drivers in an individual, to inform appropriate management and therapy. (Am J Ophthalmol 2025;279: 387–450. © 2025 The Author(s). Published by Elsevier Inc. This is an open access article under the CC BY license (<http://creativecommons.org/licenses/by/4.0/>))

Brazil; [emrocha@fmrp.usp.br](mailto:emrocha@fmrp.usp.br); Benjamin D. Sullivan, Bausch & Lomb, Bridgewater, New Jersey, USA; Lubris BioPharma, Florida, USA; [bdsliv@me.com](mailto:bdsliv@me.com); Piera Versura, Alma Mater Studiorum University of Bologna Cornea-Ocular Surface Lab and Translation Research in Ophthalmology IRCCS Azienda Ospedaliero-Universitaria Di Bologna, Bologna Italy; [piera.versura@aosp.bo.it](mailto:piera.versura@aosp.bo.it); Mark D P Willcox, School of Optometry and Vision Science, UNSW Sydney, Australia; [mdpwillcox@gmail.com](mailto:mdpwillcox@gmail.com)

---

## 1 INTRODUCTION

THE TEAR FILM & OCULAR SURFACE SOCIETY (TFOS) second dry eye workshop (DEWS II) Diagnostic Methodology report<sup>1</sup> provided practical, clinical diagnostic recommendations for dry eye disease (DED), based on the evidence available for tests with diagnostic potential to align with the revised definition of DED.<sup>2</sup> It also provided a clear rationale for the framework that informed the number and characteristics of the selected tests. Questions to inform a differential diagnosis were proposed. The need for subclassification post-diagnosis was emphasized, to inform management approaches. The purpose of the TFOS DEWS III Diagnostic Methodology report was to do the following:

- Revisit the current definition<sup>2</sup> to ensure alignment with current understanding of DED
  - Provide a rationale for the components of the definition
  - Highlight considerations when a patient has only symptoms or signs associated with DED
  - Define associated conditions
- Draw on risk/associated factors for DED (from the TFOS DEWS III: Digest) and masquerading diseases to guide appropriate history and symptom-taking
- Identify any updates required to the 2017 diagnosis of DED, reiterating the rationale for change and perceived challenges with regard to the available evidence
- Propose a new etiological driver-based approach to subclassification, identifying the tests that indicate the driver involved in an individual's dry eye, which can then be linked to management approaches by the TFOS DEWS III Management and Therapy report
- Discuss possible future directions that could help to inform further advances in DED diagnosis and subclassification.

---

## 2 DEFINITIONS

• **2.1 DRY EYE DISEASE (DED):** In 2017, after careful consideration of the terminology including diction, word order, emphasis, and accepted meaning, DED was defined by a multidisciplinary and transnational committee as “a multifactorial disease of the ocular surface characterized by a loss of homeostasis of the tear film, and accompanied by ocular symptoms, in which tear film instability and hyperosmolarity, ocular surface inflammation and damage, and neurosensory abnormalities play etiological roles.”<sup>29</sup> This was ratified by the full TFOS DEWS II authorship consisting of 150 clinical and basic science research experts from around the world, who utilized an evidence-based approach and a process of open communication, dialogue, and transparency to consolidate the understanding of DED.<sup>3</sup>

It was the consensus of TFOS DEWS III that the definition did not require radical change based on our updated understanding of the disease pathology and the tear film,<sup>4</sup> but noted the intrinsic role of the ocular surface tissues as well as the tear film in homeostasis leading to repositioning of this aspect in the revised definition to read “Dry eye is a multifactorial, symptomatic disease characterized by a loss of homeostasis of the tear film and/or ocular surface, in which tear film instability and hyperosmolarity, ocular surface inflammation and damage, and neurosensory abnormalities are etiological factors.” Key aspects of the definition include the following:

### 2.1.1 Multifactorial

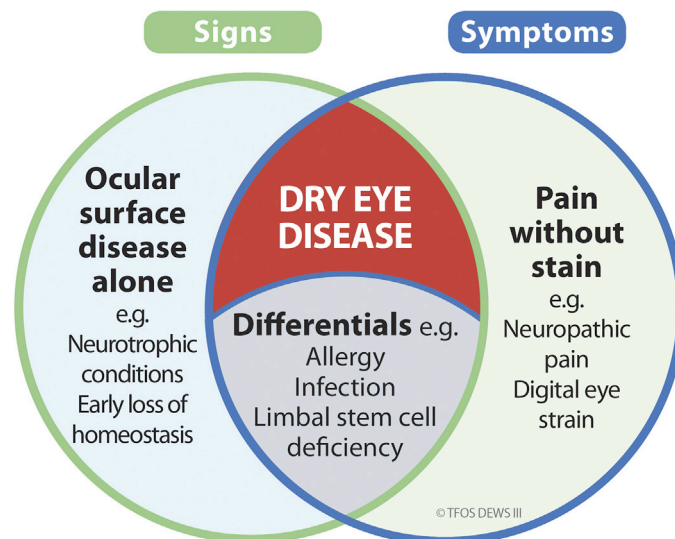
There are many aspects of our lifestyle that can impact the ocular surface including digital environments,<sup>5</sup> environmental conditions,<sup>6</sup> nutrition,<sup>7</sup> use of cosmetics,<sup>8</sup> elective medication and procedures,<sup>9</sup> contact lenses,<sup>10</sup> societal factors,<sup>11</sup> and general lifestyle.<sup>12</sup> All of these, therefore, need to be considered in the management of the disease, and appropriate treatment or therapy is likely to include more than one approach or treatment. In addition, genetic factors have been found to play a role in DED.<sup>13-15</sup>

### 2.1.2 Disease, not a syndrome

When a combination of symptoms and physical findings are common to a group of patients but the direct cause is not yet understood, it is referred to as a syndrome (from the Greek roots meaning “running together”).<sup>16</sup> However, once causative agents or processes have been identified that have a moderately high degree of certainty, then it is appropriate to use the term “disease” rather than “syndrome.”<sup>16</sup> Dry eye was once considered a syndrome due to insufficient understanding of its etiology. However, advances in medical knowledge have revealed its clearly identifiable diagnostic features<sup>1</sup> and disease progression<sup>4</sup> and its response to specific treatments.<sup>17</sup> These insights support the current recognition of dry eye as a disease entity rather than a syndrome.<sup>2</sup> Defining dry eye as a disease is an important issue for patients (as this can affect reimbursement for clinical care and treatment as well as their understanding of their symptoms that are impacting their quality of life), and for eye care practitioners, since in some countries, certain professions are not permitted to treat “disease.” The TFOS DEWS III consensus is that all eye care practitioners play an important role in managing patients with DED within the limits of their clinical competency, by providing evidence-based advice on lifestyle factors<sup>18</sup> and over-the counter treatments, as a minimum.

### 2.1.3 Dry eye is a subset of ocular surface disease and can coexist with other ocular surface disease

DED is defined as a symptomatic disease and thus, by definition, must always be accompanied by ocular symptoms. Recognition of DED as a symptomatic disease is not new;



**FIGURE 1.** Venn diagram illustrating that dry eye disease requires the presence of both signs and symptoms, and exclusion of differential diagnoses. Dry eye disease can coexist with other forms of ocular surface disease and symptomatic conditions.

the National Eye Institute/Industry Workshop in 1995 defined dry eye as “a disorder of the tear film ... associated with symptoms of ocular discomfort.”<sup>19</sup> The first TFOS DEWS report identified dry eye as a “disease of the tears and ocular surface that results in symptoms of discomfort ...”<sup>20</sup> and TFOS DEWS II as a “disease of the ocular surface characterised by a loss of homeostasis of the tear film and accompanied by ocular symptoms ....”<sup>2</sup> Hence, ocular surface signs in the absence of symptoms reflect the presence of ocular surface disease (Figure 1), but do not signify the existence of DED specifically.

**2.1.3.1 Signs vs symptoms.** It is acknowledged that there are pathological conditions that result in symptoms without clinically significant signs (see Section 4.2), which present with signs but without symptoms (see Section 4.1), or which exhibit both dryness symptoms and signs but are not DED, as they have a different pathophysiology (see Section 3.1). Such conditions can coexist with dry eye disease; for example, a patient with severe symptoms, but only mild signs, may have neuropathic pain in conjunction with mild DED (see Section 4). This is important to recognize from a management perspective, as it may indicate the need for a multimodal approach.<sup>17</sup>

#### 2.1.4 Ocular symptoms include vision

Vision and vision-specific tasks can be significantly affected by DED due to destabilisation of the tear film disrupting the smooth air-tear interface between blinks or damage to the ocular surface affecting corneal transparency.<sup>21-25</sup> An unstable tear film results in light scatter and visual fluctuations between blinks.<sup>26-28</sup> Sensitivity to light and “spots in vision” are more commonly reported accompanying DED than glaucoma and/or cataract.<sup>29</sup> Hence, while vision is

not specifically mentioned in the definition of DED (as there are many associated symptoms), visual disturbance is acknowledged to be encompassed within the terminology of “ocular symptoms.” As also previously noted by TFOS DEWS II, the term “symptoms” is considered to cover a wide range of possible patient-reported sensations associated with DED, which can include discomfort and/or visual disturbance.<sup>3</sup>

#### 2.1.5 Pathophysiology elements

The component of the definition describing the disease pathology (see TFOS DEWS III Digest Pathophysiology section<sup>4</sup>) needs to exclude other conditions with both signs and symptoms, but with different pathophysiology and their own appropriate management strategies. Clinically, these can be excluded through a process of differential diagnosis (see Section 3.1).

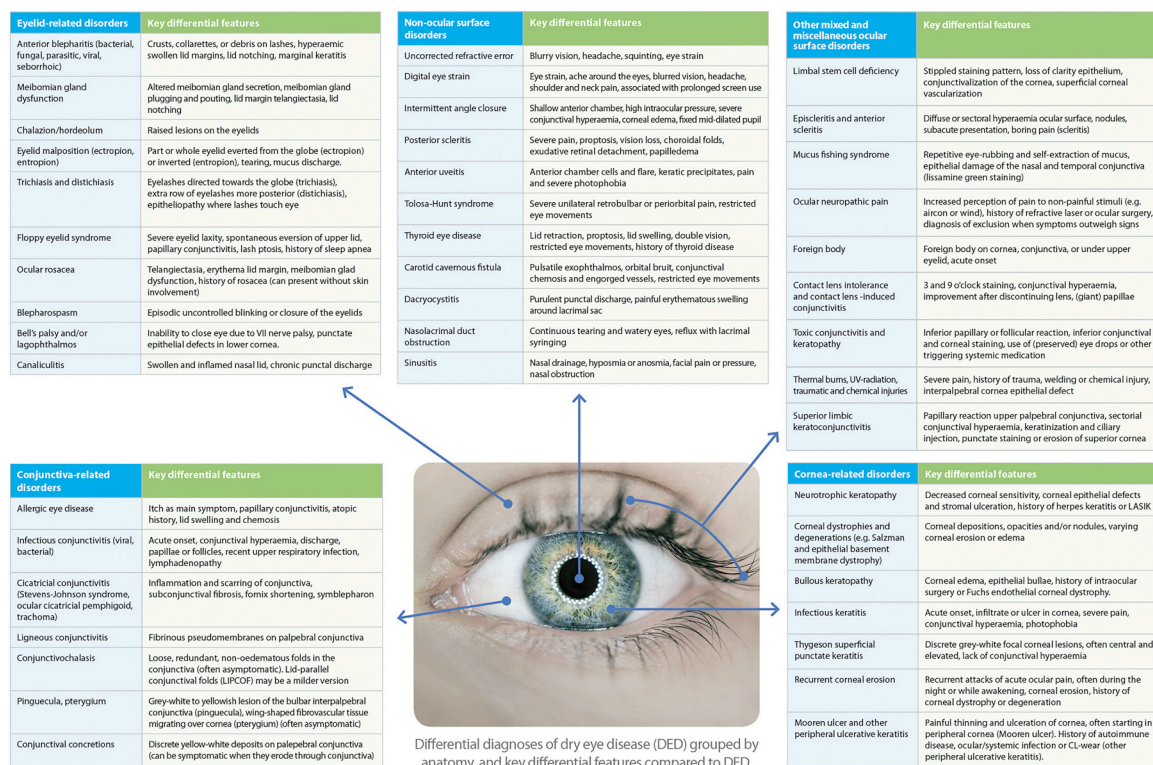
## 3 HISTORY AND SYMPTOMS

- **3.1 DIFFERENTIAL DIAGNOSIS:** Both symptoms and signs of DED are heterogeneous. Therefore, the differential diagnosis of DED is extensive and encompasses most ocular surface disease (Figure 2). Several of the ocular surface changes caused by conditions identified as differential diagnoses of DED may increase the risk of DED, and DED may sometimes exacerbate other ocular surface diseases with similar symptoms (see Section 3.2). Thus, many of the differential diagnoses are often comorbid with DED. There are also nonocular surface disease diagnoses that may mimic dry eye symptoms and that are particularly important to consider when no ocular surface disease signs are present.



# Differential diagnoses of dry eye disease

© TFOS DEWS III



**FIGURE 2.** Key differential diagnoses of dry eye disease (DED) grouped by anatomy, and main differential features compared to DED.

Figure 2 gives an overview of differential diagnoses of DED and their key differential features. The following sections focus on the most common differential diagnoses of DED.

## 3.1.1 Eyelid-related disorders

While patients with anterior blepharitis or meibomian gland dysfunction (MGD) do not always have DED, as these conditions can be asymptomatic, they are commonly a driver of DED (see Section 3.5.3.2) Diseases affecting the eyelids, such as chalazion, hordeolum, entropion, ectropion, trichiasis/distichiasis, floppy eyelid syndrome, blepharospasm, ocular rosacea, Bell's palsy and canaliculitis may result in symptoms similar to DED including watery eyes as a neuroregulated response to dry or irritated ocular surface,<sup>30</sup> and so a thorough eyelid examination should be performed in every patient suspected of having DED.<sup>31</sup>

## 3.1.2 Conjunctival and corneal abnormalities

To distinguish between DED and other etiologies, a thorough patient history is vital; this is especially important in patients with a history of contact lens wear,<sup>32</sup> use of multiple eye drops, or exposure to toxic chemicals.<sup>33,34</sup> Observation of the ocular surface provides further useful information. For example, a "curl" pattern of fluorescein staining (which may indicate epithelial stress, for example due to medication toxicity)<sup>33</sup> or corneal con-

junctivalization (which may be indicative of limbal stem cell deficiency).<sup>32,35</sup> Fluorescein staining in the superior cornea may point to superior limbic keratoconjunctivitis<sup>36</sup> or floppy eyelid syndrome,<sup>37</sup> or may result from contact lens wear issues.<sup>38-40</sup> Non-responsive to standard DED therapies warrants consideration of concurrent systemic conditions such as mucus membrane pemphigoid (ocular cicatricial pemphigoid) or Stevens-Johnson syndrome.<sup>41,42</sup> Even though DED can co-exist in these conditions, early diagnosis is vital, as advanced therapies including systemic immunomodulatory therapy are often required.

Superficial punctate keratitis can commonly be observed in a variety of corneal disorders. If it is primarily the superior cornea that is affected, possible causes include vernal keratoconjunctivitis, superior limbic keratoconjunctivitis, trachoma, poorly fitting contact lenses, floppy eyelid syndrome, trichiasis, or distichiasis.<sup>38</sup> If it is primarily inferior in location, it might more likely be attributable to ocular rosacea, atopic keratoconjunctivitis, allergic keratitis, blepharitis, exposure keratopathy, lower eyelid margin lesions, topical medication toxicity, entropion or ectropion, trichiasis, or distichiasis.<sup>38</sup> If the superficial punctate keratitis is primarily interpalpebral, it may be contact lens related (chemical toxicity, tight lens syndrome, overwear syndrome), or may be due to exposure to ultraviolet light, neurotrophic keratopathy, or DED.<sup>38</sup>

Filamentary keratitis is a persistent corneal condition, recognizable by the presence of fine strands (from mucin bound degenerated epithelial cells) and mucus that adhere to the corneal surface.<sup>43-45</sup> It may arise secondary to DED, causing discomfort symptoms and photophobia; blepharospasm and increased blinking are also common.<sup>46</sup>

### 3.1.2.1 Conjunctival-related disorders.

**3.1.2.1.1 Allergic conjunctivitis.** The signs and symptoms of dry eye overlap with those of allergic conjunctivitis, and the conditions can coexist.<sup>47,48</sup> In a study of 689 randomly sampled patients from an ambulatory optometric practice in California in the United States, 57% of those reporting itching had clinically significant dryness, and 45% of those with dry eye reported itching.<sup>49</sup> Immunoglobulin E (IgE) antibodies against seasonal or perennial allergens are commonly evaluated by a blood test,<sup>50</sup> and diagnostic tests are available to detect the presence of IgE in the tear film. Additionally, typical ocular signs of allergy, such as eyelid edema, and conjunctival papillae as well as conjunctival chemosis, help differentiate allergic conjunctivitis from DED.<sup>51,52</sup> A strong family history of allergy, atopic dermatitis, and/or the presence of asthma is common in those patients.<sup>53</sup> Atopic and vernal keratoconjunctivitis, chronic, bilateral, inflammatory, and visually threatening forms of the disease also have signs and symptoms similar to those of DED and can serve as a trigger for DED. Signs of inflammation can be found in the cornea, conjunctiva, and eyelids. Typically, symptoms are photophobia, burning, tearing, itching, mucous discharge, and hyperemia and papillary hypertrophy of the eyelids. Some of the most common signs found in both atopic keratoconjunctivitis and DED (although generally less severely in DED) include superficial punctate keratitis, conjunctival injection or hyperemia, anterior blepharitis, MGD, and tear instability.<sup>39,54-57</sup> Atopic keratoconjunctivitis should be considered if there are signs such as conjunctivitis (possibly with scarring) and periorbital eczema,<sup>58</sup> corneal neovascularization, symblepharon, keratoconus, and sometimes anterior polar cataracts.<sup>59,60</sup> Again, a family history of allergy, atopic dermatitis (occurring in 95% of cases), asthma (occurring in 87%), and periorbital eczema are common.<sup>39,61,62</sup>

**3.1.2.1.2 Viral conjunctivitis.** While viruses cause approximately 80% of cases of acute infectious conjunctivitis in adults, they may be responsible for only around 20% of pediatric cases.<sup>63,64</sup> Even though watery discharge is typical of viral conjunctivitis, this may also be seen in about 25% of bacterial cases.<sup>63,64</sup> Most viral conjunctivitis involves the highly contagious adenovirus (65%-90%),<sup>65</sup> which has an incubation period of 4 to 10 days before being clinically observable<sup>66</sup> and may have associated pharyngoconjunctival fever and epidemic keratoconjunctivitis. Other causes of viral conjunctivitis include herpes viruses, picornaviruses, and several systemic viral infections.<sup>39,64</sup> Unilateral herpetic keratitis can affect the tear film of both eyes.<sup>67,68</sup> Even

though viral conjunctivitis shares a number of findings with DED such as tearing, burning, redness, irritation, photophobia, and blurred vision, the following signs and symptoms may help to differentiate a viral etiology.<sup>39,69</sup>

- Acute onset of signs and symptoms
- Redness and irritation initially in one eye, which often spreads to the other eye within a few days
- Recent upper respiratory tract infection or close contact with someone with a red eye
- Crusting around the eyes in the morning
- Examination findings of watery, mucoid discharge and red, edematous eyelids
- Preauricular lymphadenopathy (swelling of the lymph nodes anterior to the ears, which drain lymph fluid from the area around the eyes, cheeks, and surrounding scalp).

Epstein-Barr virus infects more than 90% of the adult population.<sup>70</sup> Even though the infection of ocular structures with the Epstein-Barr virus results most commonly in transient follicular conjunctivitis,<sup>71</sup> it can also present with signs and symptoms similar to those of DED, as well as with keratitis, uveitis, choroiditis, retinitis, ocular glandular syndrome, papillitis, and ophthalmoplegia.<sup>72</sup> Several systemic viruses, including measles, rubella (German measles), mumps, and influenza, are also frequently associated with conjunctivitis.<sup>69</sup>

**3.1.2.1.3 Bacterial conjunctivitis.** Bacteria as a causative agent of conjunctivitis occurs more often in children than in adults (70% vs 20% of cases).<sup>63,73</sup> Purulent conjunctival discharge and morning eyelash crusting may suggest a bacterial involvement, but this does not rule out a viral cause.<sup>63</sup> Patients with bacterial conjunctivitis may complain of symptoms similar to those of DED, such as burning, stinging, irritation, foreign body sensation, and photophobia. In contrast to dry eye, there is typically significant conjunctival hyperemia (often more than with viral conjunctivitis or DED) and discharge (typically moist and mucopurulent). Affected patients often complain about matting or clumping of the eyelashes, mostly in the morning. Bacterial conjunctivitis can occur in one or both eyes and systemic findings may be present, especially in children, such as purulent rhinorrhea and respiratory infection, fever, and malaise.<sup>74</sup> Chlamydial conjunctivitis should be considered in sexually active persons who present with a chronic follicular conjunctivitis, that is more prominent in the lower palpebral conjunctiva, and with mucopurulent discharge.<sup>75</sup>

**3.1.2.1.4 Cicatrizing conjunctivitis.** Cicatrizing conjunctivitis is characterized by inflammation and scarring of the conjunctiva. Cicatrization can range from mild and subtle, with only subconjunctival fibrosis, often seen as fine white lines at the palpebral conjunctiva, to extensive, with shortening of the fornix, multiple symblepharon, and ankyloblepharon. It can induce ocular dryness and lead to gross distortion of the anatomy of the eyelid and ocular surface, including entropion, trichiasis, limbal stem cell deficiency,

and keratinization of the ocular surface. Causes of cicatrizing conjunctivitis are many and include autoimmune diseases such as ocular pemphigoid, epidermolysis bullosa, sarcoidosis, systemic sclerosis, Sjögren's disease, and lichen planus, bacterial and viral conjunctivitis such as trachoma and adenoviral conjunctivitis, thermal and chemical burns, graft-versus-host disease, Stevens–Johnson syndrome, ocular rosacea, and atopic keratoconjunctivitis. Conjunctival biopsy is important to confirm a diagnosis and to identify the cause.<sup>76-78</sup>

**3.1.2.1.5 Conjunctivochalasis.** Conjunctivochalasis is characterized by loose, redundant, nonedematous folds in the conjunctiva, the more mild expression of which is lid-parallel conjunctival folds (LIPCOF). It is most often seen in the inferior bulbar conjunctiva, overlying the inferior lid margin. It is often asymptomatic, but can lead to tear film instability and symptoms consistent with those of DED, including irritation, dryness, foreign body sensation, mucus discharge, and tearing. The etiology of conjunctivochalasis is still unclear, but it is more common with increasing age, in patients with DED, and in contact lens wearers. Symptoms may be increased during downward gaze or with vigorous blinking.<sup>79,80</sup>

**3.1.2.1.6 Pinguecula and pterygium.** A pinguecula is a benign degeneration of the conjunctiva that presents as a gray–white or yellowish lesion on the bulbar interpalpebral conjunctiva, adjacent to the limbus, which may cause localized disruption of the tear film due to a change in lid-globe alignment. Wind, dust, and ultraviolet (UV) exposure are factors associated with pinguecula and pterygium development. Pinguecula are usually asymptomatic, but may present with mild foreign body sensation or itch.<sup>81</sup> A pterygium is a wing-shaped protrusion representing growth of epithelial and fibrovascular tissue from the neighboring conjunctiva migrating over the corneal limbus. Pterygia have similar associated factors as pingueculae, and a pterygium is often preceded by, or is comorbid with, a pinguecula. Irregular astigmatism with a pterygium can lead to visual symptoms, and irritation may be present. Inflammation of pterygia and pingueculae is also possible, leading to conjunctival hyperemia and edema, and increased chance of irritation.<sup>82,83</sup>

**3.1.2.1.7 Conjunctival concretions.** Conjunctival concretions are benign discrete yellow–white deposits, most commonly found in the palpebral conjunctiva or fornices. Most are idiopathic and the result of degenerative changes with ageing, but they may be secondary to conjunctival inflammation, such as that associated with allergic keratoconjunctivitis, trachoma, and DED. They are normally asymptomatic, but when they erode through the conjunctiva they may irritate the cornea and bulbar conjunctiva.<sup>84</sup>

### 3.1.2.2 Corneal-related disorders.

**3.1.2.2.1 Neurotrophic keratitis.** Neurotrophic keratitis is characterized by a decrease in corneal sensitivity and stems from dysfunction in the ophthalmic division of the

trigeminal nerve, which can be triggered by conditions such as diabetes mellitus, ocular herpes simplex/zoster, nonocular surface neoplasia, or ophthalmic surgery. This dysfunction ultimately leads to a decrease in aqueous tear production.<sup>39</sup>

#### 3.1.2.2.2 Corneal dystrophies and degenerations.

Corneal dystrophies and degenerations present with similar symptoms as DED. They can also lead to recurrent corneal erosions. The more common cases seen in clinical practice are Salzmann nodular degeneration, epithelial basement membrane dystrophy, and Fuchs endothelial corneal dystrophy. Salzmann nodular degeneration is a noninflammatory degeneration of the anterior cornea with blue–white–grayish subepithelial nodules of the cornea, usually mid-peripheral. It can lead to symptoms of decreased visual acuity and irritation, pain, foreign body sensation, and blepharospasm,<sup>85,86</sup> epithelial basement membrane dystrophy, previously known as map–dot–fingerprint dystrophy; it affects around 42% of the general population and is characterized by abnormal epithelial turnover, maturation, and production of basement membrane. Typical signs are gray patches, microcysts, and fine lines in the corneal epithelium, and typical symptoms are blurred vision and pain.<sup>87,88</sup> Fuchs endothelial cornea dystrophy is a hereditary progressive disease of the posterior cornea, with progressive decline of corneal endothelial cells and the formation of extracellular matrix excrescences in the Descemet membrane. This can eventually lead to corneal edema, bullous keratopathy (see Section 3.1.2.2.3), loss of vision, photophobia, epiphora, and pain.<sup>89</sup>

**3.1.2.2.3 Bullous keratopathy.** Bullous keratopathy forms small vesicles or bullae in the cornea due to endothelial dysfunction. These blister-like formations can rupture painfully and disrupt vision. Treatment options may include 5% sodium chloride or other hyperosmotic eye drops to reduce swelling, amniotic membranes, bandage contact lenses for comfort, antiglaucoma medications (when associated with glaucoma) to decrease fluid flow into the cornea, and corneal transplants to replace damaged tissue.<sup>90</sup>

**3.1.2.2.4 Infectious keratitis.** Infection of the cornea can be microbial (bacteria, fungal or parasitics), or viral (herpes simplex or zoster), and is a sight-threatening condition that always needs to be ruled out in patients with ocular surface symptoms. Contact lens wear, topical steroid use, ocular trauma, previous keratitis, and previous ocular surgery are important risk factors. Blurred vision, bulbar hyperemia, pain, photophobia, tearing and discharge, and an acute, unilateral clinical picture should particularly raise suspicion.<sup>91</sup>

**3.1.2.2.5 Thygeson superficial punctate keratitis.** Thygeson superficial punctate keratitis is a chronic and recurrent corneal epitheliopathy with episodes of foreign body sensation, tearing, photophobia, and visual symptoms. Clinical signs are multiple, slightly elevated, round or oval, white–gray intraepithelial corneal lesions, usually with little or no conjunctival involvement. Etiology and optimal treatment



are unknown as yet, but mild topical corticosteroids and immunomodulatory agents are often effective in causing regression of the keratitis.<sup>92</sup>

### 3.1.3 Other mixed and miscellaneous ocular surface disorders

**3.1.3.1 Limbal stem cell deficiency.** Limbal stem cell deficiency is characterized by loss or deficiency of the limbal epithelial stem cells, which are essential for the maintenance of the corneal surface and its physiological functioning. Diagnosis is primarily clinical, with varying signs depending on the stage, such as a stippled staining pattern of the epithelium, late fluorescein staining, loss of corneal transparency, conjunctivalization of the cornea, and superficial corneal vascularization. Symptoms include ocular redness, discomfort, pain, tearing, photophobia, and decreased vision, the latter occurring particularly when the visual axis is involved.<sup>93</sup>

**3.1.3.2 Episcleritis.** Episcleritis is a usually benign and self-limiting disease of the episcleral tissue that presents as superficial bulbar redness, most commonly in the interpalpebral area. In the majority of patients, the inflammation is limited to a single sector, but may involve the entire episclera, and may present with a semi-mobile nodule. Symptoms are often not present, but may include localized irritation and tenderness.<sup>94</sup>

**3.1.3.3 Mucus fishing syndrome.** Mucus fishing syndrome is caused by repetitive eye rubbing and self-extraction of mucus discharge (for example, that arises as a result of DED or allergic conjunctivitis) out of the eye, leading to chronic inflammation of the ocular surface, and triggering further mucus production, sparking a vicious cycle. An important clinical sign is epithelial damage (as seen by lissamine green staining) of the nasal and temporal conjunctiva.<sup>95,96</sup>

**3.1.3.4 Ocular neuropathic pain.** Ocular neuropathic pain, or corneal neuropathic pain, is characterized by increased perception of pain in response to stimuli that are normally not painful. It is usually a diagnosis of exclusion, when symptoms outweigh clinical signs. Questionnaires that potentially could be used for the diagnosis of ocular neuropathic pain have been identified, although no gold standard questionnaire has been established.<sup>97</sup> Neuropathic pain can result from injury or disease of peripheral corneal nerves, but may also have a central nervous system origin.<sup>98</sup> A proparacaine challenge test may help to distinguish between neuropathic pain of peripheral or central origin.<sup>99</sup> Reported symptoms may be very similar to those of DED, albeit often very severe, and treatment is often difficult and encompasses both regular ocular surface treatments including anti-inflammatory options and systemic analgesics, tricyclic antidepressants, anticonvulsants (for example, gabapentin and pregabalin), low-dose naltrexone, and electrical neurostimulation to reduce pain.<sup>100-102</sup>

### 3.1.4 Nonocular surface disease disorders

Finally, the early stage of several nonocular surface disease disorders of the eye, orbit, and surrounding tissues may mimic symptoms of DED. These should be considered particularly when no ocular surface signs are visible. Ocular disorders include refractive error (such as latent hypermetropia), digital eye strain, intermittent angle closure, anterior scleritis, and uveitis. Orbital disorders include Tolosa–Hunt syndrome, thyroid eye disease (which may ultimately lead to severe ocular surface disease secondary to chronic exposure), and carotid cavernous fistula and disorders of the nasolacrimal duct that include dacryocystitis and nasolacrimal duct obstruction. In addition, sinusitis and headache disorders may also present with referred pain around the eye.<sup>103</sup>

### 3.1.5 Summary

Many conditions can mimic symptoms and/or signs of DED. Failing to investigate possible comorbidities may lead to delayed diagnoses of source conditions and may impact outcomes due to suboptimal treatment. To aid in the differential diagnoses, specific questions are listed below. For patients in whom the differential diagnostic history and symptoms suggest source issues unrelated to, or triggering DED, a detailed anterior eye examination using a slitlamp biomicroscope is warranted,<sup>39</sup> including assessment of the following:

- Eyelashes for blepharitis, trichiasis, distichiasis, milphosis, madarosis, and/or poliosis
- Eyelids, including palpebral conjunctiva for irregularities or the presence of follicles, papillae or swelling, and eyelashes for crusting or cylindrical dandruff, and meibomian gland orifices for blockage, pouting, or presence of *Demodex* tails
- Ocular surface for conjunctivochalasis, pinguecula, pterygium, and any post-treatment/postsurgical signs of corneal disruption (see Section 3.5.4.1)
- Bulbar conjunctiva for redness and/or swelling
- Cornea, including staining, for signs of ulceration, marginal keratitis, erosion, lesions, and possible trauma
- Anterior chamber for the presence of cells or keratic precipitates indicating intraocular inflammation.

Medications that can cause DED and the use of cosmetics should be considered (as reviewed by the TFOS Lifestyle reports,<sup>8,9</sup> as well as risk/associated factors (as reviewed in the TFOS DEWS III: Digest<sup>4</sup>), including general health conditions.

Key clinical differential diagnosis questions asked of patients, alongside general health and medications, are:

- Do you feel eye pain rather than discomfort?
  - DED commonly presents with symptoms of discomfort, light sensitivity, or blurred vision, rather than pain, especially in mild-to-moderate dry eye. If pain is present, investigate for signs of

trauma/erosion/infection/ulceration/acute glaucoma, and consider administering a pain questionnaire (see Section 3.1.2.2).

- Do you have any facial flushing/redness, mouth dryness, or enlarged salivary glands?
  - Trigger for rosacea, sarcoidosis, or Sjögren's disease investigation.
- When did your symptoms start, and can you recall any triggering event?
  - DED is a chronic condition. If there is increased dryness when waking up or dryness symptoms at night, consider incomplete lid closure, for example.
  - If the onset was sudden or linked with an event, examine the eyes for trauma/infection/ulceration.
  - If the symptoms are linked with contact lens use, refer to the patient's contact lens practitioner to consider alternative approaches that might improve symptoms (such as changing lens material, fit, or modality).<sup>104</sup>
- Is your vision affected, and if so, does it improve on blinking?
  - A reduction in vision that does not improve with blinking, especially with sudden onset, requires an urgent complete ophthalmic examination to rule out conditions such as vascular occlusions.
- Are the symptoms or any redness much worse in one eye than the other?
  - DED is commonly bilateral. If signs and/or symptoms are significantly greater in one eye, investigate for signs of trauma/infection/ulceration.
- Do the eyes itch, are they swollen or crusty, or is there any discharge?
  - Ocular itching is more likely associated with allergies/history of atopy, while a mucopurulent discharge is associated with ocular infection. Reported itching, specifically along the lash line, warrants assessment for *Demodex*-related anterior blepharitis.<sup>105</sup>

• **3.2 RISK FACTORS:** Identifying risk/associated factors may help in establishing causes and pathophysiological mechanisms of DED, in determining subtypes, in confirming a differential diagnosis, in identifying comorbidities, and in explaining possible discordance between symptoms and signs (see Section 3.3.3). In addition, it may help in patient education, and many associated factors may be modifiable, offering the potential to improve symptoms and signs and to help prevent or slow progression of disease. In clinical practice, administering a questionnaire to the patient (such as via paper or a digital application) for completion before the consultation is recommended to save time and to ensure that all commonly associated factors have been addressed.

DED is a multifactorial and heterogeneous disease, and more than 200 associated factors have been described in the literature. Not all these factors necessarily play a causative role, and some associated factors are linked more strongly with symptoms, while others are linked with signs. [Figure 3](#)

shows consistent and probable associated factors of DED as described in the TFOS DEWS III Digest Epidemiology section.<sup>4</sup> The following section briefly highlights key risk/associated factors by category. Irrespective of a possible causal mechanism, all associated factors described may be useful in elucidating the etiology of DED and seeking to identify the possible disease driver(s) in an individual. [Table 1](#) presents frequently described risk factors that have inconclusive evidence (either directly conflicting information in peer-reviewed publications, or inconclusive information but with some basis for a biological rationale).

### • 3.3 SYMPTOMOLOGY:

#### 3.3.1 Routine questions based on variability of symptoms

Patients with DED often report sensations of grittiness and burning alongside dryness, while contact lens wearers frequently complain of dryness, along with sensations of scratchiness and watery eyes, increasing likelihood of failure for long-term successful wear.<sup>127-129</sup> Individuals diagnosed with DED present with variable symptom severity, ranging from mild to severe, throughout the day.<sup>39</sup> Dryness symptoms are typically worse upon waking than later in the morning, and tend to increase toward the end of the day in contact lens wearers.<sup>130-133</sup> Ocular allergies, exposure to air conditioning, and climatic factors that change between seasons may be associated with seasonal variations in symptoms and signs. However, a cross-sectional, retrospective cohort study in two Japanese clinics found that none of the symptoms examined (dryness, irritation, pain, fatigue, blurring, and photophobia) showed significant seasonal variation.<sup>134</sup> This was confirmed by another study, which failed to demonstrate seasonal or weather-related variation in the severity of presenting signs or symptoms of DED over a period of three years in 652 people in Oslo, Norway.<sup>135</sup> Hence seasonality of DED symptoms does not seem to warrant specific questioning beyond the differential diagnosis if the patient reports that the eyes generally itch. However, itching along the lash line, specifically, may indicate a *Demodex* blepharitis issue.<sup>105</sup>

#### 3.3.2 Standardized questionnaires

Around 25 questionnaires can be identified from a literature search using terms “dry eye” and “questionnaire” as well as by research articles cited in the identified publications. Each questionnaire warrants evaluation to assess its clinical relevance, known population validity, concurrent validity, internal consistency, and reproducibility.<sup>136, 137</sup> Additionally, unidimensional evaluation validity should be confirmed using Rasch analysis, and it should be confirmed whether “health-related quality of life” has been assessed.

Questionnaires such as the Ocular Surface Disease Index (OSDI), Impact of Dry Eye in Everyday Life (IDEEL), Dry Eye-Related Quality-Of-Life Score (DEQS), University of North Carolina Dry Eye Management Scale (UNC



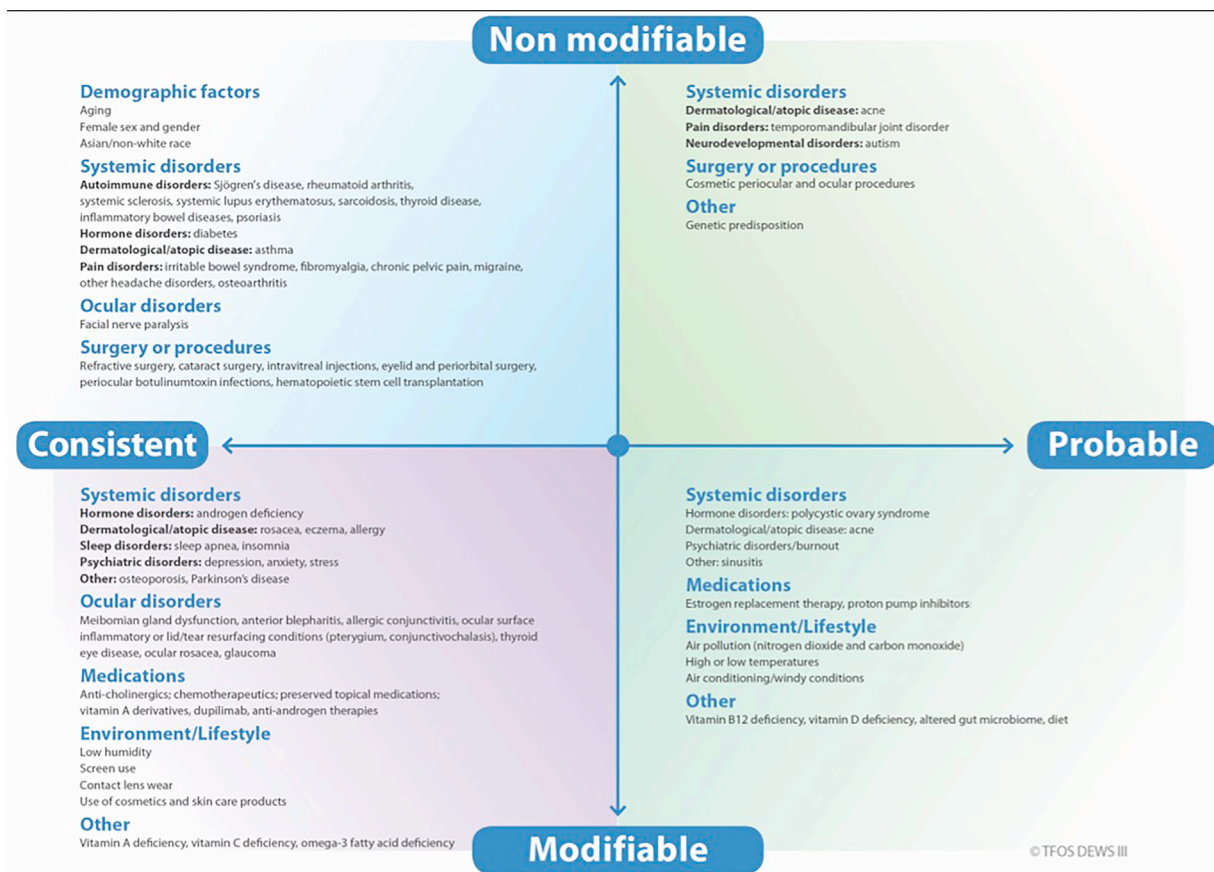


FIGURE 3. Consistent and probable associated factors of DED described in the TFOS DEWS III Digest Epidemiology section.<sup>4</sup>

TABLE 1. Frequently Described Risk Factors With Inconclusive Evidence<sup>a</sup>

- Smoking<sup>106-108</sup>
- Caffeine intake<sup>7,109-112</sup>
- Alcohol intake<sup>7,113,114</sup>
- Water intake<sup>7,115,116</sup>
- Food restriction<sup>7</sup>
- Mediterranean diet (possible positive effect)<sup>117-121</sup>
- Menopause<sup>122,123</sup>
- Air pollution from particulate matter of <10 µm<sup>6</sup>
- Oral contraceptives<sup>124-126</sup>

<sup>a</sup>Either directly conflicting information in peer-reviewed publications or inconclusive information but with some biological rationale.

DEMS), and the 25-Item National Eye Institute Visual Function Questionnaire (NEI VFQ-25) are validated to a greater or lesser extent in regard to their utility in assessing the impact of DED on health-related quality of life.<sup>137</sup> These questionnaires are not interchangeable, underscoring the necessity of recommending a single, comprehensive, standardized tool in establishing robust diagnostic criteria.<sup>137</sup> A diagnostic questionnaire should have a low response burden on the patient, be simple to score for the clin-

ician, and contribute to the assessment of severity and monitoring treatment efficacy. TFOS DEWS II recommended the use of either the OSDI or the 5-item Dry Eye Questionnaire (DEQ-5).<sup>138</sup> However, subsequent comparisons of the results from these questionnaires have shown poor comparability.<sup>139-141</sup>

The OSDI-6 was introduced in 2018 to reduce the response burden on patients. Researchers conducted a study that included Rasch analysis, to determine whether the ef-

	Constantly	Mostly	Often	Sometimes	Never
<b>Have you experienced any of the following during a typical day within the last month?</b>					
1. Eyes that are sensitive to light?	4	3	2	1	0
2. Vision blurring between blinks (with your refractive correction if needed)?	4	3	2	1	0
Symptoms and visual disturbance subscale ⇒					
<b>Have problems with your eyes limited you in performing any of the following during a typical day within the last month?</b>					
3. Driving or being driven at night?	4	3	2	1	0
4. Watching TV, or a similar task?	4	3	2	1	0
Visual function / tasks subscale ⇒					
<b>Have your eyes felt uncomfortable in any of the following situations during a typical day within the last month?</b>					
5. Windy conditions?	4	3	2	1	0
6. Places or areas with low humidity?	4	3	2	1	0
Environmental subscale ⇒					

FIGURE 4. Questions of the OSDI-6.<sup>146,147</sup> The diagnostic cut-off for dry eye is a summed score of  $\geq 4$ .

fectiveness of the 12-item OSDI questionnaire could be maintained with a shortened version (Figure 4). The questionnaire was further adapted such that questions would reflect a recall period of 1 month versus only 1 week in the original OSDI. The resulting abbreviated version, OSDI-6, comprising 6 questions, was found consistently to be more repeatable than either the full OSDI or DEQ-5.<sup>142</sup> Moreover, the scoring method, which involves simply summing the item scores and using a diagnostic cutoff of  $\geq 4$  to indicate symptoms of DED, allows for a quicker evaluation by clinicians.<sup>142</sup> It is possible that this abbreviated format might also be more suitable for children, who are known to better tolerate questionnaires that require less time and assistance to complete.<sup>143</sup> Similarly to the original OSDI, the OSDI-6 results can be indexed against severity, as normal (0-3 points), mild-to-moderate DED (4-8 points), or severe DED ( $>8$ ).<sup>144</sup> A Chinese translation of the OSDI-6 found it to be repeatable, valid, and psychometrically responsive to DED in a Chinese population.<sup>145</sup> The OSDI-6 thus yields outcomes comparable to those of the full OSDI, requires less time to complete and score, and maintains similar variability and improved sensitivity to treatment effects.<sup>146</sup> Consequently, the OSDI-6 merits consideration as a suitable screening questionnaire for DED diagnostic purposes, while other questionnaires may offer supplementary aid for risk factor identification and treatment selection, after confirming the initial diagnosis.

### 3.3.3 Discordance between signs and symptoms

It is well established that there is a poor correlation between symptoms and signs in DED. A systematic review including 33 population-based and cohort studies, with a total of 175 individual sign-symptoms associations, found the vast majority of correlations to range between  $+0.4$  and  $-0.4$ .<sup>148</sup> This means that dry eye signs generally ex-

plain only up to 15% of the variation in symptoms within a population.

There are numerous methodological, statistical, but also physiological reasons why the correlation between symptoms and signs in studies is low.

- First, measurement error is a common problem for many of the DED tests, and the order in which tests are performed, or the instillation of fluorescein, for example, can impact test findings.<sup>39</sup> Outcomes are often subjectively scored, not only for symptoms, but also for purportedly objective signs such as fluorescein break-up time, staining of the ocular surface, and MGD.
- Second, DED is recognized to be a dynamic disease, in which symptoms can fluctuate over time, and in which test outcomes may be affected by environmental factors, time of the day, and recent artificial tear use.<sup>39</sup> Furthermore, symptoms are often scored as an average over a defined period (such as “during the last week” in the OSDI), leading to differences in time period over which signs are measured and symptoms are scored.
- Third, DED is multifactorial, with potentially more than one etiology being identified in clinical practice.<sup>47,149</sup> Studies that include different subgroups of DED in one analysis risk a dramatic fall in correlation values, such as when patients with neuropathic pain are included in studies.<sup>150</sup> Indeed, when certain subgroups of patients with DED have been analyzed independently, higher correlations between symptoms and signs have been found.<sup>148</sup>
- Fourth, neurosensory abnormalities and inflammation of the ocular surface, which are considered two core mechanisms of dry eye, are not (directly) measured in common clinical dry eye tests. With time, changes in nerve status may effect changes in reported symptomology in DED. For example, a small study of patients with

Sjögren's disease found that, counterintuitively, those with advanced corneal staining reported fewer symptoms than patients with more mild corneal staining.<sup>151</sup> Increasing age can also lead to a reduction in corneal sensitivity.<sup>152,153</sup> A study in the United States found correlations between a number of tear film measures and symptoms scores on the DEQ-5 and OSDI to have coefficients all lower than  $r = 0.18$ , while symptoms were much more strongly correlated with nonocular pain, depression, and post-traumatic stress disorder scores.<sup>154</sup> A large single-center study in the Netherlands also found poor correlation between common dry eye signs and OSDI symptom scores (all  $r < 0.30$ ), and found correlations to be significantly lower in women than in men, indicating sex differences in symptom reporting in DED.<sup>150</sup> A wide variety of factors, including depression, stress, age, sex, and gender can affect symptomology scores.

- Fifth, other comorbid ocular surface diseases (that are often associated with DED) may also lead to symptoms (see Section 3.1), risking obscuration of true correlations between dry eye signs and symptoms in analyses.
- Sixth, signs of DED may not necessarily lead to symptoms. For example, MGD is a common finding in asymptomatic persons.<sup>155</sup>
- Seventh, treatment may alter the correlation between symptoms and signs, with certain treatments influencing one variable more than another.<sup>156</sup> Frequently, clinical trials show a positive effect of a DED treatment on symptoms only, but not signs, or vice versa.<sup>157-162</sup> In addition, some longer-duration trials have found signs to improve at a later stage than symptoms (for example, with artificial tears), or vice versa (with cyclosporine A).<sup>163,164</sup>
- Finally, despite the longitudinal nature of these clinical trials, there remains a lack of natural history studies that attempt to correlate dry eye signs and symptoms *within* the individual patient rather than *between* patients; there is therefore a need for *within*-patient correlation studies across different time points, where it might be expected that relationships between signs and symptoms may be stronger.

In recent years, several studies have explored predictors of discordance between symptoms and signs in DED. In a study in the Netherlands, 648 patients were ranked based on a composite dry eye signs' severity score, and also ranked according to symptoms using the OSDI score. Next, a risk factor association analysis was performed with the difference between these two rank scores being the dependent variable. Factors associated with a finding of symptoms exceeding signs were chronic pain syndromes, a history of atopic diseases, allergies, use of antihistamines, depression, the use of antidepressants, and osteoarthritis. Predictors of fewer symptoms than signs were increased age, Sjögren's disease, and graft-versus-host disease.<sup>165</sup> A similar study in the United States with 326 patients replicated many of these

factors, finding associations between increasing age and fewer reported symptoms, while mental health and chronic pain disorders were associated with more symptoms. In addition, the study found quantitative sensory testing scores that indicate hyperalgesia to be associated with more symptoms than signs.<sup>166</sup> A recent Taiwanese study with 1229 patients, using a similar approach, found female sex and a history of cataract, pterygium, and conjunctivochalasis surgery to be associated more with symptoms than with signs, and people of older age and those using artificial tears to be relatively less symptomatic than their signs might suggest.<sup>167</sup>

Other studies looking at discordance between signs and symptoms in DED have found corneal microneuroma-like structures and increased corneal dendritic cell density,<sup>168</sup> but also decreased corneal nerve density<sup>169</sup> and tear and conjunctival cytokines<sup>168, 170</sup> in patients in whom symptoms outweighed signs. Table 2 lists the factors across studies that were associated with symptoms outweighing signs, and conversely, those with significantly fewer symptoms than signs. These factors may help in understanding outcomes in clinical practice, may aid in patient education (such as in explaining about central sensitization mechanisms or altered nerve status after surgery), and may offer clues for differential diagnoses and comorbid disorders (for example, atopy and allergic conjunctivitis) in patients with DED exhibiting discordance between signs and symptoms. The findings also emphasize the need for clinicians not to rely solely on symptom reporting in older patients, or those with Sjögren's disease or graft-versus-host disease, as symptoms may be understated in relation to the severity of effects on the ocular surface.

### 3.3.4 Pediatric considerations

While DED is common in children<sup>176</sup> (see TFOS DEWS III Digest Epidemiology section<sup>4</sup>), diagnostic tests have largely been validated only in adults. One study examined the quantification of dry eye symptoms in children (6-15 years of age) using standardized questionnaires, identifying that the completion time was  $\leq 2$  minutes for each individual questionnaire and that while younger participants took longer to complete and required more assistance, especially with longer visual analog scales, repeatability was noted to remain high across this age range.<sup>177</sup>

## • 3.4 OCULAR EXAMINATION:

### 3.4.1 Diagnostic homeostasis test battery

3.4.1.1 *What is a diagnosis?*. As previously described, the ability to receive a diagnosis is critical for patients to acknowledge their symptoms and/or signs as real and that they have the attention of health care practitioners, as well as being required for healthcare insurance coverage where available. For practitioners, diagnostic criteria inform which evidence-based clinical practice guidelines to follow, and provide confidence in making patient diagnoses that are consistent with those of their peers. A standardized

**TABLE 2.** Factors Associated With a Discordance Between Symptoms and Signs in Dry Eye Disease

Predictors of More Symptoms Than Signs	Predictors of Fewer Symptoms Than Signs
<b>Demographics</b>	
Female sex <sup>150, 167</sup>	Older age <sup>165, 167, 171</sup>
Black race <sup>166</sup>	
<b>Pathophysiological Factors</b>	
Tear and conjunctival cytokines (IL-10, IL-2, IL-6, IL-17a, TNF- $\alpha$ ) <sup>168, 170</sup>	Decreased corneal nerve density <sup>169</sup>
Increased corneal dendritic cell density <sup>168</sup>	
Hyperalgesia confirmed by quantitative sensory testing <sup>166</sup>	
Nonocular pain intensity <sup>166</sup>	
<b>Comorbidity Factors</b>	
Post-traumatic stress disorder <sup>166</sup>	Sjögren's disease <sup>165, 172</sup>
Allergy <sup>165</sup>	Graft-versus-host disease <sup>165</sup>
Atopic disorders <sup>165</sup>	Benign prostatic hyperplasia <sup>166</sup>
Osteoarthritis <sup>165</sup>	Hypertension <sup>166</sup>
Depression <sup>165, 166</sup>	
Anxiety <sup>166</sup>	
Chronic pain syndromes <sup>165, 166, 173-175</sup>	
<b>Pharmaceuticals</b>	
Use of analgesics <sup>166</sup>	Use of artificial tears <sup>167</sup>
Use of anxiolytics <sup>166</sup>	
Use of antidepressants <sup>165, 166</sup>	
Use of antihistamines <sup>165</sup>	
<b>Lifestyle Choices</b>	
Current smoking <sup>166</sup>	
<b>Surgery</b>	
Cataract surgery <sup>167</sup>	
Pterygium surgery <sup>167</sup>	
Conjunctivochalasis surgery <sup>167</sup>	

diagnosis is essential for industry and researchers to be able to target and validate the efficacy and safety of new products and to obtain regulatory approvals. Appropriate health resource allocation requires robust epidemiological and economic data that are based on consistent diagnoses. Hence diagnosis of a disease must be characterized by standardized, universally adopted criteria, based on widely available and inexpensive tests with validated cut-off values. There are advantages in having a simple screening element that can rapidly identify those individuals who would benefit from further testing by a healthcare practitioner.

**3.4.1.2 Need for standardization.** The definition of DED (see Section 2.1) dictates that symptoms must be present, and a loss of homeostasis of the tear film and/or ocular surface must be established. Identifying that the expected symptoms are present in a standardized way requires a validated questionnaire, as discussed in Section 3.3.2. While TFOS DEWS II recommended two possible questionnaires that could be used, these questionnaires have since been shown not to be equivalent, risking variability in diagnosis depending on the instrument chosen, so it is appropriate to select a single questionnaire to be used in this setting. Based on evidence published since TFOS DEWS II, this has been identified as the OSDI-6 with a summed cut-

off score of  $\geq 4$  to be positive for dry eye symptoms (see Section 3.3.2).

**3.4.1.3 Other approaches since TFOS DEWS II.** The Asian Dry Eye Society,<sup>178,179</sup> supported by the Japanese Dry Eye Society,<sup>180</sup> suggested that DED should be diagnosed by confirming the presence of ocular symptoms (using any one of 4 possible questionnaires) along with identification of an unstable tear film (assessed with fluorescein tear breakup time of  $< 5$  seconds). This approach shows similarities to TFOS DEWS II, but lacks the standardization that can be offered by a single questionnaire as proposed by TFOS DEWS III. Furthermore, changing the chemical composition and volume of the tear film by instilling fluorescein prior to assessment of its stability is not ideal. The Korean Dry Eye Society defined dry eye as “a disease of the ocular surface characterized by tear film abnormalities and ocular symptoms” without referring to the pathophysiology or specifying the means by which to diagnose ocular symptoms (no questionnaire proposed). The diagnostic criteria included an unstable tear film in the form of fluorescein breakup time  $< 7$  seconds (a test that is invasive in itself, and recommended without scientific justification for the cut-off), with a Schirmer test ( $< 10$  mm) and ocular surface staining considered “adjunctive criteria.”<sup>181</sup>



It has been suggested that diagnostic certainty (in the form of sensitivity and specificity) can be increased by requiring multiple discriminatory tests to be positive,<sup>182</sup> leading to the recommendation that both corneal and conjunctival staining needed to be present to match a Bayesian-informed global prevalence of DED.<sup>183</sup> However, the reported global prevalence used had been generated from existing studies that relied on these various diagnostic criteria, which introduces bias into the approach. Furthermore, using the sensitivity and specificity of tests from multiple studies is also susceptible to bias,<sup>184</sup> as previously identified in the TFOS DEWS II report.<sup>1</sup> There is increasing chance of misdiagnosing or underdiagnosing a disease if standardized diagnostic criteria are not used, because it can require excessive time, consumables costs, or equipment that is expensive or has limited availability. Corneal staining often occurs in later and in more severe stages of DED, so while requiring its presence will increase diagnostic specificity, it will exclude appropriate treatment for many individuals whom clinicians recognize to have a marked loss of quality of life as a result of their symptomatic ocular surface disease and would currently be identified as having DED.<sup>185</sup>

Attempts have been made to use dry eye tests to differentiate diseases that affect the ocular surface such as Sjögren's disease, graft-versus-host-disease, Graves orbitopathy, facial nerve palsy, nonproliferative diabetes mellitus, and glaucoma treated with preserved topical drops, with mixed results.<sup>186-188</sup>

**3.4.1.4 Use of sensitivity and specificity to select diagnostic tests.** Without there being a recognized gold standard, and due to the well-established low correlation between signs and symptoms in DED,<sup>189-191</sup> the level of certainty in derived sensitivity and specificity values of new DED "diagnostic" tests is low. Sensitivity and specificity depend on the inclusion and exclusion criteria for the "healthy" and "disease" groups, increasing with the severity of signs or symptoms required to be allocated to the DED group (spectrum bias). Individuals who do not meet the criteria of either group prevent generalizability of the results across the broad population (sampling bias). Selection bias occurs when the patient groups are selected with test(s) with a similar focus to the test being evaluated.<sup>192</sup> Parallel testing (requiring multiple tests to be positive) will increase the sensitivity and specificity of differentiating a selected "healthy" and "disease" group, but this approach is just as susceptible to the bias in group selection. Detailed discussion and examples of these issues are reported in the TFOS DEWS II Diagnostic Methodology report.<sup>1</sup>

**3.4.1.5 Tests to establish a loss of homeostasis of the tear film.** While the diagnostic or screening potential of tests such as thermography,<sup>193-195</sup> interferometry,<sup>196</sup> lipid layer pattern/thickness,<sup>197</sup> and tear evaporation rate<sup>198</sup> have been evaluated, they are not widely used in clinical or research settings. Artificial intelligence deep learning has been used

to show that multiple factors including age, ocular surface staining, and symptoms are the most important predictors of an unstable tear film, followed by meibomian gland dropout and expressibility, blink frequency, osmolarity, and meibum quality,<sup>199</sup> but it would not be practical to assess all of these in making a diagnosis of DED.

Tear film stability, as usually assessed by the tear film breakup time, is defined as the measured time interval between a blink and the appearance of the first discontinuity in the tear film.<sup>200,201</sup> While it is commonly assessed by instilling fluorescein, illuminating the ocular surface with blue light and observing the fluorescence through a yellow filter,<sup>202</sup> the application of fluorescein itself reduces the stability of the tear film and increases its volume so the tear film generally breaks up much more quickly<sup>203-205</sup> and the measurement may not be an accurate reflection of the natural tear film status.<sup>206-208</sup> Fluorescein breakup time is also limited as a measure of tear film stability due to the requirement for subjective assessment by the observer; and, while an attempt has been reported to automate this measurement,<sup>209</sup> the required equipment is not available in clinical settings. Instead of the time taken for the first break in the tear film to be detected, a metric to describe overall disruption in tear film surface quality (assessed from a Placido disc reflection) has been used to assess tear film instability,<sup>210-212</sup> but this has not been widely adopted. Non-invasive objective assessment, usually with a Placido disc reflected from the tear film surface, determines the time until the first detected break as well as mapping the locations of the tear film disruption and the velocity of the destabilized area. Clinically insignificant differences occur between the objective measurements by many automated devices to measure non-invasive breakup<sup>213,214</sup> but not all.<sup>215-217</sup> The detection algorithm results can be adjusted in the validation stage of new instruments (such as adjusting the threshold of discontinuity in the mires) to benchmark more closely to existing devices as there is no "gold standard." Controlling environmental factors such as temperature, humidity, and air circulation during and immediately before the measurement is important, as well as instructing the patient to blink naturally several times and then to cease blinking until instructed to blink again.<sup>218</sup> The Ocular Protection Index is the ratio of the tear film breakup time divided by the blink interval; however, as with other signs of a loss of homeostasis of the tear film and/or ocular surface, levels deemed "pathological" are poorly associated with patient-reported DED symptoms.<sup>219</sup>

Increased osmolarity of the tear film occurs within the pathophysiology of dry eye<sup>4</sup> with estimated localized levels up to around 900 mOsm/kg predicted across the ocular surface at points of tear film destabilization.<sup>220</sup> Point-of-care devices that measure osmolality are currently limited to sampling from the tear meniscus, as the volume of tears is too small to sample from the ocular surface. Osmolarity has also been reported to differ according to the location along the lid margin from which it is sampled.<sup>221</sup> While some

studies have advocated for its diagnostic role,<sup>222,223</sup> other studies have suggested that current instrumentation yields results that are not repeatable from a single *in vivo* measurement<sup>224</sup> and that values vary with the device used.<sup>225</sup> Tear meniscus osmolarity may account for <5% of the variability in other tear film and ocular surface homeostasis signs<sup>226</sup> and is therefore unreliable in identifying individuals in whom DED is diagnosed<sup>227</sup> or the DED severity is determined<sup>228</sup> with other dry eye metrics. The daily variation of osmolarity has been suggested to be a better marker of DED,<sup>229</sup> but this is impractical for diagnostic purposes in a clinical setting. Tear osmolarity was able to predict poor surgical outcomes and patient dissatisfaction in a cataract surgery population with mild ocular surface disease, again suggesting that it provides additional information to tear stability and ocular surface damage<sup>230</sup> and hence is an important metric in diagnosing DED.<sup>4</sup> The inclusion of osmolarity among the possible signs of a loss of homeostasis of the tear film in the TFOS DEWS II diagnostic algorithm made less than 5% difference to the prevalence of DED.<sup>231,232</sup> Similarly to osmolarity, tear composition alters where there is loss of homeostasis of the tear film, but not in a measurably consistent manner, and the value of current point-of-care tests for other tear film biomarkers is limited (see Section 3.5.4.4.2).<sup>233</sup>

**3.4.1.6 Tests to establish a loss of ocular surface homeostasis.** Loss of homeostasis of the ocular surface is most widely established by topically applying ophthalmic dyes such as fluorescein and lissamine green, and the resulting staining of the tissues is considered to be a diagnostic sign of DED.<sup>234-236</sup> Staining is one of the clinical signs most strongly associated with dryness symptoms in moderate-to-severe DED.<sup>150,237</sup> Punctate staining, albeit not pathognomonic of DED, is commonly associated with desiccation stress, particularly when present in the inferior quadrant of the cornea.<sup>238,239</sup> Fluorescein staining occurs due to a loss of corneal epithelial cell integrity such as a disruption in superficial cell tight junctions or defective glycocalyx.<sup>238,240</sup> Lissamine green has largely replaced the use of rose Bengal, as it is less toxic to the ocular surface,<sup>241</sup> and stains epithelial cells if the cell membrane is damaged, irrespective of the presence of mucin.<sup>238,242-244</sup> Staining of the eyelid margin conjunctiva that wipes the ocular surface during blinking (termed lid wiper epitheliopathy), possibly due to mechanical stress resulting from insufficient lubrication,<sup>245</sup> is common in patients with DED and is associated with poor lipid spread, poor tear film stability, abnormal lid anatomy, and blink speed.<sup>246,247</sup> It is also an earlier diagnostic sign than corneal and conjunctival staining in the natural history of DED pathophysiology.<sup>248-250</sup> A clinically detectable poor seal between the eyelids has also been identified as a factor associated with symptoms of ocular surface discomfort.<sup>251</sup>

The diagnostic potential of point-of-care inflammation testing (MMP-9) has been reviewed, but while inflamma-

tion was associated with severe DED, it was not sensitive to more mild-to-moderate DED, which is more common in the general population.<sup>252</sup> Several studies have investigated the potential for epithelial thickness to serve as a diagnostic test for DED; while the central epithelial thickness has largely been found to be similar in individuals with DED compared to healthy controls, the epithelium of the superior cornea is generally thinner, especially in more severe disease<sup>253,254</sup>; however, this finding is not consistent.<sup>255,256</sup>

Squamous metaplasia and goblet cell density of the conjunctiva can be assessed using impression cytology and, as goblet cell density reduces in patients with dry eye, it has been suggested as a DED diagnostic technique.<sup>257,258</sup> Impression cytology removes cells from the 3 most superficial layers of the epithelium, typically by applying cellulose acetate filters or biopore membranes; the cells can then be analyzed by techniques such as microscopy, flow cytometry, immunoblotting analysis, immunocytochemistry, and polymerase chain reaction to meet the aims of the investigation.<sup>259</sup> It is a useful alternative to a biopsy, but the changes observed are not pathognomonic of DED.<sup>260,261</sup>

**3.4.1.7 Practical diagnostic criteria considerations.** Sections 3.4.1.5 and 3.4.1.6 highlight that the key tests to assess the homeostatic status of the tear film remain unchanged from those derived in TFOS DEWS II. The key homeostatic markers are thus non-invasive tear film breakup time, osmolarity, and ocular surface staining. The sequence of diagnostic assessment can affect the results, as restricting blinking and viewing with bright lights can stimulate reflex tearing. It is therefore recommended that tear film assessment tests be carefully ordered, from the least to the most invasive.<sup>262</sup>

The OSDI-6 is a short questionnaire, ideal for screening, and is recommended to be conducted as the first component within routine eye examinations to identify those patients who would benefit from a fuller diagnostic evaluation to determine the likely drivers of disease.

As identified in Section 3.4.1, it is critical that diagnosis follow a standard protocol. While combining more tests can improve sensitivity, this may be at the expense of clinical utility.

TFOS DEWS II recommended that a minimum of one of 3 signs of a loss of homeostasis needs to be present to confirm a diagnosis of DED:

- Non-invasive breakup time (first break) <10 seconds: as highlighted in Section 3.4.1.5, this test establishes a loss of homeostasis of the tear film. There are now a range of affordable instruments available to the practitioner to avoid the adverse impacts of fluorescein dye on the robustness of the test result, as is well documented (see Section 3.4.1.5). Where there is no access to such a device to allow non-invasive measurement of breakup time, fluorescein can be applied, but the volume instilled should be minimized and a cut-off of <5 seconds applied as a positive sign of instability.<sup>204,205</sup>

- Osmolarity  $\geq 308$  mOsm/L in either eye or an interocular difference  $> 8$  mOsm/L (cut-offs established with the TearLab device only). This test serves as a marker of loss of homeostasis for both the tear film and ocular surface (see Section 3.4.1.5). Consideration of the inter-eye difference alone was found to be valid in one study<sup>263</sup> but not in another (at least in relating to dryness symptoms),<sup>264</sup> and interocular osmolarity was found to have modest but superior discriminative ability over absolute osmolarity (higher value of the 2 eyes).<sup>265</sup>
- Ocular surface staining of  $> 5$  corneal or  $> 9$  conjunctival punctate spots or lid margin staining of  $\geq 2$  mm length and  $\geq 25\%$  width following the instillation of both fluorescein and lissamine green dyes.<sup>238,266</sup> It is more common to observe corneal and conjunctival staining in severe DED (see Section 3.5.4.3)

*Corneal staining observation:* The corneal surface, following the instillation of fluorescein drops or the application of a moistened fluorescein strip, is best observed using a blue light of 495 nm, as this is the peak excitation wavelength for fluorescein (rather than the 450 nm “cobalt blue” peak of light filters historically used in slitlamp biomicroscopes).<sup>202</sup> An observation filter with a band pass at 500 nm enhances observation, by limiting visibility to the wavelength of the excited fluorescence molecules (emittance  $\sim 515$  nm) while excluding those from the applied blue light.<sup>202</sup> Consensus on the ideal time after instillation for staining assessment is 1 to 4 minutes.<sup>238,262,267</sup>

*Conjunctival and lid margin staining observation:* Lissamine green staining is critical for observation of conjunctival and lid margin staining assessment. A lissamine green strip (noting that not all brands are equivalent)<sup>268,269</sup> should be moistened with sterile saline, with the whole drop applied to the eye after having been placed on the strip for at least 5 seconds to allow the dye to be eluted for maximal concentration.<sup>269,270</sup> The staining should be observed between 1 and 5 minutes post instillation of lissamine green,<sup>269-271</sup> potentially through a red filter to aid visualization.<sup>241,272</sup> Everting the eyelids multiple times should be avoided, as this can stress the tissues and affect the degree of staining observed, whereas exposure time seems to be less impactful on the outcomes.<sup>273</sup> Assessment of lid wiper staining generally involves subjective estimation of the length and sagittal depth of staining, but may be optimized using semi-objective imaging techniques.<sup>274</sup>

*Grading:* It should be noted that if using a grading scheme such as the Oxford Grading System, applying half unit increments improves sensitivity and repeatability, while summing regional grading does not give a score comparable to that of global ocular surface staining and increases variability.<sup>275</sup> For diagnosis, counting punctate spots should result in higher consistency. Despite claims that objective assessment of corneal staining can be used as a highly successful automated dry eye diagnostic system,<sup>276</sup> a review of objective techniques suggest that this still has limited reliability.<sup>275</sup> While there are challenges to grading staining of

the lid margin,<sup>277</sup> a diagnostic criterion of 2 mm or greater length over at least 25% of the sagittal lid width still seems appropriate.

A study found that a substantial proportion of patients “diagnosed” with DED by a consultant ophthalmologist without following any set criteria reported symptoms and exhibited hyperosmolarity, but no other obvious signs of DED; however, tear film stability was assessed invasively, and staining of only the cornea (not bulbar or lid margin conjunctiva) was included.<sup>191</sup>

In a population study in the United Kingdom, among the TFOS DEWS II diagnostic signs for DED, conjunctival staining (with lissamine green dye) occurred in most people diagnosed with DED, followed by reduced non-invasive tear breakup time, lower or upper lid wiper epitheliopathy staining, corneal staining, and signs of tear hyperosmolarity.<sup>231</sup> The prevalence of DED was notably consistent if any one of the 3 markers indicating a loss of homeostasis was omitted from the TFOS DEWS II diagnostic algorithm, indicating its robustness.<sup>231</sup> In a larger study,<sup>232</sup> it was found that evaluating just one of the 3 TFOS DEWS II homeostatic signs resulted in between 12.3% and 36.2% of patients who would otherwise have met the DED diagnostic criteria not being assigned this diagnosis; hence at least two signs need to be assessed to exclude a diagnosis of dry eye, even although only one needs to be positive. While comprehensive ocular surface staining evaluation in combination with symptoms had the highest sensitivity (87.7%) of the 3 markers, the sensitivity dropped to 44.6% if corneal staining only was evaluated; hence conjunctival and lid margin staining assessment (with lissamine green) is critical to diagnosing DED.<sup>182,232</sup> Omitting either non-invasive tear breakup time or osmolarity each dropped the sensitivity by less than 5%. The prevalence of DED within the population was substantially reduced if diagnosis required symptoms plus two of the three signs to be positive (by between 43.7% and 61.2%) and by 65.9% if all 3 signs indicating a loss of tear film homeostasis were required.<sup>232</sup> The outcomes of this analysis did not change significantly across differing severities of DED symptoms, confirming the robustness of the DED diagnostic approach (Figure 5).

### 3.4.2 Advanced screening

Diagnosing and monitoring DED often relies on specialized equipment (such as a slitlamp biomicroscope) and dyes, which are not readily available in non-eyecare setting. A non-invasive and simplified test for DED could enable earlier diagnosis and intervention to help prevent disease onset or exacerbations.<sup>278</sup> Additionally, improved accessibility of DED screening could raise public awareness and encourage high-risk or undiagnosed individuals to seek attention by an eyecare practitioner.

Blinking is a natural process that refreshes the tear film, removes ocular surface debris, and maintains vision quality.<sup>279</sup> Altered blinking physiology is a common feature in DED and is implicated in its pathogenesis.<sup>280-282</sup> As such,

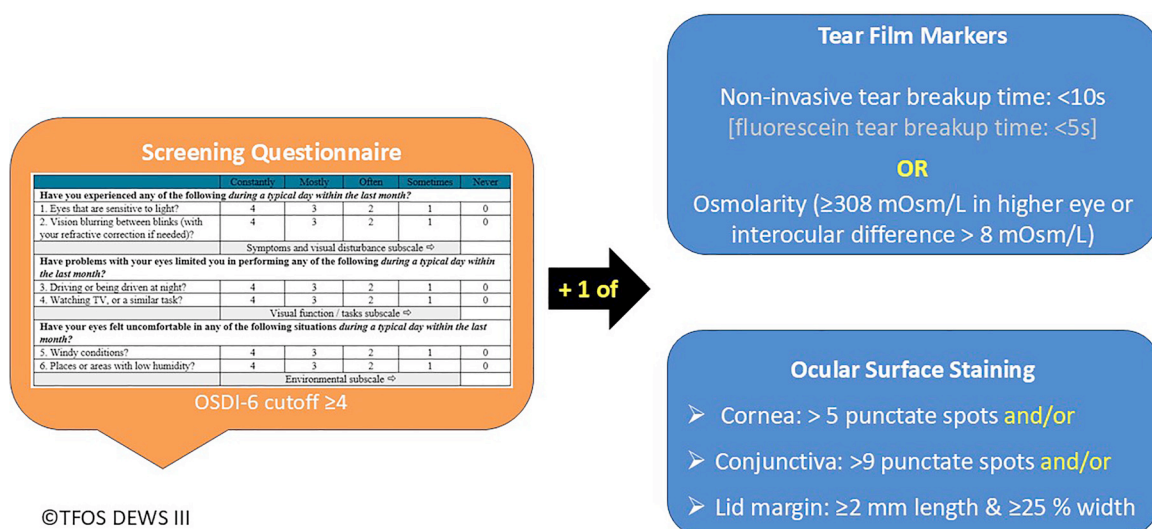


FIGURE 5. TFOS DEWS III diagnostic algorithm.

DED-associated blinking patterns could potentially serve as a non-invasive biomarker. Blink rate, interblink interval, and maximum blink interval (defined as the length of time that the participants can comfortably keep the eye open before blinking) have been reported to be useful in distinguishing between healthy participants and patients with DED.<sup>283-288</sup>

Maximum blink interval (cut-off 12.4 seconds) has demonstrated a sensitivity of 82.5% and specificity of 51.0% for a DED diagnosis based on OSDI symptoms and fluorescein tear breakup time).<sup>289</sup> A smartphone application has been tested,<sup>278,287,290,291</sup> showing comparable results with conventional paper-based OSDI and subjectively observed maximum blink interval.<sup>292,293</sup> The app-based maximum blink interval had an area under the curve of 0.649, with a cut-off of 10.5 seconds on a digital device with an iOS, but a much shorter 7.0 seconds on an Android operating system (compared to 12.4 seconds subjectively assessed) for a symptom (perhaps due to differences in refresh rate and software algorithms) and fluorescein breakup time DED-based diagnosis.<sup>294</sup> Similarly, the interblink interval, with a cut-off of 3.1 seconds, has shown an approximately 80% sensitivity and 70% specificity for a DED diagnosis based on general symptoms and corneal staining.<sup>283</sup> Furthermore, patients with DED are reported to have higher blinking rates,<sup>295</sup> with a greater proportion of incomplete blinks.<sup>296</sup> By analyzing such blinking characteristics, clinicians may be able to gain valuable insights into a patient's ocular surface status.

As maximum blink interval is dependent on an individual's tolerance to eye pain, an alternative approach is to ask an individual to report when their eyes become uncomfortable after a blink while keeping their eyes open, which demonstrated a sensitivity of 66%, a specificity of 88%, and an area under the curve of 0.77 (cut-off 10 seconds) com-

pared to a full TFOS DEWS II diagnosis of DED, improving to 71%, 90%, and 0.81, respectively, when considered in combination with the OSDI score.<sup>288</sup>

### 3.4.3 Severity rating

The severity of a disease is rated for a diverse range of purposes, but primarily for evaluation and communication<sup>297</sup>:

- To predict prognosis
- To characterize the impact of the disease on the person's well-being at a given point in time
- To establish the basis for treatment decisions
- To evaluate disease activity and monitor response to treatment.

Some classifications are based on pathological or physiological status, while others have used impairments or specific symptoms (such as pain), and still others have characterized severity based on exercise tolerance or functional status.<sup>297</sup> Symptoms and outcomes tend to be used in systems that are designed to reflect the patient experience. Pathological or physiological measures have been incorporated in systems used to predict prognosis, and both tend to be used to guide treatment or to measure response to treatment.<sup>297</sup> Some severity classification systems also take into account the presence of other conditions, diseases, demographics, or behaviors in their staging, if these are considered risk factors for a poorer prognosis.<sup>297</sup>

In other eye diseases, severity ratings vary from those based on the risk of advanced disease progression (for example, in age-related macular degeneration<sup>298</sup>) to those variably combining signs and symptoms that align with clinician consensus (for example, in keratoconus<sup>299-301</sup>). The former approach requires a large sample of natural history data<sup>302</sup> and the latter, a reasonably high association be-



tween subjective and objective clinical metrics,<sup>303</sup> neither of which are currently available for DED.

Severity grading in DED has been based on factors such as inflammatory cytokine concentrations,<sup>304</sup> corneal fluorescein staining scores,<sup>305</sup> and doctor (clinical judgment) rating.<sup>306</sup> The ODISSEY group proposed a severity rating based on the expert opinion of 10 ophthalmologists<sup>307</sup> in which the DED diagnosis relied on poor tear stability alone, and severe dry eye was considered to be present in those with an OSDI score  $\geq 33$  and corneal fluorescein staining grade  $\geq 3$  on the Oxford Grading System scale or with additional criteria if there was less staining. An objective composite index of disease severity has been proposed using an independent component analysis approach.<sup>308</sup> However, key non-invasive tests of the tear film and ocular surface were missing, such as non-invasive tear breakup time, interferometry, tear meniscus height, and lid wiper epitheliopathy and the cut-off for each test's severity grade was based on an "expert panel" of 5. The amount of independent information provided by each test (eigenvalue) was used as its weighting for each component's contribution to a composite score, which was based on the sum of the squared measures, divided by the square root of the sum of the weighting coefficients. A survey approach involving 37 corneal specialists in a hospital setting of unknown location (not representative of dry eye practitioners in general) identified clinical tests and cut-offs that they believed represented a diagnosis and reflected severity (mild, moderate, severe, and very severe) of DED<sup>309</sup>; seven tests were identified, and overall severity was based on an algorithm of combined scores with equal weighting (identified as a limitation), which was based on undefined clinician ratings of 50 patients. A recent study suggested that observing corneal cell morphology and density with *in vivo* confocal microscopy in areas that stain with fluorescein and lissamine green dyes may be a reliable basis for clinical grading of DED severity; however, the cohort of 24 participants was classified into severity grades based on the Chinese Cornea Society criteria, which also involved staining, as well as fluorescein tear breakup time, so the observation was unsurprising.<sup>310</sup>

A recent review of how to "best diagnose severity levels of DED" erroneously described "asymptomatic DED", only mentioned non-invasive tear breakup time as a form of interferometry, and concluded, without proposing a clinical algorithm, that the evaluation of severity of the condition has often been difficult.<sup>311</sup> While the original TFOS DEWS report proposed a severity matrix<sup>312</sup> based on a prior Delphi panel of 17 DED specialists,<sup>313</sup> this was not adopted by TFOS DEWS II (2017) due to the limited association between the characteristics included and the lack of evidence for the tests included to inform their weighting in a composite algorithm. Likewise, the Asian Dry Eye Society did not propose a severity algorithm for DED.<sup>179</sup> The Korean Dry Eye Society proposed a severity matrix, but without scientific justification for the proposed tests and the severity lev-

els provided.<sup>181</sup> The revised American Academy of Ophthalmology Preferred Practice Pattern guidance<sup>314</sup> mentions the role of DED severity in informing management, but without guidance on how to rate severity. In a recent survey in the United Kingdom, patients with DED rated symptom frequency and severity along with tear film stability as the most desired aspects of their DED to improve with treatment, although other factors such as ocular surface, corneal nerve, and tear gland damage followed by tear volume and constituents were rated as only slightly less important.<sup>315</sup>

### • 3.5 SUBCLASSIFICATION TO IDENTIFY DED ETIOLOGICAL DRIVERS:

#### 3.5.1 Purpose of a DED subclassification

Diagnostic subcategories (for diseases and most syndromes) are simply concepts. Their purpose is to segregate multifactorial aspects to allow a better characterization of patient outcomes and to guide decision-making regarding treatment.<sup>316</sup> TFOS DEWS and DEWS II confirmed the importance of subclassifying DED into aqueous deficient or evaporative forms, or a combination of the two.<sup>2, 312</sup> However, several studies have confirmed that at least two-thirds of individuals with DED exhibit the evaporative form,<sup>317-321</sup> which is recognized to have a number of etiologies including those that are lid-related and ocular surface-related,<sup>322</sup> which, without distinction, limits the ability to target treatment to the appropriate etiology. The selection of tests used to differentiate evaporative from aqueous-deficient forms of DED varies among studies, and a Delphi panel approach has attempted to establish agreement.<sup>323</sup> In addition, it has been noted that between 18% and 29% of individuals have no obvious signs of either a reduction in tear volume or disruption to meibomian gland structure and function, suggesting the need to acknowledge other subtypes of the disease.<sup>191,319-321,324</sup> DED is accepted to be a multifactorial disease,<sup>2,20</sup> so addressing the different mechanisms leading to an individual's DED could impact treatment outcomes. Disease heterogeneity will reflect differences in the underlying pathophysiology, genetic risk, and environmental contributors of affected individuals.<sup>325</sup> Clinical tests that identify the possible drivers of an individual's disease (which are not mutually exclusive), in turn, inform the appropriate treatment approach(es).<sup>326</sup> The Asian Dry Eye Society<sup>179</sup> proposed 4 targets for therapy (lipid, aqueous and mucin layers along with ocular surface inflammation), but with a target of the epithelium consisting of membrane-associated mucins and epithelial (goblet) cells. Expanding on this approach, the following section outlines those clinical tests that inform the clinician about the contribution to DED from the following:

#### 3.5.2 Tear Film Deficiencies

The latest understanding on the tear film is reported in the TFOS DEWS III Digest.<sup>4</sup> It has been proposed that differ-

ences observed in the fluorescein tear breakup patterns can inform the clinician about which tear film layer has been disrupted. Area break is thought to be associated with severe aqueous-deficient DED; spot, dimple, and line breaks with rapid expansion are associated with decreased wettability DED, with a line break thought to be associated with mild-to-moderate aqueous-deficient DED; and a random break appearance, associated with increased evaporation DED.<sup>327-329</sup> However, to date, there has been only limited published evidence to support these hypotheses.<sup>329</sup>

### 3.5.2.1 Lipid component.

**3.5.2.1.1 Interferometry.** Tear interferometry allows the tear film lipid layer thickness to be estimated non-invasively.<sup>330,331</sup> Due to the nature of the thin lipid layer overlying a body of aqueous of a different refractive index, reflections from the air-lipid and the lipid-aqueous interfaces create interference patterns, which can be analyzed quantitatively or semi-quantitatively.<sup>332</sup> Lipid layer interference pattern grades correlate with corneal staining and tear film breakup time.<sup>333</sup> Lipid layer thickness should be increased in hypersecretory MGD and decreased in obstructive meibomian MGD, but a direct association between the thickness of the lipid layer and the rate of tear evaporation has not been proven.<sup>334,335</sup> There are various non-invasive diagnostic devices for assessing the tear film lipid layer.<sup>336-342</sup> Some devices attach to a slitlamp biomicroscope base, while others are stand-alone instruments. Most require subjective grading of the lipid pattern,<sup>343</sup> which equates the pattern observed with an estimated thickness.<sup>337</sup> A dynamic lipid layer interference pattern test has been proposed, reporting the optimal number of blinks to observe a significant change in lipid pattern as being up to five forced blinks, followed by 10 natural blinks at two-second intervals; in patients with DED, the number of blinks required to change the lipid pattern by one grade ( $2.4 \pm 3.1$  blinks) was statistically lower than in healthy subjects ( $18.1 \pm 5.9$  blinks).<sup>344</sup> The LipiView interferometer has a sensitivity of around 68% and a specificity of 64% if a cut-off value of 75 nm is used for MGD diagnosis<sup>332,345</sup>; the coefficient of variability for interobserver repeatability was 13 nm and the intraobserver repeatability, 16 nm in healthy individuals, with values of <60 nm considered pathological.<sup>346</sup> In a study of 221 participants, optimal diagnostic cut-offs for DED based on the TFOS DEWS II criteria were <72 nm with the LipiView and a grade of  $\leq 3$  subjectively, based on interferometric patterns (modified Guillon scale).<sup>197</sup> Lipid layer thickness values obtained with the LipiView instrument have been reported to correlate well with meibomian gland loss.<sup>347</sup> Another technique, using a spectrophotometer, claims an ability to directly image tear muco-aqueous and lipid layer thicknesses *in vivo* with nanometer axial resolution.<sup>348,349</sup>

**3.5.2.1.2 Lipid turnover.** The turnover of the lipids of the tears assessed by fluorophotometry ( $0.9\% \pm 0.4\%$  per minute) is slower than the aqueous turnover ( $10.3\%$

$\pm 3.7\%$  per minute).<sup>350</sup> Contrast-enhanced optical coherence tomography (OCT) imaging has also been used to evaluate the clearance of lipids in human tears.<sup>351</sup> A system that combines simultaneous OCT and thickness-dependent fringes interferometry can be used for *in vivo* assessment, simultaneously imaging both the lipid layer thickness and overall tear film thickness.<sup>352,353</sup> The analysis of the OCT's *en face* maps of the tear lipid layer provides complementary information to interferometry.<sup>354</sup> The previously mentioned spectrophotometer technique (Tear Film Imager) allows real-time evaluation of the rate of lipid thickness change and discontinuities over a large field of view.<sup>330</sup> The muco-aqueous thickness correlates with the Schirmer test score and lipid or fluorescein tear breakup time.<sup>349</sup>

**3.5.2.1.3 Evaporimetry.** A meta-analysis of studies measuring evaporation found raised levels in patients with DED, particularly evaporative DED (normal,  $13.57 \pm 6.52 \times 10^{-7}$  g/cm<sup>2</sup>/s; aqueous deficient dry eye,  $17.91 \pm 10.49 \times 10^{-7}$  g/cm<sup>2</sup>/s; evaporative dry eye,  $25.34 \pm 13.08 \times 10^{-7}$  g/cm<sup>2</sup>/s).<sup>355</sup> Different instruments have been used for assessing evaporation, although only one device (the Delfin), is currently in reported use in clinical research.<sup>356-359</sup> Tear evaporation has been shown to be reduced by eyelid warming therapy.<sup>360</sup> Confounding factors are the sampling response rate to blinking, perspiration within the sampling area, variations in palpebral aperture, blink speeds and blink patterns, and in the level of chamber ventilation, as well as differences in resistance to evaporation caused by variations in humidity and air movement.<sup>361,362</sup>

**3.5.2.1.4 Thermography.** Thermography uses a specialized camera to detect infrared radiation emitted from the ocular surface, mapping changes in the ocular surface temperature that are presumed to be caused by tear fluid evaporation.<sup>363</sup> The technique appears repeatable.<sup>364</sup> Thermal cooling of the ocular surface is a predictor of soft contact lens induced dryness symptoms.<sup>365</sup> Ocular surface temperature decreases more rapidly following a blink in individuals with adequate tear volume but unstable tear films.<sup>366-368</sup> The temperature differential between the central cornea and limbus is higher in persons with DED than in those without,<sup>369</sup> with evaporative DED associated with higher ocular surface temperature than aqueous deficient DED and patients with MGD having higher ocular surface temperature than those with healthy eyes.<sup>367,370</sup>

**3.5.2.1.5 Meibum expressibility and quality (meibometry).** Meibomian gland functionality is assessed by testing the expressibility of meibum and the quality of expressed meibum.<sup>332,371</sup> Meibum quality is typically graded as 0 (clear fluid), 1 (cloudy fluid), 2 (cloudy particulate), or 3 (toothpaste-like). The expressibility of meibum from the meibomian glands of the upper and lower eyelids is graded after 10 to 15 seconds of applying pressure as: 0 (all glands expressible), 1 (3 or 4 glands expressible), 2 (1 or 2 glands expressible) or 3 (no glands expressible). Meibomian gland

expressor devices have been developed as a means of standardizing the pressure for “diagnostic” expression, which aims to be equivalent to that of a natural blink.<sup>371</sup> Meibum quality and expressibility are correlated with gland loss and lipid layer thickness.<sup>372-375</sup>

Meibometry is a technique applied to assess lipid volume,<sup>376</sup> involving sampling meibum from the lower lid margin with a loop of translucent plastic tape. The tape is air dried for 3 minutes to allow evaporation of any contaminating tear fluid, and the optical density of the oil retained on the tape is assessed using a diode laser. A correlation has been reported between lower lid meibometry readings and expressibility of meibum from the central upper lid, as well as a reduction in volume in patients with MGD and an increase after meibomian gland orifice probing.<sup>377</sup>

A test strip made of hemp oil-absorbing material, designed specifically to absorb tear lipid, has been developed. The folded end is placed in the conjunctival sac of the lower eyelid and the length of absorption (over 1 minute seemed optimal) measured and recorded, similar to the Schirmer test.<sup>378</sup>

Tear lipidomics are reviewed in Section 3.5.4.4.2.

**3.5.2.2 Aqueous.** As the aqueous component represents the majority of the tear film volume, techniques assessing tear volume are often used to quantify this tear component.

**3.5.2.2.1 Meniscometry or tear meniscus assessment.** Meniscometry involves non-invasive biometry of the lower eyelid tear meniscus, usually in the form of a central height measurement in primary gaze. Subjective methods of tear meniscus height measurement, such as estimating the meniscus height relative to a height-adjusted slitlamp beam scale, has shown poor inter-visit reproducibility.<sup>379</sup> Slit-image photography has also been used to quantify tear meniscus height, radius, width, as well as cross-sectional area and radius of meniscus curvature.<sup>376</sup> The TFOS DEWS II Diagnostic Methodology report proposed tear meniscus height assessment as a differentiating factor for the subclassification of DED, describing a value of 0.20 mm or lower as an indicator of aqueous-deficient DED, which has subsequently been confirmed.<sup>39,320,380</sup> Tear meniscus height should be measured directly below the pupil midline ( $\pm 1$  mm), as it is affected by varying eyelid morphological characteristics more peripherally.<sup>381</sup> The timing of the assessment after a blink should be controlled, with the period between 1.0 and 2.5 seconds after the second of two non-forced blinks found to be most robust; a single measure of tear meniscus height from a single image captured is sufficient, either with infrared or visible white light (although it is noted that these are not interchangeable and clinicians should use one light source consistently).<sup>382</sup> Alternative meniscometry systems have been developed in research settings, projecting a target to dynamically visualize the tear meniscus curvature, without the need for fluorescein instillation.<sup>379,383,384</sup>

OCT allows the cross-sectional area of the tear prism or even the volume along the lower lid to be quanti-

fied.<sup>385,386</sup> Spectral-domain OCT has enabled higher resolution, greater imaging depth, and faster acquisition (facilitating 3-dimensional volume imaging) compared to time-domain OCT, which has improved image quality and measurement repeatability.<sup>330,387-389</sup> The high repeatability allows changes in tear meniscus morphology after fluid instillation to be tracked, to determine tear clearance rate.<sup>390</sup> Meniscus measurements are instrument dependent<sup>391</sup> and can be distorted by anatomical features such as lid parallel conjunctival folds, conjunctivochalasis, or other disruptions to the shape of the lid margin or ocular surface.<sup>392</sup> Furthermore, analysis of the image may be complex, time consuming, and operator dependent.<sup>393</sup>

**3.5.2.2.2 Phenol red thread test.** The slight alkalinity of the tear fluid (between pH 7 and 8)<sup>39</sup> allows the length of a thin cotton thread, with the folded end hooked over the temporal end of the eyelid, moistened by tear absorption over a 15-second period to be observed from a color change from yellow to red. Compared to the Schirmer test (see Section 3.5.2.2.3), the smaller profile and limited amount of pH indicator in the thread is expected to limit the chance of triggering substantial reflex tearing, and, as a result, intersession repeatability is better.<sup>394</sup> While the phenol red thread test is thought to indirectly measure the tear volume, it is only weakly correlated with other established methods such as fluorophotometry or tear meniscus height.<sup>394,395</sup> In addition, it is weakly correlated with dry eye symptoms.<sup>396</sup> Reported agreement with the Schirmer test is variable between studies.<sup>397,398</sup> An arbitrary aqueous deficient DED cut-off value of 20 mm has been adopted in clinical practice,<sup>399</sup> and values of  $<9$  mm in 15 seconds suggest more severe cases of aqueous-deficient DED.<sup>400</sup> Due to issues with accessibility of a commercialized product, techniques to develop an equivalent test have been described.<sup>401</sup>

**3.5.2.2.3 Schirmer test.** The Schirmer test is an invasive test of tear volume, which involves assessing the length of a (Whatman 41) filter paper strip that becomes saturated by tears, 5 minutes after hooking the end of the strip, folded at the notch, over the lower lid margin, within the temporal one-third.<sup>332</sup> Technique variations, such as the use of anesthetic that aim to differentiate basal from reflex tearing,<sup>402</sup> demonstrate poor repeatability, sensitivity, and specificity.<sup>1</sup> Using the wetting of the Schirmer strip over the final 4 minutes out of the 5 seems to be more robust than other time intervals including assessment over the full 5 minutes, but, not surprisingly, accounts for  $<3\%$  of the variance in fluorescein breakup time, a key homeostatic marker for all DED subtypes, and in meibomian gland secretion, a recognized marker of evaporative DED.<sup>403</sup>

**3.5.2.2.4 Strip meniscometry.** Strip meniscometry involves placing a strip with a 0.4-mm-diameter central duct into the lower lid tear meniscus for 5 seconds.<sup>404-406</sup> A cut-off value of  $\leq 2.5$  mm has been adopted, with test results correlating with other tear film assessments, and the values moderately repeatable.<sup>407,408</sup> The combination of strip meniscometry and fluorescein breakup time have been pro-



posed as a more sensitive approach for assessing DED than either test alone.<sup>386</sup>

**3.5.2.2.5 Tear clearance.** Measuring the fluorescence of instilled quantities of fluorescein across the ocular surface (termed fluorophotometry) can be used to quantify tear turnover, reported in terms of the decrease (in percent) per minute.<sup>409</sup> Alternative approaches to measuring tear flow include conducting a Schirmer test 5 minutes after instilling fluorescein with anesthetic, with both the length of wetting and the intensity of strip staining compared to a standard color plate after 5 minutes recorded.<sup>410</sup> Due to the various factors that can affect Schirmer test results, the tear function index, which is the value obtained by dividing the value of the Schirmer test by the tear clearance rate, is a measure that has been used by a limited number of authors to assess patients with DED.<sup>411-413</sup> Other methods of tear clearance assessment include anterior segment OCT, which has been used to evaluate the early phase of tear clearance.<sup>414</sup> Lacrimal scintigraphy (tracking a small amount of radioactive material instilled into the conjunctival cul-de-sac) has also been used to measure tear clearance.<sup>415,416</sup>

**3.5.2.2.6 Lacrimal gland patency.** A clinical test for examining the patency of the palpebral lobe of the lacrimal gland has been described, which involves having the patient look inferonasally while the upper eyelid is retracted in a superotemporal direction. Dry 2% fluorescein ophthalmic strips are applied onto the exposed palpebral lobe multiple times over 20 seconds. This allows the number and location of ductules per lobe as well as the tear flow rate to be assessed.<sup>417</sup> Alternatively, the patency of the lacrimal gland can be assessed by stimulating the ocular surface with a pure CO<sub>2</sub> gas jet at 200 mL·min<sup>-1</sup> for 3 seconds, delivered 5 mm from the cornea and measuring the increase in reflex tearing volume with a Schirmer strip.<sup>418</sup>

**3.5.2.2.7 Tear proteins and other components.** Levels of the antibacterial and anti-inflammatory lacrimal gland proteins, lipocalin, lactoferrin, and lysozyme,<sup>419</sup> can be assessed as an indirect measure of lacrimal gland function. Tear protein concentration has generally been found to decrease with age.<sup>420</sup> Although lactoferrin has been proposed as a biomarker of DED,<sup>421-423</sup> low tear lactoferrin levels are also found in giant papillary conjunctivitis, vernal keratoconjunctivitis, and chronic meibomitis associated with acne rosacea.<sup>424-426</sup> Tear film urea levels are linearly related to Schirmer test values; for diagnosing DED, a cutoff of  $\leq 37.2$  mg/dL has been reported to provide a sensitivity of 96% and specificity of 76%.<sup>427</sup> Tear fluid proteomics are reviewed in Section 3.5.4.4.2.7.

### 3.5.2.3 Mucin/glycocalyx.

**3.5.2.3.1 Mucins.** Human conjunctival goblet cells synthesize and secrete the largest type of gel-forming, non-surface-bound mucin in the eye, MUC5AC, which acts to protect and lubricate the ocular surface, mitigating friction during blinking.<sup>4,428</sup> Patients with DED typically show reduced concentrations of soluble MUC5AC in tear fluid.<sup>429</sup>

Together with lipids, a concomitant increase in MUC5AC protein expression in the tears of infants may contribute to their greater tear film stability.<sup>430</sup> Goblet cell count and tear MUC5AC protein are decreased in Graves ophthalmopathy, thought possibly to be due to ocular surface inflammation secondary to ocular surface exposure.<sup>431</sup>

Immunohistochemistry and immunoelectron microscopy have been used to examine binding of the HI85 antibody, which recognizes carbohydrate epitopes on the MUC16 mucin on the surfaces of apical conjunctival cells.<sup>432,433</sup>

Other membrane-associated mucins, MUC1, MUC4, as well as MUC16 (glycocalyx) as well as gel-forming mucin MUC5AC, have been studied using a range of different techniques.<sup>244,434,435</sup> In other research, large decreases in sialic acid (almost 7-fold)<sup>436</sup> and increases in galectin-3 (proxies for the glycocalyx/mucin)<sup>437</sup> have been observed in tear fluid and have been shown to correlate strongly with clinically assessed disease severity.<sup>438</sup>

**3.5.2.3.2 Rose bengal and lissamine green** (see Section 3.4.1.7). Rose bengal has been shown to stain ocular surface epithelial cells that are unprotected by the mucin rich glycocalyx,<sup>439</sup> but it has been shown to suppress human corneal epithelial cell viability *in vitro*, indicating toxicity.<sup>240</sup> Lissamine green is less toxic to the ocular surface and has largely replaced the use of rose bengal in clinical care and research. Lissamine green is a vital dye that stains epithelial cells where the cell membrane or intracellular junctions are damaged, irrespective of the presence of mucin.<sup>39,440</sup>

**3.5.2.3.3 Conjunctival impression cytology.** After the instillation of topical anesthetic, a cellulose acetate filter is pressed against the bulbar conjunctival surface, usually the upper, for 5 to 10 seconds using forceps. The samples are then fixed using 95% ethanol, stained with periodic acid-Schiff reagent, and fixed on a slide to be viewed with a light microscope.<sup>261</sup> The Nelson classification system is used most frequently to grade the density, morphology, cytoplasmic staining affinity, and nucleus/cytoplasm ratio of conjunctival epithelial and goblet cells across the ocular surface.<sup>39</sup> There is variation in goblet cell distribution across the conjunctival surface, with the lower forniceal conjunctival goblet cell density higher than that in the bulbar conjunctiva.<sup>441</sup> Recently, moxifloxacin-based fluorescence microscopy has emerged as a novel technique that enables efficient, non-invasive and *in vivo* imaging of goblet cells in animals.<sup>442</sup> Confocal imaging, on the other hand, can be used to assess corneal cell morphology,<sup>443</sup> goblet cell density,<sup>444</sup> and conjunctival squamous metaplasia (from nucleocytoplasmic ratios)<sup>445</sup> *in vivo* in humans.

**3.5.2.3.4 Ferning test.** Whole tears collected by one of a number of possible techniques<sup>446</sup> are transferred immediately to a small plastic centrifuge tube (0.5 mL or less); a sample (1-2  $\mu$ L) is then pipetted onto a clean glass microscope slide and allowed to dry for 7 to 10 minutes under normal room temperature (20-26°C) and room humid-



ity (up to 50%).<sup>447</sup> The slide then can be observed under a light or digital microscope with varying magnification.<sup>446</sup> Depending on the tear film composition, a variety of ferning patterns can be observed. The classification is typically as follows: type I: uniform large arborization; type II: ferning abundant but of a smaller size; type III: partially present but incomplete ferning; and type IV: no ferning.<sup>448</sup> Healthy tear samples typically produce full dense ferning patterns (types I and II), while the ferning pattern are often fragmented or absent in patients with DED.<sup>446</sup>

The exact nature of what determines the ferning pattern is still not fully understood,<sup>1,449</sup> although a causal link has been proposed between tear ferning pattern and the ocular mucins.<sup>449</sup> Hyperosmolarity affects the appearance of ferning patterns,<sup>446</sup> as does introducing electrolytes into the tear film.<sup>450</sup> Tear ferning patterns have been found to be repeatable.<sup>451</sup> A correlation has been found between the ferning test grade, non-invasive breakup time,<sup>452</sup> and low Schirmer test values, but no correlation has been reported between ferning pattern and various tear protein levels.<sup>453</sup>

### 3.5.3 Eyelid anomalies

**3.5.3.1 Blink and lid closure anomalies.** Blinking is a complex neuromuscular process that plays a vital role in maintaining ocular surface homeostasis and proper functioning of the tear film. Specifically, it facilitates the even distribution of tears, mucin, and lipids that are essential for lubrication, protection from eye irritation, and removal of debris and foreign bodies.<sup>289,454-456</sup> Blinking is primarily controlled by the orbicularis oculi muscle, innervated by the facial nerve (cranial nerve VII).<sup>457</sup> The levator palpebrae superioris muscle, innervated by the oculomotor nerve (cranial nerve III), and Müller muscle, innervated by sympathetic fibres, are also contributory.<sup>458</sup> Sensory input from the cornea and conjunctiva, relayed via the trigeminal nerve (cranial nerve V), modulates the blink reflex.<sup>459</sup>

Blinking can be categorized into 3 types.<sup>460</sup> The first type is spontaneous blinking, which is the unconscious and coordinated closure of both upper eyelids occurring briefly and symmetrically without any evident stimulus. The second type is reflex blinking, which is triggered by trigeminal, visual, and acoustic stimuli. The third type is voluntary blinking, which is defined as the closure of eyelids, consciously initiated by the individual. The normal rate for spontaneous blinking ranges from 10 to 15 blinks per minute.<sup>295,461</sup> This rate can be influenced by multiple factors, such as age, cognitive load, social activity, neurological and psychiatric diseases, fatigue, eye injury, medication, contact lens wear, and dryness.<sup>295,460</sup>

Abnormalities in blinking patterns have been implicated in DED development.<sup>279,282,289</sup> Blink rates, interblink interval, and maximum blink interval can differentiate patients who are considered healthy from those with DED,<sup>285,291</sup> likely associated with the changes in ocular surface exposure and failure to restore tear film structure between blinks. Patients with DED often exhibit increased

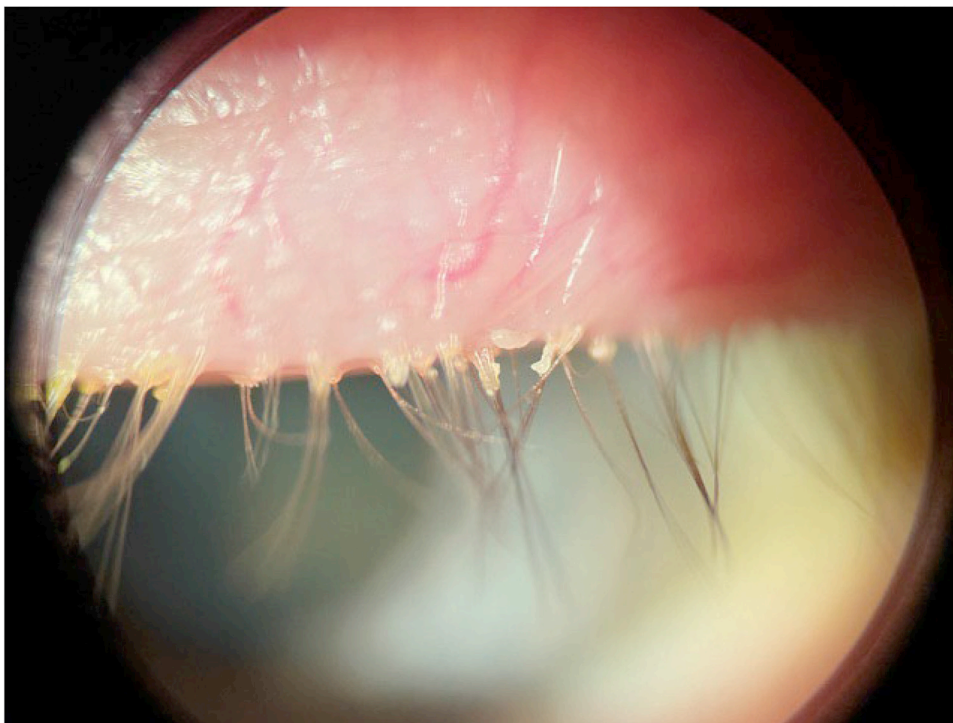
blink rates<sup>295</sup> relative to normal individuals. However, reduced blink rates have also been observed both in individuals with and without DED, particularly during activities requiring prolonged visual attention (eg, screen use), leading to insufficient tear film distribution and increased tear evaporation rates.<sup>462</sup> Similarly, studies have shown that patients with DED had shorter mean and maximum interblink intervals compared to healthy controls.<sup>283,289,463</sup> Notably, people with DED also demonstrated higher rates of incomplete blinking,<sup>296</sup> which in itself is associated with inadequate expression of meibomian gland secretions into the lipid layer on the ocular surface, exacerbating tear film instability.<sup>464-466</sup>

Given the multifactorial nature of DED, a comprehensive evaluation of blinking physiology is essential for understanding its pathophysiology and employing effective treatment strategies. Clinical monitoring is usually subjective and surreptitious to avoid conscious or unconscious changes in blink behaviour from the patient,<sup>467</sup> but objective image analysis is becoming more widely available. Improving blink quality and frequency through behavioral modifications and therapeutic interventions can significantly benefit ocular surface health and patient comfort.<sup>475</sup> Poor lid seal is also linked to symptomology in DED and can be detected by placing a pen torch or transilluminator against the relaxed, closed, outer upper eyelids of semi-reclined patients and observing visible light emanating from the lid area between the lashes.<sup>251</sup>

### 3.5.3.2 Lid margin health.

**3.5.3.2.1 Anterior blepharitis.** Anterior blepharitis has been defined as “inflammation of the lid margin anterior to the gray line and concentrated around the lashes” that may be accompanied by squamous debris or cylindrical dandruff around the lashes (Figure 6), and may spill onto the posterior lid margin.”<sup>47,468,469</sup> The term “blepharitis” is often used by clinicians to describe anterior blepharitis, with posterior cases referred to by the more specific etiology, such as meibomian gland dysfunction. The pathophysiology of anterior blepharitis is multi-staged and relates to microbial changes that can culminate in inflammation: periocular bacteria build a defensive structure known as a biofilm, which predisposes to forming on the eyelid margin due to its moisture, nutrients, and warmth. Biofilms are composed of a polysaccharide/protein matrix that adheres strongly to surfaces due to proteins such as adhesin produced by bacteria such as *Staphylococcus epidermidis* and *Staphylococcus aureus*. Biofilms allow bacteria to evade the impacts of desiccation and host defense mechanisms, facilitating gene activation and inflammatory virulence factors.<sup>470</sup> Dry eye symptoms<sup>471</sup> and signs,<sup>472</sup> as well as contact lens discomfort,<sup>473,474</sup> are reduced on treatment of anterior blepharitis,<sup>475</sup> implicating anterior blepharitis as one of the key triggers of the multifactorial DED.

Common clinical manifestations of anterior blepharitis include the presence of squamous debris or cylindrical dan-



**FIGURE 6.** Cylindrical dandruff around the eyelash bases in anterior blepharitis, observed by slit lamp biomicroscopy with white light at 15× magnification.

druff around the base of the lashes, accompanied by vascular changes in the lid skin.<sup>468,476</sup> Anterior blepharitis is associated with ocular rosacea, seborrhea, and hypersensitivity caused by staphylococcal toxins, infectious processes (bacterial or viral), or infestation by phthiriasis or *Demodex*, or combinations of these triggers.<sup>477</sup>

The most frequently identified species are *Staphylococcus epidermidis* (in around one-third of cases), followed by *Pseudomonas* (approximately 20%), *Staphylococcus aureus*, *Cutibacteria*, *Corynebacteria*, and *Moraxella*.<sup>478,479</sup> Immunologic mechanisms have been documented, with enhanced cell-mediated immunity to *Staphylococcus aureus* detected in 40% of patients with chronic blepharitis. Seborrheic blepharitis, in contrast, presents with greasy deposits and is commonly associated with seborrheic dermatitis of the eyebrows and scalp.<sup>476,480</sup>

**3.5.3.2.1.1 *Demodex-associated blepharitis.*** Anterior blepharitis can also result from the activity of *Demodex* parasites identified in 14% to 89% of the population (especially in older patients).<sup>105,481-483</sup> Two types have been identified in human eyelids: *Demodex folliculorum* and *Demodex brevis*.<sup>484</sup> *Demodex folliculorum* is typically found in the eyelash follicles of the eyelids.<sup>485</sup> Characteristic features are apparent at the base of the lashes, and these can be present in asymptomatic individuals. *Demodex* mite presence is associated with changes in the anterior lid margin, such as increased scale intensity and cylindrical dandruff or sleeves. Cylindrical dandruff are considered pathognomonic of the presence of *Demodex* mites.<sup>485,486</sup>

*Demodex* can be detected by examining epilated eyelashes under white light microscopy at high magnification<sup>487,488</sup> or on a slitlamp at high magnification. Manipulating an eyelash with cylindrical dandruff around its axis in a circular motion<sup>489,490</sup> or by applying lateral traction<sup>491</sup> using fine-tipped metal forceps can reveal mite tails at the insertion point of the lashes. Detection of *Demodex* using *in vivo* confocal microscopy has also been described, but this technique is cumbersome, time-consuming and costly, limiting its diagnostic utility.<sup>491,492</sup>

**3.5.3.2.2 Meibomian gland dysfunction (MGD).** MGD, a major contributing factor to DED, is described as “a chronic, diffuse abnormality of the meibomian glands, commonly characterized by terminal duct obstruction and/or qualitative/quantitative changes in the glandular secretion” in the TFOS International Report on Meibomian Gland Dysfunction Definition and Classification report published in 2011.<sup>468</sup> The diagnosis of MGD is primarily clinically based, focusing on detection of signs indicative of altered meibomian gland secretions, lid margin changes, and meibomian gland dropout.<sup>372</sup> The severity of MGD is classified based on subjective symptoms, abnormal signs at the orifices (plugging, pouting, and capping), vascularization or reddening of the eyelid margin, anterior or posterior displacement of the mucocutaneous junction, eyelid margin irregularity and rounding, gland dropout observed by meibography (where imaging both upper and lower lids is important<sup>493</sup>), corneal and tear film abnormalities, such as superficial punctate keratitis and the quality of the expressed

meibum.<sup>494-496</sup> Various clinical grading criteria for gland appearance have been proposed.<sup>495,497-499</sup> Additionally, the term “plus disease” has been used to refer to coexisting or accompanying disorders of the ocular surface and/or eyelids.<sup>331</sup> Another scoring system combines subjective symptoms, slitlamp microscopy findings, and tear film test results to classify MGD severity into stages 1 to 4 and describes the relationship between MGD severity and serum lipids.<sup>500</sup> An alternative scoring system integrates subjective symptoms, *in vivo* confocal microscopy findings, slitlamp biomicroscopy, meibography, tear film breakup time, and corneal staining scores, classifying MGD severity into 3 stages.<sup>494,500</sup> Yet another scoring system elected to combine scores for secretion appearance and the digital pressure needed to express the meibum.<sup>501</sup>

The number of lower eyelid meibomian glands yielding liquid secretion has been assessed as a metric of MGD.<sup>371</sup> Assessing meibum expressibility, color, and quantity is crucial,<sup>502</sup> either as the highest grade from 8 expressed glands (total score range: 0-3) or summing all 8 gland expressibility scores (total score range: 0-24).<sup>467,468</sup>

Anatomically, there are more meibomian glands in the upper eyelid, with a median count of 31, compared to a median count of 26 in the lower eyelid.<sup>469</sup> The glands in the upper eyelid are notably longer and slimmer than those in the lower eyelid. Studies on lower and upper eyelids separately highlight secretion differences between the nasal and temporal sides. The lower eyelid reportedly has higher secretion rates and poorer meibum quality than the upper eyelid.<sup>467</sup> Additionally, nasal glands appear more active, with activity diminishing toward the temporal margin.<sup>503</sup> Upper, undertaken together with lower, eyelid meibography has been proposed to be an integral component of comprehensive meibomian gland evaluation.<sup>493</sup>

Non-invasive infrared or transillumination photography of meibomian glands has advanced the assessment of two-dimensional gland silhouettes.<sup>498,504</sup> Meibography enables direct visualization of meibomian gland morphology, highlighting partial or total nonvisible meibomian tissue as dropout or loss.<sup>372,505</sup> This can be assessed through subjective grading<sup>468,506-508</sup> or semi-quantitative or quantitative analyses.<sup>509</sup> Asymptomatic individuals have been found to have meibomian gland loss of <16.9% for the upper and <28.7% for the lower eyelid.<sup>498</sup> Various gland morphological characteristics have been identified, including truncation, dilation, and tortuosity,<sup>510,511</sup> but none in isolation seems to be a good predictor of DED.<sup>512</sup>

Tortuosity of the meibomian glands in the upper eyelid has been observed to correlate negatively with tear film stability, while tortuosity in the lower eyelid correlated with dry eye symptoms.<sup>508</sup> However, its variability makes it less reliable as a standalone diagnostic parameter,<sup>503,508</sup> and it is only weakly correlated with meibomian gland expressibility.<sup>372</sup> Meibomian gland thickness increases with overall loss, potentially as a compensatory response, although

this does not improve expressibility.<sup>372,503</sup> On the other hand, distorted and thinned glands appear to be transitional phases before dropout.<sup>468,469,502</sup> However, meibomian gland length has been identified as the key morphological metric for function in terms of expressibility.<sup>372</sup>

OCT has been used to image meibomian glands and may be more sensitive than traditional meibography techniques.<sup>513</sup> *In vivo* confocal microscopy can observe meibomian gland orifice tissues at a cellular level, enabling evaluation of acinar density, acinar diameter, enlarged meibomian gland orifice, and conjunctival inflammatory cell density<sup>514</sup>; it can also allow assessment of glandular atrophy and peri-glandular fibrosis. However, the equipment is expensive and requires a learning curve to obtain good images, and the technique requires contact with the epithelium, posing disadvantages with respect to invasiveness and prolonged examination burden. The technique is unable to permit visualization of the glands themselves in the human eyelid margin due to light attenuation at that tissue depth; the structures imaged are rete ridges located at the dermal-epidermal junction, with alterations believed to reflect a shift of the mucocutaneous junction.<sup>515</sup> Clinical use remains limited.<sup>331,494,514,516</sup> Lipid quantification at the eyelid margins and biochemical analysis of gland secretions for lipid components and markers are still being researched (see Section 3.5.4.4.2).<sup>494</sup>

The inner border of the eyelid margin plays a crucial role in helping to maintain ocular surface integrity by ensuring even spread of the thin tear film with each blink. Normally, the eyelid margin features a convex inner border with a keratinized epidermis, which ends abruptly behind the posterior margin of the meibomian orifices. This is followed by the mucocutaneous junction, creating a transition zone between the moist, non-keratinized conjunctival tissue of the ocular surface and the dry, keratinized tissue of the eyelid margin.<sup>517</sup> This area, termed the lid wiper zone, is in constant contact with the ocular surface to distribute the tear film and morphological changes at this site have been associated with tear film instability and early signs of DED.<sup>266,518</sup> The lid wiper zone extends from the mucocutaneous junction to the subtarsal fold sagittally and from the medial punctum to the lateral canthus horizontally. Posterior migration of the mucocutaneous junction leads to lid-margin keratinization.<sup>519</sup> Mechanical factors between the eyelid and the ocular surface contribute to diseases perceived to be friction-related (in the form of shear forces), including superior limbic keratoconjunctivitis, lid wiper epitheliopathy, and conjunctivochalasis.<sup>520</sup> Damage to the epithelium of the marginal conjunctiva at the lid wiper zone is a clinical sign indicative of DED<sup>271</sup> and its staining and grading is covered in Section 3.5.4.3.

Factors such as aging, inflammation, hormonal imbalance, bacterial growth, eye drops, and oral medications can induce hyperkeratinization of the meibomian gland ductal epithelium, altering meibum transparency and viscosity.<sup>494</sup>



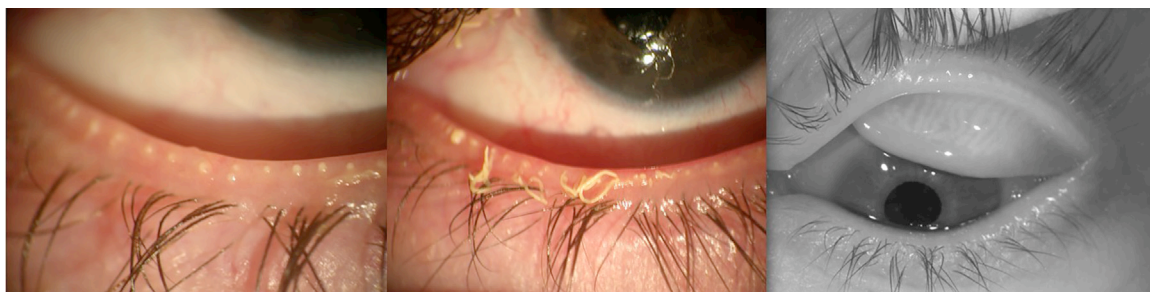


FIGURE 7. (A) Blocked meibomian glands. (B) “Toothpaste”-like meibum. (C) Upper lid meibography of an eye with meibomian gland truncation.

These changes are hypothesized to lead to gland obstruction and reduced meibum secretion.

Keratinization of the lid margin can also result from long-term rigid contact lens wear or severe systemic conditions such as Stevens–Johnson syndrome/toxic epidermal necrolysis. These conditions lead to loss of the mucocutaneous junction barrier, epidermalization, whitish keratin deposits over the lid wiper zone, dyskeratosis, T-cell and neutrophil infiltration, and altered local microbiome.<sup>517,521,522</sup> Keratinization can also occur with androgen insensitivity<sup>523</sup> and androgen deficiency,<sup>47,123</sup> *Staphylococcus aureus* overcolonization,<sup>524</sup> estradiol increases of cornulin,<sup>525</sup> stearyl-CoA desaturase-1 deficiency, and related upregulation of ceramides due to altered fatty acid metabolism,<sup>526</sup> hyperlipidemia,<sup>527</sup> and isotretinoin.<sup>528</sup> (Figure 7)

**3.5.3.2.3 Ocular rosacea.** Acne rosacea has long been recognized as an inflammatory disease resulting from a complex interaction of abnormalities of the innate and adaptive immune system, accompanied by mast cell dysfunction and/or neurovascular compromise. However, the exact mechanisms and roles of these different components of the pathophysiology remain incompletely elucidated.<sup>529</sup> Acne rosacea is currently diagnosed<sup>530</sup> based on the presence of at least one “diagnostic phenotype” (centro-facial erythema with periodic intensification or phymatous changes) or at least two “major phenotypes” (papules and pustules, flushing, telangiectasia, or ocular rosacea); however, ocular rosacea is not well defined, with a list of features proposed from blepharitis and conjunctival injection as being indicative of mild-to-moderate disease, to punctate keratitis, infiltrates, vascularization, and scleritis indicating moderate-to-severe disease.<sup>530</sup> A recent review identified 10 typical ocular signs and nine diagnostic steps for recognizing ocular rosacea, but many of these overlap with other posterior blepharitic conditions, with the main differentiating features being concurrent signs of rosacea on the skin, recurrent hordeola/chalazia, corneal vascularization, corneal infiltrates/ulcers, and anterior uveitis.<sup>531</sup>

### 3.5.4 Ocular surface abnormalities

**3.5.4.1 Anatomical misalignment.** Ultraviolet radiation and other chronic environmental exposures can cause changes

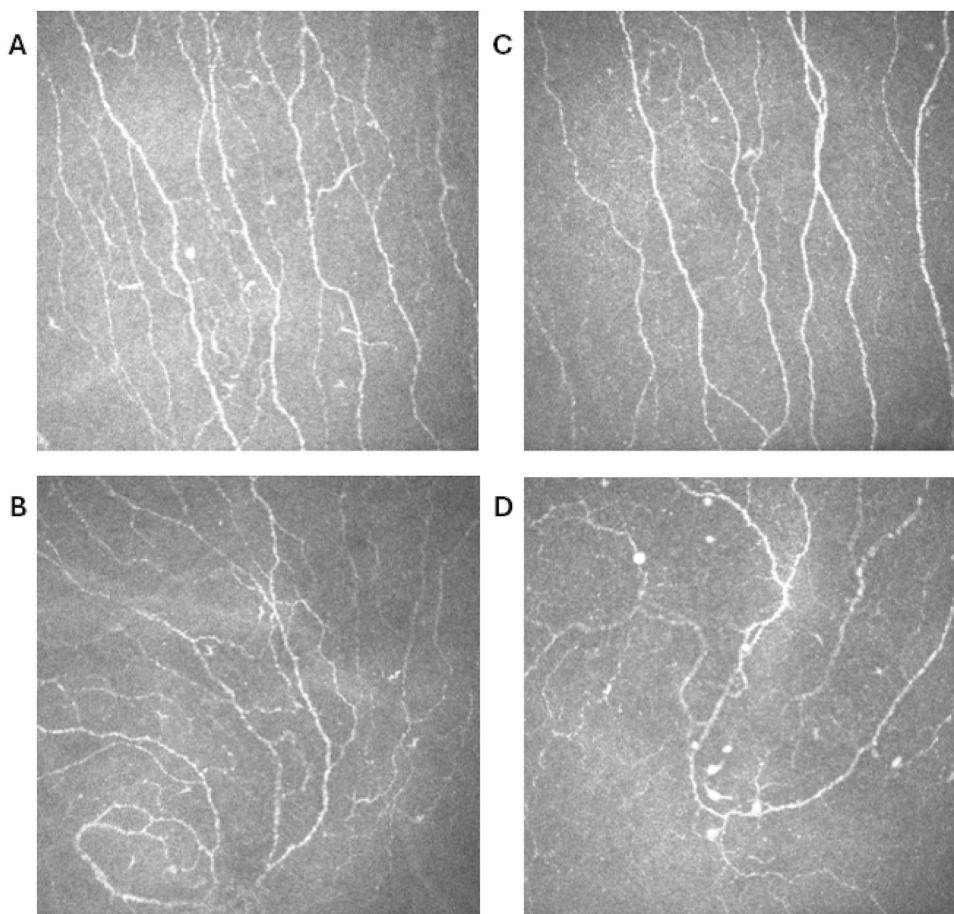
in the corneal and conjunctival cells, leading to disruption of the smooth ocular surface: for example, pterygia,<sup>532,533</sup> pingueculae,<sup>534</sup> LIPCOF (see Section 3.1.4.6),<sup>392,535</sup> and conjunctivochalasis.<sup>535</sup> Any such raised structures can affect the flow of the tear film, the position/function of the glands, and the conformity between the eyelids and the ocular surface, reducing tear film stability and altering tear volume distribution.<sup>536</sup>

LIPCOF are undulations in the inferior bulbar conjunctiva, parallel to the margin of the lower lid. LIPCOF may be observed as the initial signs of conjunctivochalasis (possibly having the same etiology)<sup>537</sup> but exhibit a smaller cross-sectional area,<sup>392,538</sup> do not occur centrally,<sup>539,541</sup> and have no apparent relationship with age.<sup>539</sup> LIPCOF have a moderately high predictive ability for differentiating symptomatic eyes with poor tear stability,<sup>540,542,543</sup> but not in all studies.<sup>544</sup> Independent groups have shown that OCT can optically resolve LIPCOF morphology, such as LIPCOF area, that correlates well with subjective grading.<sup>545,546</sup>

While other signs are associated with DED, such as ocular surface/conjunctival redness, epithelial thickness,<sup>547</sup> corneal nerve damage, inflammatory cell migration into the cornea, a loss of corneal sensitivity, changes to the meibomian glands (morphology and expressibility), and blinking, there is not strong evidence for the role of each in the broader, initial diagnosis of DED. These other tests may be valuable, however, and are covered with respect to their role in determining the etiological drivers of DED (see Section 3.5).

**3.5.4.2 Neural dysfunction.** Corneal neuropathic pain is complex, with a pragmatic and systematized approach needed for management.<sup>548</sup> Abnormal corneal sensitivity has been associated with signs and symptoms in individuals with ocular surface disease.<sup>549,550</sup> The corneal nerves serve both sensory and trophic functions. The sensory function is not only linked to the blink reflex, but also to tear secretion by the lacrimal gland. Corneal sensitivity is a measure of corneal nerve function and an indicator of the integrity of the protective mechanisms of the ocular surface.<sup>551</sup> Morphological and anatomical features can be directly observed by *in vivo* confocal microscope imag-





**FIGURE 8.** Corneal nerves observed by *in vivo* confocal microscopy (IVCM). (A) Central corneal and (B) inferior whorl nerves in a healthy eye. (C) Central corneal and (D) inferior whorl nerves in dry eye disease.

ing and objectively graded using software,<sup>552,553</sup> whereas function is assessed with the aid of a contact or non-contact corneal esthesiometer to assess corneal sensitivity. Lid margin sensitivity determined by non-contact esthesiometry has been demonstrated to be strongly correlated with corneal sensitivity;<sup>550</sup> lid margin sensitivity thresholds exhibited marginally higher predictive performance than corneal sensitivity for clinical signs of DED, as defined by the TFOS DEWS II criteria, and were significantly correlated with non-invasive tear film breakup time, corneal, conjunctival, and lid wiper staining.<sup>550</sup> Liquid jet esthesiometers have also been developed, and corneal hypersensitivity to cold has been found to be related to digital eye strain.<sup>554</sup> The corneal subbasal nerves may be evaluated in detail, using *in vivo* confocal microscopy.<sup>555</sup> Corneal subbasal nerve plexus density and length tend to decrease and tortuosity to increase, whereas the loss of corneal endothelium is accelerated in patients with DED, indicating damaged nerve fibres (Figure 8).<sup>556-558</sup> Moreover, the damage to the nerves in DED may prevent the nervous system from exerting its immunomodulatory role, leading to changes in corneal sensitivity.<sup>559</sup> Although many studies have shown

that the number and density of the subbasal nerves in patients with DED decrease significantly and strongly correlate with the decrease in corneal sensitivity,<sup>560-563</sup> some studies show no relationship, perhaps due to variations in DED subtypes and severity of disease being examined.<sup>564</sup> Some studies have also found that different clinical presentations of DED show corresponding corneal sensitivity changes.<sup>565</sup>

Severe neuropathic corneal pain, as an abnormality of corneal sensitivity with extreme effects, has attracted significant attention from researchers aiming to more fully understand its underlying nerve abnormalities (see TFOS DEWS III Digest Pain and Sensation section).<sup>4</sup> The decrease in corneal nerve density in neuropathic corneal pain is consistent with other types of DED. However, the relationship between microneuromas and nerve beading (Figure 9) and corneal nerve pain is still unclear, and further studies are required.<sup>566,567</sup> (Table 3)

Systemic diseases that are associated with DED can cause corneal hypoesthesia such as in patients with diabetes.<sup>569-571</sup> In addition to nerve reduction, a significant reduction in nerve beading frequency has also been re-

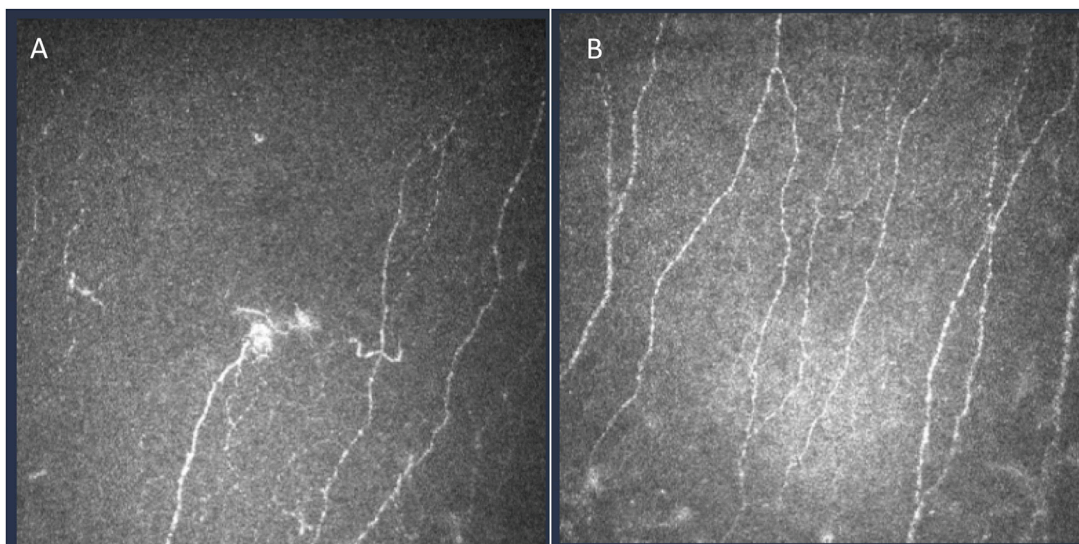


FIGURE 9. (A) Microneuromas in dry eye disease. (B) Nerve beading in dry eye disease.

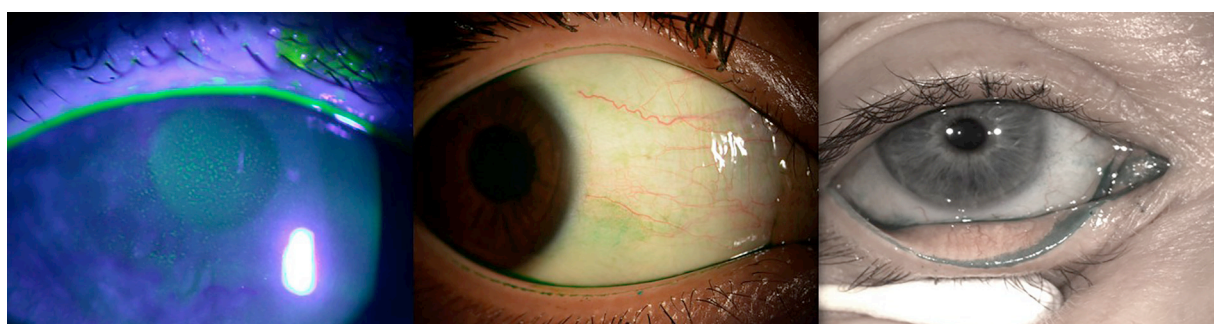


FIGURE 10. (A) Fluorescein corneal staining illuminated with a blue light. (B) Lissamine green bulbar conjunctival staining under white light. (C) Lissamine green staining of lower lid wiper epitheliopathy under white light.

ported, possibly due to reduced metabolic activity in patients with diabetes.<sup>572-574</sup> Corneal nerve changes have also been observed in patients with Graves ophthalmopathy (which is often associated with DED), perhaps due to nerve degeneration.<sup>575</sup> However, there appears to be no research on corneal sensitivity related to Graves ophthalmopathy, nor its correlation with structural alterations in nerves.

**3.5.4.3 Ocular surface cellular damage/disruption.** As noted in Section 3.4.1.6, punctate staining of the cornea and bulbar conjunctiva observed following the application of clinical dyes, such as sodium fluorescein (Figure 10), rose bengal, and lissamine green, is a key diagnostic marker of numerous anterior segment conditions, including DED.<sup>238</sup> The distribution of punctate staining may provide an indication of potential aetiology,<sup>238,576</sup> with DED traditionally thought to be predominantly associated with interpalpebral or inferior corneal staining.<sup>238</sup> There continues to be growing

interest in the utility of lid wiper epitheliopathy assessment in the diagnosis of DED.<sup>1,577</sup>

To facilitate standardized recording of the severity of ocular surface staining and lid wiper epitheliopathy (see Section 3.5.4.3), several grading systems have been devised, and the most commonly used are summarized in Table 4.<sup>578</sup> Corneal and conjunctival staining grading systems include the van Bijsterveld system,<sup>579</sup> the National Eye Institute (NEI) Industry Workshop guidelines,<sup>19</sup> the Collaborative Longitudinal Evaluation of Keratoconus (CLEK) schema,<sup>580</sup> the Oxford scheme,<sup>581</sup> the Lexitas grading system,<sup>582</sup> the area–density combination index,<sup>583</sup> and the Sjögren’s International Collaborative Clinical Alliance (SICCA) ocular staining score.<sup>584</sup> A recent study modified the Oxford scheme to incorporate half-unit increments for the assessment of corneal staining and reported improved sensitivity and repeatability.<sup>275</sup> The corneal and conjunctival staining component of the global consensus TFOS DEWS II diagnostic criteria was based on the SICCA grading system.<sup>1</sup> Lid wiper epitheliopathy is most commonly

**TABLE 3. Confocal Studies of Corneal Nerve Abnormalities in Dry Eye Disease (DED)**

Study	Cohort	Design	Results
Kalteniece et al, 2017 <sup>555</sup>	n = 35 with obesity	Cross-sectional	<ul style="list-style-type: none"> <li>• High intra and interobserver reproducibility for all corneal nerve parameters</li> <li>• 6 images sufficient for analysis</li> </ul>
Tepelus et al, 2017 <sup>557</sup>	n = 24 DED, n = 44 Sjögren's n = 10 control	Cross-sectional	<ul style="list-style-type: none"> <li>• Density of nerve fibers decreased, primarily in Sjögren's disease</li> <li>• Nerve tortuosity and reflectivity decrease in all DED</li> <li>• Density of dendritic cells higher in DED groups</li> <li>• Nerve and cell changes correlated with symptomology</li> </ul>
Kheirkhah et al, 2017 <sup>558</sup>	n = 20 DED n = 13 control	Retrospective longitudinal	<ul style="list-style-type: none"> <li>• Endothelial cell density and nerves lower in DED</li> <li>• Loss is greater than literature reports for normal ageing</li> </ul>
Levy et al, 2017 <sup>559</sup>	n = 30 Sjögren's (n = 15 control)	Prospective, non-randomized treatment study	<ul style="list-style-type: none"> <li>• 6 months Topical cyclosporine A 0.05% increased corneal subbasal nerve density (only)</li> <li>• Decreased dendritic cell numbers, more so in patients with more severe baseline symptoms and staining</li> <li>• Corneal sensitivity increased</li> </ul>
Cardigos et al, 2019 <sup>556</sup>	n = 54 with Sjögren's disease n = 62 with non-Sjögren's Sicca n = 20 control	Cross-sectional	<ul style="list-style-type: none"> <li>• Corneal subbasal nerve plexus density and length lower, and tortuosity higher in DED</li> <li>• Corneal subbasal nerve plexus strongly associated with Schirmer test score and tear breakup time</li> </ul>
Ross et al, 2020 <sup>566</sup>	n = 14 with severe ocular pain > 1 y, 4 with neuropathic pain	Cross-sectional	<ul style="list-style-type: none"> <li>• Subbasal nerve density reduced compared with controls</li> <li>• More activated keratocytes and spindle, lateral, and stump microneuromas in stroma in patients with neuropathic pain</li> </ul>
Moein et al, 2020 <sup>567</sup>	n = 30 DED n = 25 neuropathic pain n = 16 controls	Retrospective, case-control	<ul style="list-style-type: none"> <li>• Similar lower nerve density and higher dendritic cell numbers in DED and neuropathic groups</li> <li>• No difference in nerve beading</li> <li>• Microneuromas present only in neuropathic pain group</li> </ul>
Maity et al, 2024 <sup>568</sup>	n = 28 Sjögren's disease n = 25 meibomian gland dysfunction	Cross-sectional	<ul style="list-style-type: none"> <li>• Similar dendritic cell density</li> <li>• Nerve fiber length, density, and branching lower with Sjögren's disease</li> <li>• Tear osmolarity weakly negatively correlated with corneal nerve parameters</li> </ul>

assessed relative to the Korb grading system, which combines the horizontal length of staining in millimeters, as well as the sagittal width relative to the eyelid margin.<sup>266</sup> The eyelid margin staining component of the global consensus TFOS DEWS II diagnostic criteria was based on this grading system.<sup>1</sup>

Key diagnostic accuracy studies evaluating the discriminative performance of ocular surface staining and lid wiper epitheliopathy in the detection of DED are summarized in Table 5. Overall, lid wiper epitheliopathy (C-statistic range, 0.69-0.80) demonstrated superior discriminative ability relative to corneal (C-statistic range, 0.52-

0.57) and conjunctival staining (C-statistic range, 0.51-0.63),<sup>222,248,250,540,585</sup> which would support the incorporation of all 3 staining parameters in the routine diagnostic workup of DED.<sup>1</sup> The reasons underlying the greater diagnostic performance of lid wiper epitheliopathy are not completely understood. Previous studies have reported that corneal and conjunctival staining are more commonly present in patients with severe DED<sup>248,250</sup> and demonstrate poorer correlation with other dry eye signs and symptoms in mild-to-moderate disease.<sup>248,250</sup> Moreover, a number of epidemiological and diagnostic studies have suggested that lid wiper epitheliopathy might be an earlier clinical sign than

**TABLE 4.** Commonly Used Grading Systems for Ocular Surface Staining and Lid Wiper Epitheliopathy

Grading System	Details
van Bijsterveld staining score <sup>579</sup>	<p>Corneal staining scoring:</p> <p>1: sparsely scattered spots</p> <p>2: densely scattered spots</p> <p>3: confluent spots</p> <p>Conjunctival staining scoring:</p> <p>Divided into nasal and temporal zones</p> <p>1: few separated spots</p> <p>2: many separated spots</p> <p>3: confluent spots</p>
NEI staining score <sup>19</sup>	<p>Corneal staining scoring:</p> <p>Divided into 5 sectors (central, superior, inferior, nasal, and temporal), each scored from 0 to 3</p> <p>Conjunctival staining scoring:</p> <p>Divided into superior paralimbal, inferior paralimbal, and peripheral area, both nasally and temporally, each scored 0 to 3</p>
CLEK staining score <sup>580</sup>	<p>Cornea staining scoring:</p> <p>Divided into 5 sectors (central, superior, inferior, nasal, and temporal), each scored from 0 to 4 in 0.5 increments.</p> <p>Conjunctival scoring:</p> <p>Divided into 4 sectors (superior, inferior, nasal, and temporal), each scored from 0 to 4 in 0.5 increments</p> <p>Intraclass correlation coefficient<sup>587</sup>:</p> <p>Fluorescein: 0.76</p> <p>Rose bengal: 0.40</p>
Oxford staining score <sup>581</sup>	<p>Corneal staining scoring:</p> <p>Whole corneal area scored from 0 to 5 dependent on the intensity of punctate staining displayed pictorially, with the intensity of dots increasing on a logarithmic scale between grades</p> <p>Conjunctival staining scoring:</p> <p>Whole conjunctival area scored from 0 to 5 dependent on the intensity of punctate staining displayed pictorially, with the intensity of dots increasing on a logarithmic scale between grades</p>
Korb grade <sup>266</sup>	<p>Lid wiper epitheliopathy horizontal length grading:</p> <p>0: &lt;2 mm</p> <p>1: 2 to 4 mm</p> <p>2: 5 to 9 mm</p> <p>3: ≥10mm</p> <p>Lid wiper epitheliopathy sagittal width grading:</p> <p>0: &lt;25% of the lid wiper</p> <p>1: 25% to &lt;50% of the lid wiper</p> <p>2: 50% to &lt;75% of the lid wiper</p> <p>3: ≥75% of the lid wiper</p>
Area–density combination index <sup>583</sup>	<p>Corneal staining area scoring:</p> <p>A0: no punctate staining</p> <p>A1: <math>&gt; \frac{1}{3}</math></p> <p>A2: <math>\frac{1}{3}</math> to <math>\frac{2}{3}</math></p> <p>A3: <math>&gt; \frac{2}{3}</math></p> <p>Corneal staining density scoring:</p> <p>D0: no punctate staining</p> <p>D1: sparse</p> <p>D2: moderate</p> <p>D3: high with lesion overlap</p>
SICCA staining score <sup>584</sup>	<p>Corneal fluorescein staining scoring:</p> <p>0: 0 dots</p> <p>1: 1-5 dots</p> <p>2: 6-30 dots</p> <p>3: &gt;30 dots</p> <p>Extra points for confluent patches, staining within the pupil zone or filaments</p> <p>Conjunctival lissamine green staining scoring:</p> <p>Divided into nasal and temporal zones</p> <p>0: 0-9 dots</p> <p>1: 10-32 dots</p> <p>2: 33-100 dots</p> <p>3: &gt;100 dots</p> <p>Intraclass correlation coefficient: 0.90-0.91<sup>588</sup></p>



**TABLE 5.** Key Diagnostic Accuracy Studies Assessing the Discriminatory Performance of Ocular Surface Staining and Lid Wiper Epitheliopathy in Detecting Dry Eye Disease

Study	Methods	Outcomes
Lemp et al, 2011 <sup>222</sup>	<p>Sample size: 314</p> <p>Index tests:</p> <p>Corneal staining (NEI score)</p> <p>Conjunctival staining (NEI score)</p> <p>Reference standard:</p> <p>Composite disease severity index, derived from the TFOS DEWS severity scale (clinical signs only)</p> <p>Incorporation bias:</p> <p>Ocular surface staining formed part of both index testing and reference standard</p>	<p>Corneal staining:</p> <p>C-statistic: 0.77</p> <p>Sensitivity: 54%</p> <p>Specificity: 89%</p> <p>Conjunctival staining:</p> <p>C-statistic: 0.88</p> <p>Sensitivity: 60%</p> <p>Specificity: 91%</p>
Pult et al, <sup>540</sup>	<p>Sample size: 47</p> <p>Index tests:</p> <p>Corneal staining with fluorescein (CCLRU scale)</p> <p>Conjunctival staining with lissamine green (CCLRU scale)</p> <p>Lid wiper epitheliopathy with lissamine green (Korb grading)</p> <p>Reference standard:</p> <p>OSDI score (clinical symptoms only).</p> <p>Incorporation bias:</p> <p>None</p>	<p>Corneal staining:</p> <p>C-statistic: 0.52</p> <p>Sensitivity: not reported</p> <p>Specificity: not reported</p> <p>Conjunctival staining:</p> <p>C-statistic: 0.51</p> <p>Sensitivity: not reported</p> <p>Specificity: not reported</p> <p>Lid wiper epitheliopathy:</p> <p>C-statistic: 0.75</p> <p>Sensitivity: 48%</p> <p>Specificity: 96%</p>
Wang et al, 2019 <sup>248</sup>	<p>Sample size: 552</p> <p>Index tests:</p> <p>Corneal fluorescein staining (Oxford score)</p> <p>Conjunctival lissamine green staining (Oxford score)</p> <p>Superior lid wiper epitheliopathy (lissamine green) (Korb grading)</p> <p>Inferior lid wiper epitheliopathy (lissamine green) (Korb grading)</p> <p>Reference standard:</p> <p>TFOS DEWS II criteria (excluding staining parameters)</p> <p>Incorporation bias:</p> <p>None</p>	<p>Corneal fluorescein staining:</p> <p>C-statistic: 0.56</p> <p>Sensitivity: 25%</p> <p>Specificity: 86%</p> <p>Conjunctival lissamine green staining:</p> <p>C-statistic: 0.52</p> <p>Sensitivity: 11%</p> <p>Specificity: 94%</p> <p>Superior lid wiper epitheliopathy:</p> <p>C-statistic: 0.71</p> <p>Sensitivity: 65%</p> <p>Specificity: 73%</p> <p>Inferior lid wiper epitheliopathy:</p> <p>C-statistic: 0.69</p> <p>Sensitivity: 72%</p> <p>Specificity: 66%</p>
Wang et al, 2024 <sup>250</sup>	<p>Sample size: 2066</p> <p>Index tests:</p> <p>Corneal fluorescein staining (SICCA score)</p> <p>Conjunctival lissamine green staining (SICCA score)</p> <p>Superior lissamine green lid wiper epitheliopathy (Korb grading)</p> <p>Inferior lissamine green lid wiper epitheliopathy (Korb grading)</p> <p>Reference standard:</p> <p>TFOS DEWS II criteria (excluding staining parameters)</p> <p>Incorporation bias:</p> <p>None</p>	<p>Corneal fluorescein staining:</p> <p>C-statistic: 0.57</p> <p>Sensitivity: 38%</p> <p>Specificity: 76%</p> <p>Conjunctival lissamine green staining:</p> <p>C-statistic: 0.63</p> <p>Sensitivity: 58%</p> <p>Specificity: 64%</p> <p>Superior lid wiper epitheliopathy:</p> <p>C-statistic: 0.72</p> <p>Sensitivity: 72%</p> <p>Specificity: 66%</p> <p>Inferior lid wiper epitheliopathy:</p> <p>C-statistic: 0.71</p> <p>Sensitivity: 77%</p> <p>Specificity: 60%</p>

(continued on next page)

TABLE 5. (continued)

Study	Methods	Outcomes
Yeniad et al, 2010 <sup>585</sup>	Sample size: 86 Index texts: Fluorescein lid wiper epitheliopathy (Korb grading) Rose bengal lid wiper epitheliopathy (Korb grading) Lissamine green lid wiper epitheliopathy (Korb grading) Reference standard: OSDI score (clinical symptoms only) Incorporation bias: None	Fluorescein lid wiper epitheliopathy: C-statistic: 0.80 Sensitivity: 44% Specificity: 93% Rose bengal lid wiper epitheliopathy: C-statistic: 0.78 Sensitivity: 43% Specificity: 90% Lissamine green lid wiper epitheliopathy: C-statistic: 0.76 Sensitivity: 39% Specificity: 90%

corneal and conjunctival staining in the natural history of DED<sup>249,586</sup> and it remains uncertain whether the greater exposure to shearing and viscosity-induced hydrodynamic forces during the blink cycle might predispose the lid wiper region to earlier damage.<sup>537</sup>

**3.5.4.4 Primary inflammation/oxidative stress.** Inflammation plays an etiological role in the pathophysiology of DED.<sup>149</sup> Assessing the presence and intensity of inflammation is described as being essential to determine the severity of the disease,<sup>589</sup> the risk of progression,<sup>590</sup> and to inform its management. Inflammation at the ocular surface can be both a cause and a consequence of DED.<sup>591</sup> Ocular surface inflammation can occur due to ocular surface damage<sup>592</sup>; however, autoimmune diseases are intrinsically significant contributors to DED.<sup>593</sup> In systemic immune-mediated conditions such as Sjögren's disease, lymphocyte infiltration in the lacrimal gland can result in damage and fibrosis,<sup>594,595</sup> resulting in reduced tear secretion and elevated inflammatory cytokine levels in tears.<sup>596</sup> Therefore, the assessment of inflammation in DED frequently includes both local and systemic investigations to help elucidate the source of inflammation. As an example, it has been reported that MMP-9-positive patients respond more favorably to topical cyclosporine A than MMP-9-negative patients,<sup>597</sup> and the use of topical anti-inflammatory therapy has been associated with a reduction in HLA-DR<sup>598</sup> and MMP-9 tear levels.<sup>599,600</sup> Treatments targeting novel inflammatory pathways in DED are continuously being explored and developed,<sup>601,602</sup> although many to date have failed. Current diagnostic inflammatory tests have some limitations.<sup>603,604</sup> While image-based comparative scales and noncomparative methods based purely on clinical observation remain valid assessment tools for use in the clinic, objective conjunctival redness quantification is substantially more sensitive and reliable than subjective grading<sup>605,606</sup> and can be performed using a smartphone.<sup>607</sup> Moreover, enhancing the user-friendliness of *in vivo* confocal microscopy by developing a noncontact imaging technique with adequate resolu-

tion or offering a wider field of imaging would probably facilitate its adoption. In terms of molecular-based diagnostic tests, the lack of standardized methods for tear fluid collection and biomarker quantification,<sup>608,609</sup> as well as the absence of normal reference values,<sup>610</sup> are key aspects that can limit the accuracy, reproducibility, and overall implementation of these techniques. The cost and technical complexity of some of these diagnostic tests may also be important limitations to their implementation. However, improving clinical outcomes, avoiding unnecessary therapies, and accelerating patients' recovery not only stands to benefit patients but also to save costs.

#### 3.5.4.4.1 Imaging-based diagnostic tests

**3.5.4.4.1.1 Ocular conjunctival redness:** Conjunctival ocular hyperemia occurs with dilation of the microvasculature arising from a multitude of etiologies.<sup>606,611,612</sup> The vasodilatation of conjunctival microvessels plays a critical role in the efferent component of the immune system, providing both soluble mediators and cellular elements to the site of inflammation.<sup>613</sup> Accurate assessment of the underlying causes of conjunctival hyperemia is key in differentiating systemic causes from a localized inflammatory response.<sup>614</sup> Both descriptive<sup>615</sup> and reference image-based<sup>616-618</sup> subjective grading scales can facilitate the detection and monitoring of changes in the conjunctival microvasculature during follow-up, supporting decision-making in modifying the treatment plan. Multiple studies have shown that these scales have limited inter- and intraobserver repeatability,<sup>605,619</sup> which prompted the development of computer-based photographic analysis techniques to allow objective grading of conjunctival redness with higher precision and repeatability.<sup>605,606,620-627</sup>

**3.5.4.4.1.2 *In vivo* confocal imaging:** *In vivo* confocal imaging can aid in identifying characteristic structural changes in the cornea, conjunctiva, meibomian gland orifices, and lacrimal gland in patients with DED.<sup>330,628</sup> Conflicting findings in corneal and conjunctival epithelial cell changes in DED studies may result from DED disrupting

cell renewal, but simultaneously promoting cell repair at the same time, affecting the apoptosis–proliferation balance.<sup>629</sup>

Previous studies have reported characteristic changes in the corneal stroma of patients with DED such as a significant increase in anterior corneal stromal keratocyte density<sup>630</sup> and abnormal stromal hyperreflectivity believed to indicate increased activity.<sup>631</sup> An increase in dendritic cell density has been reported in patients with DED.<sup>630,632,633</sup> Mature and immature dendritic cells have been found in the corneal stroma of these patients.<sup>634</sup> Interestingly, increased dendritic cell density has been correlated with severe symptoms<sup>557</sup> as well as with aqueous deficient DED due to immune disease.<sup>635</sup> Dendritic cell and activated keratocyte density, as well as reduced corneal subbasal nerve fiber length, have shown an indirect association with inflammation on the ocular surface, through a significant reduction following treatment with topical corticosteroids.<sup>636,637</sup> Similarly, long-term therapy with topical cyclosporine A for more than 6 months has shown a positive impact on corneal epithelial, stromal, dendritic, and nerve confocal imaging parameters<sup>559,638</sup> (see TFOS DEWS III Digest Pathophysiology section).<sup>4</sup>

#### 3.5.4.4.2 Tear biomarker diagnostic tests

3.5.4.4.2.1 Matrix metalloproteinases: Matrix metalloproteinases (MMPs) are a family of enzymes that are core to several ocular and systemic inflammatory processes.<sup>639,640</sup> MMPs are generated by connective tissues and pro-inflammatory cells,<sup>641</sup> and can be detected in the tear fluid of patients with DED.<sup>642,643</sup> In DED, corneal epithelial damage can result in a local inflammatory reaction that leads to increased secretion of MMPs.<sup>591</sup> MMP-1, -3, -9, -10, and -13 are the MMPs most notably elevated at the corneal surface, splitting epithelial basement membrane components and tight junction proteins (such as ZO-1 and occludin) that maintain corneal epithelial barrier function.<sup>643,644</sup> Studies have reported a significant correlation between MMP-9 degree of positivity and ocular surface fluorescein staining.<sup>228,597</sup> However, tear volume has an impact on the assay indicator, and therefore, a MMP-9 test degree of positivity may not correlate as strongly with MMP-9 tear concentration in cases of either low tear volume or reflex tearing.<sup>645</sup>

3.5.4.4.2.2 Cytokines and chemokines: Measurement of cytokines and chemokines may enable differentiation of ocular surface inflammation caused through the innate immune response, and adaptive immune response (see TFOS DEWS III Digest Pathophysiology section).<sup>4</sup> Furthermore, within the adaptive immune response, these markers may separate into Th1-, Th2-, Th17-, and Treg-mediated responses.<sup>646</sup> Interferon- $\gamma$  (IFN- $\gamma$ ), the dominant cytokine associated with the Th1 response, has been associated with goblet cell loss and squamous epithelial hyperplasia. Consequently, some clinical studies demonstrated a correlation between higher IFN- $\gamma$  and tear deficiency, although other studies found contradictory results,<sup>647-649</sup> possibly due to inherent differences in

assay methods or population characteristics. IFN- $\gamma$  may be specifically associated with an increase in osmolarity.<sup>650</sup> Th17-mediated ocular inflammation may be induced through IL-17 signaling. IL-17 activates MMP-9, which contributes to damage to the corneal epithelial barrier.<sup>646,651</sup> A significant correlation between both corneal and conjunctival staining scores and the presence of Th cells has been reported, although Th subtypes such as Th1 and Th17 were not detectable at high enough levels for establishing correlations with tear film stability and volume in patients with DED.<sup>652</sup> In addition, no correlation was found between DED and the detection of IL-1 $\beta$ , IL-6, IL-8, IL-10, IL-17A, IFN $\gamma$ , and tumor necrosis factor- $\alpha$  (TNF- $\alpha$ ) in tears,<sup>653</sup> although cytokine upregulation has been detected in patients with Sjögren's disease.<sup>654</sup> However high MMP levels are found in patients with DED,<sup>655</sup> likely from episodic flares,<sup>656</sup> and MMPs have been found to correlate with osmolarity and tear volume, more strongly than with tear film stability and symptoms.<sup>657</sup> The variable nature of cytokine levels and DED corresponds to the heterogeneous nature of ocular surface inflammation,<sup>658-660</sup> changes over time,<sup>661</sup> and the location of sampling.<sup>662</sup> This lends support to current understanding that inflammation is more often downstream (a consequence) rather than intrinsic (a driver) in DED (see TFOS DEWS III Digest Pathophysiology section).<sup>4</sup>

3.5.4.4.2.3 Neurotrophic factors and neuropeptides: Neuropeptides and neurotrophic factors have a role in mediating sensory information and in regulating aspects of neuronal function and cell survival.<sup>649</sup>

Serotonin, which is a peripheral nerve sensitizer, is found at a higher concentration in tears of patients with DED than in those of normal eyes, and correlates with symptoms.<sup>663</sup> Serotonin is activated by inflammation and sensitizes peripheral nerves, perhaps playing a role in the development of corneal hypersensitization in DED.<sup>664</sup> Increased nerve growth factor has a protective role in DED, improving the integrity of the epithelial cell layer and tear secretion.<sup>665,666</sup> Lacrimal gland dysfunction has been associated with decreased calcitonin gene-related peptide.<sup>665,666</sup> Substance P has been found to be raised in tears of DED patients after refractive surgery,<sup>667</sup> and nerve growth factor has also been found to be raised in the tear fluid of patients with neuropathic pain.<sup>668</sup> Hence these neurotrophic factors and neuropeptides appear to regulate tear aqueous production such that they may indicate a strategy for improving tear secretion in DED where specific deficiencies are identified.

3.5.4.4.2.4 Ocular surface immune markers: Major histocompatibility complex-based markers have long been identified as a risk factor for DED, particularly in the case of Sjögren's disease.<sup>669,670</sup> Antigen presentation through the major histocompatibility process seems to play an intermediary role in T-cell activation and the cytokine-based inflammatory cascade.<sup>646</sup> While both major histocompatibility complex class I and class II have been connected

to inflammation in DED, HLA-DR, a member of the class II family, has been more thoroughly investigated.<sup>671,672</sup> A gene expression analysis of mRNA transcripts observed from conjunctival impression cytology sampling discovered a correlation between HLA-DR, CD40, and IFN. This connection further links inflammatory DED with T-cell activation.<sup>671</sup> Conjunctival impression cytology samples collected on a heterogeneous group of patients with DED revealed that the percentage total cells expressing HLA-DR was positively correlated with conjunctival and corneal staining scores<sup>672</sup> and weakly with tear volume<sup>673</sup>. Although HLA-DR percentage analysis was not a sensitive diagnostic marker for DED in itself, it may represent a means of helping to identify specific dry eye subtypes based on the lymphocytic response responsible for the ocular surface inflammation in a particular patient, and guiding therapeutic decisions. Neutrophils, macrophages, mast cells, T cells, and dendritic cells have been found to increase in DED across several studies, particularly at more severe levels of dry eye found in autoimmune disease such as Sjögren's disease and graft-versus-host disease.<sup>674</sup>

**3.5.4.4.2.5 Inflammasome markers:** The inflammasomes are innate immune system sensors that induce an inflammatory form of cell death, known as pyroptosis, in response to harmful stimuli such as pathogens or oxidative stress, among others<sup>675,676</sup> (see TFOS DEWS III Digest Pathophysiology section).<sup>4</sup> Reactive oxygen species are involved in the pathogenesis of DED,<sup>677</sup> and have been suggested as a priming signal for inflammasome activation.<sup>602</sup> NOD-like receptor protein-3 (NLRP3) inflammasome, a key driver in the innate immune system, has a role in DED pathogenesis,<sup>677,678</sup> is upregulated in the tear fluid in Sjögren's disease,<sup>678</sup> and is activated by hyperosmolarity.<sup>677,679</sup> Tear levels of caspase-1, a molecule involved in the inflammasome cascade, and various clinical signs of ocular surface damage in patients with DED and patients using topical glaucoma medications have been found to be correlated.<sup>680</sup> Moreover, tear levels of gasdermin-D, a pyroptosis executor, are also elevated in patients with DED.<sup>681</sup>

**3.5.4.4.2.6 MicroRNAs:** MicroRNAs are noncoding RNAs that serve as significant regulators in a variety of molecular pathways<sup>682</sup> (see TFOS DEWS III Digest Pain and Sensation section).<sup>4</sup> Several studies have identified tear microRNAs as potential biomarkers for ocular diseases, including Sjögren's disease<sup>683</sup> and DED,<sup>684-686</sup> among others.<sup>608,687</sup> Nine tear microRNAs (miR-127-5p, miR-1273h-3p, miR-1288-5p, miR-130b-5p, miR-139-3p, miR-1910-5p, miR-203b-5p, miR-22-5p, and miR-4632-3p) associated with inflammation have been found to be upregulated in the tear fluid of patients with DED.

**3.5.4.4.2.7 Oxidative stress markers:** Oxidative stress, an imbalance of free radicals and antioxidants that leads to cell damage, may play a role in the pathogenesis of DED.<sup>688</sup> Proteomic analysis of tears from patients with DED shows an upregulation of proteins associated with oxidative stress injury.<sup>689</sup> It is well established that oxida-

tive damage triggers an inflammatory response, resulting in ocular surface dysfunction.<sup>690-692</sup> Moreover, oxidative stress may cause the progression of DED by exacerbating inflammation by triggering the vicious cycle of DED. Oxidative stress biomarkers, which indicate the degree of oxidative stress, have been found to be elevated in tear fluid and the conjunctiva of patients with DED.<sup>693</sup> The detection of oxidative stress biomarkers through tear fluid or conjunctival impression cytology samples may be undertaken to evaluate DED status, to monitor the efficacy of drugs, or to evaluate disease progression. Oxidative markers such as lactoferrin (tears), peroxiredoxin 2 (tears), SOD (tears), CAT (tears), and GSH-Px (tears) are downregulated in DED.<sup>689,694</sup> In contrast, markers such as S100A8 (tears), S100A9 (tears), reactive oxygen species (conjunctiva), LPO (conjunctiva), 4-HNE (conjunctiva), MDA (conjunctiva), and HEL (tears) are upregulated in these patients.<sup>692,695-698</sup> A correlation between ocular surface oxidative stress markers and topical treatments has been described by several author groups,<sup>696,699,700</sup> indicating the utility of these markers in monitoring response to antioxidant therapies.

**3.5.4.4.2.8 Serum markers:** DED is associated with chronic inflammatory systemic conditions including collagen vascular diseases,<sup>701</sup> rheumatoid arthritis,<sup>702</sup> and Sjögren's disease,<sup>703</sup> among others.<sup>704</sup> Acute phase reactants such as erythrocyte sedimentation rate and C-reactive protein indicate active systemic inflammation.<sup>705</sup> However, previous studies found that levels of these reactants do not correlate with ocular surface symptoms or tear parameters in DED,<sup>701,706</sup> although serum inflammatory markers PM-Sc1100 and Sm were associated with more severe DED symptoms, while inflammatory markers U2SnRNP A', Ro52, La, DNA, and Ro60 were associated with more severe ocular surface disease signs.<sup>707,708</sup> Other serum inflammatory-related markers such as antinuclear antibody and IL-2 receptor(sIL-2R), or anti-double-strand DNA antibody, have been associated with DED in primary Sjögren's disease<sup>709,710</sup> or systemic lupus erythematosus.<sup>701</sup> Similarly, serum levels of IL-17, a proinflammatory cytokine,<sup>711</sup> are significantly increased in patients with DED and high fluorescein staining scores.<sup>712</sup> S100A8/A9 and granulysin have been found to be higher in more severe dry eye secondary to Stevens-Johnson.<sup>713</sup> In addition, in a large population-based study, decreased serum androgens were found to be highly associated with DED diagnosis and symptoms.<sup>714</sup> (Table 6)

### 3.5.5 Systemic diseases leading to dry eye

Many systemic diseases significantly contribute to DED through inflammation, autoimmunity, metabolic dysregulation, and ocular surface exposure. Interdisciplinary collaboration in the management of DED patients with underlying systemic conditions is important, such as coordinating care with rheumatologists, endocrinologists, or other relevant specialists to optimize both ocular and systemic outcomes.



**TABLE 6.** Subclassification of Dry Eye Disease Etiological Drivers: Recommended Tests and Cut-Offs (where available)

		Standard Testing	Advanced Testing
Tear Film Deficiencies	Lipid	Interferometry: grade $\leq 3$ (non-amorphous or colored pattern) or $<72$ nm on LipiView <sup>197,320,343</sup> Meibum expressibility/quality: meibum not clear or limited expressibility <sup>332,371,715</sup>	
	Aqueous	Meniscometry: tear meniscus height $\leq 0.20$ mm <sup>39,320,380</sup>	Strip meniscometry: $\leq 2.5$ mm wetting length <sup>404-406</sup> Tear proteins and other chemical components testing
	Mucin/glycocalyx	Rose bengal or lissamine green staining: $>9$ punctate spots <sup>581</sup>	Immunohistochemistry and immunoelectron microscopy of tear fluid Impression cytology: goblet cell density and epithelial cell morphology
Eyelid Anomalies	Blink/lid closure	Partial blinking observation: $>40\%$ occurrence <sup>463</sup> Lagophthalmos/inadequate lid seal: observed	
	Lid margin	Anterior blepharitis observation MGD Keratinization Ocular rosacea	Meibography: gland length $<75\%$ <sup>320,372,509</sup> Gland plugging: observed <sup>715</sup> Telangiectasia: observed <sup>715</sup> Gland expressibility Slitlamp biomicroscopy Slitlamp biomicroscopy
Ocular Surface Abnormalities	Anatomical misalignment	Slit-lamp biomicroscopy	Corneal topography
	Neural dysfunction	Sensation to puff or physical contact: corneal and lid margin sensitivity thresholds $\geq 0.8$ mbar, <sup>550</sup> although instruments are not interchangeable <sup>716</sup>	<i>In vivo</i> confocal microscopy: normative values available for nerve length, branch, and density metrics <sup>717</sup>
	Ocular surface cellular damage/disruption	Corneal fluorescein staining: $>5$ punctate spots <sup>250,581</sup> Conjunctival lissamine green staining: $>9$ punctate spots <sup>250,581</sup> Lid wiper staining: $>2$ mm length and 25% width <sup>250</sup>	
	Primary inflammation/oxidative stress	Bulbar conjunctival hyperemia: $>1.5$ Efron scale or $>0.95$ objective JENVIS <sup>604</sup>	<i>In vivo</i> confocal microscopy Tear fluid and ocular surface cell molecular testing
Systemic Drivers	Check for systemic conditions		

**3.5.5.1 Autoimmune conditions.** Systemic inflammatory diseases such as rheumatoid arthritis, systemic lupus erythematosus, Stevens–Johnson syndrome, and Sjögren’s disease are closely associated with DED. Chronic inflammation leads to the infiltration of immune cells in the lacrimal gland, reducing tear production and altering tear film composition.<sup>718</sup> Key inflammatory cytokines include IL-1, tumor necrosis factor- $\alpha$  (TNF- $\alpha$ ) and MMPs.<sup>719</sup> Patients with ankylosing spondylitis treated with tumor necrosis factor inhibitors showed improvement in clinical and laboratory disease parameters, tear production, DED severity, and impression cytology scores, suggesting that tumor necrosis factor inhibitors may restore lacrimal gland acinar cells affected by proinflammatory cytokines.<sup>720</sup> In rheumatoid arthritis, the activation of the NF- $\kappa$ B pathway and over-

expression of TNF- $\alpha$  and IL-6 lead to systemic and ocular inflammation.<sup>721</sup> The full potential of TNF- $\alpha$  inhibitors to reduce ocular surface inflammation and to improve tear production in rheumatoid arthritis remains uncertain.<sup>722,723</sup>

Autoimmune diseases, particularly Sjögren’s disease, share a close association with DED. Sjögren’s disease involves lymphocytic infiltration of exocrine glands, affecting the production of aqueous tears and saliva, respectively, and leading to dry eye and dry mouth. Detection of antibodies, such as anti-Ro/SSA and anti-La/SSB, support its autoimmune nature.<sup>724</sup> Gene analysis of conjunctival imprints revealed 53 differentially expressed genes in Sjögren’s disease patients compared to healthy controls, which indicated immune activation in patients with Sjögren’s disease.<sup>725</sup> Higher percentages of antigen-presenting cells and

mature dendritic cells in the conjunctiva are associated with more severe dryness secondary to aqueous deficiency in Sjögren's disease, which may contribute to goblet cell loss.<sup>726</sup>

Multidisciplinary treatment for both the underlying systemic disease as well as managing the residual ocular symptoms of DED is generally appropriate. In rheumatoid arthritis, for example, disease-modifying antirheumatic drugs such as methotrexate and biologics such as tumor necrosis factor inhibitors help control systemic inflammation and improve ocular symptoms.<sup>721</sup>

**3.5.5.2 Hormonal imbalance.** Hormonal changes can trigger DED by affecting tear production and quality, especially in women who experience hormonal fluctuations throughout their lives.<sup>727</sup> Hormonal imbalance and its management in patients with DED is covered in the TFOS DEWS III Digest.<sup>4</sup>

**3.5.5.3 Metabolic disease.** Metabolic diseases such as diabetes mellitus significantly impact the ocular surface and can lead to DED.<sup>4,7</sup> Hyperglycemia and advanced glycation end-products contribute to microvascular damage and neuropathy, affecting the lacrimal glands and corneal nerves.<sup>728</sup> Patients with diabetes often exhibit reduced tear secretion, increased tear osmolarity, and altered corneal sensitivity.<sup>729</sup> Antioxidant therapy, along with strict glycemic control, can mitigate the effects of diabetes on the body<sup>730</sup> and the ocular surface.<sup>731,732</sup> The impact of medications and procedures related to managing metabolic disease on the ocular surface are covered in the TFOS Lifestyle reports.<sup>7,9</sup>

**3.5.5.4 Exposure.** A multitude of diseases as well as trauma can cause intermittent (for example, nocturnal) or constant lagophthalmos (such as facial nerve palsy), leading to exposure of the ocular surface and DED.<sup>733</sup> A number of these conditions and the impact of medications and procedures related to ocular exposure on the ocular surface are covered in the TFOS Lifestyle reports.<sup>9,12</sup>

• **3.6 TESTS FOR MONITORING TREATMENT:** In monitoring treatment effects over time, it is important to consider indicators that may lag (such as corneal staining<sup>749</sup>), those that respond more rapidly (such as symptomology), and the treatment's mechanism of action.<sup>734</sup> It is therefore recommended that practices adopt a standardized, reproducible, and repeatable DED protocol that involves validated questionnaires, diagnostic tests, and clinical examination that remains consistent from visit to visit. While every real-life patient encounter will undoubtedly not be as clear-cut, clinicians are encouraged to make diagnostic and treatment decisions based on scientific evidence and on tracking subjective and objective data over time, and with the aid of clinical judgment, experience, and acumen, as outlined in this report.

As the number of testing options increases, the volume of clinical data that is required to be processed at each patient visit also increases and can, at times, seem overwhelming. This becomes increasingly challenging as physician time becomes progressively constrained and face-to-face consultation times are shortened. With handwritten paper records, processing diagnostic data trends over long periods of time encompassing multiple office visits was challenging, time consuming, and rarely undertaken thoroughly. However, in the current electronic medical record era, the ability to seamlessly and instantaneously process, summarize, plot, and chart large volumes of disparate diagnostic data over long periods of time is much easier to facilitate. DED/ocular surface disease-specific electronic medical record platforms are now available and enhance the ability to track and monitor DED symptoms, objective tests, examination findings, and treatment outcomes,<sup>735</sup> as well as real-world registries, which also provide the facility to monitor patient progress and benchmark against peers.<sup>736</sup> Additionally, with the ubiquity of smartphones and the burgeoning emergence of smart glasses and wearable health monitors/sensors, there is unprecedented potential for gathering and analyzing real-time continuous data in-between office visits data.<sup>292,737-739</sup> Machine learning and artificial intelligence (see Section 5.1), when integrated into electronic medical record platforms and smart devices, with access to process reliable data from disparate physicians, practices, and geographic locations, may possibly provide novel insights into DED that are as yet unknown, facilitating more accurate diagnoses, better treatments, and more strategic clinical trial designs.<sup>740</sup> With the assistance of machine learning and artificial intelligence, historically challenging diagnoses such as neurotrophic keratopathy and neuropathic corneal pain will likely be made earlier, with the potential to improve patient outcomes and reduce late-stage sequelae.

---

## 4 PATIENTS WITH ONLY SYMPTOMS OR OCULAR SURFACE SIGNS

There are numerous explanations highlighted in Section 3.3.3 for the often-vexing clinical scenario of discordant signs and symptoms. Significant corneal staining in a pain-free patient, colloquially referred to as “stain without pain,” may indicate neurotrophic keratopathy.<sup>741</sup> Conversely, when the clinical signs of ocular surface dysfunction are mild or subtle in the absence of patient-reported symptoms, it might indicate an early, preclinical, or situational DED.<sup>155</sup> In the extreme, a clinical scenario involving significant symptomology in the absence of, or out of proportion to, clinical signs, colloquially referred to as “pain without stain,” might be indicative of neuropathic corneal pain.<sup>175</sup>

• **4.1 OCULAR SURFACE DISEASE IN THE ABSENCE OF SYMPTOMS:** It is recommended to treat any significant oc-

ular surface disease prior to a patient undergoing any type of eye surgery (such as laser vision correction or cataract removal), initiating contact lens wear, starting any high-risk topical or systemic medications, and/or any other intervention known to cause or exacerbate DED (see TFOS DEWS III Digest Iatrogenic section).<sup>4</sup> The surgical informed consent process should include a discussion of the risk of worsening signs and/or symptoms of DED, including visual symptoms, which may require intensive long-term treatment to control. The importance of identifying, offering education about, and treating early preclinical DED/ocular surface disease is particularly critical in the setting of refractive, cataract, or laser vision correction surgery, for which patient expectations tend to be particularly high.<sup>742</sup>

There is a high prevalence of ocular surface disease in presurgical cataract patients, many of whom have few or no reported symptoms.<sup>743,744</sup> It is speculated that the stark disconnect between signs and symptoms in this older population is due to a combination of generational stoicism, inherent bias to focus on the perceived “bigger” problem (for example, their poor vision due to cataract), and/or age-related reductions in corneal nerve density and sensation.<sup>152,153,165,167,171,745</sup> In the younger patient population, contact lens intolerance from DED is a common reason for seeking laser vision correction surgery,<sup>746</sup> but can also place the patient at higher risk of postsurgical complications if not identified, discussed, and managed preoperatively.

Many studies have shown that DED, especially when significant corneal staining is present, can adversely affect the accuracy of preoperative measurements (such as keratometry, topography, optical pachymetry, and aberrometry), potentially leading to postsurgical refractive error inaccuracy, poor and/or fluctuating visual quality (especially when multifocal or extended-depth-of-focus intraocular lenses are implanted), and lowered patient satisfaction.<sup>28,747-751</sup> Due to the high prevalence of ocular surface disease in this patient population, an algorithm has been designed by the American Society of Cataract and Refractive Society to help identify and treat visually significant ocular surface disease preoperatively.<sup>752</sup>

#### 4.1.1 Diagnosing ocular neurosensory abnormalities

A medical history questionnaire or intake form should include often-missed non-ophthalmic risk factors for neurotrophic keratopathy (diabetes, herpes, Parkinson disease, multiple sclerosis, prior brain surgery such as acoustic neuroma, cerebrovascular accidents, and congenital dysautonomia) and for neuropathic corneal pain (such as small-fiber peripheral neuropathies, fibromyalgia, migraine, irritable bowel, anxiety, depression, and posttraumatic stress disorder).<sup>753</sup> Clinical suspicion for neurosensory abnormalities should be raised in any patient with marked discordance of signs and symptoms, risk factors, and/or positive answers to targeted triaging questions. Corneal surgical incisions, laser

corneal ablation, suction prior to flap creation by microkeratome or femtosecond laser, phototoxicity from the operating microscope, and benzalkonium chloride–preserved postoperative drops, among other factors, can exacerbate pre-existing or induce new corneal neurosensory abnormalities, potentially leading to visually significant postoperative ocular surface disease.<sup>9,33,107,754-761</sup>

#### 4.1.2 Diagnosing neurotrophic keratopathy

Neurotrophic keratopathy is considered a rare disease, but is likely underdiagnosed.<sup>762</sup> It is caused by a unilateral or bilateral abnormality of the trigeminal nerve, resulting in decreased or absent corneal sensation, and leading to diffuse corneal punctate epithelial defects (Mackie stage 1), persistent epithelial defects with characteristic smooth rolled edges (stage 2), and stromal melting with the potential for corneal perforation (stage 3).<sup>763,764</sup> A more nuanced and detailed 6-stage grading system has recently been proposed by a Neurotrophic Keratopathy Study Group to better delineate the stages of progression and to allow practitioners to identify neurotrophic keratopathy at earlier stages.<sup>741</sup> Because early stages of neurotrophic keratopathy can involve corneal epitheliopathy with staining, increased mucous viscosity, and decreased tear film stability, it is often misdiagnosed and treated as moderate-to-severe DED. The pattern of corneal staining in neurotrophic keratopathy is often diffuse, involving the entire cornea, in contrast to the inferior or interpalpebral staining typically seen in DED.<sup>551,765</sup> Patients with neurotrophic keratopathy will also typically have lower blink rates and poorer blink quality,<sup>762</sup> whereas patients with DED and poor blink quality tend to blink more frequently.<sup>766</sup> Patients with neurotrophic keratopathy typically do not self-report symptoms of pain or discomfort, which appears inconsistent with the level of corneal staining, but they may complain about reduced visual acuity, quality, stability, and performance. This clinical scenario of “stain without pain” should alert clinicians to suspect the possibility of neurotrophic keratopathy as early as possible, prior to the patient failing long-term DED treatment, and, ideally well before potentially blinding corneal stromal breakdown occurs in later stages.

Reduced or absent corneal sensitivity is suggestive of neurotrophic keratopathy, and therefore corneal sensation should be assessed as soon as there is clinical suspicion and prior to instillation of anesthetic drops. Various methods are available for assessing corneal sensitivity. The Cochet–Bonnet esthesiometer is quantitative and makes contact with the ocular surface, while the gas esthesiometers are quantitative, non-contact, and able to assess chemical, thermal, and/or mechanical corneal sensitivity.<sup>716,767-770</sup> Both are commonly used in research and in specialty referral centers, but historically have been costly and impractical for most general eyecare practitioners. Less expensive and simpler methods involving contact with the eye’s surface that are commonly used in practice include testing sensation to a wisp from a cotton-tipped applicator, a cor-

ner of a disposable facial tissue, and/or unwaxed and unflavored dental floss as a quick qualitative assessment of the presence of corneal sensation in a primary eyecare setting.<sup>741</sup> A patient with normal sensation will blink and report discomfort when the central cornea is touched; a patient with a hypoesthetic cornea may blink but not report sensation; and a patient with an anesthetic cornea typically will not register a blink or any sensation in response to the stimulus.<sup>741</sup> A modified-Delphi expert panel on neurotrophic keratopathy strongly recommended corneal sensitivity testing for persistent epithelial defects after 14 days, for new painless epithelial defects, a history of herpetic eye disease, or procedures that may injure the trigeminal nerve, and for pain in an eye with multiple concurrent risk factors for neurotrophic keratopathy such as poorly controlled diabetes and either reduced blink rate or a history of corneal surgery.<sup>771</sup> As more modalities for non-contact, reproducible, quantifiable, and inexpensive esthesiometry become available,<sup>769,772-774</sup> corneal sensation assessment can be performed earlier in the diagnostic subtyping process and can ideally be incorporated into office-based routine DED/ocular surface disease protocols (see Section 6.1).

Once clinical suspicion for neurotrophic keratopathy and reduced corneal sensation are identified, further investigation with corneal *in vivo* confocal microscopy can be diagnostically confirmatory (see Sections 3.5.3.6.1.2 and 3.5.3.4). Studies have consistently demonstrated significant alterations in the corneal nerves, epithelial cells, and corneal stroma in patients with neurotrophic keratopathy.<sup>775-778</sup> Of note, corneal sensation may remain relatively normal despite significant reductions (of 50%-80%) in subbasal nerve density, accompanied by morphological changes such as increased tortuosity and beading,<sup>779</sup> and may be clinically detectable only when the nerve density drops below 1000  $\mu\text{m}$  nerve length per frame.<sup>780,781</sup> Epithelial abnormalities include enlarged and irregular cell shapes, decreased cell density, and squamous metaplasia correlating with disease severity.<sup>780,781</sup> Severe disorganization, altered keratocyte morphology, and presence of hyperreflective cells can be observed in stage 3, along with increased dendritiform cell density, particularly in the central cornea, suggesting a possible inflammatory component.<sup>782</sup> Substantial reductions in sub-basal nerve density are commonly seen in patients with neurotrophic keratopathy secondary to herpetic eye disease.<sup>777,778,781</sup> Interestingly, patients with unilateral herpes simplex and zoster ophthalmicus may exhibit contralateral reductions in sub-basal nerve density.<sup>67,780</sup>

• **4.2 SYMPTOMS IN THE ABSENCE OF OCULAR SURFACE DISEASE:** Unlike nociceptive pain that involves the triggering of nociceptors from local tissue damage, neuropathic pain, which can be peripheral or central in origin, is caused by an abnormality in the somatosensory nervous system.<sup>783</sup> Diagnosing neuropathic corneal pain is primarily clinical and exclusionary and is based heavily on clinical history,

risk factors, and discordance in terms of the level of symptoms in the absence of corresponding clinical signs, colloquially termed “pain without stain.”<sup>784</sup> While DED is commonly the initial diagnosis and treatment target for many of these patients, neuropathic pain does not respond to conventional treatments in the same way, and artificial tears do not provide the same temporary symptom relief.<sup>785</sup> DED and neuropathic corneal pain can coexist, requiring treatment for both. Indeed, DED may have been the trigger, leading to neuropathic corneal pain, often in patients with comorbid chronic pain (such as migraine and fibromyalgia) or psychiatric and/or mental health disorders.<sup>175,786,787</sup> Patients with Sjögren’s disease also have a higher risk of chronic ocular pain with neuropathic features.<sup>788</sup> Other risk factors and associated comorbidities of neuropathic ocular pain include DED, diabetes, sarcoidosis, small-fiber neuropathies, herpetic eye disease, prior eye surgery, infection, trauma, contact lens wear, and radiation keratopathy, and many of these overlap with risk factors for neuropathic keratopathy.<sup>789</sup> An association with long COVID has also been identified.<sup>790,791</sup> To confound the inherent diagnostic challenges even further, a subset of patients with stage 1 neurotrophic keratopathy and concomitant neuropathic corneal pain has also been reported.<sup>792</sup> If neuropathic corneal pain is suspected on the basis of clinical history, symptoms, and a lack of signs on examination, a pain-specific validated questionnaire such as the Ocular Pain Assessment Survey or the Neuropathic Pain Symptom Inventory, which has been modified for the eye, can be used to score symptoms.<sup>793,794</sup>

#### 4.2.1 Diagnosing corneal neuropathic pain

If the patient’s eyes are painful despite lubricating drops and the pain is incited by light, wind, or other triggers, neuropathic corneal pain should be suspected. In such a situation, a proparacaine challenge test can be performed to aid in both diagnosis and differentiation between peripheral and central etiologies.<sup>789,795,796</sup> If the pain is completely ameliorated by an anesthetic drop, the patient likely has peripheral or nociceptive corneal pain, whereas if the pain persists unchanged afterward, then a central neuropathic pain mechanism is likely; if only partial relief is achieved, then a mixed mechanism of peripheral and central neuropathic corneal pain is likely.<sup>795</sup> Differentiating peripheral from central neuropathic corneal pain is important, as the treatment strategies differ significantly between the two.<sup>797,798</sup> While corneal esthesiometry is a critical test for neurotrophic keratitis, it is less useful in the workup of neuropathic corneal pain, as studies have revealed both higher and lower sensitivities in these patients and overall poor diagnostic correlation,<sup>152,796,799,800</sup> although more objective, non-contact techniques may offer some promise in identifying neuropathic pain.<sup>769</sup> Reduced density of sub-basal nerves is a finding common to both neurotrophic keratitis and neuropathic corneal pain, but the increased presence of sub-basal and stromal microneuromas, detectable by con-



focal microscopy, is more common in neuropathic corneal pain.<sup>168,169,566,567,801</sup> Further studies are needed to establish whether confocal microscopy can be used reliably for differentiating the etiological drivers in a patient with DED.

## 5 FUTURE ADVANCES

• **5.1 ARTIFICIAL INTELLIGENCE:** Artificial intelligence, a term coined by emeritus Stanford Professor John McCarthy in 1955, was defined by him as “the science and engineering of making intelligent machines.” A wide range of definitions have now been proposed, making it difficult to assess claims on its use. It has been suggested that it is already widely used in DED clinical tests and research,<sup>802</sup> but it could be argued whether an algorithm to detect a change in pixel contrast or an “edge” of a Placido ring is truly “intelligence.” Machine learning thorough training has been used to try to predict video frames that a specialist identified as showing breakup, with a sensitivity of 78% and specificity of 86%.<sup>803</sup> There is the potential that machine learning could make a clinical test used in the diagnosis of dry eye more objective, but as such a diagnosis would require a gold standard disease group against which to compare the individual, and a consensus of which tests are the most suitable to identify this group based on available evidence. Along with practical considerations such as cost and equipment availability this presents challenges, as artificial intelligence cannot in itself drive development or change in the diagnostic algorithm for dry eye. It certainly can aid in image analysis, however, and particularly structural segmentation such as in meibography.<sup>804-809</sup> Rating of corneal fluorescein staining, on the other hand, remains more challenging.<sup>810</sup> Potential barriers to widespread adoption of artificial intelligence include cost, accessibility, regulatory and ethical considerations, training requirements, and integration with existing diagnostic protocols.<sup>811</sup>

• **5.2 TEAR BIOMARKER TESTING OF TEARS:** MMPs are one of many classes of proteases secreted into the tears in DED. Since MMPs can destroy tight junctions in the ocular surface epithelium, increased levels of MMPs reflect loss of ocular surface barrier function.<sup>812-814</sup> MMPs are produced as inactive proenzymes and can be cleaved to become active enzymes.<sup>815</sup> It is therefore important for future MMP tests to detect enzyme activity levels and not simply total tear protein levels. MMP-9 is detected more commonly in severe DED and has been proposed as a potential means of monitoring the success of DED management; patients with a positive MMP-9 test showed a greater benefit from topical cyclosporine A than those whose tests were MMP-9 negative.<sup>597</sup> A silicon nanowire-based field-effect transistor MMP-9 tear film biosensor was found to have a sensitivity of 87% and specificity of 90% for DED.<sup>816</sup> More advanced point-of-care tear proteomic test kits for identifying DED

subtype drivers are needed, along with independent validation/replication studies.

Lymphotoxin- $\alpha$  (LT- $\alpha$ ), a member of the tumor necrosis factor superfamily, is expressed by T cells, B cells, and natural killer cells, playing a crucial role in immune system development and function<sup>817-819</sup>; this includes the formation of lymphoid organs, maintenance of lymphatic microenvironments, host defense, and modulation of inflammation. Despite its established association with inflammation, emerging research has identified a negative correlation between LT- $\alpha$  levels in the blood and fatigue symptoms (often linked to proinflammatory processes) in patients with primary Sjögren’s disease.<sup>820,821</sup> This suggests that the role of LT- $\alpha$  in inflammation might be more complex than previously thought. Levels of multiple tear protein markers (TNF- $\alpha$ , IL-10, IL-1 $\beta$ , IL-1Ra, IL-17A, and IL-12/23 p40) were elevated in patients with DED with high LT- $\alpha$  ( $>700$  pg/mL) compared to those in patients with lower LT- $\alpha$  ( $\leq 700$  pg/mL), indicating possible differences in pathogenesis.<sup>822</sup>

• **5.3 SUSTAINABILITY:** To date, there has been a significant paucity of literature examining the sustainability implications of diagnostic testing and practices for DED.<sup>823</sup> Future research is required to characterize the potential sustainability implications, environmental effects, and carbon footprint of the production, use, and disposal of different types of diagnostic instruments, dyes, consumables, treatments, and packaging.

• **5.4 NEED FOR EXPERIENCE-INFORMED APPROACH TO UNRESEARCHED OR UNDERRESEARCHED AREAS:** Where research on best practice is limited, conflicting, or logistically or ethically difficult to obtain, a group process using collective intelligence may help.<sup>824</sup> This can, for example, be applied to achieve consensus on the best clinical criteria for diagnosis or to initiate treatment.<sup>825</sup> The Delphi technique is a systematic process designed to establish consensus in a group of experts. A series of questionnaires is distributed, and controlled feedback with group statistical responses is given each time, until answers are converged and a predefined criterion is reached to bring the process to a close. Important aspects, in order to obtain valid outcomes, include systematic identification of the problem area, the selection of panel members based on objective and predefined criteria, anonymity of panelists and responses, controlled feedback, and stability of results including a predefined closing criteria.<sup>824</sup>

A Delphi approach has been used to define ocular surface disease activity and damage indices.<sup>826</sup> Several Delphi or other group process approaches have been conducted in the past 2 decades to establish a best practice on a diagnostic aspect of DED and blepharitis. The ODISEY European Consensus group defined a 2-step scoring algorithm for diagnosing DED, but only at a severe level. Symptom-based assessment and corneal fluorescein staining were con-

sidered to be the two most important criteria. In case of discordance between these two tests, identification of additional criteria was recommended.<sup>827</sup> Separately, the DIDA-TIC study used a Delphi approach to categorize signs and symptoms to identify DED pathophysiology. A total of 19 items were deemed indicative of evaporative dry eye, and 12 items of aqueous-deficient DED.<sup>323</sup> Using nominal group and Delphi techniques, a group of Italian ophthalmologists reached consensus on criteria for classification of DED. Three types were classified: a transient and reversible form, a recurrent form, and a chronic form, each with its own clinical characteristics.<sup>828</sup> Recent industry-sponsored Delphi panels on *Demodex*-associated blepharitis achieved consensus on it being chronic and recurrent,<sup>486</sup> with the presence of cylindrical dandruff at the base of the eyelashes, visible *Demodex* mites, lid margin telangiectasia, and a previous history of anterior blepharitis not responding to treatment being proposed as the most indicative independent signs.<sup>485</sup> Cylindrical dandruff is considered pathognomonic of *Demodex* blepharitis, with the suggestion that patients with >10 collarettes should be treated even in the absence of symptoms, and that treatment efficacy can be tracked by the extent of cylindrical dandruff resolution.<sup>829</sup>

Examples of areas in the field of diagnostic methodology of DED that lack scientific evidence and could benefit from a future Delphi approach include:

- how DED severity should be graded
- whether site-specific itch is useful in differentiating dry eye from allergy
- what cut-offs should be used for etiological drivers where current evidence-based diagnostic thresholds do not exist
- the best practices (e.g. sequence, timing and dose) surrounding fluorescein and lissamine green staining of the ocular surface.

## 6 SUMMARY

A standardized approach is vital to providing robust epidemiological information on DED in the future.<sup>4</sup> It is critical that all practitioners and researchers adopt the same approach for the field to move forward for the benefit of patients.

• **6.1 WORKFLOW AND ENHANCED LINK TO INDIVIDUALIZED MANAGEMENT:** In patients who identify dryness type symptoms, the OSDI-6 screening questionnaire should be used to quantify these (see Section 3.3.2; [Figure 4](#)) and a score of  $\geq 4$  used as a prompt for further investigation. Risk factors should be explored (see Section 3.2; [Figure 3](#); [Table 1](#)) and a differential diagnosis conducted (see Section 3.1; [Figure 2](#)). If the practitioner lacks the expertise and access to instrumentation to facilitate a detailed examination of the eye, the triaging questions (see Section 3.1.5)

**TABLE 7.** Example of a Test Sequence (From Least to Most Invasive) to Diagnose (Second Column) and Identify the Drivers (Subtypes: Third Column) of Dry Eye Disease Based on Key Tests/Observations in the Same Appointment

Sequence	Diagnosis	Subtype Drivers
1	Symptoms Screening: OSDI-6	
2		Blink/lid closure: rate/completeness/lid seal
3		Aqueous: tear meniscus height (using infrared illumination)
4	Non-invasive tear breakup time	
5		Anatomical lid/globe misalignment: features such as pterygia
6		Inflammation: redness
7		Lipid: interferometry
8	Osmolarity	
9		Lid margin: eyelashes, lid margin, diagnostic expression
[10]	[Fluorescein tear breakup time]	
11	Ocular surface staining	Ocular surface damage: corneal, conjunctival and lid wiper staining Mucin: conjunctival staining Lid margin: keratinization staining
12		Lid margin: meibography
13		Neural dysfunction: corneal nerves/sensation (if contact methods are used)

will help to identify patients for whom referral is appropriate. Diagnosis of DED requires evaluation of ocular surface staining (including the cornea, conjunctiva, and lid margin) along with tear film instability and/or hyperosmolarity ([Figure 5](#)), and the criteria met by demonstrating a positive score in at least one of these 3 indices of tear film and ocular surface homeostasis. In those diagnosed with DED, it is important to identify the etiological driver(s) of the individual's disease (see Section 3.5; [Table 6](#)) to inform the most appropriate management and therapy option(s) (as described in the TFOS DEWS III Management and Therapy report<sup>17</sup>; [Figure 11](#))

An example of a test sequence to diagnose and to identify the drivers (subtypes) of dry eye disease based on key tests or observations is presented in [Table 7](#). Tests should be ordered from least to most invasive, to best maintain the integrity of the assessments and to minimize the impact on subsequent test results. Slight variations in the test order may be expected where the tests applied differ, but, regardless, the same test order should be used consistently in

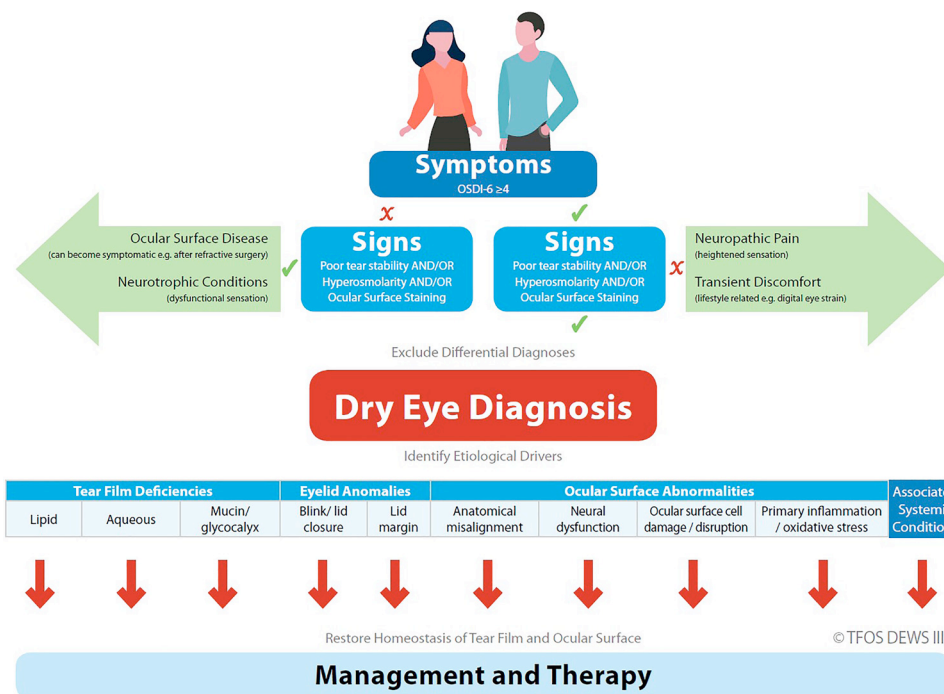


FIGURE 11. TFOS DEWS III classification of dry eye disease.

the case of each patient at any one site, to enhance consistency in diagnosis and subclassification. Diagnosis and assessment for subtype drivers may be conducted in a single visit (if time allows) or may be separated into 2 visits to include a rapid diagnosis as part of routine testing, with follow-up for subtype driver analysis at a separate visit. Test order will be adjusted accordingly, always from least to most invasive.

• **6.2 PATIENT COMMUNICATION:** When communicating with a patient experiencing dry eye, active, two-way communication should be prioritized by openly discussing their symptoms, addressing concerns, educating them on lifestyle modifications to manage the condition, and empowering them to actively participate in developing and executing their treatment plan. Key aspects include: explaining the chronic nature of DED, setting realistic expectations, discussing environmental triggers, promoting proper ocular surface hygiene practices and recommending appropriate tear supplements or other treatments based on their individual needs and as indicated by their individually identified etiological drivers. Patients are usually highly engaged in their desired outcomes<sup>315</sup> and, if DED is suspected, a follow up appointment is likely to be needed to perform a differential diagnosis, conduct the diagnostic algorithm, identify the etiological drivers (with the potential for ancillary staff to conduct these measurements) and to discuss these with the patient and ideally show them the images captured, to assist in making shared decisions on appropriate management and therapy.<sup>17</sup>

• **6.3 KEY DIAGNOSTIC METHODOLOGICAL CHANGES FROM TFOS DEWS II:** The revised definition: “Dry eye is a multifactorial, symptomatic disease characterized by a loss of homeostasis of the tear film and/or ocular surface, in which tear film instability and hyperosmolarity, ocular surface inflammation and damage, and neurosensory abnormalities are etiological factors.” Key features of DED from the definition that have been re-emphasised include that DED is multifactorial, is a disease not a syndrome, and is always symptomatic.

The recommended screening questionnaire is the OSDI-6 with a cut-off of a score  $\geq 4$  (Figure 4). Other questionnaires can be used as desired to gain further understanding of the environmental risk factors and symptomology detail, but the standardized diagnostic questionnaire is necessary to achieve diagnostic consistency for all patients.

Key clinical differential diagnosis questions, alongside asking about a patient’s general health and medication, are as follows:

- Do you feel eye pain rather than discomfort?
- Do you have any facial flushing/redness, mouth dryness, or enlarged salivary glands?
- When did your symptoms start, and can you recall any triggering event?
- Is your vision affected, and if so, does it improve on blinking?
- Are the symptoms or any redness much worse in one eye than the other?
- Do the eyes itch, or are they swollen, crusty, or have they given off any discharge?

A detailed examination of the ocular surface is recommended where the responses to these questions suggest the possible presence of eye conditions that might masquerade as DED, with a guide to the ocular examination presented in [Figure 2](#).

Known DED risk/associated factors ([Figure 3](#)) have been updated based on the scientific evidence<sup>4</sup> and factors commonly assumed to be associated with, or even to cause, DED for which the evidence is equivocal, are reported ([Table 1](#)).

The diagnostic algorithm for DED has been refined ([Figure 5](#)) and, in mitigating the established variability between questionnaires, only one (the OSDI-6) is recommended for the diagnostic algorithm. The impact on the diagnosis of each of the individual signs of a loss of homeostasis of the tear film and ocular surface recommended in TFOS DEWS II has been examined, demonstrating that the lack of one or other (but not both) non-invasive breakup time or osmolarity has only a minor effect. Hence the revised, TFOS DEWS III approach has been shown to be robust<sup>232</sup> and further simplifies the procedure for application in clinical practice.

In aligning treatment strategies that possess different mechanisms of action with the multiple established drivers of dry eye disease, it has become clear that a greater number of distinct subtypes than simply aqueous and evaporative need to be acknowledged to ensure optimal patient care. This report has compiled the evidence on a more detailed subclassification of the disease based on the etiological drivers, so that these can be identified for an individual patient for the purpose of informing appropriate management and therapy. Cut-offs for the identified clinical tests have been provided where available ([Table 6](#)). Many of these clinical tests are already part of a standard clinical DED routine ([Table 7](#)), with the TFOS DEWS III approach offering structure and links to management and therapy ([Figure 11](#)).<sup>17</sup>

---

## CREDIT AUTHORSHIP CONTRIBUTION STATEMENT

**James S. Wolffsohn:** Conceptualization, Data curation, Writing – original draft, Methodology, Project administration, Visualization, Writing – review & editing. **José M. Benítez-Del-Castillo:** Data curation, Writing – original draft, Writing – review & editing. **Denise Loya-Garcia:** Data curation, Writing – original draft, Writing – review & editing. **Takenori Inomata:** Data curation, Writing – original draft, Writing – review & editing. **Geetha Iyer:** Data curation, Writing – original draft, Writing – review & editing. **Lingyi Liang:** Data curation, Writing – original draft, Writing – review & editing. **Heiko Pult:** Data curation, Writing – original draft, Writing – review & editing. **Alfonso L. Sabater:** Data curation, Writing – original draft, Writing – review & editing. **Christopher E. Starr:** Data curation, Writing – original draft, Writing – review & editing. **Jelle Vehof:** Conceptualization, Data curation, Methodology, Project administration, Writing – original draft, Writing – review & editing. **Michael T.M. Wang:** Data curation, Writing – original draft, Writing – review & editing. **Wei Chen:** Conceptualization, Writing – original draft, Writing – review & editing. **Jennifer P. Craig:** Conceptualization, Data curation, Methodology, Project administration, Writing – original draft, Writing – review & editing. **Murat Dogru:** Conceptualization, Writing – original draft, Writing – review & editing. **Victor L. Perez:** Conceptualization, Project administration, Writing – review & editing. **Fiona Stapleton:** Conceptualization, Writing – original draft, Writing – review & editing. **David A. Sullivan:** Conceptualization, Funding acquisition, Project administration, Supervision, Validation, Writing – review & editing. **Lyndon Jones:** Conceptualization, Writing – original draft, Writing – review & editing.



**Funding/Support:** The TFOS DEWS III effort was supported by unrestricted donations from Alcon, Bausch + Lomb, Azura, AbbVie, CooperVision, Dompé, Espansione Group, Harrow, Laboratoire Théa, SIFI, SINQI, Tarsus, Topcon and Trukera. **Financial Disclosures:** J.S.W.: Grants or contracts: Alcon, 3M, Bausch + Lomb, M2C Pharmaceuticals, NuVision, Théa, Espansione, Essilor, Rayner, Novartis, Scope Ophthalmics, Topcon; Consulting fees: Alcon, Bausch + Lomb, CSIDryEye, TearOptix; Payment or honoraria for lectures, presentations, speakers bureaus, manuscript writing or educational events: Santen, Bausch + Lomb, Alcon, Scope Ophthalmic. Support for attending meetings, travel: Santen; Participation on a Data Safety Monitoring Board or Advisory Board: Bausch + Lomb, Alcon, Santen; Leadership or fiduciary role in other board, society, committee or advocacy group, paid or unpaid: Tear Film and Ocular Surface Society, British Contact Lens Association; Stock or stock options: Aston Vision Sciences, Eyoto, Wolffsohn Research Ltd. J.B.-D.-C.: Grants or contracts: Alcon, Bausch + Lomb, Santen, Sifi; Consulting fees: Théa, Brill; Payment or honoraria for lectures, presentations, speakers bureaus, manuscript writing or educational events: Théa, Brill, Alcon, Santen, Farmamix, Faes; Participation on a Data Safety Monitoring Board or Advisory Board: Abbvie, GSK. T.I.: Grants or contracts (grants outside of submitted work): Johnson & Johnson Vision Care, Yuimedi, ROHTO Pharmaceutical, Kobayashi Pharmaceutical Kandenko, Fukoku; Payment or honoraria for lectures, presentations, speakers bureaus, manuscript writing or educational events (honoraria for lectures outside of the submitted work): Santen Pharmaceutical, Senju Pharmaceutical, Seed; Leadership or fiduciary role in other board, society, committee or advocacy group, paid or unpaid (personal fees outside of the submitted work): Santen Pharmaceutical, Ono Pharmaceutical, Innojin; Stock or stock options (outside of the submitted work): Innojin; Nonfinancial support outside of the submitted work: Lion Corporation, Sony Network Communications. C.E.S.: Payment or honoraria for lectures, presentations, speakers bureaus, manuscript writing or educational events: Abbvie, Sun, Trukera, Bruder, BlephEx, Kala, Quidel, Dombe, Johnson & Johnson Vision, Sight Sciences, Tarsus, Oyster Point, Aldeyra, Alcon, Versea, Bausch + Lomb, Novaliq, Lumenis, Théa, Glaukos, Amgen, Oculis; Stock or stock options: Essiri, Sofia Biologics, Nuvisa, CSI Dry Eye. J.P.C.: Grants or contracts (research grant paid to institution): Alcon, Azura, Laboratoires Théa, Resono Ophthalmic, Topcon, TRG Natural Pharmaceuticals; Consulting fees: Alcon, Bausch + Lomb; Payment or honoraria for lectures, presentations, speakers bureaus, manuscript writing or educational events (payment to author): Alcon, Bausch + Lomb, Johnson & Johnson Vision, Laboratoires Théa, Topcon; Payment for expert testimony (payment to author): Optometrists and Dispensing Opticians Board of New Zealand; Support for attending meetings and/or travel: Alcon, Bausch + Lomb, Laboratoires Théa; Participation on a Data Safety Monitoring Board or Advisory Board: Alcon, Bausch + Lomb; Leadership or fiduciary role in other board, society, committee or advocacy group, paid or unpaid: Tear Film and Ocular Surface Society (director), Optometry Council of Australia and New Zealand (director), University of Auckland Board of Research (chair), British Contact Lens Association (global ambassador); Receipt of equipment, materials, drugs, medical writing, gifts or other services: E-Swin, Espansione Group, Medmont International, Resono Ophthalmic, Titan Optical, Topcon, TRG Natural Pharmaceuticals. F.S.: Grants or contracts (funds paid to institution): Alcon, Roche, Exonate, IOLYX, Nthalmics; Consulting fees (funds paid to institution): CooperVision, Alcon, Mentholum, CSL Seqirus; Azura Ophthalmics; Payment or honoraria for lectures, presentations, speakers bureaus, manuscript writing or educational events: CSL Seqirus, Alcon, InMode, Menicon (all, funds paid to institution), Johnson & Johnson, Santen (both, funds paid to author); Participation on a Data Safety Monitoring Board or Advisory Board (institution): Azura Ophthalmics, CSL Seqirus; Leadership or fiduciary role in other board, society, committee or advocacy group, paid or unpaid: Scientia Clinical Research (unpaid board chair), Vision Research Foundation (paid board member), Brien Holden Foundation (unpaid board member). D.A.S.: Consulting fees: Azura, Rimondi Capital; Support for attending meetings and/or travel: Tear Film and Ocular Surface Society; Leadership or fiduciary role in other board, society, committee or advocacy group, paid or unpaid: Tear Film and Ocular Surface Society (chair, board of directors); Stock or stock options: Lubris Biopharma. L.J.: Grants or contracts (funds paid to institution): Avizor, Essilor, Euclid, Hoya, iMed Pharma, Integral Biosystems, Johnson & Johnson Vision, Menicon; Myoptechs, Novartis, Ophtechs, Scope Ophthalmics, SightGlass, Topcon, Visioneering; Consulting fees: Alcon, CooperVision, Ophtechs; Payment or honoraria for lectures, presentations, speakers bureaus, manuscript writing or educational events: Alcon, Bausch + Lomb, CooperVision, J&J Vision; Leadership or fiduciary role in other board, society, committee or advocacy group (unpaid): Board of Directors, TFOS.

The remaining authors report no disclosures or conflicts of interest. All authors attest that they meet the current ICMJE criteria for authorship.

**Acknowledgments:** Sarp Orgul and Arthur Chan are acknowledged for their support in specific sections of the report.

## REFERENCES

- Wolffsohn JS, Arita R, Chalmers R, et al. TFOS DEWS II Diagnostic Methodology report. *Ocul Surf.* 2017;15:539–574.
- Craig JP, Nichols KK, Akpek E, et al. TFOS DEWS II Definition and Classification report. *Ocul Surf.* 2017;15:276–283.
- Craig JP, Nelson JD, Azar DT, et al. TFOS DEWS II report Executive Summary. *Ocul Surf.* 2017;15:802–812.
- Stapleton F, Argueso P, Azar D, et al. TFOS DEWS III Digest report. *Am J Ophthalmol.* 2025.
- Wolffsohn JS, Lingham G, Downie LE, et al. TFOS Lifestyle: impact of the digital environment on the ocular surface. *Ocul Surf.* 2023;28:213–252.
- Alves M, Asbell P, Dogru M, et al. TFOS Lifestyle report: impact of environmental conditions on the ocular surface. *Ocul Surf.* 2023;29:1–52.
- Markoulli M, Ahmad S, Arcot J, et al. TFOS Lifestyle: impact of nutrition on the ocular surface. *Ocul Surf.* 2023;29:226–271.
- Sullivan DA, da Costa AX, Del Duca E, et al. TFOS Lifestyle: impact of cosmetics on the ocular surface. *Ocul Surf.* 2023;29:77–130.
- Gomes JAP, Azar DT, Baudouin C, et al. TFOS Lifestyle: impact of elective medications and procedures on the ocular surface. *Ocul Surf.* 2023;29:331–385.
- Jones L, Efron N, Bandamwar K, et al. TFOS Lifestyle: impact of contact lenses on the ocular surface. *Ocul Surf.* 2023;29:175–219.
- Stapleton F, Abad JC, Barabino S, et al. TFOS lifestyle: impact of societal challenges on the ocular surface. *Ocul Surf.* 2023;28:165–199.
- Galor A, Britten-Jones AC, Feng Y, et al. TFOS Lifestyle: impact of lifestyle challenges on the ocular surface. *Ocul Surf.* 2023;28:262–303.
- Hsu CC, Chuang HK, Hsiao YJ, et al. Predicting risks of dry eye disease development using a genome-wide polygenic risk score model. *Transl Vis Sci Technol.* 2024;13:13.
- Vehof J, Wang B, Kozareva D, Hysi PG, Snieder H, Hammond CJ. The heritability of dry eye disease in a female twin cohort. *Invest Ophthalmol Vis Sci.* 2014;55:7278–7283.
- Vehof J, Zavos HMS, Lachance G, Hammond CJ, Williams FMK. Shared genetic factors underlie chronic pain syndromes. *Pain.* 2014;155:1562–1568.
- Spranger J. Disease, syndrome, sequence]. *Monatsschrift Kinderheilkunde.* 1989;137:2–7.

17. Jones L, Craig JP, Markoulli M, et al. TFOS DEWS III Management and Therapy report. *Am J Ophthalmol*. 2025.
18. Craig JP, Alves M, Wolffsohn JS, et al. TFOS Lifestyle report introduction: a lifestyle epidemic—ocular surface disease. *Ocul Surf*. 2023;28:304–309.
19. Lemp MA. Report of the National Eye Institute/industry workshop on clinical trials in dry eyes. *CLAO J*. 1995;21:221–232.
20. The definition and classification of dry eye disease: report of the Definition and Classification Subcommittee of the International Dry Eye WorkShop (2007). *Ocul Surf*. 2007;5:75–92.
21. Tong L, Waduthantri S, Wong TY, et al. Impact of symptomatic dry eye on vision-related daily activities: the Singapore Malay Eye Study. *Eye (Lond)*. 2010;24:1486–1491.
22. Eroy AA, Utheim TP, Sundling V. Cross-sectional study exploring vision-related quality of life in dry eye disease in a Norwegian optometric practice. *Optom Vis Sci*. 2023;100:679–687.
23. Karakus S, Mathews PM, Agrawal D, Henrich C, Ramulu PY, Akpek EK. Impact of dry eye on prolonged reading. *Optom Vis Sci*. 2018;95:1105–1113.
24. Morthen MK, Magno MS, Utheim TP, et al. The vision-related burden of dry eye. *Ocul Surf*. 2022;23:207–215.
25. Boboridis KG, Messmer EM, Benítez-del-Castillo J, et al. Patient-reported burden and overall impact of dry eye disease across eight European countries: a cross-sectional web-based survey. *BMJ Open*. 2023;13:e067007.
26. D'Souza S, Annavajjhala S, Thakur P, Mullick R, Tejal SJ, Shetty N. Study of tear film optics and its impact on quality of vision. *Indian J Ophthalmol*. 2020;68:2899–2902.
27. Habay T, Majzoub S, Perrault O, Rousseau C, Pisella PJ. Objective assessment of the functional impact of dry eye severity on the quality of vision by double-pass aberrometry. *J Fr Ophthalmol*. 2014;37:188–194.
28. Sullivan BD, Palazón de la Torre M, Yago I, et al. Tear film hyperosmolarity is associated with increased variation of light scatter following cataract surgery. *Clin Ophthalmol*. 2024;18:2419–2426.
29. Zhao DX, Quintero M, Mihailovic A, et al. Utilizing visual symptoms to distinguish dry eye from glaucoma, cataract, and suspect glaucoma patients: a cross-sectional study. *BMC Ophthalmol*. 2024;24:16.
30. Hartong DT, van der Meeren SW, Coumou AD, Kloos R, Saeed P. [Watery eyes: diagnostic and therapeutic considerations]. *Nederlands tijdschrift voor geneeskunde*. 2023;167.
31. Gordon AA, Danek DJ, Phelps PO. Common inflammatory and infectious conditions of the eyelid. *Disease-a-Month*. 2020;66:101042.
32. Kim BY, Riaz KM, Bakhtiari P, et al. Medically reversible limbal stem cell disease: clinical features and management strategies. *Ophthalmology*. 2014;121:2053–2058.
33. Gomes JAP, Azar DT, Baudouin C, et al. TFOS DEWS II Iatrogenic report. *Ocul Surf*. 2017;15:511–538.
34. Pisella PJ, Pouliquen P, Baudouin C. Prevalence of ocular symptoms and signs with preserved and preservative free glaucoma medication. *Br J Ophthalmol*. 2002;86:418–423.
35. Dua HS, Watson NJ, Mathur RM, Forrester JV. Corneal epithelial cell migration in humans: 'hurricane and blizzard keratopathy'. *Eye*. 1993;7:53–58.
36. Nelson JD. Superior limbic keratoconjunctivitis (SLK). *Eye*. 1989;3:180–189.
37. De Gregorio A, Cerini A, Scala A, Lambiase A, Pedrotti E, Morselli S. Floppy eyelid, an under-diagnosed syndrome: a review of demographics, pathogenesis, and treatment. *Ther Adv Ophthalmol*. 2021;13:25158414211059247.
38. Rapuano CJ, ed. *Color Atlas & Synopsis of Clinical Ophthalmology: Cornea* Wolters Kluwer; 2019:2–421.
39. Wolffsohn JS, Arita R, Chalmers R, et al. TFOS DEWS II Diagnostic Methodology report. *Ocul Surf*. 2017;15:539–574.
40. Wolffsohn JS, Dumbleton K, Huntjens B, et al. CLEAR—evidence-based contact lens practice. *Contact Lens Anterior Eye*. 2021;44:368–397.
41. Saw VPJ, Dart JKG. Ocular mucous membrane pemphigoid: diagnosis and management strategies. *Ocul Surf*. 2008;6:128.
42. Kohanim S, Palioura S, Saeed HN, et al. Stevens-Johnson syndrome/toxic epidermal necrolysis—a comprehensive review and guide to therapy. I. Systemic disease. *Ocul Surf*. 2016;14:2–19.
43. Zaidman GW, Geeraets R, Paylor RR, Ferry AP. The histopathology of filamentary keratitis. *Arch Ophthalmol*. 1985;103:1178–1181.
44. Roy A, Priyadarshini SR, Das S. Filamentary keratitis: a review. *Ocul Surf*. 2024;34:22–29.
45. Weiss M, Molina R, Ofoegbuna C, Johnson DA, Kheirikhah A. A review of filamentary keratitis. *Surv Ophthalmol*. 2022;67:52–59.
46. Albietz J, Sanfilippo P, Troutbeck R, Lenton LM. Management of filamentary keratitis associated with aqueous-deficient dry eye. *Optom Vis Sci*. 2003;80:420–430.
47. Bron AJ, de Paiva CS, Chauhan S, et al. TFOS DEWS II Pathophysiology report. *Ocul Surf*. 2017;15:438–510.
48. Zemba M, Ionescu MA, Pîrvulescu RA, et al. Biomarkers of ocular allergy and dry eye disease. *Romanian J Ophthalmol*. 2023;67:250–259.
49. Hom MM, Nguyen AL, Bielory L. Allergic conjunctivitis and dry eye syndrome. *Ann Allergy Asthma Immunol*. 2012;108:163–166.
50. Bonini S. Atopic keratoconjunctivitis, 78 ed. *Allergy: Eur J Allergy Clin Immunol*. 2004(suppl):71–73.
51. Kubicka-Trzaska A, Romanowska-Dixon B. Dry eye syndrome and allergic conjunctivitis—epidemics of XXI century—diagnostic problems and management. *Przegląd lekarski*. 2009;66:967–971.
52. Akil H, Celik F, Ulas F, Kara IS. Dry eye syndrome and allergic conjunctivitis in the pediatric population. *Middle East African J Ophthalmol*. 2015;22:467–471.
53. Bonini M, Gramiccioni C, Fioretti D, et al. Asthma, allergy and the olympics: a 12-year survey in elite athletes. *Curr Opin Allergy Clin Immunol*. 2015;15:184–192.
54. Chen JJ, Applebaum DS, Sun GS, Pflugfelder SC. Atopic keratoconjunctivitis: a review. *J Am Acad Dermatol*. 2014;70:569–575.
55. Akpek EK, Dart JK, Watson S, et al. A randomized trial of topical cyclosporin 0.05% in topical steroid-resistant atopic keratoconjunctivitis. *Ophthalmology*. 2004;111:476–482.
56. Akova YA, Rodriguez A, Foster CS. Atopic keratoconjunctivitis. *Ocul Immunol Inflamm*. 1994;2:125–144.

57. Cornish KS, Gregory ME, Ramaesh K. Systemic cyclosporin a in severe atopic keratoconjunctivitis. *Eur J Ophthalmol*. 2010;20:844–851.
58. Dogru M, Katakami C, Nakagawa N, Tetsumoto K, Yamamoto M. Impression cytology in atopic dermatitis. *Ophthalmology*. 1998;105:1478–1484.
59. Power WJ, Tugal-Tutkun I, Foster CS. Long-term follow-up of patients with atopic keratoconjunctivitis. *Ophthalmology*. 1998;105:637–642.
60. Guglielmetti S, Dart JK, Calder V. Atopic keratoconjunctivitis and atopic dermatitis. *Curr Opin Allergy Clin Immunol*. 2010;10:478–485.
61. Bielory B, Bielory L. Atopic dermatitis and keratoconjunctivitis. *Immunol Allergy Clin North Am*. 2010;30:323–336.
62. Friedman T, Friedman Z, Neumann E. Giant papillary conjunctivitis following cataract extraction. *Ann Ophthalmol*. 1984;16:50–52.
63. Durand ML, Barshak MB, Sobrin L. Eye infections. *N Engl J Med*. 2023;389:2363–2375.
64. Muto T, Imaizumi S, Kamoi K. Viral conjunctivitis. *Viruses*. 2023;15.
65. Maranhão AG, Soares CC, Albuquerque MCM, Santos N. Molecular epidemiology of adenovirus conjunctivitis in Rio de Janeiro, Brazil, between 2004 and 2007. *Revista do Instituto de Medicina Tropical de Sao Paulo*. 2009;51:227–229.
66. Lynch JP, Fishbein M, Echavarría M. Adenovirus. *Semin Respir Crit Care Med*. 2011;32:494–511.
67. M'Garrech M, Rousseau A, Kaswin G, et al. Impairment of lacrimal secretion in the unaffected fellow eye of patients with recurrent unilateral herpetic keratitis. *Ophthalmology*. 2013;120:1959–1967.
68. Cavalcanti BM, Cruzat A, Sahin A, Pavan-Langston D, Samayoa E, Hamrah P. In vivo confocal microscopy detects bilateral changes of corneal immune cells and nerves in unilateral herpes zoster ophthalmicus. *Ocul Surf*. 2018;16:101–111.
69. Alfonso SA, Fawley JD, Alexa Lu X. Conjunctivitis. *Primary Care*. 2015;42:325–345.
70. Henle G, Henle W, Clifford P, et al. Antibodies to Epstein-Barr virus in Burkitt's lymphoma and control groups. *J Natl Cancer Inst*. 1969;43:1147–1157.
71. Wong KW, D'Amico DJ, Hedges III TR, Soong HK, Schooley RT, Kenyon KR. Ocular involvement associated with chronic Epstein-Barr virus disease. *Arch Ophthalmol*. 1987;105:788–792.
72. Matoba AY. Ocular disease associated with Epstein-Barr virus infection. *Surv Ophthalmol*. 1990;35:145–150.
73. Orden Martínez B, Martínez Ruiz R, Millán Pérez R. Conjunctivitis bacteriana: patógenos más prevalentes y sensibilidad antibiótica. *Anales de Pediatría*. 2004;61:32–36.
74. Sugita G, Hotomi M, Sugita R, et al. Genetic characteristics of *Haemophilus influenzae* and *Streptococcus pneumoniae* isolated from children with conjunctivitis-otitis media syndrome. *J Infect Chemother*. 2014;20:493–497.
75. Azari AA, Barney NP. Conjunctivitis: a systematic review of diagnosis and treatment. *JAMA*. 2013;310:1721–1729.
76. Faraj HG, Hoang-Xuan T. Chronic cicatrizing conjunctivitis. *Curr Opin Ophthalmol*. 2001;12:250–257.
77. Vazirani J, Donthineni PR, Goel S, et al. Chronic cicatrizing conjunctivitis: a review of the differential diagnosis and an algorithmic approach to management. *Indian J Ophthalmol*. 2020;68:2349–2355.
78. Branisteanu DC, Stoleriu G, Branisteanu DE, et al. Ocular cicatricial pemphigoid (review). *Exp Ther Med*. 2020;20:3379–3382.
79. Marmalidou A, Kheirkhah A, Dana R. Conjunctivochalasis: a systematic review. *Surv Ophthalmol*. 2018;63:554–564.
80. Yvon C, Patel B, Conjunctivochalasis Malhotra R. *Int Ophthalmol Clin*. 2023;63:209–223.
81. Somnath A, Tripathy K. *Pinguecula*. 2024.
82. Ghiasian L, Samavat B, Hadi Y, Arbab M, Abolfathzadeh N. Recurrent pterygium: a review. *J Curr Ophthalmol*. 2021;33:367–378.
83. Van Acker SI, Van den Bogerd B, Haagdoorens M, et al. Pterygium—the good, the bad, and the ugly. *Cells*. 2021;10.
84. Sood G, Patel BC. *Conjunctival concretions*. StatPearls; 2024.
85. Wang K, See CW. Salzmann's nodular degeneration. *Exp Eye Res*. 2021;202:108351.
86. Maharana PK, Sharma N, Das S, et al. Salzmann's nodular degeneration. *Ocul Surf*. 2016;14:20–30.
87. Lin SR, Aldave AJ, Chodosh J. Recurrent corneal erosion syndrome. *Br J Ophthalmol*. 2019;103:1204–1208.
88. Laibson PR. Recurrent corneal erosions and epithelial basement membrane dystrophy. *Eye Contact Lens*. 2010;36:315–317.
89. Ong Tone S, Kocaba V, Bohm M, Wylegala A, White TL, Jurkunas UV. Fuchs endothelial corneal dystrophy: the vicious cycle of Fuchs pathogenesis. *Prog Retin Eye Res*. 2021;80:100863.
90. Siu GDJY, Young AL, Jhanji V. Alternatives to corneal transplantation for the management of bullous keratopathy. *Curr Opin Ophthalmol*. 2014;25:347–352.
91. Cabrera-Aguas M, Khoo P, Watson SL. Infectious keratitis: a review. *Clin Exp Ophthalmol*. 2022;50:543–562.
92. Mandal N, Yeung SN, Tadrous C, Iovieno A. Thygeson's superficial punctate keratitis. *Graefes Arch Clin Exp Ophthalmol*. 2022;260:1837–1841.
93. Kate A, Basu S. A review of the diagnosis and treatment of limbal stem cell deficiency. *Front Med (Lausanne)*. 2022;9:836009.
94. Tappeiner C, Walscheid K, Heiligenhaus A. [Diagnosis and treatment of episcleritis and scleritis]. *Ophthalmologe*. 2016;113:797–810.
95. Chiew RLJ, Au Eong DTM, Au Eong KG. Mucus fishing syndrome. *BMJ Case Rep*. 2022;15.
96. Slagle WS, Slagle AM, Brough GH. Mucus fishing syndrome: case report and new treatment option. *Optometry (St Louis, Mo)*. 2001;72:634–640.
97. Le DT, Kandel H, Watson SL. Evaluation of ocular neuropathic pain. *Ocul Surf*. 2023;30:213–235.
98. Tagawa Y, Noda K, Ohguchi T, Tagawa Y, Ishida S, Kitaichi N. Corneal hyperalgesia in patients with short tear film break-up time dry eye. *Ocul Surf*. 2019;17:55–59.
99. Kim J, Yoon HJ, You IC, Ko BY, Yoon KC. Clinical characteristics of dry eye with ocular neuropathic pain features: comparison according to the types of sensitization based on the Ocular Pain Assessment Survey. *BMC Ophthalmol*. 2020;20:455.
100. Galor A, Levitt RC, Felix ER, Martin ER, Sarantopoulos CD. Neuropathic ocular pain: an important yet under-evaluated feature of dry eye. *Eye (Lond)*. 2015;29:301–312.

101. Rosenthal P, Borsook D. Ocular neuropathic pain. *Br J Ophthalmol*. 2016;100:128–134.
102. Dermer H, Lent-Schochet D, Theotoka D, et al. A review of management strategies for nociceptive and neuropathic ocular surface pain. *Drugs*. 2020;80:547–571.
103. Vehof JH, J C. Systemic pain conditions and dry eye disease. In: Galor A, ed. *Dry Eye Disease*; 2022:135–145.
104. Papas EB, Ciolino JB, Jacobs D, et al. The TFOS International Workshop on Contact Lens Discomfort: report of the Management and Therapy subcommittee. *Invest Ophthalmol Vis Sci*. 2013;54 Tfos183-203.
105. Bitton E, Aumond S. Demodex and eye disease: a review. *Clin Exp Optom*. 2021;104:285–294.
106. Tariq MA, Amin H, Ahmed B, Ali U, Mohiuddin A. Association of dry eye disease with smoking: a systematic review and meta-analysis. *Indian J Ophthalmol*. 2022;70:1892–1904.
107. Vehof J, Snieder H, Jansonius N, Hammond CJ. Prevalence and risk factors of dry eye in 79,866 participants of the population-based Lifelines cohort study in the Netherlands. *Ocul Surf*. 2021;19:83–93.
108. Karimi S, Nouri H, Mahmoudinejad-Azar S, Abtahi SH. Smoking and environmental tobacco smoke exposure: implications in ocular disorders. *Cutan Ocul Toxicol*. 2023;42:1–7.
109. Abu-Ismaïl L, Abuawwad MT, Taha MJ, et al. Prevalence of dry eye disease among medical students and its association with sleep habits, use of electronic devices and caffeine consumption: a cross-sectional questionnaire. *Clin Ophthalmol*. 2023;17:1013–1023.
110. Li YZ, Wang C, Peng X, et al. Caffeine's protective role in dry eye disease and meibomian gland dysfunction: insights from clinical and experimental models. *Int Immunopharmacol*. 2024;146:113863.
111. Magno MS, Utheim TP, Morthen MK, et al. The relationship between caffeine intake and dry eye disease. *Cornea*. 2023;42:186–193.
112. Garcia-Marques JV, Talens-Estrelles C, Garcia-Lazaro S, Wolffsohn JS, Cervino A. Systemic, environmental and lifestyle risk factors for dry eye disease in a Mediterranean Caucasian population. *Cont Lens Anterior Eye*. 2022;45:101539.
113. Magno MS, Daniel T, Morthen MK, et al. The relationship between alcohol consumption and dry eye. *Ocul Surf*. 2021;21:87–95.
114. You YS, Qu NB, Yu XN. Alcohol consumption and dry eye syndrome: a meta-analysis. *Int J Ophthalmol*. 2016;9:1487–1492.
115. Nguyen L, Magno MS, Utheim TP, Jansonius NM, Hammond CJ, Vehof J. The relationship between habitual water intake and dry eye disease. *Acta Ophthalmol*. 2023;101:65–73.
116. Walsh NP, Fortes MB, Raymond-Barker P, et al. Is whole-body hydration an important consideration in dry eye? *Invest Ophthalmol Vis Sci*. 2012;53:6622–6627.
117. Wu Y, Xie Y, Yuan Y, et al. The Mediterranean diet and age-related eye diseases: a systematic review. *Nutrients*. 2023;15.
118. Galor A, Gardener H, Pouyeh B, Feuer W, Florez H. Effect of a Mediterranean dietary pattern and vitamin D levels on dry eye syndrome. *Cornea*. 2014;33:437–441.
119. Ismail AMA, El-Azeim ASA, Saif H. Effect of aerobic exercise alone or combined with Mediterranean diet on dry eye in obese hypertensive elderly. *Ir J Med Sci*. 2023;192:3151–3161.
120. Magno MS, Moschowits E, Morthen MK, et al. Greater adherence to a mediterranean diet is associated with lower C-reactive protein (CRP) levels, but not to lower odds of having dry eye disease. *Ocul Surf*. 2023;30:196–203.
121. Molina-Leyva I, Molina-Leyva A, Riquelme-Gallego B, Cano-Ibanez N, Garcia-Molina L, Bueno-Cavanillas A. Effectiveness of Mediterranean diet implementation in dry eye parameters: a study of PREDIMED-PLUS Trial. *Nutrients*. 2020;12.
122. Sriprasert I, Warren DW, Mircheff AK, Stanczyk FZ. Dry eye in postmenopausal women: a hormonal disorder. *Menopause*. 2016;23:343–351.
123. Sullivan DA, Rocha EM, Aragona P, et al. TFOS DEWS II Sex, Gender, and Hormones report. *Ocul Surf*. 2017;15:284–333.
124. Chen SP, Massaro-Giordano G, Pistilli M, Schreiber CA, Bunya VY. Tear osmolarity and dry eye symptoms in women using oral contraception and contact lenses. *Cornea*. 2013;32:423–428.
125. Moschos MM, Nitoda E. The impact of combined oral contraceptives on ocular tissues: a review of ocular effects. *Int J Ophthalmol*. 2017;10:1604–1610.
126. Wolpert LE, Snieder H, Jansonius NM, Utheim TP, Hammond CJ, Vehof J. Medication use and dry eye symptoms: a large, hypothesis-free, population-based study in the Netherlands. *Ocul Surf*. 2021;22:1–12.
127. McMonnies CW, Ho A. Responses to a dry eye questionnaire from a normal population. *J Am Optom Assoc*. 1987;58:588–591.
128. McMonnies CW. Key questions in a dry eye history. *J Am Optom Assoc*. 1986;57:512–517.
129. Dumbleton KA, Guillon M, Theodoratos P, Patel T. Diurnal variation in comfort in contact lens and non-contact lens wearers. *Optom Vis Sci*. 2016;93:820–827.
130. Chalmers RL, Begley CG. Dryness symptoms among an unselected clinical population with and without contact lens wear. *Cont Lens Anterior Eye*. 2006;29:25–30.
131. Begley CG, Chalmers RL, Mitchell GL, et al. Characterization of ocular surface symptoms from optometric practices in North America. *Cornea*. 2001;20:610–618.
132. González-Méijome JM, Paraíta MA, Yebra-Pimentel E, Almeida JB. Symptoms in a population of contact lens and noncontact lens wearers under different environmental conditions. *Optom Vis Sci*. 2007;84:296–302.
133. Guillon M, Shah S. Rationale for 24-hour management of dry eye disease: a review. *Cont Lens Anterior Eye*. 2019;42:147–154.
134. Ayaki M, Negishi K. Seasonality of tear meniscus volume and dry eye-related symptoms—a cross-sectional retrospective cohort study. *Clin Ophthalmol*. 2023;17:3809–3816.
135. Eidet JR, Chen X, Ræder S, Badian RA, Utheim TP. Seasonal variations in presenting symptoms and signs of dry eye disease in Norway. *Sci Rep*. 2022;12:21046.
136. Wolffsohn JS. Chapter 1—Questionnaire design and use to assess dry eye disease. editor. *Dry Eye Disease*. 2023:1–14.
137. Okumura Y, Inomata T, Iwata N, et al. A review of dry eye questionnaires: measuring patient-reported outcomes and health-related quality of life. *Diagnostics (Basel)*. 2020;10.



138. Chalmers RL, Begley CG, Caffery B. Validation of the 5-Item Dry Eye Questionnaire (DEQ-5): discrimination across self-assessed severity and aqueous tear deficient dry eye diagnoses. *Cont Lens Anterior Eye*. 2010;33:55–60.
139. Wang MTM, Xue AL, Craig JP. Comparative evaluation of 5 validated symptom questionnaires as screening instruments for dry eye disease. *JAMA Ophthalmol*. 2019;137:228–229.
140. Akowuah PK, Adjei-Anang J, Nkansah EK, et al. Comparison of the performance of the dry eye questionnaire (DEQ-5) to the ocular surface disease index in a non-clinical population. *Cont Lens Anterior Eye*. 2022;45.
141. Chatterjee S, Agrawal D, Chaturvedi P. Ocular Surface Disease Index© and the Five-Item Dry Eye Questionnaire: a comparison in Indian patients with dry eye disease. *Indian J Ophthalmol*. 2021;69:2396–2400.
142. Pult H, Wolffsohn JS. The development and evaluation of the new Ocular Surface Disease Index-6. *Ocul Surf*. 2019;17(4):817–821 2019.
143. Chidi-Egboka NC, Golebiowski B, Lee SY, Vi M, Jalbert I. Dry eye symptoms in children: can we reliably measure them? *Ophthalmic Physiol Opt*. 2021;41:105–115.
144. Pult H, Wolffsohn JS. The development and evaluation of the new Ocular Surface Disease Index-6. *Ocul Surf*. 2019;17(4):817–821.
145. Qin G, Moutari S, Chen J, et al. Validity of OSDI-6 questionnaire in a Chinese adult population. *Sci Rep*. 2024;14:14320.
146. Wolffsohn JS, Travé-Huarte S, Craig JP, Muntz A, Stapleton FJ. Appropriateness of questionnaires for the diagnosis and monitoring treatment of dry eye disease. *J Clin Med*. 2024;13(11):3146.
147. Pult H, Wolffsohn JS. The development and evaluation of the new Ocular Surface Disease Index-6. *Ocul Surf*. 2019;17:817–821.
148. Bartlett JD, Keith MS, Sudharshan L, Snedecor SJ. Associations between signs and symptoms of dry eye disease: a systematic review. *Clin Ophthalmol*. 2015;9:1719–1730.
149. Craig JP, Nichols KK, Akpek EK, et al. TFOS DEWS II Definition and Classification report. *Ocul Surf*. 2017;15:276–283.
150. Vehof J, Sillevs Smitt-Kamminga N, Nibourg SA, Hammond CJ. Sex differences in clinical characteristics of dry eye disease. *Ocul Surf*. 2018;16:242–248.
151. Adatia FA, Michaeli-Cohen A, Naor J, Caffery B, Bookman A, Slomovic A. Correlation between corneal sensitivity, subjective dry eye symptoms and corneal staining in Sjogren's syndrome. *Can J Ophthalmol*. 2004;39:767–771.
152. Bourcier T, Acosta MC, Borderie V, et al. Decreased corneal sensitivity in patients with dry eye. *Invest Ophthalmol Vis Sci*. 2005;46:2341–2345.
153. Chin JY, Liu C, Lee IXY, et al. Impact of age on the characteristics of corneal nerves and corneal epithelial cells in healthy adults. *Cornea*. 2024;43:409–418.
154. Galor A, Felix ER, Feuer W, et al. Dry eye symptoms align more closely to non-ocular conditions than to tear film parameters. *Br J Ophthalmol*. 2015;99:1126–1129.
155. Viso E, Rodriguez-Ares MT, Abelenda D, Oubina B, Gude F. Prevalence of asymptomatic and symptomatic meibomian gland dysfunction in the general population of Spain. *Invest Ophthalmol Vis Sci*. 2012;53:2601–2606.
156. McCann P, Kruoch Z, Lopez S, Malli S, Qureshi R, Li T. Interventions for dry eye: an overview of systematic reviews. *JAMA Ophthalmol*. 2024;142:58–74.
157. Hynnekleiv L, Magno M, Vernhardsdottir RR, et al. Hyaluronic acid in the treatment of dry eye disease. *Acta Ophthalmol*. 2022;100:844–860.
158. Downie LE, Ng SM, Lindsley KB, Akpek EK. Omega-3 and omega-6 polyunsaturated fatty acids for dry eye disease. *Cochrane Database Syst Rev*. 2019;12:CD011016.
159. Baudouin C, de la Maza MS, Amrane M, et al. One-year efficacy and safety of 0.1% cyclosporine A cationic emulsion in the treatment of severe dry eye disease. *Eur J Ophthalmol*. 2017;27:678–685.
160. Liu SH, Saldanha IJ, Abraham AG, et al. Topical corticosteroids for dry eye. *Cochrane Database Syst Rev*. 2022;10:CD015070.
161. de Paiva CS, Pflugfelder SC, Ng SM, Akpek EA. Topical cyclosporine A therapy for dry eye syndrome. *Cochrane Database Syst Rev*. 2019;9:CD010051.
162. Vernhardsdottir RR, Magno MS, Hynnekleiv L, et al. Antibiotic treatment for dry eye disease related to meibomian gland dysfunction and blepharitis—a review. *Ocul Surf*. 2022;26:211–221.
163. Craig JP, Muntz A, Wang MTM, et al. Developing evidence-based guidance for the treatment of dry eye disease with artificial tear supplements: a six-month multicentre, double-masked randomised controlled trial. *Ocul Surf*. 2021;20:62–69.
164. Wirta DL, Galor A, Aune CA, et al. Long-term safety and efficacy of a water-free cyclosporine 0.1% ophthalmic solution for treatment of dry eye disease: ESSENCE-2 OLE. *Cornea*. 2024;44(6):692–700.
165. Vehof J, Sillevs Smitt-Kamminga N, Nibourg SA, Hammond CJ. Predictors of discordance between symptoms and signs in dry eye disease. *Ophthalmology*. 2017;124:280–286.
166. Ong ES, Felix ER, Levitt RC, Feuer WJ, Sarantopoulos CD, Galor A. Epidemiology of discordance between symptoms and signs of dry eye. *Br J Ophthalmol*. 2018;102:674–679.
167. Lu PT, Lee CY, Sun CC. Sex differences and discordance between symptoms and signs of dry eye disease. *Am J Ophthalmol*. 2024;260:14–20.
168. D'Souza S, Shetty R, Nair AP, et al. Corneal confocal microscopy features and tear molecular profile in study participants with discordance between ocular surface disease clinical signs and discomfort. *J Clin Med*. 2022;11.
169. Shtein RM, Harper DE, Pallazola V, et al. Discordant dry eye disease (an American Ophthalmological Society thesis). *Trans Am Ophthalmol Soc*. 2016;114:T4.
170. Li B, Tian Y, Wang S. The correlation of cytokines and sensory hypersensitivity in mild dry eye patients characterized by symptoms outweighing signs. *Mol Vis*. 2020;26:359–369.
171. Ayaki M, Negishi K, Kawashima M, Uchino M, Kaido M, Tsubota K. Age is a determining factor of dry eye-related signs and symptoms. *Diagnostics (Basel)*. 2020;10.
172. Kim M, Chun YS, Kim KW. Different perception of dry eye symptoms between patients with and without primary Sjogren's syndrome. *Sci Rep*. 2022;12:2172.
173. Ucar IC, Esen F, Turhan SA, Oguz H, Ulasoglu HC, Aykut V. Corneal neuropathic pain in irritable bowel syndrome: clinical findings and in vivo corneal confocal microscopy. *Graefes Arch Clin Exp Ophthalmol*. 2021;259:3011–3017.
174. Vehof J, Sillevs Smitt-Kamminga N, Kozareva D, Nibourg SA, Hammond CJ. Clinical characteristics of dry eye

- patients with chronic pain syndromes. *Am J Ophthalmol*. 2016;162:59–65.
175. Galor A, Covington D, Levitt AE, et al. Neuropathic ocular pain due to dry eye is associated with multiple comorbid chronic pain syndromes. *J Pain*. 2016;17:310–318.
  176. Stapleton F, Velez FG, Lau C, Wolffsohn JS. Dry eye disease in the young: a narrative review. *Ocul Surf*. 2024;31:11–20.
  177. Chidi-Egboka NC, Golebiowski B, Lee SY, Vi M, Jalbert I. Dry eye symptoms in children: can we reliably measure them? *Ophthalmic Physiol Optics*. 2021;41:105–115.
  178. Tsubota K, Yokoi N, Shimazaki J, et al. New perspectives on dry eye definition and diagnosis: a consensus report by the Asia Dry Eye Society. *Ocul Surf*. 2017;15:65–76.
  179. Tsubota K, Yokoi N, Watanabe H, et al. A new perspective on dry eye classification: proposal by the Asia Dry Eye Society. *Eye Contact Lens*. 2020;46(suppl 1):S2–S13.
  180. Shimazaki J. Definition and diagnostic criteria of dry eye disease: historical overview and future directions. *Invest Ophthalmol Vis Sci*. 2018;59:DES7–DES12.
  181. Kim DH, Eom Y, Yoon CH, et al. New Korean guidelines for the diagnosis and management of dry eye disease. *Korean J Ophthalmol*. 2024;38:156–163.
  182. Papas EB. Diagnosing dry-eye: which tests are most accurate? *Cont Lens Anterior Eye*. 2023;46.
  183. Papas EB. The global prevalence of dry eye disease: a Bayesian view. *Ophthalmic Physiol Opt*. 2021;41:1254–1266.
  184. Llewellyn HJB. Sensitivity and specificity are not appropriate for diagnostic reasoning. *BMJ*. 2017;358:j4071.
  185. Wolffsohn JS, Travé-Huarte S, Craig JP, Wang MTM, Jones L. Letter to Editor re “Diagnosing dry-eye: Which tests are most accurate?”. *Cont Lens Anterior Eye*. 2023;46:102061.
  186. Alves M, Reinach PS, Paula JS, et al. Comparison of diagnostic tests in distinct well-defined conditions related to dry eye disease. *PLoS One*. 2014;9:e97921.
  187. de Oliveira FR, Motta ACF, Módulo CM, et al. Clinical and laboratory evaluation of sicca complaints: distinctive aspects of primary, secondary and non-Sjogren syndrome. *Adv Rheumatol (London, England)*. 2022;62:23.
  188. Garcia DM, Reis de Oliveira F, Módulo CM, et al. Is Sjögren's syndrome dry eye similar to dry eye caused by other etiologies? Discriminating different diseases by dry eye tests. *PLoS One*. 2018;13:e0208420.
  189. Sullivan BD, Crews LA, Messmer EM, et al. Correlations between commonly used objective signs and symptoms for the diagnosis of dry eye disease: clinical implications. *Acta Ophthalmol*. 2014;92:161–166.
  190. Mizuno Y, Yamada M, Miyake Y. Dry Eye Survey Group of the National Hospital Organization of Japan. Association between clinical diagnostic tests and health-related quality of life surveys in patients with dry eye syndrome. *Jpn J Ophthalmol*. 2010;54:259–265.
  191. Sullivan BD, Smith GT, Gupta A, Harman F, Ansari E. Impact of clinician subjectivity on the assessment of dry eye disease prevalence in a UK public health care patient population. *Clin Ophthalmol*. 2024;18:743–753.
  192. Szalai E, Berta A, Szekanecz Z, Szucs G, Modis Jr L. Evaluation of tear osmolarity in non-Sjogren and Sjogren syndrome dry eye patients with the TearLab system. *Cornea*. 2012;31:867–871.
  193. Zhang Q, Wu Y, Song Y, et al. Screening evaporative dry eyes severity using an infrared image. *J Ophthalmol*. 2021;2021:8396503.
  194. Kamao T, Yamaguchi M, Kawasaki S, Mizoue S, Shiraishi A, Ohashi Y. Screening for dry eye with newly developed ocular surface thermographer. *Am J Ophthalmol*. 2011;151:782–791.
  195. Su TY, Hwa CK, Liu PH, et al. Noncontact detection of dry eye using a custom designed infrared thermal image system. *J Biomed Optics*. 2011;16:046009.
  196. Kikukawa Y, Tanaka S, Kosugi T, Pflugfelder SC. Non-invasive and objective tear film breakup detection on interference color images using convolutional neural networks. *PLoS One*. 2023;18:e0282973.
  197. Wang MTM, Power B, Xue AL, Craig JP. Diagnostic performance and optimal cut-off values for tear film lipid layer grading and thickness in dry eye disease: an investigator-masked, randomised crossover study. *Ocul Surf*. 2024;34:415–417.
  198. Monfared N, Murphy PJ. Features and influences on the normal tear evaporation rate. *Cont Lens Anterior Eye*. 2023;46:101809.
  199. Fineide F, Storås AM, Chen X, et al. Predicting an unstable tear film through artificial intelligence. *Sci Rep*. 2022;12:21416.
  200. Lemp MA, Holly FJ, Iwata S, Dohlman CH. The precorneal tear film. I. Factors in spreading and maintaining a continuous tear film over the corneal surface. *Arch Ophthalmol*. 1970;83:89–94.
  201. Norm M. Desiccation of the precorneal tear film I. Corneal wetting time. *Acta Ophthalmol*. 1969;47:865–880.
  202. Peterson RC, Wolffsohn JS, Fowler CW. Optimization of anterior eye fluorescein viewing. *Am J Ophthalmol*. 2006;142:572–575.
  203. Acet Y, Dağ Y. Changes caused by fluorescein in tear film by hybrid break-up time test—part one; on quantitative values. *Photodiagn Photodynamic Ther*. 2022;40:103137.
  204. Itokawa T, Suzuki T, Koh S, Hori Y. Evaluating the differences between fluorescein tear break-up time and noninvasive measurement techniques. *Eye Contact Lens*. 2023;49:104–109.
  205. Wang MTM, Craig JP. Comparative evaluation of clinical methods of tear film stability assessment: a randomized crossover trial. *JAMA Ophthalmol*. 2018;136:291–294.
  206. Mengher LS, Bron AJ, Tonge SR, Gilbert DJ. Effect of fluorescein instillation on the pre-corneal tear film stability. *Curr Eye Res*. 1985;4:9–12.
  207. Mooi JK, Wang MT, Lim J, Muller A, Craig JP. Minimising instilled volume reduces the impact of fluorescein on clinical measurements of tear film stability. *Cont Lens Anterior Eye*. 2017;40(3):170–174.
  208. Pflugfelder SC, Kikukawa Y, Tanaka S, Kosugi T. The utility of software-detected non-invasive tear break-up in comparison to fluorescein tear break-up measurements. *Front Med (Lausanne)*. 2024;11:1351013.
  209. Ramos L, Barreira N, Mosquera A, Penedo MG, Yebra-Pimentel E, García-Resúa C. Analysis of parameters for the automatic computation of the tear film break-up time test based on CCLRU standards. *Comput Methods Programs Biomed*. 2014;113:715–724.

210. Downie LE. Automated tear film surface quality breakup time as a novel clinical marker for tear hyperosmolarity in dry eye disease. *Invest Ophthalmol Vis Sci.* 2015;56:7260–7268.
211. Alonso-Caneiro D, Iskander DR, Collins MJ. Tear film surface quality with soft contact lenses using dynamic-area high-speed videokeratography. *Eye Contact Lens.* 2009;35:227–231.
212. Szczesna DH, Alonso-Caneiro D, Robert Iskander D, Read SA, Collins MJ. Predicting dry eye using noninvasive techniques of tear film surface assessment. *Invest Ophthalmol Vis Sci.* 2011;52:751–756.
213. Zeri F, Rizzo GC, Ponzini E, Tavazzi S. Comparing automated and manual assessments of tear break-up time using different non-invasive devices and a fluorescein procedure. *Sci Rep.* 2024;14:2516.
214. Bandlitz S, Peter B, Pflug T, et al. Agreement and repeatability of four different devices to measure non-invasive tear breakup time (NIBUT). *Cont Lens Anterior Eye.* 2020;43:507–511.
215. Lee R, Yeo S, Aung HT, Tong L. Agreement of noninvasive tear break-up time measurement between Tomey RT-7000 Auto Refractor-Keratometer and Oculus Keratograph 5M. *Clin Ophthalmol.* 2016;10:1785–1790.
216. Szczesna-Iskander DH, Llorens-Quintana C. Agreement between invasive and noninvasive measurement of tear film breakup time. *Sci Rep.* 2024;14:3852.
217. Lim J, Wang MTM, Craig JP. Evaluating the diagnostic ability of two automated non-invasive tear film stability measurement techniques. *Cont Lens Anterior Eye.* 2021;44:101362.
218. Johnson ME, Murphy PJ. Measurement of ocular surface irritation on a linear interval scale with the ocular comfort index. *Invest Ophthalmol Vis Sci.* 2007;48:4451–4458.
219. Yazdani M, Chen X, Tashbayev B, et al. Evaluation of the Ocular Surface Disease Index Questionnaire as a discriminative test for clinical findings in dry eye disease patients. *Curr Eye Res.* 2019;44:941–947.
220. Liu H, Begley C, Chen M, et al. A link between tear instability and hyperosmolarity in dry eye. *Invest Ophthalmol Vis Sci.* 2009;50:3671–369.
221. Yi HC, Lee YP, Shin YJ. Influence of nasal tear osmolarity on ocular symptoms related to dry eye disease. *Am J Ophthalmol.* 2018;189:71–76.
222. Lemp MA, Bron AJ, Baudouin C, et al. Tear osmolarity in the diagnosis and management of dry eye disease. *Am J Ophthalmol.* 2011;151:792–798.
223. Park J, Choi Y, Han G, et al. Evaluation of tear osmolarity measured by I-Pen osmolarity system in patients with dry eye. *Sci Rep.* 2021;11:7726.
224. Tavakoli A, Markoulli M, Flanagan J, Papas E. The validity of point of care tear film osmometers in the diagnosis of dry eye. *Ophthalmic Physiol Opt.* 2022;42:140–148.
225. Nolfi J, Caffery B. Randomized comparison of in vivo performance of two point-of-care tear film osmometers. *Clin Ophthalmol.* 2017;11:945–950.
226. Greiner JV, Ying GS, Pistilli M, Maguire MG, Asbell PA. Association of tear osmolarity with signs and symptoms of dry eye disease in the Dry Eye Assessment and Management (DREAM) Study. *Invest Ophthalmol Vis Sci.* 2023;64:5.
227. Tashbayev B, Utheim TP, Utheim Ø A, et al. Utility of tear osmolarity measurement in diagnosis of dry eye disease. *Sci Rep.* 2020;10:5542.
228. Choi M, Park YM, Ko BY. Comparative evaluation of matrix metalloproteinase-9 immunoassay and tear osmolarity measurement for diagnosing severity of dry eye disease. *Korean J Ophthalmol.* 2023;37:409–416.
229. van Setten GB. Osmokinetics: a new dynamic concept in dry eye disease. *J Fr Ophthalmol.* 2019;42:221–225.
230. Kursite A, Laganovska G. Effect of tear osmolarity on post-operative refractive error after cataract surgery. *J Ophthalmol (Ukraine).* 2023;11–15.
231. Vidal-Rohr M, Craig JP, Davies LN, Wolffsohn JS. The epidemiology of dry eye disease in the UK: the Aston Dry Eye Study. *Cont Lens Anterior Eye.* 2023;46:101837.
232. Wolffsohn JS, Travé-Huarte S, Stapleton F, et al. Investigating the relative importance of tear homeostatic signs for the diagnosis of dry eye disease. *Ocul Surf.* 2025;36:151–155.
233. Fong PY, Shih KC, Lam PY, Chan TCY, Jhanji V, Tong L. Role of tear film biomarkers in the diagnosis and management of dry eye disease. *Taiwan J Ophthalmol.* 2019;9:150–159.
234. Li Y, Smith RG, Steel JC, Layton CJ. Attitudes of eye health practitioners towards diagnostic tests and therapies for dry eye disease in Australasia. *Cont Lens Anterior Eye.* 2022;45:101724.
235. Casemore RK, Wolffsohn JS, Dutta D. Dry eye clinical practice patterns of UK optometrists. *Cont Lens Anterior Eye.* 2023;46:101889.
236. Arita R, Morishige N, Koh S, et al. Increased tear fluid production as a compensatory response to meibomian gland loss: a multicenter cross-sectional study. *Ophthalmology.* 2015;122:925–933.
237. Tawfik A, Pistilli M, Maguire MG, et al. Association of dry eye symptoms and signs in patients with dry eye disease. *Ophthalmic Epidemiol.* 2024;31:274–282.
238. Bron AJ, Argueso P, Irkec M, Bright FV. Clinical staining of the ocular surface: mechanisms and interpretations. *Prog Retinal Eye Res.* 2015;44:36–61.
239. Woods J, Hutchings N, Srinivasan S, Jones L. Geographic distribution of corneal staining in symptomatic dry eye. *Ocul Surf.* 2020;18:258–266.
240. Feenstra RP, Tseng SC. Comparison of fluorescein and rose bengal staining. *Ophthalmology.* 1992;99:605–617.
241. Korb DR, Herman JP, Finnemore VM, Exford JM, Blackie CA. An evaluation of the efficacy of fluorescein, rose bengal, lissamine green, and a new dye mixture for ocular surface staining. *Eye Contact Lens.* 2008;34:61–64.
242. Kim J, Foulks GN. Evaluation of the effect of lissamine green and rose bengal on human corneal epithelial cells. *Cornea.* 1999;18:328–332.
243. Chodosh J, Dix RD, Howell RC, Stroop WG, Tseng SC. Staining characteristics and antiviral activity of sulforhodamine B and lissamine green B. *Invest Ophthalmol Vis Sci.* 1994;35:1046–1058.
244. Duan H, Yang T, Zhou Y, et al. Comparison of mucin levels at the ocular surface of visual display terminal users with and without dry eye disease. *BMC Ophthalmol.* 2023;23:189.
245. Liu S, Dong H, Huang XH, Tang SH. Analysis of factors leading to lid wiper epitheliopathy. *Eur Rev Med Pharmacol Sci.* 2020;24:1593–1601.



246. Kato H, Yokoi N, Watanabe A, et al. Clinical factors for determining the severity of lid wiper epitheliopathy in dry eye. *Cornea*. 2022;41:545–551.
247. Li W, Yeh TN, Leung T, Yuen T, Lerma M, MC Lin. The relationship of lid wiper epitheliopathy to ocular surface signs and symptoms. *Invest Ophthalmol Vis Sci*. 2018;59:1878–1887.
248. Wang MTM, Dean SJ, Xue AL, Craig JP. Comparative performance of lid wiper epitheliopathy and corneal staining in detecting dry eye disease. *Clin Exp Ophthalmol*. 2019;47:546–548.
249. Wang MTM, Muntz A, Lim J, et al. Ageing and the natural history of dry eye disease: a prospective registry-based cross-sectional study. *Ocul Surf*. 2020;18:736–741.
250. Wang MTM, Power B, Xue AL, Craig JP. Discriminative performance of ocular surface staining and lid wiper epitheliopathy in dry eye disease: an investigator-masked, prospective registry-based, diagnostic accuracy study. *Ocul Surf*. 2024;34:165–172.
251. Blackie CA, Korb DR. A novel lid seal evaluation: the Korb-Blackie light test. *Eye Contact Lens*. 2015;41:98–100.
252. Mejía-Salgado G, Rojas-Carabali W, Cifuentes-González C, et al. Real-world performance of the inflammadry test in dry eye diagnosis: an analysis of 1,515 patients. *Graefes Arch Clin Exp Ophthalmol*. 2025 [online ahead of print].
253. Levy A, Georgeon C, Knoeri J, et al. Corneal epithelial thickness mapping in the diagnosis of ocular surface disorders involving the corneal epithelium: a comparative study. *Cornea*. 2022;41:1353–1361.
254. Cui X, Hong J, Wang F, et al. Assessment of corneal epithelial thickness in dry eye patients. *Optom Vis Sci*. 2014;91:1446–1454.
255. Buffault J, Zéboulon P, Liang H, et al. Assessment of corneal epithelial thickness mapping in epithelial basement membrane dystrophy. *PLoS One*. 2020;15:e0239124.
256. Rattan SA, Anwar DS. Comparison of corneal epithelial thickness profile in dry eye patients, keratoconus suspect, and healthy eyes. *Eur J Ophthalmol*. 2020;30:1506–1511.
257. Shrestha E, Shrestha JK, Shayami G, Chaudhary M. The conjunctival impression cytology between the diagnosed cases of dry eye and normal individuals. *Nepalese J Ophthalmol*. 2011;3:39–44.
258. Baudouin C, Haouat N, Brignole F, Bayle J, Gstaude P. Immunopathological findings in conjunctival cells using immunofluorescence staining of impression cytology specimens. *Br J Ophthalmol*. 1992;76:545–549.
259. Brignole F, Pisella PJ, De Saint, Jean M, Goldschild M, Goguel A, Baudouin C. Flow cytometric analysis of inflammatory markers in KCS: 6-month treatment with topical cyclosporin A. *Invest Ophthalmol Vis Sci*. 2001;42:90–95.
260. Reddy M, Reddy PR, Reddy SC. Conjunctival impression cytology in dry eye states. *Indian J Ophthalmol*. 1991;39:22–24.
261. Laver NMV. Ocular cytology: diagnostic features and ongoing practices. *Cancer Cytopathol*. 2021;129:419–431.
262. Foulks GN. Challenges and pitfalls in clinical trials of treatments for dry eye. *Ocul Surf*. 2003;1:20–30.
263. Pena-Verdeal H, Garcia-Queiruga J, Sabucedo-Villamarin B, Giraldez MJ, Garcia-Resua C, Yebra-Pimentel E. Capability of the inter-eye differences in osmolarity, break-up time and corneal staining on the diagnostic of dry eye. *Ocul Immunol Inflamm*. 2023;1–8.
264. Nilsen C, Graae Jensen P, Gundersen M, et al. The significance of inter-eye osmolarity difference in dry eye diagnostics. *Clin Ophthalmol*. 2023;17:829–835.
265. Wang MTM, Ormonde SE, Muntz A, Craig JP. Diagnostic profile of tear osmolarity and inter-ocular variability for dry eye disease. *Clin Exp Ophthalmol*. 2020;48:255–257.
266. Korb DR, Herman JP, Greiner JV, et al. Lid wiper epitheliopathy and dry eye symptoms. *Eye Contact Lens*. 2005;31:2–8.
267. Begley CG, Caffery B, Nelson JD, Situ P. The effect of time on grading corneal fluorescein and conjunctival lissamine green staining. *Ocul Surf*. 2022;25:65–70.
268. Delaveris A, Stahl U, Madigan M, Jalbert I. Comparative performance of lissamine green stains. *Cont Lens Anterior Eye*. 2018;41:23–27.
269. Ghorbani-Mojarrad N, Wolffsohn JS, Craig JP, et al. A comparison of physical characteristics in different brands and staining techniques in a brand of lissamine green strips. *J Clin Med*. 2025;14:2022.
270. Ghorbani-Mojarrad N, Vianya-Estopa M, Martin E, et al. Optimizing the methodology for the assessment of bulbar conjunctival lissamine green staining. *Optom Vis Sci*. 2024;101:589–594.
271. Lievens CW, Norgett Y, Briggs N, Allen PM, Vianya-Estopa M. Optimal methodology for lid wiper epitheliopathy identification. *Cont Lens Anterior Eye*. 2021;44:101332.
272. Hamrah P, Alipour F, Jiang S, Sohn JH, Foulks GN. Optimizing evaluation of Lissamine Green parameters for ocular surface staining. *Eye (Lond)*. 2011;25:1429–1434.
273. Shaw A, Collins M, Huang J, et al. Lid wiper epitheliopathy: the influence of multiple lid eversions and exposure time. *Cont Lens Anterior Eye*. 2019;42:304–310.
274. Kunnen CME, Wolffsohn JS, Ritchey ER. Comparison of subjective grading of lid wiper epitheliopathy with a semi-objective method. *Cont Lens Anterior Eye*. 2018;41:28–33.
275. Wolffsohn JS, Recchioni A, Hunt OA, et al. Optimising subjective grading of corneal staining in Sjögren's syndrome dry eye disease. *Ocul Surf*. 2024;32:166–172.
276. Bağbaba A, Şen B, Delen D, Uysal BS. An automated grading and diagnosis system for evaluation of dry eye syndrome. *J Med Syst*. 2018;42:227.
277. Arvind A, Nanjappa R, Gupta KK, Macedo-de-Araújo RJ, Fadel D. Lid wiper epitheliopathy: topical review of current identification strategies and future perspectives. *Cont Lens Anterior Eye*. 2024;47:102312.
278. Nagino K, Okumura Y, Yamaguchi M, et al. Diagnostic ability of a smartphone app for dry eye disease: protocol for a multicenter, open-label, prospective, and cross-sectional study. *JMIR Res Protoc*. 2023;12:e45218.
279. Oganov A, Yazdanpanah G, Jabbehdari S, Belamkar A, Pflugfelder S. Dry eye disease and blinking behaviors: a narrative review of methodologies for measuring blink dynamics and inducing blink response. *Ocul Surf*. 2023;29:166–174.
280. Palakuru JR, Wang J, Aquavella JV. Effect of blinking on tear dynamics. *Invest Ophthalmol Vis Sci*. 2007;48:3032–3037.
281. Seo J, Byun WY, Alisafaei F, et al. Multiscale reverse engineering of the human ocular surface. *Nat Med*. 2019;25:1310–1318.



282. Wang MTM, Tien L, Han A, et al. Impact of blinking on ocular surface and tear film parameters. *Ocul Surf.* 2018;16:424–429.
283. Johnston PR, Rodriguez J, Lane KJ, Ousler G, Abelson MB. The interblink interval in normal and dry eye subjects. *Clin Ophthalmol.* 2013;7:253–259.
284. Tsubota K, Hata S, Okusawa Y, Egami F, Ohtsuki T, Nakamori K. Quantitative videographic analysis of blinking in normal subjects and patients with dry eye. *Arch Ophthalmol.* 1996;114:715–720.
285. Pena-Verdeal H, García-Resúa C, Ramos L, Yebra-Pimentel E, Giraldez MJ. Diurnal variations in tear film break-up time determined in healthy subjects by software-assisted interpretation of tear film video recordings. *Clin Exp Optom.* 2016;99:142–148.
286. Nakamori K, Odawara M, Nakajima T, Mizutani T, Tsubota K. Blinking is controlled primarily by ocular surface conditions. *Am J Ophthalmol.* 1997;124:24–30.
287. Inomata T, Nakamura M, Sung J, et al. Smartphone-based digital phenotyping for dry eye toward P4 medicine: a crowd-sourced cross-sectional study. *NPJ Digit Med.* 2021;4:171.
288. Wolffsohn JS, Craig JP, Vidal-Rohr M, Huarte ST, Ah Kit L, Wang M. Blink Test enhances ability to screen for dry eye disease. *Cont Lens Anterior Eye.* 2018;41:421–425.
289. Inomata T, Iwagami M, Hiratsuka Y, et al. Maximum blink interval is associated with tear film breakup time: a new simple, screening test for dry eye disease. *Sci Rep.* 2018;8:13443.
290. Inomata T, Nakamura M, Iwagami M, et al. Risk factors for severe dry eye disease: crowdsourced research using DryEyeRhythm. *Ophthalmology.* 2019;126:766–768.
291. Hirosawa K, Inomata T, Sung J, et al. Diagnostic ability of maximum blink interval together with Japanese version of Ocular Surface Disease Index score for dry eye disease. *Sci Rep.* 2020;10:18106.
292. Nagino K, Okumura Y, Akasaki Y, et al. Smartphone app-based and paper-based patient-reported outcomes using a disease-specific questionnaire for dry eye disease: randomized crossover equivalence study. *J Med Internet Res.* 2023;25:e42638.
293. Fujio K, Nagino K, Huang T, et al. Clinical utility of maximum blink interval measured by smartphone application DryEyeRhythm to support dry eye disease diagnosis. *Sci Rep.* 2023;13:13583.
294. Okumura Y, Inomata T, Midorikawa-Inomata A, et al. DryEyeRhythm: a reliable and valid smartphone application for the diagnosis assistance of dry eye. *Ocul Surf.* 2022;25:19–25.
295. Su Y, Liang Q, Su G, Wang N, Baudouin C, Labbé A. Spontaneous eye blink patterns in dry eye: clinical correlations. *Invest Ophthalmol Vis Sci.* 2018;59:5149–5156.
296. Zheng Q, Wang L, Wen H, et al. Impact of incomplete blinking analyzed using a deep learning model with the Keratograph 5M in dry eye disease. *Transl Vis Sci Technol.* 2022;11:38.
297. Boyd C, Weiss C, Halter J, Han K, Ershler W, Fried L. Framework for evaluating disease severity measures in older adults with comorbidity. *J Gerontol Series A Biol Sci Med Sci.* 2007;62:286–295.
298. Ferris FL, Davis MD, Clemons TE, et al. A simplified severity scale for age-related macular degeneration: AREDS report no. 18. *Arch Ophthalmol.* 2005;123:1570–1574.
299. Alio JL, Shabayek MH. Corneal higher order aberrations: a method to grade keratoconus. *J Refract Surg.* 2006;22:539–545.
300. Belin MW, Duncan JK. Keratoconus: the ABCD Grading System. *Klinische Monatsblätter für Augenheilkunde.* 2016;233:701–707.
301. Issarti I, Consejo A, Jimenez-Garcia M, Kreps EO, Koppen C, Rozema JJ. Logistic index for keratoconus detection and severity scoring (Logik). *Comput Biol Med.* 2020;122:103809.
302. Age-Related Eye Disease Study Research GroupThe Age-Related Eye Disease Study (AREDS): design implications. AREDS report no. 1. *Control Clin Trials.* 1999;20:573–600.
303. Koh S, Inoue R, Ambrosio Jr R, Maeda N, Miki A, Nishida K. Correlation between corneal biomechanical indices and the severity of keratoconus. *Cornea.* 2020;39:215–221.
304. Mrugacz M, Ostrowska L, Bryl A, Szulc A, Zelazowska-Rutkowska B, Mrugacz G. Pro-inflammatory cytokines associated with clinical severity of dry eye disease of patients with depression. *Adv Med Sci.* 2017;62:338–344.
305. Kim S, Park D, Shin Y, et al. Deep learning-based fully automated grading system for dry eye disease severity. *PLoS One.* 2024;19:e0299776.
306. Yu J, Asche CV, Fairchild CJ. The economic burden of dry eye disease in the United States: a decision tree analysis. *Cornea.* 2011;30:379–387.
307. Baudouin C, Aragona P, Van Setten G, et al. Diagnosing the severity of dry eye: a clear and practical algorithm. *Br J Ophthalmol.* 2014;98:1168–1176.
308. Sullivan BD, Whitmer D, Nichols KK, et al. An objective approach to dry eye disease severity. *Invest Ophthalmol Vis Sci.* 2010;51:6125–6130.
309. Ebrahimi F, Ayatollahi H, Aghaei H. A clinical decision support system for diagnosing and determining severity of dry eye disease. *Eye (Lond).* 2023;37:1619–1624.
310. Guo M, Huang B, Jia X, Liu B. Utilizing corneal fluorescein and conjunctival lissamine green staining combined with in vivo confocal microscopy for grading the severity of dry eye disease. *Clin Ophthalmol.* 2025;19:807–817.
311. Chester T, Garg SS, Johnston J, Ayers B, Gupta P. How can we best diagnose severity levels of dry eye disease: current perspectives. *Clin Ophthalmol.* 2023;17:1587–1604.
312. Methodologies to diagnose and monitor dry eye disease: report of the Diagnostic Methodology Subcommittee of the International Dry Eye WorkShop (2007). *Ocul Surf.* 2007;5:108–152.
313. Behrens A, Doyle JJ, Stern L, et al. Dysfunctional tear syndrome: a Delphi approach to treatment recommendations. *Cornea.* 2006;25:900–907.
314. Amescua G, Ahmad S, Cheung AY, et al. American Academy of Ophthalmology Preferred Practice Pattern guidance—dry eye syndrome. Preferred Practice Guidelines; 2023.
315. Chiang JCB, Wolffsohn JS. Perspectives of dry eye patients in the United Kingdom on risk factors and desired treatment outcomes. *Cont Lens Anterior Eye.* 2025;48(2):102340.
316. Calvo F, Karras BT, Phillips R, Kimball AM, Wolf F. Diagnoses, syndromes, and diseases: a knowledge representation problem. *AMIA Annu Symp Proc.* 2003;2003:802.

317. Albiets JM. Prevalence of dry eye subtypes in clinical optometry practice. *Optom Vis Sci.* 2000;77:357–363.
318. Rege A, Kulkarni V, Puthran N, Khandgave T. A clinical study of subtype-based prevalence of dry eye. *J Clin Diagn Res.* 2013;7:2207–2210.
319. Asiedu K, Dzasimatu SK, Kyei S. Clinical subtypes of dry eye in youthful clinical sample in Ghana. *Cont Lens Anterior Eye.* 2019;42:206–211.
320. Vidal-Rohr M, Craig JP, Davies LN, Wolffsohn JS. Classification of dry eye disease subtypes. *Cont Lens Anterior Eye.* 2024;47(5):102257.
321. Wang MTM, Craig JP, Power B, Wolffsohn JS. Prospective registry-based external validation cohort analysis of dry eye disease subtype classification criteria. *Cont Lens Anterior Eye.* 2024;47:102290.
322. Craig JP, Nichols KK, Akpek EK, et al. TFOS DEWS II Definition and Classification Report. *Ocul Surf.* 2017;15:276–283.
323. Labetoulle M, Bourcier T, Doan Sgroup D. Classifying signs and symptoms of dry eye disease according to underlying mechanism via the Delphi method: the DIDACTIC study. *Br J Ophthalmol.* 2019;103:1475–1480.
324. Lemp MA, Crews LA, Bron AJ, Foulks GN, Sullivan BD. Distribution of aqueous-deficient and evaporative dry eye in a clinic-based patient cohort: a retrospective study. *Cornea.* 2012;31:472–478.
325. Misra S, Wagner R, Ozkan B, et al. Precision subclassification of type 2 diabetes: a systematic review. *Commun Med.* 2023;3:138.
326. Jones L, Downie LE, Korb D, et al. TFOS DEWS II Management and Therapy Report. *Ocul Surf.* 2017;15:575–628.
327. Yokoi N, Georgiev GA. Tear-film-oriented diagnosis for dry eye. *Jpn J Ophthalmol.* 2019;63:127–136.
328. Yokoi N, Georgiev GA. Tear film-oriented diagnosis and tear film-oriented therapy for dry eye based on tear film dynamics. *Invest Ophthalmol Vis Sci.* 2018;59:DES13–DES22.
329. Yokoi N, Georgiev GA, Kato H, et al. Classification of fluorescein breakup patterns: a novel method of differential diagnosis for dry eye. *Am J Ophthalmol.* 2017;180:72–85.
330. Han SB, Liu YC, Mohamed-Noriega K, Tong L, Mehta JS. Objective imaging diagnostics for dry eye disease. *J Ophthalmol.* 2020;2020:3509064.
331. Geerling G, Baudouin C, Aragona P, et al. Emerging strategies for the diagnosis and treatment of meibomian gland dysfunction: proceedings of the OCEAN group meeting. *Ocul Surf.* 2017;15:179–192.
332. Singh S, Donthineni PR, Srivastav S, Jacobi C, Basu S, Paulsen F. Lacrimal and meibomian gland evaluation in dry eye disease: a mini-review. *Indian J Ophthalmol.* 2023;71:1090–1098.
333. Yoon DY, Hee Eun J, Hyon JY. Correlation between tear film lipid layer thickness and transepidermal water loss from the ocular area in patients with dry eye disease and in healthy controls. *PLoS One.* 2022;17:e0270810.
334. McGinnigle S, Naroo SA, Eperjesi F. Evaluation of dry eye. *Surv Ophthalmol.* 2012;57:293–316.
335. Craig JP, Tomlinson A. Importance of the lipid layer in human tear film stability and evaporation. *Optom Vis Sci.* 1997;74:8–13.
336. Rinert J, Branger G, Bachmann LM, et al. Accuracy of a new noninvasive automatic ocular surface analyzer for the diagnosis of dry eye disease-two-gate design using healthy controls. *Cornea.* 2023;42:416–422.
337. Sanchez-Gonzalez MC, Capote-Puente R, MC Garcia-Romera, et al. Dry eye disease and tear film assessment through a novel non-invasive ocular surface analyzer: the OSA protocol. *Front Med (Lausanne).* 2022;9:938484.
338. Toth N, Szalai E, Rak T, Lillik V, Nagy A, Csutak A. Reliability and clinical applicability of a novel tear film imaging tool. *Graefes Arch Clin Exp Ophthalmol.* 2021;259:1935–1943.
339. Ward CD, Murchison CE, Petroll WM, Robertson DM. Evaluation of the repeatability of the lacrydiag ocular surface analyzer for assessment of the meibomian glands and tear film. *Transl Vis Sci Technol.* 2021;10:1.
340. Garcia-Marques JV, Talens-Estrelles C, Garcia-Lazaro S, Cervino A. Validation of a new objective method to assess lipid layer thickness without the need of an interferometer. *Graefes Arch Clin Exp Ophthalmol.* 2022;260:655–676.
341. Finis D, Pischel N, Schrader S, Geerling G. Evaluation of lipid layer thickness measurement of the tear film as a diagnostic tool for meibomian gland dysfunction. *Cornea.* 2013;32:1549–1553.
342. Lee Y, Hyon JY, Jeon HS. Characteristics of dry eye patients with thick tear film lipid layers evaluated by a Lip-iView II interferometer. *Graefes Arch Clin Exp Ophthalmol.* 2021;259:1235–1241.
343. Arita R, Morishige N, Fujii T, et al. Tear interferometric patterns reflect clinical tear dynamics in dry eye patients. *Invest Ophthalmol Vis Sci.* 2016;57:3928–3934.
344. Rolando M, Valente C, Barabino S. New test to quantify lipid layer behavior in healthy subjects and patients with keratoconjunctivitis sicca. *Cornea.* 2008;27:866–870.
345. Arita R, Fukuoka S, Morishige N. New insights into the lipid layer of the tear film and meibomian glands. *Eye Contact Lens.* 2017;43:335–339.
346. Zhao Y, Tan CL, Tong L. Intra-observer and inter-observer repeatability of ocular surface interferometer in measuring lipid layer thickness. *BMC Ophthalmol.* 2015;15:53.
347. Kim WJ, Ahn YJ, Kim MH, Kim HS, Kim MS, Kim EC. Lipid layer thickness decrease due to meibomian gland dysfunction leads to tear film instability and reflex tear secretion. *Ann Med.* 2022;54:893–899.
348. Cohen Y, Epshtein S, Harris A, Gefen R, Kagemann L, Arieli Y. Tear film imager for dynamic mapping of the human tear film. *Appl Optics.* 2019;58:7987–7995.
349. Segev F, Geffen N, Galor A, et al. Dynamic assessment of the tear film muco-aqueous and lipid layers using a novel tear film imager (TFI). *Br J Ophthalmol.* 2020;104:136–141.
350. Mochizuki H, Yamada M, Hatou S, Tsubota K. Turnover rate of tear-film lipid layer determined by fluorophotometry. *Br J Ophthalmol.* 2009;93:1535–1538.
351. Napoli PE, Coronella F, Satta GM, Fossarello M. A novel technique of contrast-enhanced optical coherence tomography imaging in evaluation of clearance of lipids in human tears. *PLoS One.* 2014;9:e109843.
352. Bai Y, Ngo W, Nichols JJ. Characterization of the thickness of the tear film lipid layer using high resolution microscopy. *Ocul Surf.* 2019;17:356–359.
353. Bai Y, Ngo W, Khanal S, Nichols KK, Nichols JJ. Human precorneal tear film and lipid layer dynamics in meibomian gland dysfunction. *Ocul Surf.* 2021;21:250–256.

354. Stegmann H, Aranha Dos Santos V, Schmidl D, et al. Classification of tear film lipid layer en face maps obtained using optical coherence tomography and their correlation with clinical parameters. *Cornea*. 2023;42:490–497.
355. Wong S, Murphy PJ, Jones L. Tear evaporation rates: what does the literature tell us? *Cont Lens Anterior Eye*. 2018;41:297–306.
356. Mathers WD, Lane JA, Zimmerman MB. Tear film changes associated with normal aging. *Cornea*. 1996;15:229–234.
357. Kim YH, Graham AD, Li W, et al. Tear-film evaporation flux and its relationship to tear properties in symptomatic and asymptomatic soft-contact-lens wearers. *Cont Lens Anterior Eye*. 2023;46:101850.
358. Goto E, Endo K, Suzuki A, Fujikura Y, Matsumoto Y, Tsubota K. Tear evaporation dynamics in normal subjects and subjects with obstructive meibomian gland dysfunction. *Invest Ophthalmol Vis Sci*. 2003;44:533–539.
359. Petznick A, Tan JH, Boo SK, Lee SY, Acharya UR, Tong L. Repeatability of a new method for measuring tear evaporation rates. *Optom Vis Sci*. 2013;90:366–371.
360. Yeo S, Tan JH, Acharya UR, Sudarshan VK, Tong L. Longitudinal changes in tear evaporation rates after eyelid warming therapies in meibomian gland dysfunction. *Invest Ophthalmol Vis Sci*. 2016;57:1974–1981.
361. Monfared N, Murphy PJ. Features and influences on the normal tear evaporation rate. *Cont Lens Anterior Eye*. 2023;46:101809.
362. Kimball SH, PE King-Smith, Nichols JJ. Evidence for the major contribution of evaporation to tear film thinning between blinks. *Invest Ophthalmol Vis Sci*. 2010;51:6294–6297.
363. Persiya J, Sasithradevi A. Thermal mapping the eye: a critical review of advances in infrared imaging for disease detection. *J Therm Biol*. 2024;121:103867.
364. Tan LL, Sanjay S, Morgan PB. Repeatability of infrared ocular thermography in assessing healthy and dry eyes. *Cont Lens Anterior Eye*. 2016;39:284–292.
365. Moghadas M, Nosch DS, Käser E, et al. Ocular thermography and clinical measurements in symptomatic and asymptomatic soft contact lens wearers. *Optom Vis Sci*. 2024;101:595–602.
366. Shah AM, Galor A. Impact of ocular surface temperature on tear characteristics: current insights. *Clin Optom (Auckl)*. 2021;13:51–62.
367. Matteoli S, Favuzza E, Mazzantini L, et al. Ocular surface temperature in patients with evaporative and aqueous-deficient dry eyes: a thermographic approach. *Physiol Meas*. 2017;38:1503–1512.
368. Yamaguchi M, Sakane Y, Kamao T, et al. Noninvasive dry eye assessment using high-technology ophthalmic examination devices. *Cornea*. 2016;35(suppl 1):S38–S48.
369. Craig JP, Singh I, Tomlinson A, Morgan PB, Efron N. The role of tear physiology in ocular surface temperature. *Eye (Lond)*. 2000;14(Pt 4):635–641.
370. Su TY, Ho WT, Chiang SC, Lu CY, Chiang HK, Chang SW. Infrared thermography in the evaluation of meibomian gland dysfunction. *J Formos Med Assoc*. 2017;116:554–559.
371. Korb DR, Blackie CA. Meibomian gland diagnostic expressibility: correlation with dry eye symptoms and gland location. *Cornea*. 2008;27:1142–1147.
372. Bilkhu P, Vidal-Rohr M, Trave-Huarte S, Wolffsohn JS. Effect of meibomian gland morphology on functionality with applied treatment. *Cont Lens Anterior Eye*. 2022;45:101402.
373. Li Y, Lu J, Zhou Q, et al. Analysis of clinical and regional distribution characteristics of obstructive meibomian gland dysfunction in china: a multicenter study. *Curr Eye Res*. 2020;45:1373–1379.
374. Sang X, Li Y, Yang L, et al. Lipid layer thickness and tear meniscus height measurements for the differential diagnosis of evaporative dry eye subtypes. *Int J Ophthalmol*. 2018;11:1496–1502.
375. Yang B, Wen K, Li J, et al. Quantitative evaluation of lipid layer thickness and blinking in children with allergic conjunctivitis. *Graefes Arch Clin Exp Ophthalmol*. 2021;259:2795–2805.
376. Yokoi N, Komuro A. Non-invasive methods of assessing the tear film. *Exp Eye Res*. 2004;78:399–407.
377. Nakayama N, Kawashima M, Kaido M, Arita R, Tsubota K. Analysis of meibum before and after intraductal meibomian gland probing in eyes with obstructive meibomian gland dysfunction. *Cornea*. 2015;34:1206–1208.
378. Li Q, Jiao SJ, Wang YQ, Xie HT, Zhang MC. Development of a novel tear lipid test strip. *Cornea*. 2022;41:232–237.
379. Niedernolte B, Trunk L, Wolffsohn JS, Pult H, Bandlitz S. Evaluation of tear meniscus height using different clinical methods. *Clin Exp Optom*. 2021;104:583–588.
380. Sabucedo-Villamarin B, Pena-Verdeal H, Garcia-Queiruga J, Giraldez MJ, Garcia-Resua C, Yebra-Pimentel E. Categorization of the aqueous deficient dry eye by a cut-off criterion of TMH measured with Tearscope. *Life (Basel)*. 2022;12.
381. Guinel M, Bitton E. Does the palpebral morphology influence the tear meniscus height between Caucasian and Asian eyes? *Optom Vis Sci*. 2024;101:537–541.
382. Wolffsohn JS, Ayaz M, Bandlitz S, von der Höf F, Ebner A, Craig JP. Optimising the methodology for assessing tear meniscus height when using a digital camera. *Cont Lens Anterior Eye*. 2025;48(4):102419.
383. Yokoi N, Bron A, Tiffany J, Brown N, Hsuan J, Fowler C. Reflective meniscometry: a non-invasive method to measure tear meniscus curvature. *Br J Ophthalmol*. 1999;83:92–97.
384. Yokoi N, Bron AJ, Tiffany JM, Kinoshita S. Reflective meniscometry: a new field of dry eye assessment. *Cornea*. 2000;19:S37–S43.
385. Fukuda R, Usui T, Miyai T, Yamagami S, Amano S. Tear meniscus evaluation by anterior segment swept-source optical coherence tomography. *Am J Ophthalmol*. 2013;155:620–624.
386. Ibrahim OM, Dogru M, Takano Y, et al. Application of visante optical coherence tomography tear meniscus height measurement in the diagnosis of dry eye disease. *Ophthalmology*. 2010;117:1923–1929.
387. Qiu X, Gong L, Lu Y, Jin H, Robitaille M. The diagnostic significance of Fourier-domain optical coherence tomography in Sjögren syndrome, aqueous tear deficiency and lipid tear deficiency patients. *Acta Ophthalmol*. 2012;90:e359–e366.
388. Qiu X, Gong L, Sun X, Jin H. Age-related variations of human tear meniscus and diagnosis of dry eye with Fourier-domain anterior segment optical coherence tomography. *Cornea*. 2011;30:543–549.
389. Akiyama R, Usui T, Yamagami S. Diagnosis of dry eye by tear meniscus measurements using anterior seg-

- ment swept source optical coherence tomography. *Cornea*. 2015;34(suppl 11):S115–S120.
390. Elhusseiny AM, Khalil AA, El Sheikh RH, Bakr MA, Eissa MG, El Sayed YM. New approaches for diagnosis of dry eye disease. *Int J Ophthalmol*. 2019;12:1618–1628.
  391. Singh S, Srivastav S, Modiwala Z, Ali MH, Basu S. Repeatability, reproducibility and agreement between three different diagnostic imaging platforms for tear film evaluation of normal and dry eye disease. *Eye (Lond)*. 2023;37:2042–2047.
  392. Pult H, Riede-Pult BH. Impact of conjunctival folds on central tear meniscus height. *Invest Ophthalmol Vis Sci*. 2015;56:1459–1466.
  393. Wang Y, Xu Z, Gong Q, et al. The role of different tear volume detection methods in the evaluation and diagnosis of mild dry eye disease. *Transl Vis Sci Technol*. 2022;11:15.
  394. Tomlinson A, Blades KJ, Pearce EI. What does the phenol red thread test actually measure? *Optom Vis Sci*. 2001;78:142–146.
  395. Hao Y, Jin T, Zhu L, et al. Validation of the phenol red thread test in a Chinese population. *BMC Ophthalmol*. 2023;23:498.
  396. Moore JE, Graham JE, Goodall EA, et al. Concordance between common dry eye diagnostic tests. *Br J Ophthalmol*. 2009;93:66–72.
  397. Vashisht S, Singh S. Evaluation of phenol red thread test versus Schirmer test in dry eyes: a comparative study. *Int J Appl Basic Med Res*. 2011;1:40–42.
  398. Masmali A, Alqahtani TA, Alharbi A, El-Hiti GA. Comparative study of repeatability of phenol red thread test versus Schirmer test in normal adults in Saudi Arabia. *Eye Contact Lens*. 2014;40:127–131.
  399. Patel S, Farrell J, Blades KJ, Grierson DJ. The value of a phenol red impregnated thread for differentiating between the aqueous and non-aqueous deficient dry eye. *Ophthalmic Physiol Opt*. 1998;18:471–476.
  400. Senchyna M, Wax MB. Quantitative assessment of tear production: a review of methods and utility in dry eye drug discovery. *J Ocul Biol Dis Infor*. 2008;1:1–6.
  401. Puentes B, Hisey EA, Ferneding M, et al. Development and validation of a method to generate phenol red thread tests. *Ocul Surf*. 2024;34:262–266.
  402. Li N, Deng XG, He MF. Comparison of the Schirmer I test with and without topical anesthesia for diagnosing dry eye. *Int J Ophthalmol*. 2012;5:478–481.
  403. Wang X, Fan X, Wu Y, Mou Y, Min J, Jin X. Rear 4-min Schirmer test, a modified indicator of Schirmer test in diagnosing dry eye. *Sci Rep*. 2022;12:6272.
  404. Miyasaka K, Ayaki M, Negishi K. Tear strip meniscometry and its clinical application: analysis of more than 2000 cases. *Transl Vis Sci Technol*. 2022;11:3.
  405. Dogru M, Ishida K, Matsumoto Y, et al. Strip meniscometry: a new and simple method of tear meniscus evaluation. *Invest Ophthalmol Vis Sci*. 2006;47:1895–1901.
  406. Alshammeri S, Madden L, Hagan S, Pearce EI. Strip meniscometry tube: a rapid method for assessing aqueous deficient dry eye. *Clin Exp Optom*. 2020;103:469–473.
  407. Hao Y, Tian L, Cao K, Jie Y. Repeatability and reproducibility of SMTube measurement in dry eye disease patients. *J Ophthalmol*. 2021;2021:1589378.
  408. Negishi K, Ayaki M, Uchino M, Takei K, Tsubota K. Strip meniscometry correlates with ocular surface tests and symptoms. *Transl Vis Sci Technol*. 2020;9:31.
  409. Garaszczuk IK, Iskander DR. Qualitative assessment of tear dynamics with fluorescein profilometry. *Cont Lens Anterior Eye*. 2017;40:208–212.
  410. Lim P, Han TA, Tong L. Short-term changes in tear lipid layer thickness after instillation of lipid containing eye drops. *Transl Vis Sci Technol*. 2020;9:29.
  411. Alotaibi WM, Abusharha A, Pearce EI, Althomali M, Afsar T, Razak S. Assessment of tamarind seed polysaccharide (TSP) and hyaluronic acid (HA) containing ophthalmic solution to maintain tear osmolarity, ocular surface temperature (OST) and tear production. *Clin Ophthalmol*. 2024;18:3503–3513.
  412. Abusharha A, Pearce EI, Afsar T, Razak S. Evaluation of therapeutic efficacy of Emustil drops for ocular discomfort and tear film osmolarity using different treatment management modes under dry environmental conditions. *BMC Ophthalmol*. 2024;24:129.
  413. Abusharha A, Pearce EI, Alsaqar A, Fagehi R, Afsar T, Razak S. Efficacy of hydroxypropyl-guar drops in improving tear film index and ocular surface dynamics using two treatment methods under a controlled desiccating environment. *Int Ophthalmol*. 2024;44:175.
  414. Garaszczuk IK, Mousavi M, Cervino Exposito A, Bartuzel MM, Montes-Mico R, Iskander DR. Evaluating tear clearance rate with optical coherence tomography. *Cont Lens Anterior Eye*. 2018;41:54–59.
  415. Erhamamci S, Karalezli A, Yilmaz S, Aktas A. The clinical value and histopathological correlation of lacrimal scintigraphy in patients with primary Sjogren's syndrome. *Nucl Med Commun*. 2012;33:689–694.
  416. Gencoglu EA, Dursun D, Akova YA, Cengiz F, Yalcin H, Koyuncu A. Tear clearance measurement in patients with dry eye syndrome using quantitative lacrimal scintigraphy. *Ann Nucl Med*. 2005;19:581–587.
  417. Singh S, Shanbhag SS, Basu S. Tear secretion from the lacrimal gland: variations in normal versus dry eyes. *Br J Ophthalmol*. 2022;106:772–776.
  418. Merino ML, Belmonte J, Rosas J, Acosta MC, Gallar J, Belmonte C. Maximal tear secretion evoked by controlled stimulation of corneal sensory nerves in healthy individuals and dry eye subjects. *Ocul Surf*. 2023;27:80–88.
  419. Chang AY, Purt B. *Biochemistry, tear film*. 2024.
  420. Versura P, Giannaccare G, Vukatana G, Mule R, Malavolta N, Campos EC. Predictive role of tear protein expression in the early diagnosis of Sjogren's syndrome. *Ann Clin Biochem*. 2018;55:561–570.
  421. Caffery B, Joyce E, Boone A, et al. Tear lipocalin and lysozyme in Sjogren and non-Sjogren dry eye. *Optom Vis Sci*. 2008;85:661–667.
  422. Sonobe H, Ogawa Y, Yamada K, et al. A novel and innovative paper-based analytical device for assessing tear lactoferrin of dry eye patients. *Ocul Surf*. 2019;17:160–166.
  423. Lin Y, Zhang Y, Shi K, Wu H, Ou S. Advances in clinical examination of lacrimal gland. *Front Med (Lausanne)*. 2023;10:1257209.
  424. Ballow M, Donshik PC, Rapacz P, Samartino L. Tear lactoferrin levels in patients with external inflammatory ocular disease. *Invest Ophthalmol Vis Sci*. 1987;28:543–545.
  425. Kiratli H, Irkeç M, Orhan M. Tear lactoferrin levels in chronic meibomitis associated with acne rosacea. *Eur J Ophthalmol*. 2000;10:11–14.



426. Rapacz P, Tedesco J, Donshik PC, Ballow M. Tear lysozyme and lactoferrin levels in giant papillary conjunctivitis and vernal conjunctivitis. *CLAO J.* 1988;14:207–209.
427. Velamakanni GS, Sharma A, Batra HS, Velamakanni SM, Khan M, Gupta S. Evaluation of tear film urea level as a diagnostic marker of dry eye disease: a pilot study. *J Lab Physicians.* 2022;14:43–46.
428. Hori Y. Secreted mucins on the ocular surface. *Invest Ophthalmol Vis Sci.* 2018;59:DES151–DES156.
429. Argüeso P, Balaram M, Spurr-Michaud S, Keutmann HT, Dana MR, Gipson IK. Decreased levels of the goblet cell mucin MUC5AC in tears of patients with Sjögren syndrome. *Invest Ophthalmol Vis Sci.* 2002;43:1004–1011.
430. Mantelli F, Tiberi E, Micera A, Lambiasi A, Visintini F, Bonini S. MUC5AC overexpression in tear film of neonates. *Graefes Arch Clin Exp Ophthalmol.* 2007;245:1377–1381.
431. You Y, Chen J, Chen H, et al. Investigation of conjunctival goblet cell and tear MUC5AC protein in patients with Graves' ophthalmopathy. *Transl Vis Sci Technol.* 2023;12:19.
432. Danjo Y, Watanabe H, Tisdale AS, et al. Alteration of mucin in human conjunctival epithelia in dry eye. *Invest Ophthalmol Vis Sci.* 1998;39:2602–2609.
433. Argüeso P, Spurr-Michaud S, Russo CL, Tisdale A, Gipson IK. MUC16 mucin is expressed by the human ocular surface epithelia and carries the H185 carbohydrate epitope. *Invest Ophthalmol Vis Sci.* 2003;44:2487–2495.
434. Choi M, Tichenor AA. Regional conjunctival differences in glycocalyx mucin expression in dry eye and normal subjects. *Invest Ophthalmol Vis Sci.* 2024;65:20.
435. Inatomi T, Spurr-Michaud S, Tisdale AS, Gipson IK. Human corneal and conjunctival epithelia express MUC1 mucin. *Invest Ophthalmol Vis Sci.* 1995;36:1818–1827.
436. Nakamura Y, Yokoi N, Tokushige H, Kinoshita S. Sialic acid in human tear fluid decreases in dry eye. *Jpn J Ophthalmol.* 2004;48:519–523.
437. Uchino Y, Mauris J, Woodward AM, et al. Alteration of galectin-3 in tears of patients with dry eye disease. *Am J Ophthalmol.* 2015;159:1027–1035.
438. Hata-Mizuno M, Uchino Y, Uchino M, et al. Analysis of the Association between Galectin-3 concentration in tears and the severity of dry eye disease: a case-control study. *J Clin Med.* 2021;11.
439. Argüeso P, Tisdale A, Spurr-Michaud S, Sumiyoshi M, Gipson IK. Mucin characteristics of human corneal-limbal epithelial cells that exclude the rose bengal anionic dye. *Invest Ophthalmol Vis Sci.* 2006;47:113–119.
440. Srinivas SP, Rao SK. Ocular surface staining: current concepts and techniques. *Indian J Ophthalmol.* 2023;71:1080–1089.
441. Vujkovic V, Mikac G, Kozomara R. Distribution and density of conjunctival goblet cells. *Med Pregl.* 2002;55:195–200.
442. Liu Y, Duan Z, Yuan J, Xiao P. Imaging assessment of conjunctival goblet cells in dry eye disease. *Clin Exp Ophthalmol.* 2024;52(5):576–588.
443. Matsumoto Y, Ibrahim OMA, Kojima T, Dogru M, Shimazaki J, Tsubota K. Corneal in vivo laser-scanning confocal microscopy findings in dry eye patients with Sjögren's syndrome. *Diagnostics (Basel).* 2020:10.
444. Mastropasqua R, Fasanella V, Brescia L, et al. In vivo confocal imaging of the conjunctiva as a predictive tool for the glaucoma filtration surgery outcome. *Invest Ophthalmol Vis Sci.* 2017;58:Bio114–Bio120.
445. Simsek C, Dogru M, Shinzawa M, et al. The efficacy of 2% topical rebamipide on conjunctival squamous metaplasia and goblet cell density in dry eye disease. *J Ocul Pharm Ther.* 2019;35:350–358.
446. Masmali AM, Purslow C, Murphy PJ. The tear ferning test: a simple clinical technique to evaluate the ocular tear film. *Clin Exp Optom.* 2014;97:399–406.
447. Horwath J, Ettinger K, Bachernegg M, Bodner E, Schmut O. Ocular ferning test—effect of temperature and humidity on tear Ferning patterns. *Ophthalmologica.* 2001;215:102–107.
448. Rolando M. Tear mucus ferning test in normal and keratoconjunctivitis sicca eyes. *Chibret Int J Ophthalmol.* 1984;2:33–41.
449. Pearce EI, Tomlinson A. Spatial location studies on the chemical composition of human tear ferns. *Ophthalmic Physiol Optics.* 2000;20:306–313.
450. Masmali AM. Improvement of ferning patterns of lubricant eye drops mixed with various electrolytes and carboxymethylcellulose. *Cont Lens Anterior Eye.* 2019;42:633–639.
451. Dutta D, Kim J, Sarkes M, Nath S, Markoulli M. The repeatability of subjective and objective tear ferning assessment and its association with lipid layer thickness, non-invasive tear break-up time and comfort. *Cont Lens Anterior Eye.* 2019;42:420–427.
452. Sharanjeet K, Ho CY, Mutalib HA, Ghazali AR. The relationship between tear ferning patterns and non-invasive tear break-up time in normal Asian population. *J Optom.* 2016;9:175–181.
453. Puderbach S, Stolze HH. Tear ferning and other lacrimal tests in normal persons of different ages. *Int Ophthalmol.* 1991;15:391–395.
454. Mantelli F, Argüeso P. Functions of ocular surface mucins in health and disease. *Curr Opin Allergy Clin Immunol.* 2008;8:477–483.
455. Bron AJ, Tiffany JM, Gouveia SM, Yokoi N, Voon LW. Functional aspects of the tear film lipid layer. *Exp Eye Res.* 2004;78:347–360.
456. Tsubota K. Tear dynamics and dry eye. *Prog Retinal Eye Res.* 1998;17:565–596.
457. Tong J, Lopez MJ, Patel BC. *Anatomy, head and neck: orbicularis oculi muscle.* StatPearls; 2024.
458. Knight B, Lopez MJ, Patel BC. *Anatomy, head and neck: levator palpebrae superioris muscle.* StatPearls; 2024.
459. Ogino MH, Tadi P. *Neuroanatomy, trigeminal reflexes.* StatPearls; 2024.
460. Cruz AA, Garcia DM, Pinto CT, Cechetti SP. Spontaneous eyeblink activity. *Ocul Surf.* 2011;9:29–41.
461. Godfrey KJ, Wilsen C, Satterfield K, Korn BS, Kikkawa DO. Analysis of spontaneous eyelid blink dynamics using a 240 frames per second smartphone camera. *Ophthalmic Plast Reconstr Surg.* 2019;35:503–505.
462. Mitchell T, Murri M, Pflugfelder SC. Video viewing blink rate in normal and dry eyes. *Eye Contact Lens.* 2021;47:442–444.
463. Wang MTM, Power B, Xue AL, Craig JP. Blink completeness and rate in dry eye disease: an investigator-masked, prospective registry-based, cross-sectional, prognostic study. *Cont Lens Anterior Eye.* 2025;48(3):102369.

464. Jie Y, Sella R, Feng J, Gomez ML, Afshari NA. Evaluation of incomplete blinking as a measurement of dry eye disease. *Ocul Surf*. 2019;17:440–446.
465. Li Y, Li S, Zhou J, Liu C, Xu M. Relationship between lipid layer thickness, incomplete blinking rate and tear film instability in patients with different myopia degrees after small-incision lenticule extraction. *PLoS One*. 2020;15:e0230119.
466. Jeon YJ, Song MY, Kim KY, Hwang KY, Kwon YA, Koh K. Relationship between the partial blink rate and ocular surface parameters. *Int Ophthalmol*. 2021;41:2601–2608.
467. Shew W, Muntz A, Dean SJ, Pult H, Wang MTM, Craig JP. Blinking and upper eyelid morphology. *Cont Lens Anterior Eye*. 2022;45:101702.
468. Nelson JD, Shimazaki J, Benitez-del-Castillo JM, et al. The International Workshop on Meibomian Gland Dysfunction: report of the Definition and Classification Subcommittee. *Invest Ophthalmol Vis Sci*. 2011;52:1930–1937.
469. Knop E, Knop N, Millar T, Obata H, Sullivan DA. The International Workshop on Meibomian Gland Dysfunction: report of the Subcommittee on Anatomy, Physiology, and Pathophysiology of the Meibomian Gland. *Invest Ophthalmol Vis Sci*. 2011;52:1938–1978.
470. Rynerson JM, Perry HD. DEBS—a unification theory for dry eye and blepharitis. *Clin Ophthalmol*. 2016;10:2455–2467.
471. Guillon M, Maissa C, Wong S. Symptomatic relief associated with eyelid hygiene in anterior blepharitis and MGD. *Eye Contact Lens*. 2012;38:306–312.
472. Assayag E, Abulafia A, Teren D, Gelman E, Givoni H, Zadok D. Efficacy of 1% povidone-iodine in the treatment of anterior blepharitis-randomized single-center controlled trial. *J Clin Med*. 2024;13.
473. Siddireddy JS, Tan J, Vijay AK, Willcox MDP. The effect of microblepharon exfoliation on clinical correlates of contact lens discomfort. *Optom Vis Sci*. 2019;96:187–199.
474. Siddireddy JS, Vijay AK, Tan J, Willcox M. Effect of eyelid treatments on bacterial load and lipase activity in relation to contact lens discomfort. *Eye Contact Lens*. 2020;46:245–253.
475. Kim AD, Muntz A, Lee J, Wang MTM, Craig JP. Therapeutic benefits of blinking exercises in dry eye disease. *Cont Lens Anterior Eye*. 2021;44:101329.
476. de Paula A, Oliva G, Barraquer RI, de la Paz MF. Prevalence and antibiotic susceptibility of bacteria isolated in patients affected with blepharitis in a tertiary eye centre in Spain. *Eur J Ophthalmol*. 2020;30:991–997.
477. Rocha KM, Farid M, Raju L, et al. Eyelid margin disease (blepharitis and meibomian gland dysfunction): clinical review of evidence-based and emerging treatments. *J Cataract Refract Surg*. 2024;50(8):876–882.
478. Teweldemedhin M, Saravanan M, Gebreyesus A, Gebreegzi-abihier D. Ocular bacterial infections at Quilha Ophthalmic Hospital, Northern Ethiopia: an evaluation according to the risk factors and the antimicrobial susceptibility of bacterial isolates. *BMC Infect Dis*. 2017;17:207.
479. Marasini S, Swift S, Dean SJ, Ormonde SE, Craig JP. Spectrum and sensitivity of bacterial keratitis isolates in Auckland. *J Ophthalmol*. 2016;2016:3769341.
480. Sakimoto T, Sugiura T. Clinical features of anterior blepharitis after cataract surgery. *Sci Rep*. 2023;13:6615.
481. Rhee MK, Yeu E, Barnett M, et al. Demodex blepharitis: a comprehensive review of the disease, current management, and emerging therapies. *Eye Contact Lens*. 2023;49:311–318.
482. Rabensteiner DF, Aminfar H, Boldin I, et al. Demodex mite infestation and its associations with tear film and ocular surface parameters in patients with ocular discomfort. *Am J Ophthalmol*. 2019;204:7–12.
483. Luo X, Li J, Chen C, Tseng S, Liang L. Ocular demodicosis as a potential cause of ocular surface inflammation. *Cornea*. 2017;36(suppl 1):S9–S14.
484. Norn MS. Incidence of Demodex folliculorum on skin of lids and nose. *Acta Ophthalmol*. 1982;60:575–583.
485. Sharma N, Martin E, Pearce EI, Hagan S. A Delphi approach to establishing consensus on best practice for the diagnosis and treatment of Demodex blepharitis. *Cont Lens Anterior Eye*. 2024;47:102080.
486. Ayres BD, Donnenfeld E, Farid M, et al. Clinical diagnosis and management of Demodex blepharitis: the Demodex Expert Panel on Treatment and Eyelid Health (DEPTH). *Eye (Lond)*. 2023;37:3249–3255.
487. Man Peles I, Zahavi A, Chemodanova E, Vardizer Y. Novel in-office technique for visual confirmation of Demodex infestation in blepharitic patients. *Cornea*. 2020;39:858–861.
488. Shah PP, Stein RL, Perry HD. Update on the management of Demodex blepharitis. *Cornea*. 2022;41:934–939.
489. Mastrotta KM. Method to identify Demodex in the eyelash follicle without epilation. *Optom Vis Sci*. 2013;90:e172–e174.
490. Bitton E, Wittich W. Double-blind comparison of eyelash epilation techniques for the purpose of Demodex folliculorum mite retrieval. *Eye Contact Lens*. 2024;50:152–157.
491. Muntz A, Purslow C, Wolffsohn JS, Craig JP. Improved Demodex diagnosis in the clinical setting using a novel in situ technique. *Cont Lens Anterior Eye*. 2020;43:345–349.
492. Zhang AC, Muntz A, Wang MTM, Craig JP, Downie LE. Ocular Demodex: a systematic review of the clinical literature. *Ophthalmic Physiol Opt*. 2020;40:389–432.
493. Gupta PK, Karpecki P. Comprehensive assessment of the meibomian glands by meibography: why the upper eyelids matter. *Cornea*. 2025;44.
494. Amano S, Shimazaki J, Yokoi N, Hori Y, Arita R. Meibomian Gland Dysfunction Clinical Practice Guidelines Committee. Meibomian gland dysfunction clinical practice guidelines. *Jpn J Ophthalmol*. 2023;67:448–539.
495. Feng J, Wang J, Wu B, et al. Association of meibomian gland morphology with orifice plugging and lid margin thickening in meibomian gland dysfunction patients. *Int Ophthalmol*. 2023;43:3207–3218.
496. Crespo-Treviño RR, Salinas-Sánchez AK, Amparo F, Garza-Leon M. Comparative of meibomian gland morphology in patients with evaporative dry eye disease versus non-dry eye disease. *Sci Rep*. 2021;11:20729.
497. Arita R, Minoura I, Morishige N, et al. Development of definitive and reliable grading scales for meibomian gland dysfunction. *Am J Ophthalmol*. 2016;169:125–137.
498. Daniel E, Maguire MG, Pistilli M, et al. Grading and baseline characteristics of meibomian glands in meibography images and their clinical associations in the Dry Eye Assessment and Management (DREAM) study. *Ocul Surf*. 2019;17:491–501.
499. Pult H, Riede-Pult B. Comparison of subjective grading and objective assessment in meibography. *Cont Lens Anterior Eye*. 2013;36:22–27.
500. Fu J, Chou Y, Hao R, Jiang X, Liu Y, Li X. Evaluation of ocular surface impairment in meibomian gland dysfunction.

- tion of varying severity using a comprehensive grading scale. *Medicine*. 2019;98:e16547.
501. Opitz DL, Tyler KF. Efficacy of azithromycin 1% ophthalmic solution for treatment of ocular surface disease from posterior blepharitis. *Clin Exp Optom*. 2011;94:200–206.
  502. Hwang HS, Parfitt GJ, Brown DJ, Jester JV. Meibocyte differentiation and renewal: Insights into novel mechanisms of meibomian gland dysfunction (MGD). *Exp Eye Res*. 2017;163:37–45.
  503. Adil MY, Xiao J, Olafsson J, et al. Meibomian gland morphology is a sensitive early indicator of meibomian gland dysfunction. *Am J Ophthalmol*. 2019;200:16–25.
  504. Arita R, Itoh K, Inoue K, Amano S. Noncontact infrared meibography to document age-related changes of the meibomian glands in a normal population. *Ophthalmology*. 2008;911–915.
  505. Arita R, Itoh K, Maeda S, et al. Proposed diagnostic criteria for obstructive meibomian gland dysfunction. *Ophthalmology*. 2009;116:2058–2063.
  506. Fineide F, Arita R, Utheim TP. The role of meibography in ocular surface diagnostics: a review. *Ocul Surf*. 2021;19:133–144.
  507. Vunnavu KP, Shetty R, Prabhu SM, Tiwari P, Kummelil MK. Automatic segmentation and quantified analysis of meibomian glands from infrared images. *Indian J Ophthalmol*. 2023;71:1426–1431.
  508. Lin X, Fu Y, Li L, et al. A novel quantitative index of meibomian gland dysfunction, the meibomian gland tortuosity. *Transl Vis Sci Technol*. 2020;9:34.
  509. Wang MTM, Power B, Xue AL, Kim JS, Craig JP. Diagnostic performance of qualitative and quantitative methods of meibomian gland dropout evaluation in dry eye disease: an investigator-masked, randomised crossover study. *Cont Lens Anterior Eye*. 2024;102324.
  510. Arita R. Meibography: a Japanese perspective. *Invest Ophthalmol Vis Sci*. 2018;59:Des48–Des55.
  511. Wang MTM, Wolffsohn JS, Kim JS, et al. Meibomian gland tortuosity, truncation, and dilation in paediatric dry eye disease: a multi-centre, investigator-masked, cross-sectional study. *Ocul Surf*. 2024;34:441–443.
  512. von Ahrentschildt A, Hanenberg L, Robich ML, et al. Morphological characteristics of meibomian glands and their influence on dry eye disease in contact lens wearers. *Ocul Surf*. 2022;24:93–99.
  513. Ravichandran S, Pucker AD. Comparing meibomian gland visibility on optical coherence tomography and Keratograph 5M images using objective and subjective grading methods. *Cont Lens Anterior Eye*. 2024;47:102162.
  514. Randon M, Aragno V, Abbas R, Liang H, Labbé A, Baudouin C. In vivo confocal microscopy classification in the diagnosis of meibomian gland dysfunction. *Eye (Lond)*. 2019;33:754–760.
  515. Zhou S, Robertson DM. wide-field in vivo confocal microscopy of meibomian gland acini and rete ridges in the eyelid margin. *Invest Ophthalmol Vis Sci*. 2018;59:4249–4257.
  516. Li M, Yu Y, Yuan Y, et al. Rete ridges in eyelid margin and inflammatory cytokines in meibomian gland dysfunction associated with dry eye symptom. *Curr Eye Res*. 2021;46:202–209.
  517. Muntz A, Subbaraman LN, Craig JP, Jones L. Cytomorphological assessment of the lid margin in relation to symptoms, contact lens wear and lid wiper epitheliopathy. *Ocul Surf*. 2020;18:214–220.
  518. Knop E, Knop N, Zhivov A, et al. The lid wiper and muco-cutaneous junction anatomy of the human eyelid margins: an in vivo confocal and histological study. *J Anat*. 2011;218:449–461.
  519. Shanbhag SS, Singh S, Koshy PG, Donthineni PR, Basu S. A beginner's guide to mucous membrane grafting for lid margin keratinization: review of indications, surgical technique and clinical outcomes. *Indian J Ophthalmol*. 2021;69:794–805.
  520. Ahn H, Ji YW, Jun I, Kim TI, Lee HK, Seo KY. Effects of meibomian gland dysfunction and aqueous deficiency on friction-related disease. *Ocul Surf*. 2022;26:295–299.
  521. Koduri MA, Pingali T, Prasad D, et al. Neutrophil-driven and interleukin-36 $\gamma$ -associated ocular surface inflammation in chronic Stevens-Johnson syndrome. *Allergy*. 2024;79:2128–2143.
  522. D'Souza S, Nair AP, Ashok N, et al. Elevated neutrophils and reduced NK cells are associated with altered tear molecular signatures and clinical sequelae of chronic ocular Stevens-Johnson syndrome. *Ocul Surf*. 2024;34:9–21.
  523. Cermak JM, Krenzer KL, Sullivan RM, Dana MR, Sullivan DA. Is complete androgen insensitivity syndrome associated with alterations in the meibomian gland and ocular surface? *Cornea*. 2003;22:516–521.
  524. Chen H, Gao H, Xie HT, Liu ST, Huang YK, Zhang MC. Hyperkeratinization and proinflammatory cytokine expression in meibomian glands induced by *Staphylococcus aureus*. *Invest Ophthalmol Vis Sci*. 2021;62:11.
  525. Schröder A, Abrar DB, Hampel U, Schicht M, Paulsen F, Garreis F. In vitro effects of sex hormones in human meibomian gland epithelial cells. *Exp Eye Res*. 2016;151:190–202.
  526. Ji C, Guo Y, Liu Y, et al. Inhibition of ceramide de novo synthesis ameliorates meibomian gland dysfunction induced by SCD1 deficiency. *Ocul Surf*. 2021;22:230–241.
  527. Bu J, Wu Y, Cai X, et al. Hyperlipidemia induces meibomian gland dysfunction. *Ocul Surf*. 2019;17:777–786.
  528. Ibrahim MAA, Elwan WM. Role of topical dehydroepiandrosterone in ameliorating isotretinoin-induced Meibomian gland dysfunction in adult male albino rat. *Ann Anat*. 2017;211:78–87.
  529. Redd TK, Seitzman GD. Ocular rosacea. *Curr Opin Ophthalmol*. 2020;31:503–507.
  530. Gallo RL, Granstein RD, Kang S, et al. Standard classification and pathophysiology of rosacea: the 2017 update by the National Rosacea Society Expert Committee. *J Am Acad Dermatol*. 2018;78:148–155.
  531. Sobolewska B, Schaller M, Zierhut M. Rosacea and dry eye disease. *Ocul Immunol Inflamm*. 2022;30:570–579.
  532. Ye F, Zhou F, Xia Y, Zhu X, Wu Y, Huang Z. Evaluation of meibomian gland and tear film changes in patients with pterygium. *Indian J Ophthalmol*. 2017;65.
  533. Wanzeler ACV, Barbosa IAF, Duarte B, Barbosa EB, Borges DA, Alves M. Impact of pterygium on the ocular surface and meibomian glands. *PLoS One*. 2019;14:e0213956.
  534. Dong N, Li W, Lin H, et al. Abnormal epithelial differentiation and tear film alteration in pinguecula. *Invest Ophthalmol Vis Sci*. 2009;50:2710–2715.
  535. Ballesteros-Sánchez A, Sánchez-González J-M, Borrone MA, Borroni D, Rocha-de-Lossada C. The influence of lid-parallel conjunctival folds and conjunctivochalasis



- on dry eye symptoms with and without contact lens wear: a review of the literature. *Ophthalmol Ther*. 2024;13:651–670.
536. Linaburg T, Choi D, Bunya VY, Massaro-Giordano M, Briceno CA. Systematic review: effects of pterygium and pingueculum on the ocular surface and efficacy of surgical excision. *Cornea*. 2021;40:258–267.
  537. Pult H, Tosatti SGP, Spencer ND, Asfour J-M, Ebenhoch M, Murphy PJ. Spontaneous blinking from a tribological viewpoint. *Ocul Surf*. 2015;13:236–249.
  538. Gumus K, Pflugfelder SC. Increasing prevalence and severity of conjunctivochalasis with aging detected by anterior segment optical coherence tomography. *Am J Ophthalmol*. 2013;155:238–242.
  539. Höh H, Schirra F, Kienecker C, Ruprecht KW. Lid-parallel conjunctival folds (LIPCOF): a definite diagnostic sign of dry eye. *Ophthalmologe*. 1995;92:802–808.
  540. Pult H, Purslow C, Murphy PJ. The relationship between clinical signs and dry eye symptoms. *Eye (Lond)*. 2011;25:502–510.
  541. Pult H, Purslow C, Berry M, Murphy PJ. Clinical tests for successful contact lens wear: relationship and predictive potential. *Optom Vis Sci*. 2008;85:E924–E929.
  542. Pult H, Bandlitz S. Lid-parallel conjunctival folds and their ability to predict dry eye. *Eye Contact Lens*. 2018;44(suppl 2):S113–S119.
  543. Németh J, Fodor E, Lang Z, et al. Lid-parallel conjunctival folds (LIPCOF) and dry eye: a multicentre study. *Br J Ophthalmol*. 2012;96(11):1380–1385.
  544. Miller WL, Narayanan S, Jackson J, Bergmanson J. The association of bulbar conjunctival folds with other clinical findings in normal and moderate dry eye subjects. *Optometry (St Louis, Mo)*. 2003;74:576–582.
  545. Veres A, Tapasztó B, Kosina-Hagyo K, Somfai GM, Nemeth J. Imaging lid-parallel conjunctival folds with OCT and comparing its grading with the slit lamp classification in dry eye patients and normal subjects. *Invest Ophthalmol Vis Sci*. 2011;52:2945–2951.
  546. Bandlitz S, Purslow C, Murphy PJ, Pult H. Lid-parallel conjunctival fold (LIPCOF) morphology imaged by optical coherence tomography and its relationship to LIPCOF grade. *Cont Lens Anterior Eye*. 2019;42:299–303.
  547. Barbosa Ribeiro B, Marques JH, Baptista PM, et al. Corneal epithelial thickness correlation with dry eye symptom severity: a cross-sectional study. *Clin Ophthalmol*. 2024;18:3313–3320.
  548. Watson SL, Le DT-M. Corneal neuropathic pain: a review to inform clinical practice. *Eye*. 2024;38:2350–2358.
  549. Kaido M, Kawashima M, Ishida R, Tsubota K. Relationship of corneal pain sensitivity with dry eye symptoms in dry eye with short tear break-up time. *Invest Ophthalmol Vis Sci*. 2016;57:914–919.
  550. Wang MTM, Meyer JJ, Xue AL, Power B, Craig JP. Predictive performance of corneal and lid margin sensitivity for dry eye disease: an investigator-masked, prospective, prognostic accuracy study. *Ocul Surf*. 2024;33:11–15.
  551. Al-Aqaba MA, Dhillon VK, Mohammed I, Said DG, Dua HS. Corneal nerves in health and disease. *Prog Retinal Eye Res*. 2019;73:100762.
  552. Chiang JCB, Tran V, Wolffsohn JS. The impact of dry eye disease on corneal nerve parameters: a systematic review and meta-analysis. *Ophthalmic Physiol Opt*. 2023;43:1079–1091.
  553. Matsumoto Y, Ibrahim OMA. Application of in vivo confocal microscopy in dry eye disease. *Invest Ophthalmol Vis Sci*. 2018;59:DES41–DES47.
  554. Talens-Estarells C, Golebiowski B, Ehrmann K, García-Lázaro S, Cerviño A, Stapleton F. Corneal hypersensitivity to cold stimuli in symptomatic computer users. *Optom Vis Sci*. 2024;101.
  555. Kalteniece A, Ferdousi M, Adam S, et al. Corneal confocal microscopy is a rapid reproducible ophthalmic technique for quantifying corneal nerve abnormalities. *PLoS One*. 2017;12:e0183040.
  556. Cardigos J, Barcelos F, Carvalho H, et al. Tear meniscus and corneal sub-basal nerve plexus assessment in primary Sjogren Syndrome and Sicca syndrome patients. *Cornea*. 2019;38:221–228.
  557. Tepelus TC, Chiu GB, Huang J, et al. Correlation between corneal innervation and inflammation evaluated with confocal microscopy and symptomatology in patients with dry eye syndromes: a preliminary study. *Graefes Arch Clin Exp Ophthalmol*. 2017;255:1771–1778.
  558. Kheirikhah A, Satitpitakul V, Hamrah P, Dana R. Patients with dry eye disease and low sub-basal nerve density are at high risk for accelerated corneal endothelial cell loss. *Cornea*. 2017;36:196–201.
  559. Levy O, Labbe A, Borderie V, et al. Increased corneal sub-basal nerve density in patients with Sjogren syndrome treated with topical cyclosporine A. *Clin Exp Ophthalmol*. 2017;45:455–463.
  560. Machalińska A, Kuligowska A, Ziontkowska-Wrzalek A, et al. The severity of diabetic retinopathy corresponds with corneal nerve alterations and ocular discomfort of the patient. *Int J Mol Sci*. 2024;25.
  561. Gong Q, Huang K, Li K, et al. Structural and functional changes of binocular corneal innervation and ocular surface function after unilateral SMILE and tPRK. *Br J Ophthalmol*. 2024;108:1492–1499.
  562. Luzu J, Labbé A, Réaux-Le Goazigo A, et al. In vivo confocal microscopic study of corneal innervation in Sjögren's syndrome with or without small fiber neuropathy. *Ocul Surf*. 2022;25:155–162.
  563. Cañadas P, Lantigua Y, Enríquez-de-Salamanca A, et al. Ocular surface pathology in patients suffering from mercury intoxication. *Diagnostics (Basel)*. 2021;11.
  564. Colak D, Kocabeyoglu S, Karakaya J, Irkeç M. Association of ocular surface and meibomian gland alterations with silicone hydrogel contact lens wear. *Cont Lens Anterior Eye*. 2024;47:102093.
  565. Rahman EZ, Lam PK, Chu CK, Moore Q, Pflugfelder SC. Corneal sensitivity in tear dysfunction and its correlation with clinical parameters and blink rate. *Am J Ophthalmol*. 2015;160:858–866.
  566. Ross AR, Al-Aqaba MA, Almaazmi A, et al. Clinical and in vivo confocal microscopic features of neuropathic corneal pain. *Br J Ophthalmol*. 2020;104:768–775.
  567. Moein HR, Akhlaq A, Dieckmann G, et al. Visualization of microneuromas by using in vivo confocal microscopy: an objective biomarker for the diagnosis of neuropathic corneal pain? *Ocul Surf*. 2020;18:651–656.
  568. Maity M, Allay MB, Ali MH, Deshmukh R, Basu S, Singh S. Association of tear osmolarity and corneal nerves structure



- in dry eye disease: an in vivo study. *Graefes Arch Clin Exp Ophthalmol*. 2025;263(3):753–760.
569. Kawashima M, Sano K, Takechi S, Tsubota K. Impact of lifestyle intervention on dry eye disease in office workers: a randomized controlled trial. *J Occup Health*. 2018;60:281–288.
  570. Giannaccare G, Pellegrini M, Sebastiani S, et al. Efficacy of omega-3 fatty acid supplementation for treatment of dry eye disease: a meta-analysis of randomized clinical trials. *Cornea*. 2019;38:565–573.
  571. Molina-Leyva I, Molina-Leyva A, Bueno-Cavanillas A. Efficacy of nutritional supplementation with omega-3 and omega-6 fatty acids in dry eye syndrome: a systematic review of randomized clinical trials. *Acta Ophthalmol*. 2017;95.
  572. So WZ, Qi Wong NS, Tan HC, et al. Diabetic corneal neuropathy as a surrogate marker for diabetic peripheral neuropathy. *Neural Regen Res*. 2022;17:2172–2178.
  573. Lagali NS, Allgeier S, Guimaraes P, et al. Reduced corneal nerve fiber density in type 2 diabetes by wide-area mosaic analysis. *Invest Ophthalmol Vis Sci*. 2017;58:6318–6327.
  574. Cozzini T, Piona C, Marchini G, et al. In vivo confocal microscopy study of corneal nerve alterations in children and youths with type 1 diabetes. *Pediatr Diabetes*. 2021;22:780–786.
  575. Wu L-Q, Mou P, Chen Z-Y, et al. Altered corneal nerves in chinese thyroid-associated ophthalmopathy patients observed by in vivo confocal microscopy. *Med Sci Monitor*. 2019;25:1024–1031.
  576. Fenner BJ, Tong L. Corneal staining characteristics in limited zones compared with whole cornea documentation for the detection of dry eye subtypes. *Invest Ophthalmol Vis Sci*. 2013;54:8013–8019.
  577. Efron N, Brennan NA, Morgan PB, Wilson T. Lid wiper epitheliopathy. *Prog Retinal Eye Res*. 2016;53:140–174.
  578. Begley C, Caffery B, Chalmers R, Situ P, Simpson T, Nelson JD. Review and analysis of grading scales for ocular surface staining. *Ocul Surf*. 2019;17:208–220.
  579. van Bijsterveld OP. Diagnostic tests in the Sicca syndrome. *Arch Ophthalmol*. 1969;82:10–14.
  580. Barr JT, Schechtman KB, Fink BA, et al. Corneal scarring in the Collaborative Longitudinal Evaluation of Keratoconus (CLEK) Study: baseline prevalence and repeatability of detection. *Cornea*. 1999;18:34–46.
  581. Bron AJ, Evans VE, Smith JA. Grading of corneal and conjunctival staining in the context of other dry eye tests. *Cornea*. 2003;22:640–650.
  582. Sall K, Foulks GN, Pucker AD, Ice KL, Zink RC, Magrath G. Validation of a Modified National Eye Institute Grading Scale for Corneal Fluorescein Staining. *Clin Ophthalmol*. 2023;17:757–767.
  583. Miyata K, Amano S, Sawa M, Nishida T. A novel grading method for superficial punctate keratopathy magnitude and its correlation with corneal epithelial permeability. *Arch Ophthalmol*. 2003;121:1537–1539.
  584. Whitcher JP, Shiboski CH, Shiboski SC, et al. A simplified quantitative method for assessing keratoconjunctivitis sicca from the Sjogren's Syndrome International Registry. *Am J Ophthalmol*. 2010;149:405–415.
  585. Yeniad B, Beginoglu M, Bilgin LK. Lid-wiper epitheliopathy in contact lens users and patients with dry eye. *Eye Contact Lens*. 2010;36:140–143.
  586. Wang MTM, Craig JP. Natural history of dry eye disease: perspectives from inter-ethnic comparison studies. *Ocul Surf*. 2019;17:424–433.
  587. Nichols KK, Mitchell GL, Zadnik K. The repeatability of clinical measurements of dry eye. *Cornea*. 2004;23:272–285.
  588. Rose-Nussbaumer J, Lietman TM, Shiboski CH, et al. Inter-grader agreement of the ocular staining score in the Sjogren's International Clinical Collaborative Alliance (SICCA) Registry. *Am J Ophthalmol*. 2015;160:1150–1153.
  589. Matossian C, Crowley M, Periman L, Sorkin S. Personalized management of dry eye disease: beyond artificial tears. *Clin Ophthalmol*. 2022;16:3911–3918.
  590. Barabino S, Benitez-Del-Castillo JM. Dry eye disease pathogenesis and clinical signs: searching for correspondence in the clinical practice. *Eur Rev Med Pharmacol Sci*. 2024;28:1881–1890.
  591. Baudouin C. The pathology of dry eye. *Surv Ophthalmol*. 2001;45(suppl 2):S211–S220.
  592. Kojima T, Dogru M, Kawashima M, Nakamura S, Tsubota K. Advances in the diagnosis and treatment of dry eye. *Prog Retinal Eye Res*. 2020:100842.
  593. Kemeny-Beke A, Szodoray P. Ocular manifestations of rheumatic diseases. *Int Ophthalmol*. 2020;40:503–510.
  594. Wang YH, Li W, McDermott M, et al. IFN- $\gamma$ -producing T(H)1 cells and dysfunctional regulatory T cells contribute to the pathogenesis of Sjögren's disease. *Sci Transl Med*. 2024;16:eado4856.
  595. Hassan AS, Clouthier SG, Ferrara JL, et al. Lacrimal gland involvement in graft-versus-host disease: a murine model. *Invest Ophthalmol Vis Sci*. 2005;46:2692–2697.
  596. Chen X, Aqrabi LA, Utheim TP, et al. Elevated cytokine levels in tears and saliva of patients with primary Sjogren's syndrome correlate with clinical ocular and oral manifestations. *Sci Rep*. 2019;9:7319.
  597. Park JY, Kim BG, Kim JS, Hwang JH. Matrix metalloproteinase 9 point-of-care immunoassay result predicts response to topical cyclosporine treatment in dry eye disease. *Transl Vis Sci Technol*. 2018;7:31.
  598. Daull P, Baudouin C, Liang H, Feraille L, Barabino S, Garrigue JS. Review of preclinical outcomes of a topical cationic emulsion of cyclosporine A for the treatment of ocular surface diseases. *Ocul Immunol Inflamm*. 2022;30:1945–1955.
  599. Aragona P, Aguenouz M, Rania L, et al. Matrix metalloproteinase 9 and transglutaminase 2 expression at the ocular surface in patients with different forms of dry eye disease. *Ophthalmology*. 2015;122:62–71.
  600. Tauber J. A 6-week, prospective, randomized, single-masked study of lifitegrast ophthalmic solution 5% versus thermal pulsation procedure for treatment of inflammatory meibomian gland dysfunction. *Cornea*. 2020;39:403–407.
  601. Valdes-Arias D, Locatelli EVT, Sepulveda-Beltran PA, Mangwani-Mordani S, Navia JC, Galor A. Recent United States developments in the pharmacological treatment of dry eye disease. *Drugs*. 2024;84(5):549–563.
  602. Zhuang D, Misra SL, Mugisho OO, Rupenthal ID, Craig JP. NLRP3 inflammasome as a potential therapeutic target in dry eye disease. *Int J Mol Sci*. 2023;24.
  603. Messmer EM, von Lindenfels V, Garbe A, Kampik A. Matrix metalloproteinase 9 testing in dry eye disease using a commercially available point-of-care immunoassay. *Ophthalmology*. 2016;123:2300–2308.

604. Shon C, Muntz A, Xue A, Zhuang D, Craig JP. *Optimising diagnosis of clinically significant inflammation in dry eye disease*. American Academy of Optometry; 2022.
605. Peterson RC, Wolffsohn JS. Sensitivity and reliability of objective image analysis compared to subjective grading of bulbar hyperaemia. *Br J Ophthalmol*. 2007;91:1464–1466.
606. Amparo F, Wang H, Emami-Naeini P, Karimian P, Dana R. The Ocular Redness Index: a novel automated method for measuring ocular injection. *Invest Ophthalmol Vis Sci*. 2013;54:4821–4826.
607. Rodriguez JD, Hamm A, Bensinger E, et al. Statistical evaluation of smartphone-based automated grading system for ocular redness associated with dry eye disease and implications for clinical trials. *Clin Ophthalmol*. 2025;19:907–914.
608. Altman J, Jones G, Ahmed S, Sharma S, Sharma A. Tear film microRNAs as potential biomarkers: a review. *Int J Mol Sci*. 2023;24.
609. Winiarczyk M, Biela K, Michalak K, Winiarczyk D, Mackiewicz J. Changes in tear proteomic profile in ocular diseases. *Int J Environ Res Public Health*. 2022;19.
610. Tong L, Petznick A. Correlation between tear matrix metalloproteinases and the Schirmer's test. *Invest Ophthalmol Vis Sci*. 2012;53:1592.
611. Papas EB. Key factors in the subjective and objective assessment of conjunctival erythema. *Invest Ophthalmol Vis Sci*. 2000;41:687–691.
612. Fieguth P, Simpson T. Automated measurement of bulbar redness. *Invest Ophthalmol Vis Sci*. 2002;43:340–347.
613. Bron AJ, Mengher LS, Davey CC. The normal conjunctiva and its responses to inflammation. *Trans Ophthalmol Soc U K* (1962). 1985;104(Pt 4):424–435.
614. Roy FH. The red eye. *Ann Ophthalmol (Skokie)*. 2006;38:35–38.
615. Mandell RB. Slit lamp classification system. *J Am Optom Assoc*. 1987;58:198–201.
616. McMonnies CW, Chapman-Davies A. Assessment of conjunctival hyperemia in contact lens wearers. Part I. *Am J Optom Physiol Opt*. 1987;64:246–250.
617. Efron N, Morgan PB, Katsara SS. Validation of grading scales for contact lens complications. *Ophthalmic Physiol Opt*. 2001;21:17–29.
618. Schulze MM, Jones DA, Simpson TL. The development of validated bulbar redness grading scales. *Optom Vis Sci*. 2007;84:976–983.
619. Schulze MM, Hutchings N, Simpson TL. Grading bulbar redness using cross-calibrated clinical grading scales. *Invest Ophthalmol Vis Sci*. 2011;52:5812–5817.
620. Villumsen J, Ringquist J, Alm A. Image analysis of conjunctival hyperemia. A personal computer based system. *Acta Ophthalmol (Copenh)*. 1991;69:536–539.
621. Willingham FF, Cohen KL, Coggins JM, Tripoli NK, Ogle JW, Goldstein GM. Automatic quantitative measurement of ocular hyperemia. *Curr Eye Res*. 1995;14:1101–1108.
622. Wolffsohn JS, Purslow C. Clinical monitoring of ocular physiology using digital image analysis. *Cont Lens Anterior Eye*. 2003;26:27–35.
623. Yoneda T, Sumi T, Takahashi A, Hoshikawa Y, Kobayashi M, Fukushima A. Automated hyperemia analysis software: reliability and reproducibility in healthy subjects. *Jpn J Ophthalmol*. 2012;56:1–7.
624. Rodriguez JD, Johnston PR, Ousler 3rd GW, Smith LM, Abelson MB. Automated grading system for evaluation of ocular redness associated with dry eye. *Clin Ophthalmol*. 2013;7:1197–1204.
625. Wu S, Hong J, Tian L, Cui X, Sun X, Xu J. Assessment of bulbar redness with a newly developed keratograph. *Optom Vis Sci*. 2015;92:892–899.
626. Huntjens B, Basi M, Nagra M. Evaluating a new objective grading software for conjunctival hyperaemia. *Cont Lens Anterior Eye*. 2020;43:137–143.
627. Peterson RC, Wolffsohn JS. Objective grading of the anterior eye. *Optom Vis Sci*. 2009;86:273–278.
628. Shetty R, Dua HS, Tong L, et al. Role of in vivo confocal microscopy in dry eye disease and eye pain. *Indian J Ophthalmol*. 2023;71:1099–1104.
629. Yu M, Liu C, Mehta JS, Liu YC. A review of the application of in-vivo confocal microscopy on conjunctival diseases. *Eye Vis (London, England)*. 2024;11:43.
630. Kasikci M, Erogul O, Polat O. Evaluation of aqueous-deficient and evaporative dry eye cases with confocal microscopy. *J Fr Ophthalmol*. 2023;46:1161–1168.
631. Azizi S, Uçak T, Yaşar I, Karakurt Y, Erdogan E, Salman I. Evaluation of the corneal layers in meibomian-gland-dysfunction-related dry eye by in vivo slit-scanning confocal microscopy. *Semin Ophthalmol*. 2017;32:377–383.
632. Yang T, Ma B, Xie J, et al. Evaluation of ocular surface characteristics in dry eye disease with and without soft contact lens wear: a comparative study. *Eye Contact Lens*. 2022;48:377–383.
633. He J, Ogawa Y, Mukai S, et al. In vivo confocal microscopy evaluation of ocular surface with graft-versus-host disease-related dry eye disease. *Sci Rep*. 2017;7:10720.
634. Setu MAK, Schmidt S, Musial G, Stern ME, Steven P. Segmentation and evaluation of corneal nerves and dendritic cells from in vivo confocal microscopy images using deep learning. *Transl Vis Sci Technol*. 2022;11:24.
635. Hwang J, Dermer H, Galor A. Can in vivo confocal microscopy differentiate between sub-types of dry eye disease? A review. *Clin Exp Ophthalmol*. 2021;49:373–387.
636. Villani E, Garoli E, Termine V, Pichi F, Ratiglia R, Nucci P. Corneal confocal microscopy in dry eye treated with corticosteroids. *Optom Vis Sci*. 2015;92:e290–e295.
637. Kheirkhah A, Dohlman TH, Amparo F, et al. Effects of corneal nerve density on the response to treatment in dry eye disease. *Ophthalmology*. 2015;122:662–668.
638. Iaccheri B, Torroni G, Cagini C, et al. Corneal confocal scanning laser microscopy in patients with dry eye disease treated with topical cyclosporine. *Eye (Lond)*. 2017;31:788–794.
639. Manicone AM, McGuire JK. Matrix metalloproteinases as modulators of inflammation. *Semin Cell Dev Biol*. 2008;19:34–41.
640. Caban M, Owczarek K, Lewandowska U. The role of metalloproteinases and their tissue inhibitors on ocular diseases: focusing on potential mechanisms. *Int J Mol Sci*. 2022;23.
641. Kapoor C, Vaidya S, Wadhwan V, Hitesh Kaur G, Pathak A. Seesaw of matrix metalloproteinases (MMPs). *J Cancer Res Ther*. 2016;12:28–35.
642. Acera A, Rocha G, Vecino E, Lema I, Duran JA. Inflammatory markers in the tears of patients with ocular surface disease. *Ophthalmic Res*. 2008;40:315–321.

643. Chotikavanich S, de Paiva CS, de Quan L, et al. Production and activity of matrix metalloproteinase-9 on the ocular surface increase in dysfunctional tear syndrome. *Invest Ophthalmol Vis Sci*. 2009;50:3203–3209.
644. Knight BE, Kozlowski N, Havelin J, et al. TIMP-1 attenuates the development of inflammatory pain through MMP-dependent and receptor-mediated cell signaling mechanisms. *Front Mol Neurosci*. 2019;12:220.
645. Bang SP, Son MJ, Kim H, Lee YH, Jun JH. In vitro validation of the tear matrix metalloproteinase 9 in-situ immunoassay. *Sci Rep*. 2020;10:15126.
646. Periman LM, Perez VL, Saban DR, Lin MC, Neri P. The immunological basis of dry eye disease and current topical treatment options. *J Ocul Pharmacol Ther*. 2020;36:137–146.
647. Pflugfelder SC, De Paiva CS, Moore QL, et al. Aqueous tear deficiency increases conjunctival interferon- $\gamma$  (IFN- $\gamma$ ) expression and goblet cell loss. *Invest Ophthalmol Vis Sci*. 2015;56:7545–7550.
648. Zhao L, Yu JJ, Liu Y, et al. An enhanced model for environmental dry eye: exploring pathological features and underlying factors. *Exp Eye Res*. 2024;239:109744.
649. Kumar NR, Praveen M, Narasimhan R, et al. Tear biomarkers in dry eye disease: progress in the last decade. *Indian J Ophthalmol*. 2023;71:1190–1202.
650. Jackson DC, Zeng W, Wong CY, et al. Tear interferon-gamma as a biomarker for evaporative dry eye disease. *Invest Ophthalmol Vis Sci*. 2016;57:4824–4830.
651. Chen Y, Dana R. Autoimmunity in dry eye disease—an updated review of evidence on effector and memory Th17 cells in disease pathogenicity. *Autoimmun Rev*. 2021;20:102933.
652. Kuklinski EJ, Yu Y, Ying GS, Asbell PA. Association of ocular surface immune cells with dry eye signs and symptoms in the Dry Eye Assessment and Management (DREAM) Study. *Invest Ophthalmol Vis Sci*. 2023;64:7.
653. Roy NS, Yu Y, Ying GS, Maguire MG, Asbell PA. Effect of omega-3 on HLA-DR expression by conjunctival cells and tear cytokine concentrations in the Dry Eye Assessment and Management Study. *Eye Contact Lens*. 2022;48:384–390.
654. Willems B, Tong L, Minh TDT, Pham ND, Nguyen XH, Zumbansen M. Novel cytokine multiplex assay for tear fluid analysis in Sjogren's syndrome. *Ocul Immunol Inflamm*. 2021;29:1639–1644.
655. Roda M, Corazza I, Bacchi Reggiani ML, et al. Dry eye disease and tear cytokine levels—a meta-analysis. *Int J Mol Sci*. 2020;21.
656. Perez VL, Stern ME, Pflugfelder SC. Inflammatory basis for dry eye disease flares. *Exp Eye Res*. 2020;201:108294.
657. VanDerMeid KR, Su SP, Ward KW, Zhang JZ. Correlation of tear inflammatory cytokines and matrix metalloproteinases with four dry eye diagnostic tests. *Invest Ophthalmol Vis Sci*. 2012;53:1512–1528.
658. Enriquez-de-Salamanca A, Castellanos E, Stern ME, et al. Tear cytokine and chemokine analysis and clinical correlations in evaporative-type dry eye disease. *Mol Vis*. 2010;16:862–873.
659. Lee JH, Min K, Kim SK, Kim EK, Kim TI. Inflammatory cytokine and osmolarity changes in the tears of dry eye patients treated with topical 1% methylprednisolone. *Yonsei Med J*. 2014;55:203–208.
660. González-García MJ, Murillo GM, Pinto-Fraga J, et al. Clinical and tear cytokine profiles after advanced surface ablation refractive surgery: a six-month follow-up. *Exp Eye Res*. 2020;193:107976.
661. López-Miguel A, Tesón M, Martín-Montañez V, et al. Clinical and molecular inflammatory response in Sjögren syndrome-associated dry eye patients under desiccating stress. *Am J Ophthalmol*. 2016;161:133–141.
662. Gad A, Vingrys AJ, Wong CY, Jackson DC, Downie LE. Tear film inflammatory cytokine upregulation in contact lens discomfort. *Ocul Surf*. 2019;17:89–97.
663. Chhadva P, Lee T, Sarantopoulos CD, et al. Human tear serotonin levels correlate with symptoms and signs of dry eye. *Ophthalmology*. 2015;122:1675–1680.
664. Zhang X, Yin Y, Yue L, Gong L. Selective serotonin reuptake inhibitors aggravate depression-associated dry eye via activating the NF- $\kappa$ B pathway. *Invest Ophthalmol Vis Sci*. 2019;60:407–419.
665. Dartt DA. Regulation of lacrimal gland secretion by neurotransmitters and the EGF family of growth factors. *Exp Eye Res*. 2001;73:741–752.
666. Lambiase A, Micera A, Sacchetti M, Cortes M, Mantelli F, Bonini S. Alterations of tear neuromediators in dry eye disease. *Arch Ophthalmol*. 2011;129:981–986.
667. Yang LWY, Mehta JS, Liu YC. Corneal neuromediator profiles following laser refractive surgery. *Neural Regen Res*. 2021;16:2177–2183.
668. Liu C, Lin MT, Lee IXY, et al. Neuropathic corneal pain: tear proteomic and neuromediator profiles, imaging features, and clinical manifestations. *Am J Ophthalmol*. 2024;265:6–20.
669. Hernández-Molina G, Avila-Casado C, Nuñez-Alvarez C, et al. Utility of the American-European Consensus Group and American College of Rheumatology Classification Criteria for Sjögren's syndrome in patients with systemic autoimmune diseases in the clinical setting. *Rheumatology (Oxford, England)*. 2015;54:441–448.
670. Loiseau P, Lepage V, Djelal F, et al. HLA class I and class II are both associated with the genetic predisposition to primary Sjögren syndrome. *Hum Immunol*. 2001;62:725–731.
671. Kessal K, Liang H, Rabut G, et al. Conjunctival inflammatory gene expression profiling in dry eye disease: correlations with HLA-DRA and HLA-DRB1. *Front Immunol*. 2018;9:2271.
672. Roy NS, Wei Y, Yu Y, et al. Conjunctival HLA-DR expression and its association with symptoms and signs in the DREAM Study. *Transl Vis Sci Technol*. 2019;8:31.
673. Baudouin C, Liang H, Riancho L, et al. Correlation between the inflammatory marker HLA DR and signs and symptoms in moderate to severe dry eye disease. *Invest Ophthalmol Vis Sci*. 2015;56:CO183–CC298.
674. Nair AP, D'Souza S, Khamar P, Nuijts R, Sethu S, Shetty R. Ocular surface immune cell diversity in dry eye disease. *Indian J Ophthalmol*. 2023;71:1237–1247.
675. de Zoete MR, Palm NW, Zhu S, Flavell RA. Inflammasomes. *Cold Spring Harb Perspect Biol*. 2014;6:a016287.
676. Yerramothu P, Vijay AK, Willcox MDP. Inflammasomes, the eye and anti-inflammasome therapy. *Eye (Lond)*. 2018;32:491–505.
677. Zheng Q, Ren Y, Reinach PS, et al. Reactive oxygen species activated NLRP3 inflammasomes initiate inflammation in hyperosmolarity stressed human corneal epithelial cells and environment-induced dry eye patients. *Exp Eye Res*. 2015;134:133–140.



678. Niu L, Zhang S, Wu J, Chen L, Wang Y. Upregulation of NLRP3 Inflammasome in the tears and ocular surface of dry eye patients. *PLoS One*. 2015;10:e0126277.
679. Zheng Q, Ren Y, Reinach PS, et al. Reactive oxygen species activated NLRP3 inflammasomes prime environment-induced murine dry eye. *Exp Eye Res*. 2014;125:1–8.
680. Tovar A, Gomez A, Serrano A, et al. Role of caspase-1 as a biomarker of ocular surface damage. *Am J Ophthalmol*. 2022;239:74–83.
681. Zhang J, Dai Y, Yang Y, Xu J. Calcitriol alleviates hyperosmotic stress-induced corneal epithelial cell damage via inhibiting the NLRP3-ASC-caspase-1-GSDMD pyroptosis pathway in dry eye disease. *J Inflamm Res*. 2021;14:2955–2962.
682. Hammond SM. An overview of microRNAs. *Adv Drug Deliv Rev*. 2015;87:3–14.
683. Kim YJ, Yeon Y, Lee WJ, et al. Comparison of microRNA expression in tears of normal subjects and Sjogren syndrome patients. *Invest Ophthalmol Vis Sci*. 2019;60:4889–4895.
684. Wang Q, Xie X, Li H, Hao S. Discovery of microRNA expression profiles involved in regulating TGF-beta2 expression in the tears of dry eye patients. *Ann Clin Biochem*. 2020;57:420–428.
685. Pucker AD, Ngo W, Postnikoff CK, Fortinberry H, Nichols JJ. Tear film miRNAs and their association with human dry eye disease. *Curr Eye Res*. 2022;47:1479–1487.
686. Ren Y, Feng J, Lin Y, et al. MiR-223 inhibits hyperosmolarity-induced inflammation through downregulating NLRP3 activation in human corneal epithelial cells and dry eye patients. *Exp Eye Res*. 2022;220:109096.
687. Chan HW, Yang B, Wong W, et al. A pilot study on microRNA profile in tear fluid to predict response to anti-VEGF treatments for diabetic macular edema. *J Clin Med*. 2020;9.
688. Bu J, Liu Y, Zhang R, et al. Potential new target for dry eye disease-oxidative stress. *Antioxidants (Basel)*. 2024;13.
689. Li B, Sheng M, Li J, et al. Tear proteomic analysis of Sjogren syndrome patients with dry eye syndrome by two-dimensional-nano-liquid chromatography coupled with tandem mass spectrometry. *Sci Rep*. 2014;4:5772.
690. Kruk J, Kubasik-Kladna K, Aboul-Enein HY. The role of oxidative stress in the pathogenesis of eye diseases: current status and a dual role of physical activity. *Mini Rev Med Chem*. 2015;16:241–257.
691. Gaschler MM, Stockwell BR. Lipid peroxidation in cell death. *Biochem Biophys Res Commun*. 2017;482:419–425.
692. Wakamatsu TH, Dogru M, Matsumoto Y, et al. Evaluation of lipid oxidative stress status in Sjogren syndrome patients. *Invest Ophthalmol Vis Sci*. 2013;54:201–210.
693. Navel V, Sapin V, Henrioux F, et al. Oxidative and antioxidant stress markers in dry eye disease: a systematic review and meta-analysis. *Acta Ophthalmol*. 2022;100:45–57.
694. Sedlak L, Swierczynska M, Borymska W, Zych M, Wygladowska-Promienska D. Impact of dorzolamide, benzalkonium-preserved dorzolamide and benzalkonium-preserved brinzolamide on selected biomarkers of oxidative stress in the tear film. *BMC Ophthalmol*. 2021;21:319.
695. Choi JH, Li Y, Kim SH, et al. The influences of smartphone use on the status of the tear film and ocular surface. *PLoS One*. 2018;13:e0206541.
696. Macri A, Scanarotti C, Bassi AM, et al. Evaluation of oxidative stress levels in the conjunctival epithelium of patients with or without dry eye, and dry eye patients treated with preservative-free hyaluronic acid 0.15 % and vitamin B12 eye drops. *Graefes Arch Clin Exp Ophthalmol*. 2015;253:425–430.
697. Choi W, Lian C, Ying L, et al. Expression of lipid peroxidation markers in the tear film and ocular surface of patients with non-Sjogren syndrome: potential biomarkers for dry eye disease. *Curr Eye Res*. 2016;41:1143–1149.
698. Jung JH, Ji YW, Hwang HS, et al. Proteomic analysis of human lacrimal and tear fluid in dry eye disease. *Sci Rep*. 2017;7:13363.
699. Xiao W, Huang P. Effects of the preoperative use of artificial tears combined with recombinant bovine basic fibroblast growth factor on cataract patients complicated with dry eyes. *Arg Bras Ophthalmol*. 2022;87:0539.
700. Jee D, Park M, Lee HJ, Kim MS, Kim EC. Comparison of treatment with preservative-free versus preserved sodium hyaluronate 0.1% and fluorometholone 0.1% eyedrops after cataract surgery in patients with preexisting dry-eye syndrome. *J Cataract Refract Surg*. 2015;41:756–763.
701. Chen A, Chen HT, Hwang YH, Chen YT, Hsiao CH, Chen HC. Severity of dry eye syndrome is related to anti-ds-DNA autoantibody in systemic lupus erythematosus patients without secondary Sjogren syndrome: a cross-sectional analysis. *Medicine (Baltimore)*. 2016;95:e4218.
702. Ma W, Wang G, Li X, et al. Study of factors influencing dry eye in rheumatoid arthritis. *J Ophthalmol*. 2020;2020:5768679.
703. Psianou K, Panagoulas I, Papanastasiou AD, et al. Clinical and immunological parameters of Sjogren's syndrome. *Autoimmun Rev*. 2018;17:1053–1064.
704. D'Souza S, James E, Jois R, Mahendradas P, Koul A, Pradhan A. Systemic investigations in dry eye disease. *Indian J Ophthalmol*. 2023;71:1326–1331.
705. Osei-Bimpong A, Meek JH, Lewis SM. ESR or CRP? A comparison of their clinical utility. *Hematology*. 2007;12:353–357.
706. Crane AM, Feuer W, Galor A. C-reactive protein levels and tear function parameters. *Ophthalmology*. 2013;120:1099.
707. Hashemi MH, Ambrus Jr JL, Shukla AA, et al. Association of systemic markers of inflammation with signs and symptoms of dry eye disease and Sjogren's syndrome in the Dry Eye Assessment and Management (DREAM(c)) Study. *Curr Eye Res*. 2024;49:574–581.
708. Da Cunha E, Mariette X, Desmoulins F, et al. Associations between ocular and extra-ocular assessment in primary Sjogren's syndrome. *Joint Bone Spine*. 2022;89:105426.
709. Lim SA, Nam S, Kwok SK, Park SH, Chung SH. Serologic markers are associated with ocular staining score in primary Sjogren syndrome. *Cornea*. 2015;34:1466–1470.
710. Tsubota K, Fujihara T, Takeuchi T. Soluble interleukin-2 receptors and serum autoantibodies in dry eye patients: correlation with lacrimal gland function. *Cornea*. 1997;16:339–344.
711. Ruiz de Morales JMG, Puig L, Dauden E, et al. Critical role of interleukin (IL)-17 in inflammatory and immune disorders: an updated review of the evidence focusing in controversies. *Autoimmun Rev*. 2020;19:102429.
712. Oh JY, Kim MK, Choi HJ, et al. Investigating the relationship between serum interleukin-17 levels and systemic im-



- immune-mediated disease in patients with dry eye syndrome. *Korean J Ophthalmol*. 2011;25:73–76.
713. Panpruk R, Puangsricharern V, Klaewsongkram J, et al. Clinical parameters and biological markers associated with acute severe ocular complications in Stevens-Johnson syndrome and toxic epidermal necrolysis. *Sci Rep*. 2021;11:20275.
  714. Vehof J, Hysi PG, Hammond CJ. A metabolome-wide study of dry eye disease reveals serum androgens as biomarkers. *Ophthalmology*. 2017;124:505–511.
  715. Wang MTM, Dean SJ, Muntz A, Craig JP. Evaluating the diagnostic utility of evaporative dry eye disease markers. *Clin Exp Ophthalmol*. 2020;48:267–270.
  716. Ruiz-Lozano RE, Quiroga-Garza ME, Ramos-Dávila EM, et al. Comparative evaluation of the corneal sensitivity thresholds between the novel non-contact and Cochet-Bonnet esthesiometers. *Am J Ophthalmol*. 2025;271:407–416.
  717. Tavakoli M, Ferdousi M, Petropoulos IN, et al. Normative values for corneal nerve morphology assessed using corneal confocal microscopy: a multinational normative data set. *Diabetes Care*. 2015;38:838–843.
  718. Pflugfelder SC, de Paiva CS. The pathophysiology of dry eye disease: what we know and future directions for research. *Ophthalmology*. 2017;124:S4–S13.
  719. Chen Y, Chauhan SK, Lee HS, et al. Effect of desiccating environmental stress versus systemic muscarinic AChR blockade on dry eye immunopathogenesis. *Invest Ophthalmol Vis Sci*. 2013;54:2457–2464.
  720. Usuba FS, Saad CGS, Aikawa NE, et al. Improvement of conjunctival cytological grade and tear production in ankylosing spondylitis patients under TNF inhibitors: a long-term follow-up. *Sci Rep*. 2020;10:334.
  721. Khokhar M, Dey S, Tomo S, Jaremko M, Emwas AH, Pandey RK. Unveiling novel drug targets and emerging therapies for rheumatoid arthritis: a comprehensive review. *ACS Pharmacol Transl Sci*. 2024;7:1664–1693.
  722. Kelagere Y, Scholand KK, DeJong EN, et al. TNF is a critical cytokine in age-related dry eye disease. *Ocul Surf*. 2023;30:119–128.
  723. Mavragani CP, Moutsopoulos HM. Sjögren's syndrome: old and new therapeutic targets. *J Autoimmun*. 2020;110:102364.
  724. Shen L, Suresh L, Lindemann M, et al. Novel autoantibodies in Sjögren's syndrome. *Clin Immunol (Orlando, Fla)*. 2012;145:251–255.
  725. de Paiva CS, Trujillo-Vargas CM, Schaefer L, Yu Z, Britton RA, Pflugfelder SC. Differentially expressed gene pathways in the conjunctiva of Sjögren syndrome keratoconjunctivitis Sicca. *Front Immunol*. 2021;12:702755.
  726. Pflugfelder SC, Bian F, Gumus K, Farley W, Stern ME, De Paiva CS. Severity of Sjögren's syndrome keratoconjunctivitis Sicca increases with increased percentage of conjunctival antigen-presenting cells. *Int J Mol Sci*. 2018;19.
  727. Schaumberg DA, Buring JE, Sullivan DA, Dana MR. Hormone replacement therapy and dry eye syndrome. *JAMA*. 2001;286:2114–2119.
  728. Britten-Jones AC, Craig JP, Anderson AJ, Downie LE. Association between systemic omega-3 polyunsaturated fatty acid levels, and corneal nerve structure and function. *Eye (Basinstoke)*. 2023;37.
  729. Sağdıç HM, Ugurbas SH, Can M, et al. Tear film osmolarity in patients with diabetes mellitus. *Ophthalmic Res*. 2013;50:1–5.
  730. Darenskaya MA, Kolesnikova LI, Kolesnikov SI. Oxidative stress: pathogenetic role in diabetes mellitus and its complications and therapeutic approaches to correction. *Bull Exp Biol Med*. 2021;171:179–189.
  731. Suwajanakorn O, Puangsricharern V, Kittipibul T, Chatsuwat T. Ocular surface microbiome in diabetes mellitus. *Sci Rep*. 2022;12:21527.
  732. Ma A, Mak MS, Shih KC, et al. Association of long-term glycaemic control on tear break-up times and dry eye symptoms in Chinese patients with type 2 diabetes. *Clin Exp Ophthalmol*. 2018;46:608–615.
  733. Pereira MV, Glória AL. Lagophthalmos. *Semin Ophthalmol*. 2010;25:72–78.
  734. Craig JP, Muntz A, Wang MTM, et al. Developing evidence-based guidance for the treatment of dry eye disease with artificial tear supplements: a six-month multicentre, double-masked randomised controlled trial. *Ocul Surf*. 2021;20:62–69.
  735. Donthineni PR, Kammari P, Shanbhag SS, Singh V, Das AV, Basu S. Incidence, demographics, types and risk factors of dry eye disease in India: electronic medical records driven big data analytics report I. *Ocul Surf*. 2019;17:250–256.
  736. Watson SL, Chidi-Egboka NC, Khoo P, et al. Efficient capture of dry eye data from the real world: the Save Sight Dry Eye Registry. *AJO Int*. 2024;1:100065.
  737. Zhang S, Echegoyen J. Design and usability study of a point of care mHealth app for early dry eye screening and detection. *J Clin Med*. 2023;12.
  738. Shi Y, Wang L, Hu Y, et al. Contact lens sensor for ocular inflammation monitoring. *Biosensors Bioelectronics*. 2024;249:116003.
  739. Woods CA DK, Jones L, Fonn D. Patient use of smartphones to communicate subjective data in clinical trials. *Optom Vis Sci*. 2011;88:290–294.
  740. Yang HK, Che SA, Hyon JY, Han SB. Integration of artificial intelligence into the approach for diagnosis and monitoring of dry eye disease. *Diagnostics (Basel)*. 2022;12.
  741. Group Neurotrophic Keratopathy Study. Neurotrophic keratopathy: an updated understanding. *Ocul Surf*. 2023;30:129–138.
  742. Tamimi A, Sheikhzadeh F, Ezabadi SG, et al. Post-LASIK dry eye disease: a comprehensive review of management and current treatment options. *Front Med (Lausanne)*. 2023;10:1057685.
  743. Gupta PK, Drinkwater OJ, VanDusen KW, Brissette AR, Starr CE. Prevalence of ocular surface dysfunction in patients presenting for cataract surgery evaluation. *J Cataract Refract Surg*. 2018;44:1090–1096.
  744. Trattler WB, Majmudar PA, Donnenfeld ED, McDonald MB, Stonecipher KG, Goldberg DF. The Prospective Health Assessment of Cataract Patients' Ocular Surface (PHACO) study: the effect of dry eye. *Clin Ophthalmol*. 2017;11:1423–1430.
  745. Nosch DS, Käser E, Bracher T, Joos RE. Age-related changes in corneal sensitivity. *Cornea*. 2023;42:1257–1262.
  746. Zhao PF, Zhou YH, Hu YB, et al. Evaluation of pre-operative dry eye in people undergoing corneal refractive surgery to correct myopia. *Int J Ophthalmol*. 2021;14:1047–1051.

747. Woodward MA, Randleman JB, Stulting RD. Dissatisfaction after multifocal intraocular lens implantation. *J Cataract Refract Surg*. 2009;35:992–997.
748. Yang F, Yang L, Ning X, Liu J, Wang J. Effect of dry eye on the reliability of keratometry for cataract surgery planning. *J Fr Ophthalmol*. 2024;47:103999.
749. Nilsen C, Gundersen M, Jensen PG, et al. Effect of artificial tears on preoperative keratometry and refractive precision in cataract surgery. *Clin Ophthalmol*. 2024;18:1503–1514.
750. Chuang J, Shih KC, Chan TC, Wan KH, Jhanji V, Tong L. Preoperative optimization of ocular surface disease before cataract surgery. *J Cataract Refract Surg*. 2017;43:1596–1607.
751. Nibandhe AS, Donthineni PR. Understanding and optimizing ocular biometry for cataract surgery in dry eye disease: a review. *Semin Ophthalmol*. 2023;38:24–30.
752. Starr CE, Gupta PK, Farid M, et al. An algorithm for the preoperative diagnosis and treatment of ocular surface disorders. *J Cataract Refract Surg*. 2019;45:669–684.
753. Castillo-Macías A, Arreola-Martínez JE, Loya-García D, Valdez-García JE. Prevalence and clinical characteristics of neurotrophic keratopathy in hispanic population in north-eastern Mexico. *Int Ophthalmol*. 2023;43:3257–3262.
754. Sambhi RS, Sambhi GDS, Mather R, MS Malvankar-Mehta. Dry eye after refractive surgery: a meta-analysis. *Can J Ophthalmol*. 2020;55:99–106.
755. Shen Z, Zhu Y, Song X, Yan J, Yao K. Dry eye after small incision lenticule extraction (SMILE) versus Femtosecond laser-assisted in situ keratomileusis (FS-LASIK) for myopia: a meta-analysis. *PLoS One*. 2016;11:e0168081.
756. Kobashi H, Kamiya K, Shimizu K. Dry eye after small incision lenticule extraction and Femtosecond laser-assisted LASIK: meta-analysis. *Cornea*. 2017;36:85–91.
757. Nair S, Kaur M, Sharma N, Titiyal JS. Refractive surgery and dry eye—an update. *Indian J Ophthalmol*. 2023;71:1105–1114.
758. Miura M, Inomata T, Nakamura M, et al. Prevalence and characteristics of dry eye disease after cataract surgery: a systematic review and meta-analysis. *Ophthalmol Ther*. 2022;11:1309–1332.
759. Lu Q, Lu Y, Zhu X. Dry eye and phacoemulsification cataract surgery: a systematic review and meta-analysis. *Front Med (Lausanne)*. 2021;8:649030.
760. Qian L, Wei W. Identified risk factors for dry eye syndrome: a systematic review and meta-analysis. *PLoS One*. 2022;17:e0271267.
761. Naderi K, Gormley J, O'Brart D. Cataract surgery and dry eye disease: a review. *Eur J Ophthalmol*. 2020;30:840–855.
762. Bonini S, Rama P, Olzi D, Lambiase A. Neurotrophic keratitis. *Eye (Lond)*. 2003;17:989–995.
763. Dua HS, Said DG, Messmer EM, et al. Neurotrophic keratopathy. *Prog Retinal Eye Res*. 2018;66:107–131.
764. Mackie IA. *Current ocular therapy*. Neuroparalytic keratitis editors; 1995 Saunders.
765. Zieske JD, Gipson IK. Protein synthesis during corneal epithelial wound healing. *Invest Ophthalmol Vis Sci*. 1986;27:1–7.
766. Cardona G, Seres C, Quevedo L, Auge M. Knowledge and use of tear film evaluation tests by spanish practitioners. *Optom Vis Sci*. 2011;88:1106–1111.
767. Belmonte C, Acosta MC, Schmelz M, Gallar J. Measurement of corneal sensitivity to mechanical and chemical stimulation with a CO<sub>2</sub> esthesiometer. *Invest Ophthalmol Vis Sci*. 1999;40:513–519.
768. Merayo-Llodes J, Gómez Martín C, Lozano-Sanroma J, Renedo Laguna C. Assessment and safety of the new esthesiometer BRILL: comparison with the Cochet-Bonnet esthesiometer. *Eur J Ophthalmol*. 2024;34:1036–1045.
769. Villalba M, Sabates V, Orgul S, Perez VL, Swaminathan SS, Sabater AL. Detection of subclinical neurotrophic keratopathy by noncontact esthesiometry. *Ophthalmol Ther*. 2024;13:2393–2404.
770. Swanevelder SK, Misra SL, Tyler EF, McGhee CN. Precision, agreement and utility of a contemporary non-contact corneal aesthesiometer. *Clin Exp Optom*. 2020;103:798–803.
771. Dana R, Farid M, Gupta PK, et al. Expert consensus on the identification, diagnosis, and treatment of neurotrophic keratopathy. *BMC Ophthalmol*. 2021;21:327.
772. Giovannetti F, Sacchetti M, Marengo M, et al. New disposable esthesiometer (KeraSense®) to improve diagnosis and management of neurotrophic keratitis. *Ocul Surf*. 2024;32:192–197.
773. Merayo-Llodes J, Gómez Martín C, Lozano-Sanroma J, Renedo Laguna C. Assessment and safety of the new esthesiometer BRILL: comparison with the Cochet-Bonnet esthesiometer. *Eur J Ophthalmol*. 2024;34(4):1036–1045.
774. Crabtree JR, Tannir S, Tran K, Boente CS, Ali A, Borschel GH. Corneal nerve assessment by aesthesiometry: history, advancements, and future directions. *Vision (Basel, Switzerland)*. 2024;8.
775. Rosenberg ME, Tervo TM, Immonen IJ, Müller LJ, Grönhagen-Riska C, Vesaluoma MH. Corneal structure and sensitivity in type 1 diabetes mellitus. *Invest Ophthalmol Vis Sci*. 2000;41:2915–2921.
776. Martone G, Alegente M, Balestrazzi A, et al. In vivo confocal microscopy in bilateral herpetic keratitis: a case report. *Eur J Ophthalmol*. 2008;18:994–997.
777. Patel DV, McGhee CN. Laser scanning in vivo confocal microscopy demonstrating significant alteration of human corneal nerves following herpes zoster ophthalmicus. *Arch Neurol*. 2010;67:640–641.
778. Hamrah P, Sahin A, Dastjerdi MH, et al. Cellular changes of the corneal epithelium and stroma in herpes simplex keratitis: an in vivo confocal microscopy study. *Ophthalmology*. 2012;119:1791–1797.
779. Cruzat A, Qazi Y, Hamrah P. In vivo confocal microscopy of corneal nerves in health and disease. *Ocul Surf*. 2017;15:15–47.
780. Hamrah P, Cruzat A, Dastjerdi MH, et al. Unilateral herpes zoster ophthalmicus results in bilateral corneal nerve alteration: an in vivo confocal microscopy study. *Ophthalmology*. 2013;120:40–47.
781. Hamrah P, Cruzat A, Dastjerdi MH, et al. Corneal sensation and sub-basal nerve alterations in patients with herpes simplex keratitis: an in vivo confocal microscopy study. *Ophthalmology*. 2010;117:1930–1936.
782. Cruzat A, Witkin D, Baniasadi N, et al. Inflammation and the nervous system: the connection in the cornea in patients with infectious keratitis. *Invest Ophthalmol Vis Sci*. 2011;52:5136–5143.
783. Guerrero-Moreno A, Baudouin C, Melik Parsadaniantz S, Réaux-Le Goazigo A. Morphological and functional changes of corneal nerves and their contribution to peripheral

- and central sensory abnormalities. *Front Cell Neurosci.* 2020;14:610342.
784. McNally TW, Figueiredo FC. Corneal neuropathic pain: a patient and physician perspective. *Ophthalmol Ther.* 2024;13:1041–1050.
  785. Galor A, Batawi H, Felix ER, et al. Incomplete response to artificial tears is associated with features of neuropathic ocular pain. *Br J Ophthalmol.* 2016;100:745–749.
  786. Fernandez CA, Galor A, Arheart KL, et al. Dry eye syndrome, posttraumatic stress disorder, and depression in an older male veteran population. *Invest Ophthalmol Vis Sci.* 2013;54:3666–3672.
  787. Galor A, Feuer W, Lee DJ, et al. Depression, post-traumatic stress disorder, and dry eye syndrome: a study utilizing the national United States Veterans Affairs Administrative Database. *Am J Ophthalmol.* 2012;154:340–346.
  788. Segal BM, Pogatchnik B, Henn L, Rudser K, Sivils KM. Pain severity and neuropathic pain symptoms in primary Sjögren's syndrome: a comparison study of seropositive and seronegative Sjögren's syndrome patients. *Arthritis Care Res (Hoboken).* 2013;65:1291–1298.
  789. Dieckmann G, Goyal S, Hamrah P. Neuropathic corneal pain: approaches for management. *Ophthalmology.* 2017;124:S34–S47.
  790. Woltsche JN, Horwath-Winter J, Dorn C, et al. Neuropathic corneal pain as debilitating manifestation of Long-COVID. *Ocul Immunol Inflamm.* 2023;31:1216–1218.
  791. Costa Í F, Bonifácio LP, Bellissimo-Rodrigues F, et al. Ocular findings among patients surviving COVID-19. *Sci Rep.* 2021;11:11085.
  792. Yavuz Saricay L, Bayraktutar BN, Kenyon BM, Hamrah P. Concurrent ocular pain in patients with neurotrophic keratopathy. *Ocul Surf.* 2021;22:143–151.
  793. Qazi Y, Hurwitz S, Khan S, Jurkunas UV, Dana R, Hamrah P. Validity and reliability of a novel Ocular Pain Assessment Survey (OPAS) in quantifying and monitoring corneal and ocular surface pain. *Ophthalmology.* 2016;123:1458–1468.
  794. Farhangi M, Feuer W, Galor A, et al. Modification of the Neuropathic Pain Symptom Inventory for use in eye pain (NPSI-Eye). *Pain.* 2019;160:1541–1550.
  795. Goyal S, Hamrah P. Understanding neuropathic corneal pain—gaps and current therapeutic approaches. *Semin Ophthalmol.* 2016;31:59–70.
  796. Crane AM, Feuer W, Felix ER, et al. Evidence of central sensitisation in those with dry eye symptoms and neuropathic-like ocular pain complaints: incomplete response to topical anaesthesia and generalised heightened sensitivity to evoked pain. *Br J Ophthalmol.* 2017;101:1238–1243.
  797. Patel S, Mittal R, Sarantopoulos KD, Galor A. Neuropathic ocular surface pain: emerging drug targets and therapeutic implications. *Expert Opin Ther Targets.* 2022;26:681–695.
  798. Özmen MC, Dieckmann G, Cox SM, et al. Efficacy and tolerability of nortriptyline in the management of neuropathic corneal pain. *Ocul Surf.* 2020;18:814–820.
  799. Aykut V, Elbay A, Çigdem Uçar I, et al. Corneal sensitivity and subjective complaints of ocular pain in patients with fibromyalgia. *Eye (Lond).* 2018;32:763–767.
  800. Spierer O, Felix ER, McClellan AL, et al. Corneal mechanical thresholds negatively associate with dry eye and ocular pain symptoms. *Invest Ophthalmol Vis Sci.* 2016;57:617–625.
  801. Aggarwal S, Kheirkhah A, Cavalcanti BM, et al. Autologous serum tears for treatment of photoallodynia in patients with corneal neuropathy: efficacy and evaluation with in vivo confocal microscopy. *Ocul Surf.* 2015;13:250–262.
  802. Storås AM, Strümke I, Riegler MA, et al. Artificial intelligence in dry eye disease. *Ocul Surf.* 2022;23:74–86.
  803. Shimizu E, Ishikawa T, Tanji M, et al. Artificial intelligence to estimate the tear film breakup time and diagnose dry eye disease. *Sci Rep.* 2023;13:5822.
  804. Wang Y, Shi F, Wei S, Li X. A deep learning model for evaluating meibomian glands morphology from meibography. *J Clin Med.* 2023;12.
  805. Wang J, Yeh TN, Chakraborty R, Yu SX, MC Lin. A deep learning approach for meibomian gland atrophy evaluation in meibography images. *Transl Vis Sci Technol.* 2019;8:37.
  806. Setu MAK, Horstmann J, Schmidt S, Stern ME, Steven P. Deep learning-based automatic meibomian gland segmentation and morphology assessment in infrared meibography. *Sci Rep.* 2021;11:7649.
  807. Yu Y, Zhou Y, Tian M, et al. Automatic identification of meibomian gland dysfunction with meibography images using deep learning. *Int Ophthalmol.* 2022;42:3275–3284.
  808. Saha RK, Chowdhury AMM, Na KS, et al. Automated quantification of meibomian gland dropout in infrared meibography using deep learning. *Ocul Surf.* 2022;26:283–294.
  809. Swiderska K, Blackie CA, Maldonado-Codina C, Morgan PB, Read ML, Fergie M. A deep learning approach for meibomian gland appearance evaluation. *Ophthalmol Sci.* 2023;3:100334.
  810. Wang S, He J, He X, et al. AES-CSFS: an automatic evaluation system for corneal sodium fluorescein staining based on deep learning. *Ther Adv Chron Dis.* 2023;14:20406223221148266.
  811. Nair PP, Keskar M, Borghare PT, Methwani DA, Nasre Y, Chaudhary M. Artificial intelligence in dry eye disease: a narrative review. *Cureus.* 2024;16:e70056.
  812. Huet E, Vallée B, Delbé J, et al. EMMPRIN modulates epithelial barrier function through a MMP-mediated occludin cleavage: implications in dry eye disease. *Am J Pathol.* 2011;179:1278–1286.
  813. Jamerson EC, Elhusseiny AM, ElSheikh RH, Eleiwa TK, El Sayed YM. Role of matrix metalloproteinase 9 in ocular surface disorders. *Eye Contact Lens.* 2020;46(suppl 2):S57–S63.
  814. Sivak JM, Fini ME. MMPs in the eye: emerging roles for matrix metalloproteinases in ocular physiology. *Prog Retinal Eye Res.* 2002;21:1–14.
  815. Murphy G, Stanton H, Cowell S, et al. Mechanisms for pro matrix metalloproteinase activation. *APMIS.* 1999;107:38–44.
  816. Lu Z, Liu T, Zhou X, et al. Rapid and quantitative detection of tear MMP-9 for dry eye patients using a novel silicon nanowire-based biosensor. *Biosensors Bioelectronics.* 2022;214:114498.
  817. McDevitt H, Munson S, Ettinger R, Wu A. Multiple roles for tumor necrosis factor-alpha and lymphotoxin alpha/beta in immunity and autoimmunity. *Arthritis Res.* 2002;4(suppl 3):S141–S152.
  818. Körner H, Sedgwick JD. Tumour necrosis factor and lymphotoxin: molecular aspects and role in tissue-specific autoimmunity. *Immunol Cell Biol.* 1996;74:465–472.

819. Ruddle NH. Lymphoid neo-organogenesis: lymphotoxin's role in inflammation and development. *Immunol Res.* 1999;19:119–125.
820. Howard Tripp N, Tarn J, Natasari A, et al. Fatigue in primary Sjögren's syndrome is associated with lower levels of proinflammatory cytokines. *RMD Open.* 2016;2:e000282.
821. Davies K, Mirza K, Tarn J, et al. Fatigue in primary Sjögren's syndrome (pSS) is associated with lower levels of proinflammatory cytokines: a validation study. *Rheumatol Int.* 2019;39:1867–1873.
822. Chen H, Chen H, Liang L, et al. Evaluation of tear protein markers in dry eye disease with different lymphotoxin-alpha expression levels. *Am J Ophthalmol.* 2020;217:198–211.
823. March de Ribot F, Benitez Del Castillo JM, Geerling G, Messmer EM, Baudouin C, Alves M. Dry eye disease sustainability. *Ocul Surf.* 2023;30:104–106.
824. Nasa P, Jain R, Juneja D. Delphi methodology in healthcare research: how to decide its appropriateness. *World J Methodol.* 2021;11:116–129.
825. Graham B, Regehr G, Wright JG. Delphi as a method to establish consensus for diagnostic criteria. *J Clin Epidemiol.* 2003;56:1150–1156.
826. Mathewson PA, Williams GP, Watson SL, Hodson J, Bron AJ, Rauz S. Defining ocular surface disease activity and damage indices by an international Delphi consultation. *Ocul Surf.* 2017;15:97–111.
827. Baudouin C, Aragona P, Van Setten G, et al. Diagnosing the severity of dry eye: a clear and practical algorithm. *Br J Ophthalmol.* 2014;98:1168–1176.
828. Barabino S, Aragona P, di Zazzo A, Rolando M. with the contribution of selected ocular surface experts from the Societa Italiana di Dacriologia e Superficie O. Updated definition and classification of dry eye disease: renewed proposals using the nominal group and Delphi techniques. *Eur J Ophthalmol.* 2021;31:42–48.
829. Farid M, Ayres BD, Donnenfeld E, et al. Delphi panel consensus regarding current clinical practice management options for Demodex blepharitis. *Clin Ophthalmol.* 2023;17:667–679.