



Figure 1.2: Illustrating the **A-** tip pinch grip and **B-** lateral (key) pinch.

Acknowledgement: www.sagepub.com

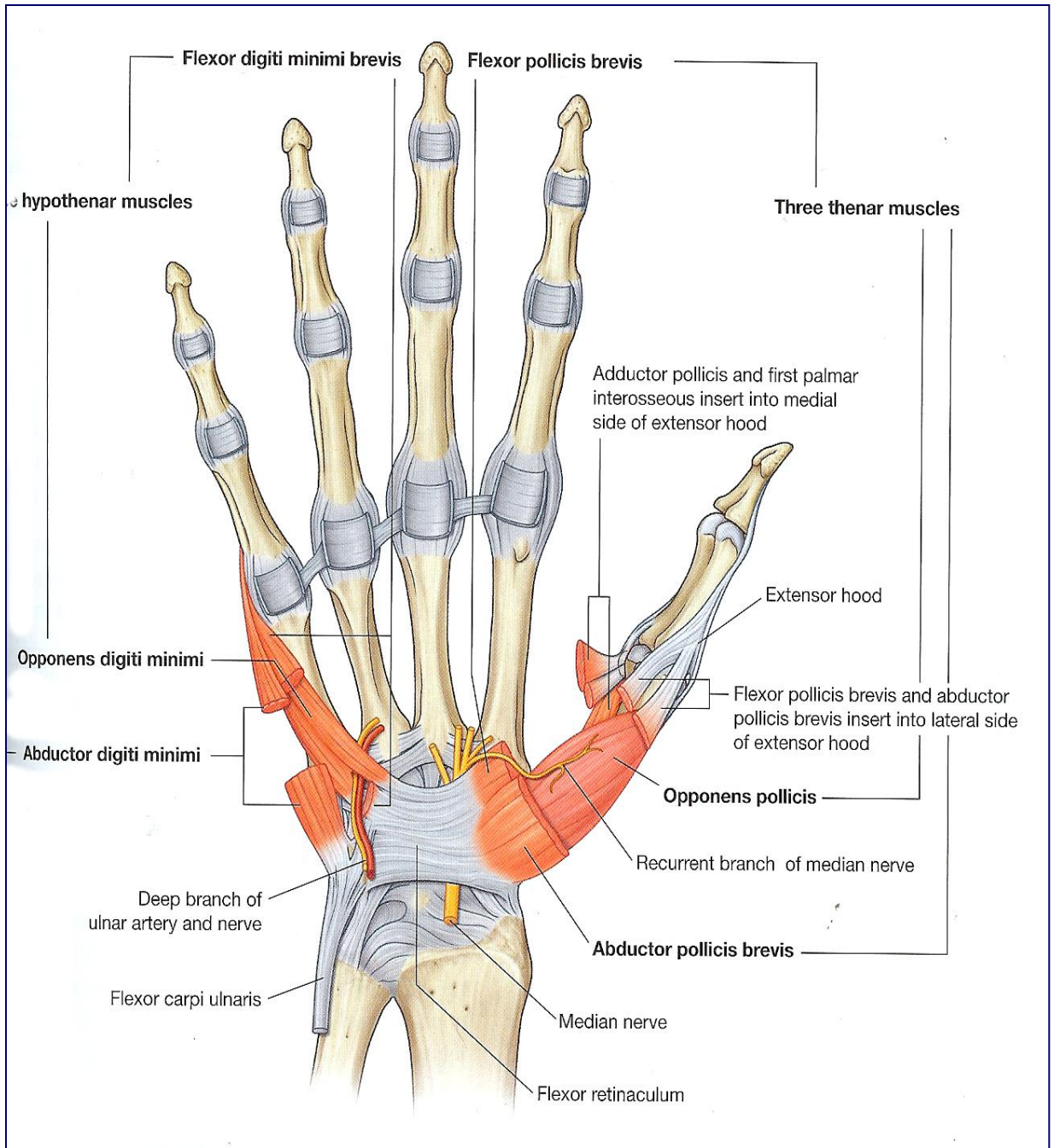


Figure 1.3: Muscles that help with the movement of the thumb.

Acknowledgement: Drake RL, Vogl W and Mitchell AWM. Grey's anatomy for students, 2nd Edition, London UK; Elsevier Churchill Livingstone publication; 2007b: 721

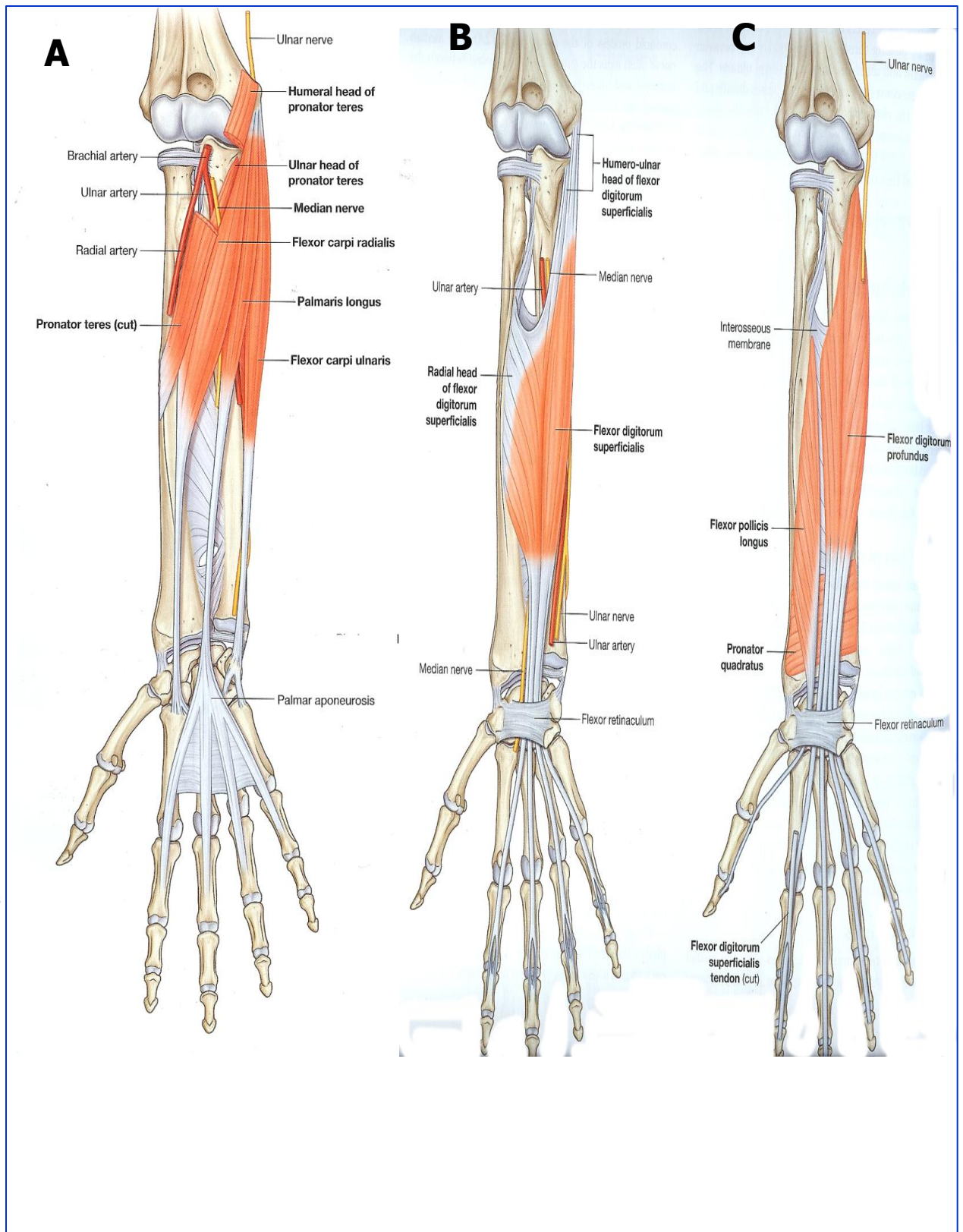


Figure 1.4: Extrinsic muscles of the hand and thumb. (A) showing the superficial layer (B) showing the intermediate layer while (C) shows the deep layers of flexor muscles.

Acknowledgement: Drake RL, Vogl W and Mitchell AWM. Grey's anatomy for students, 2nd Edition, London UK; Elsevier Churchill Livingstone publication; 2007c: 700-702

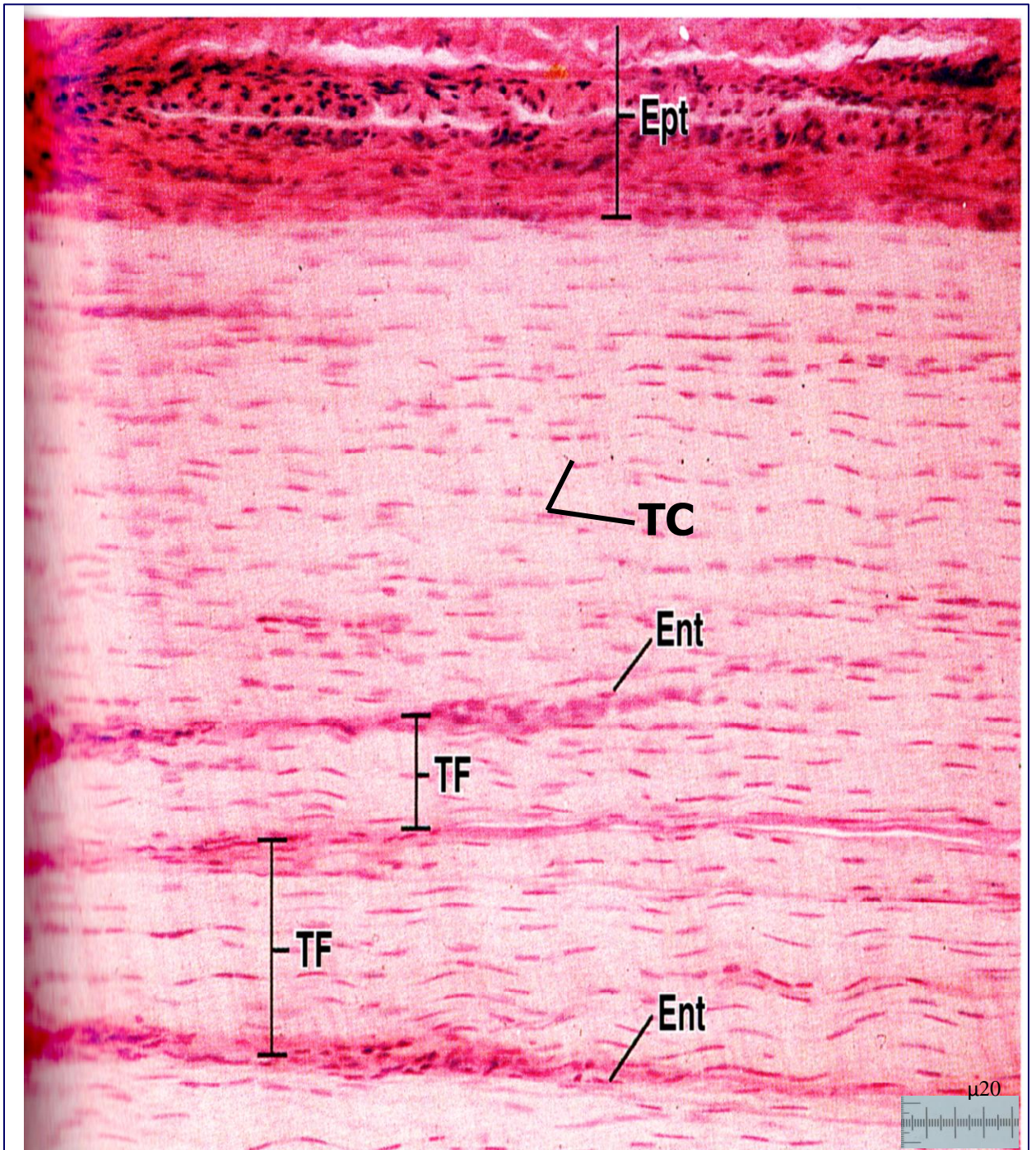


Figure 1.7: Illustrating the normal histology of the flexor tendon of the fingers (magnification x20) wherein Ent- endotenon, Ept- epitenon, Tf- collection of collagen in extra cellular matrix and TC- tendonocyte nuclei.

Acknowledgement: Ross MH and Pawlina W. Histology- A text book and atlas, 5th Edition Lippincott Williams and Wilkins publication; 2006: 179

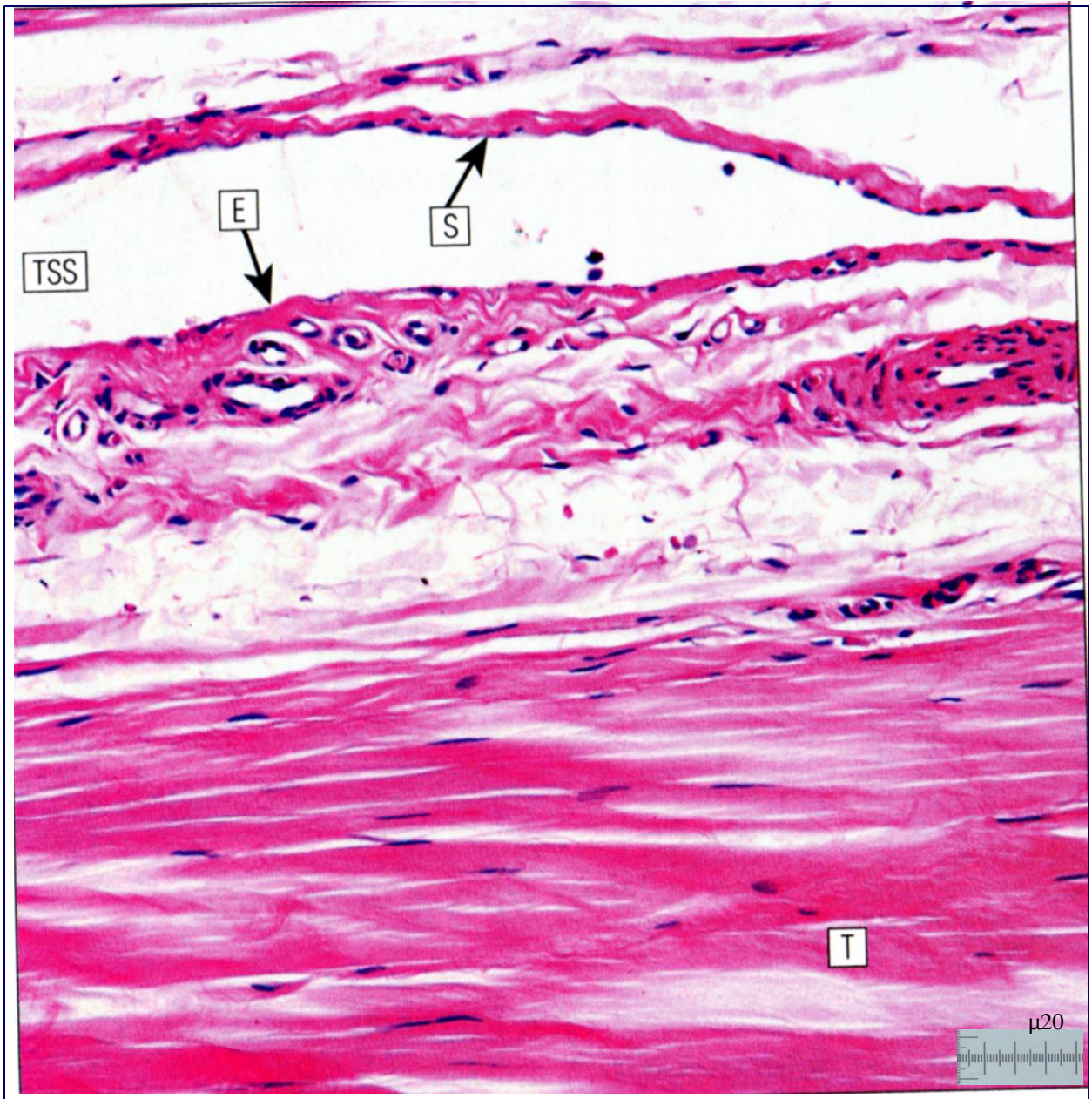


Figure 1.8: Illustrating the normal histology of the flexor tenosynovium (magnification x20) wherein T- flexor tendon, E- epitendineum, S- thin outer fibrous tendon sheath, TSS- tendon sheath space. The magnification is x20.

Acknowledgement: Steven A and Lowe J. Human Histology, 3rd Edition, Elsevier Mosby publication; 2005: 250

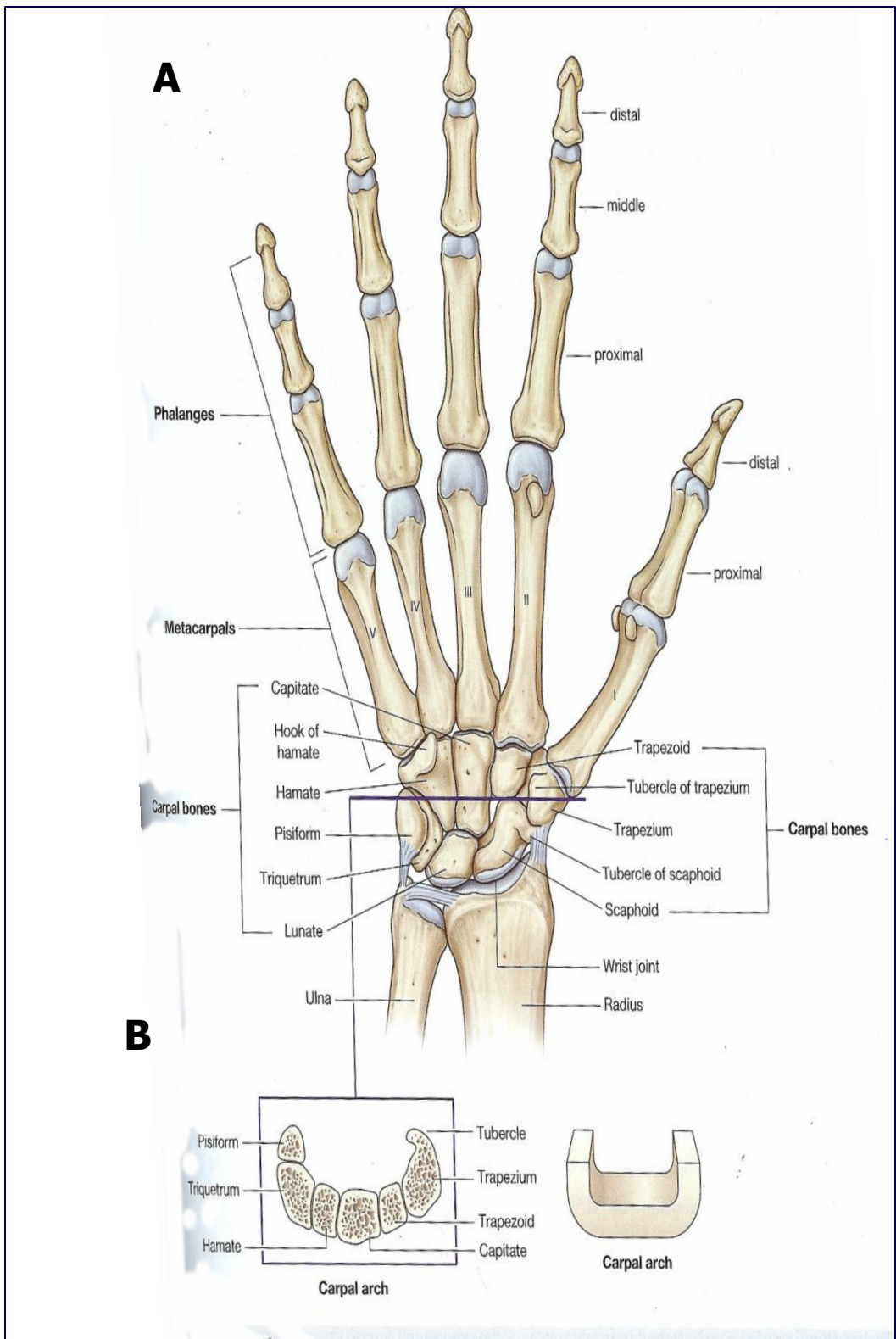


Figure 1.9: Skeleton of the hand (A), while (B) shows the carpal arch.

Acknowledgement: Drake RL, Vogl W and Mitchell AWM. Grey's anatomy for students, London UK; 2nd Edition, Elsevier Churchill Livingstone publication; 2007a: 709

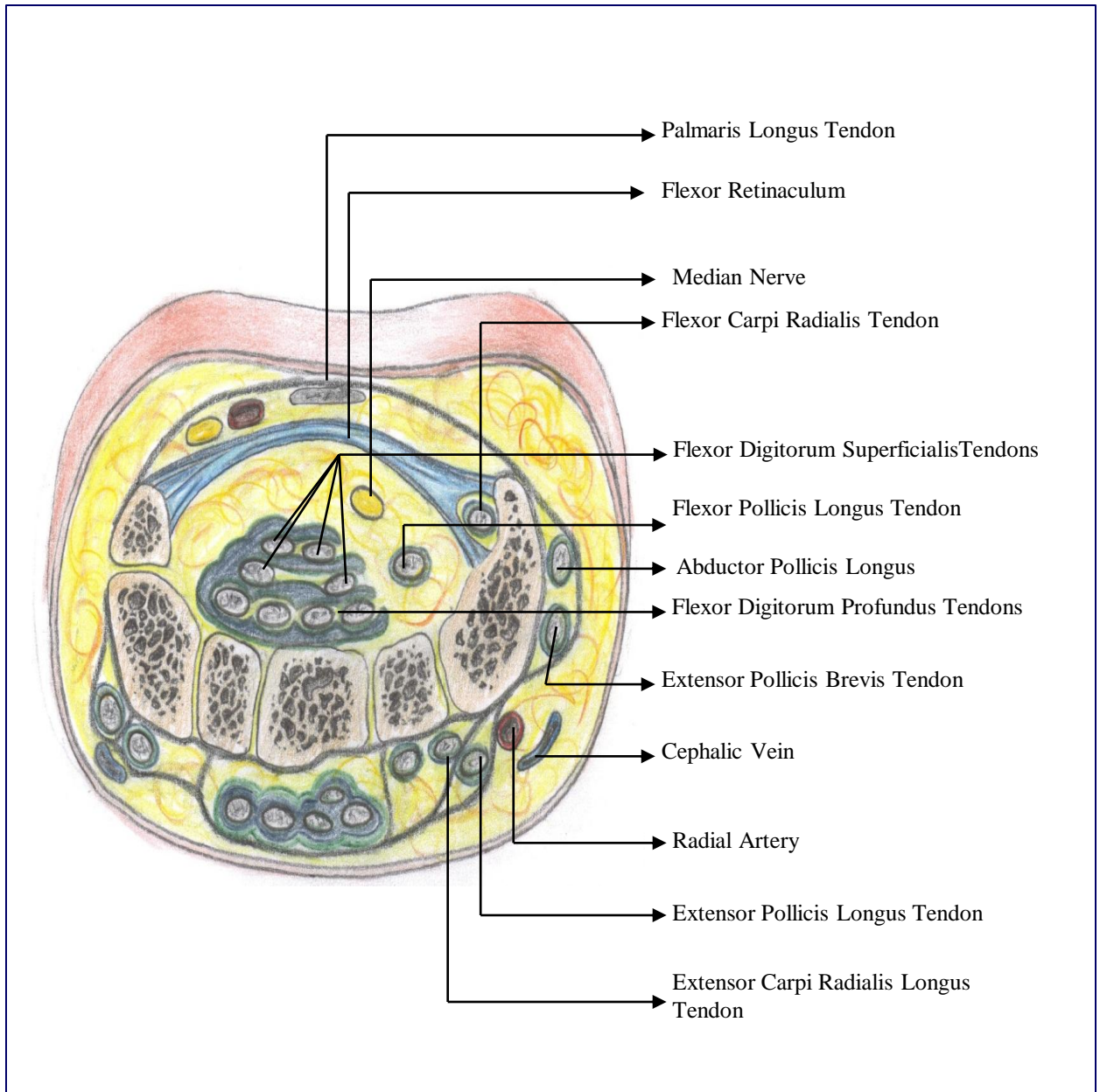


Figure 1.10: Cross section of the carpal tunnel.

Acknowledgement: Wheat J, Satherley L, Stephens S and Enoch S. Applied Surgical Anatomy for MRCS OSCE, Doctors Academy Publication, 1st Edition, Cardiff, UK, 2009:17

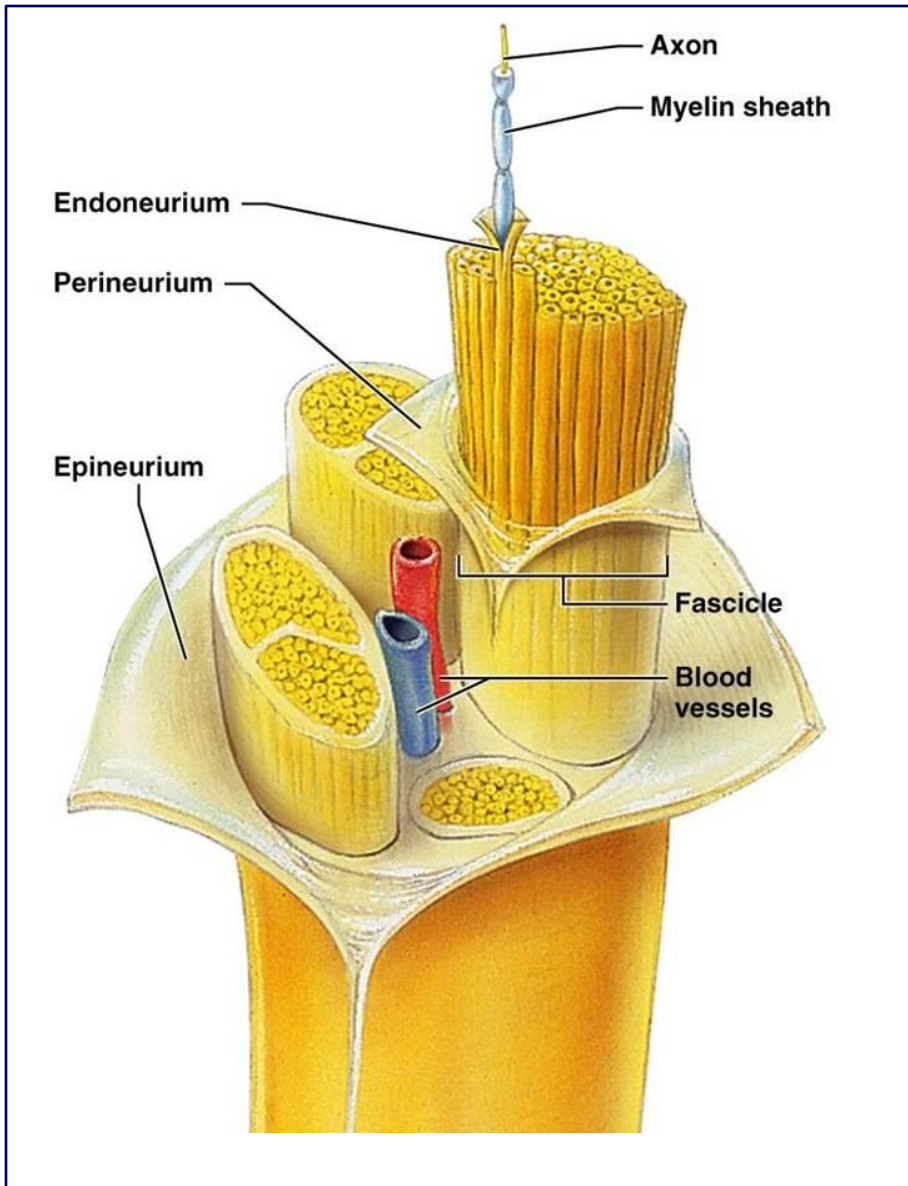


Figure 1.11 : Showing the different covering of a peripheral nerve.

Acknowledgement: www.sosondoc.egloos.com

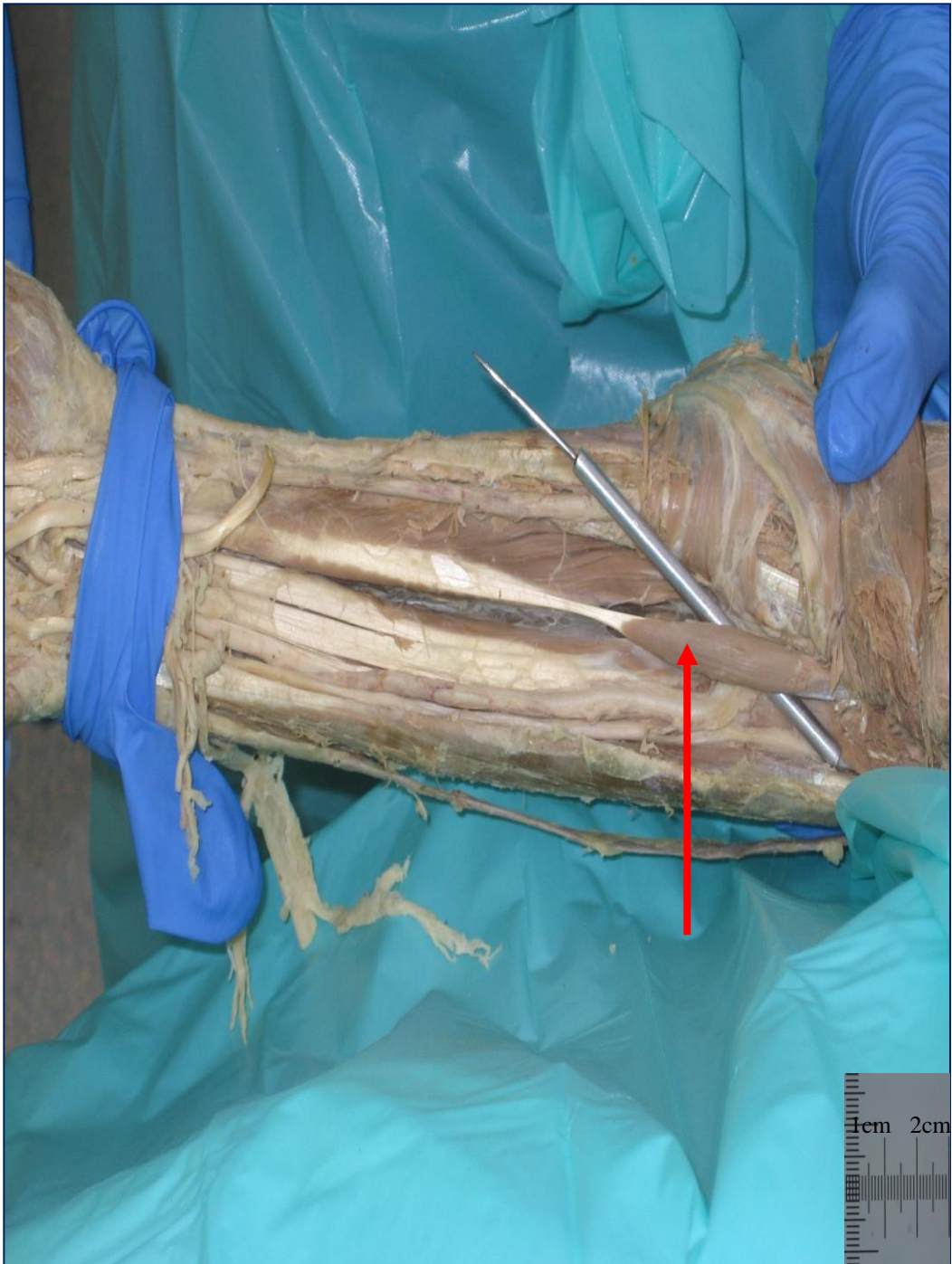

Figure 1.15A: Accessory head of Flexor Pollicis Longus (Arrowed).

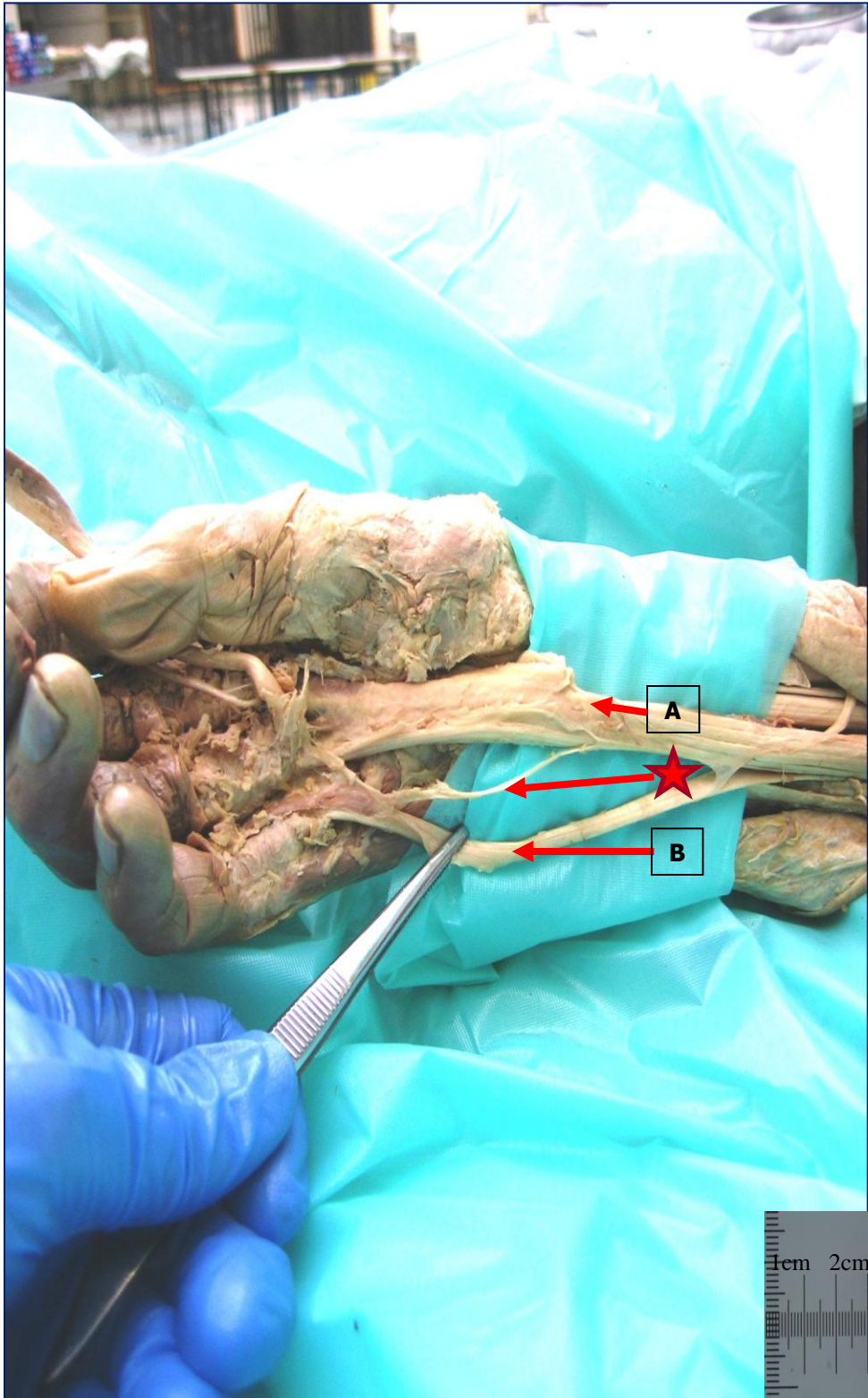


Figure 1.15B: Interconnection (★) between the Flexor Digitorum Profundus of ring finger (A) and little fingers (B).

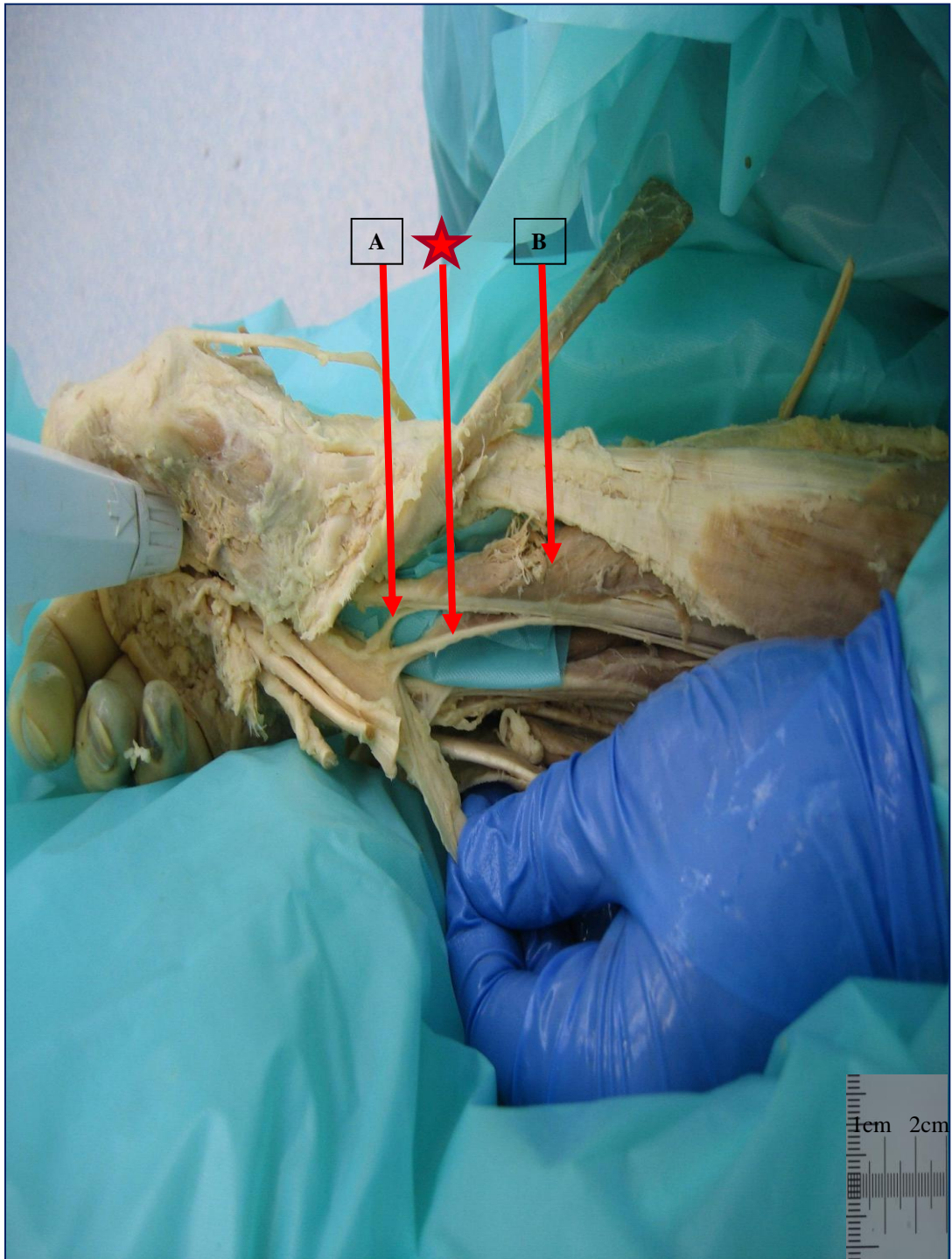


Figure 1.15C: Interconnection (★) between the Flexor Digitorum Profundus of index finger (A) and Flexor Pollicis Longus (B).

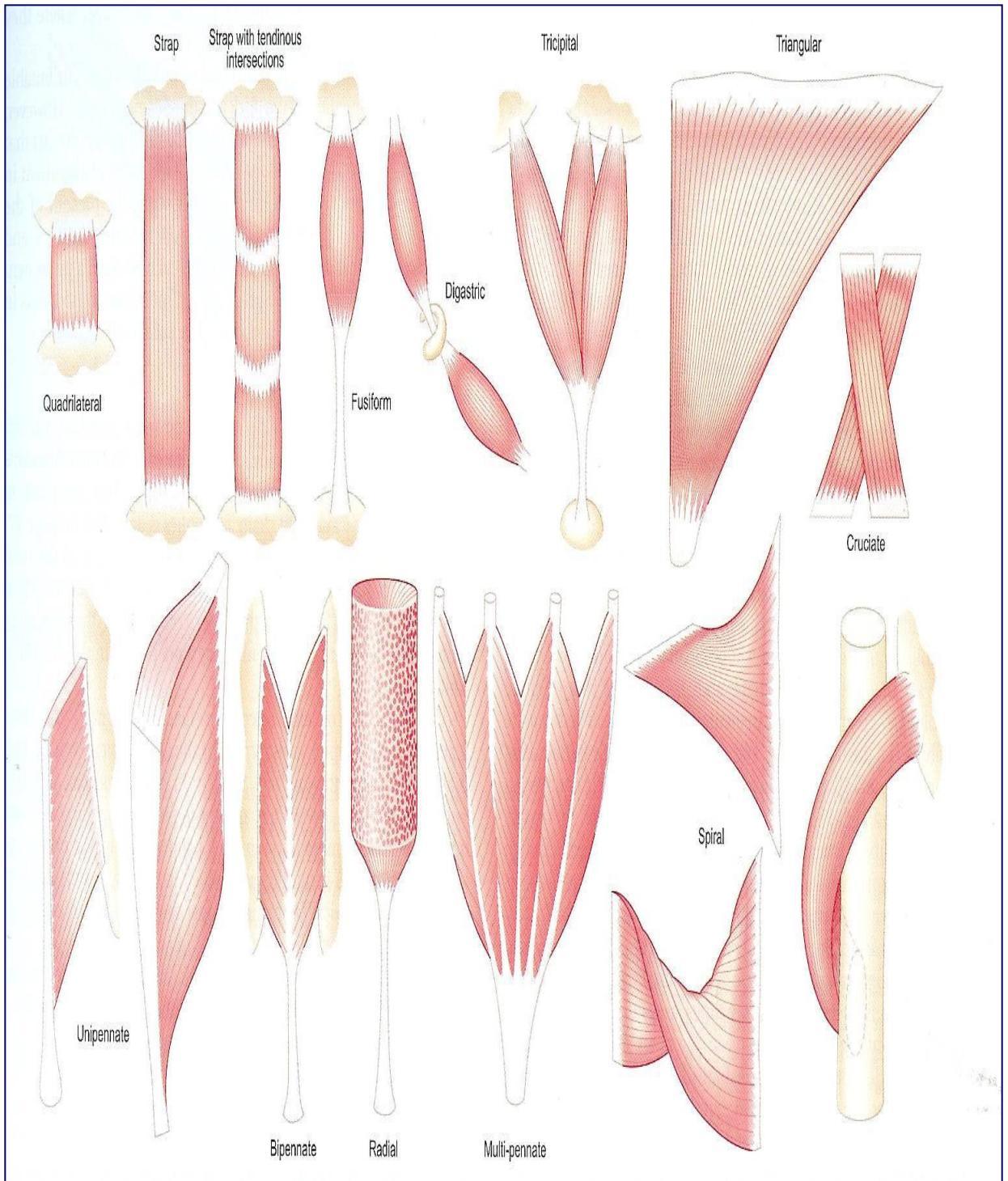


Figure 2.1: Morphological types of muscle based on their general form and fascicular architecture.

Acknowledgement: Stradring S, Grays anatomy, The anatomical basis of clinical practice, 39th Edition, London UK, by Elsevier Churchill Livingstone publication; 2005: 113

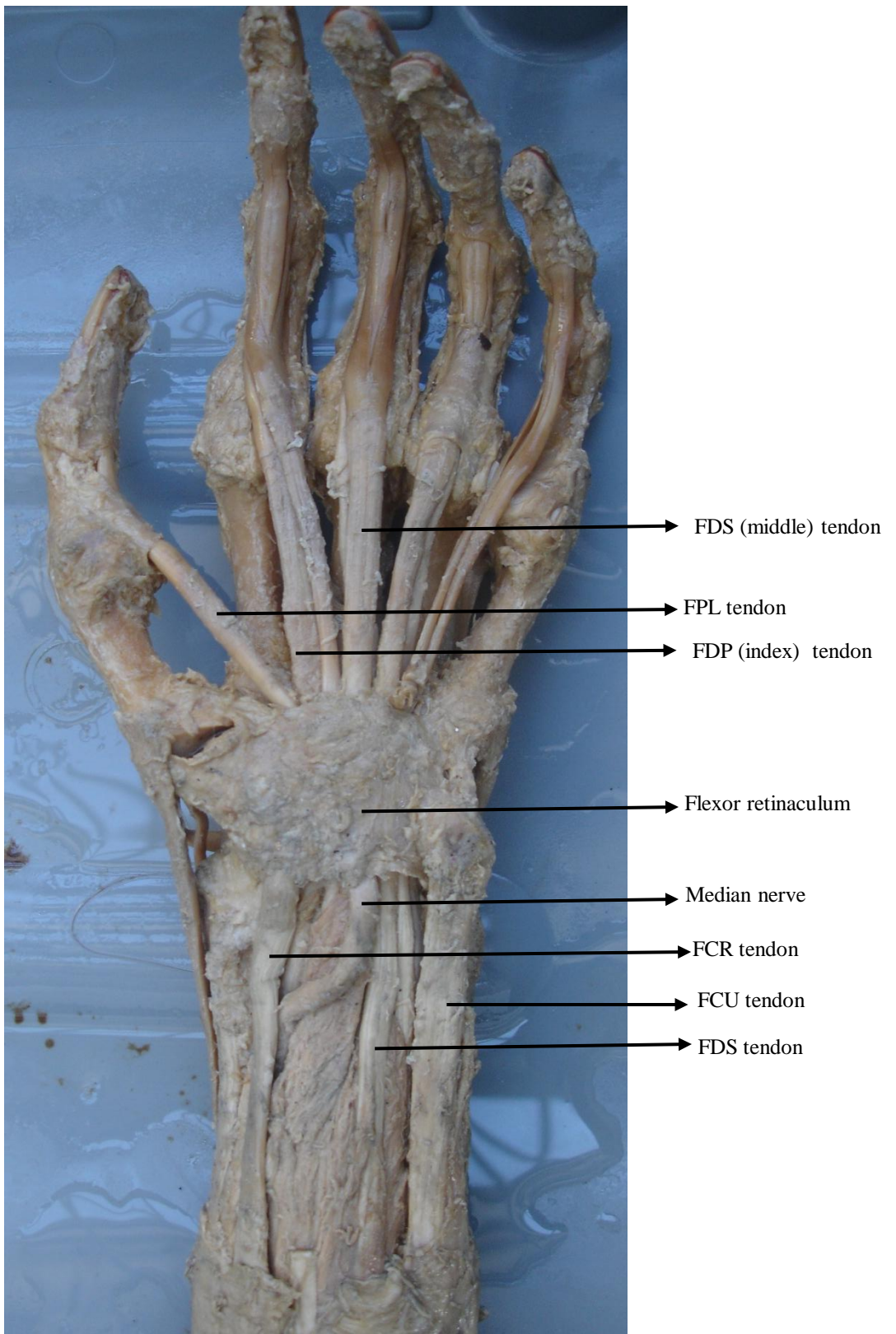


Figure 2.2: Shows the relations of FPL, FDS, FDP, FCU and FCR.




Figure 2.4: Shows the method used to calculate the tendon length.

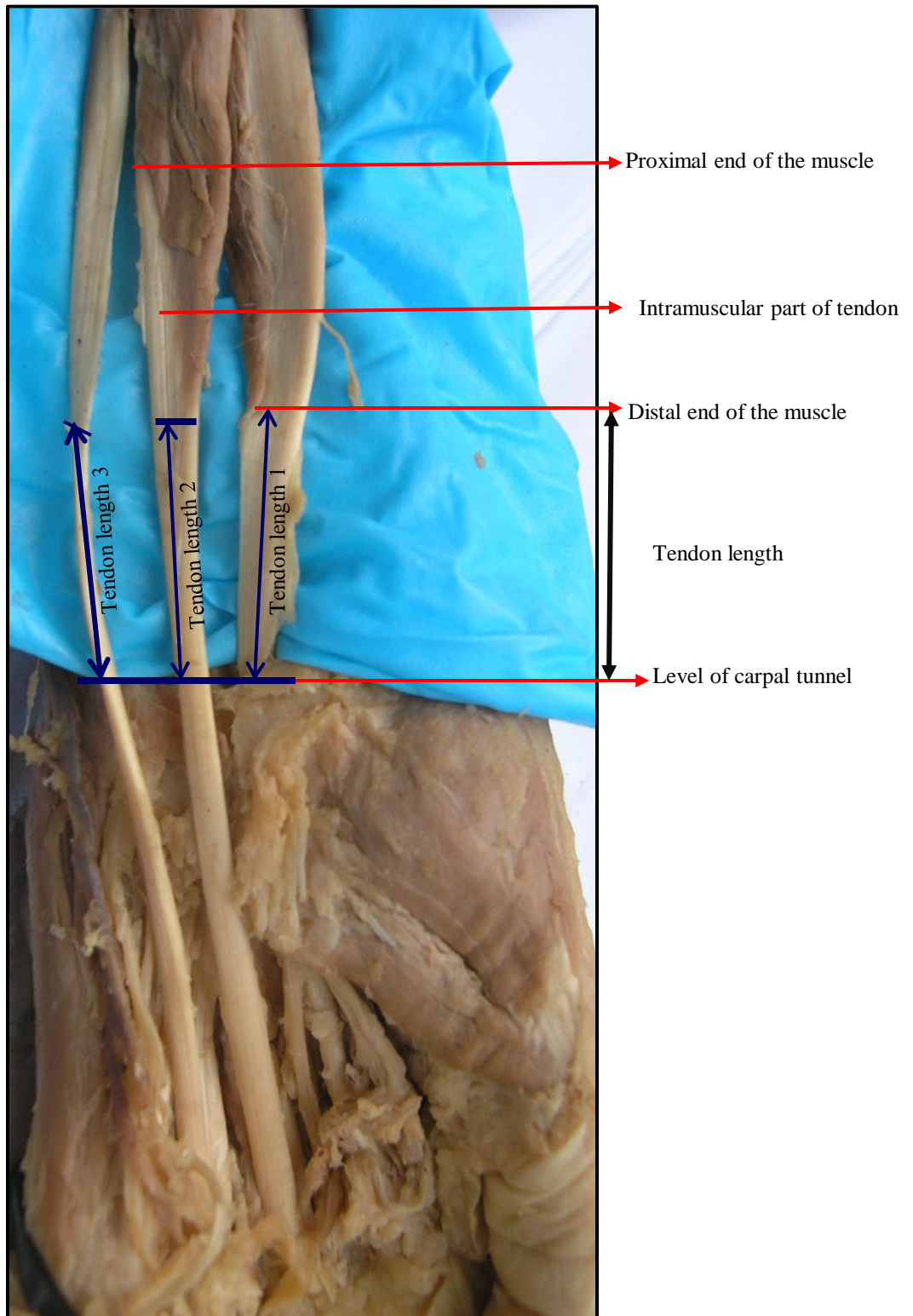



Figure 2.5: Illustrating the method used to calculate the tendon length of multipennate muscle (FDS). The mean of all the extra muscular tendon length up to the carpal tunnel were taken.



Midpoint of the muscle
(midpoint between the origin and distal
Insertion of the muscle)

	Lateral angle	Medial angle
	10°	12°
	11°	15°
	9°	12°
Mean	10°	13°
Angle of pennation	13°	

Figure 2.6: Illustrating the method undertaken to calculate the midpoint and angle of pennation in a multipennate muscle.




Figure 2.8: Illustrating the FDS muscle after being removed from the cadaver for measuring the mass and density. Note that the intramuscular part of the tendon had been left intact.

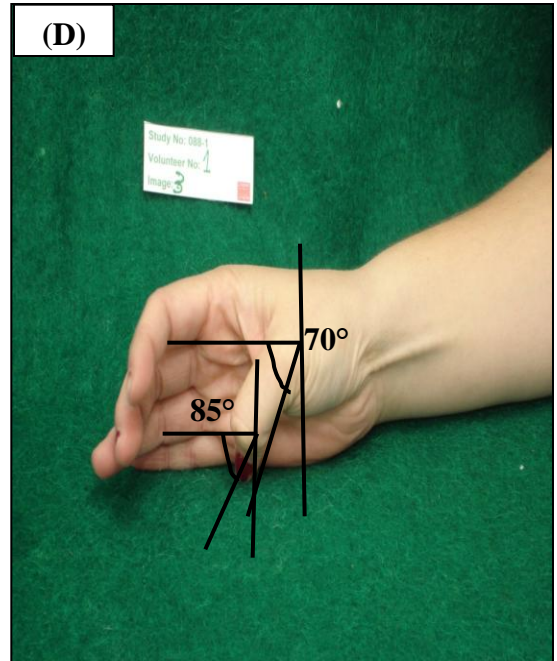
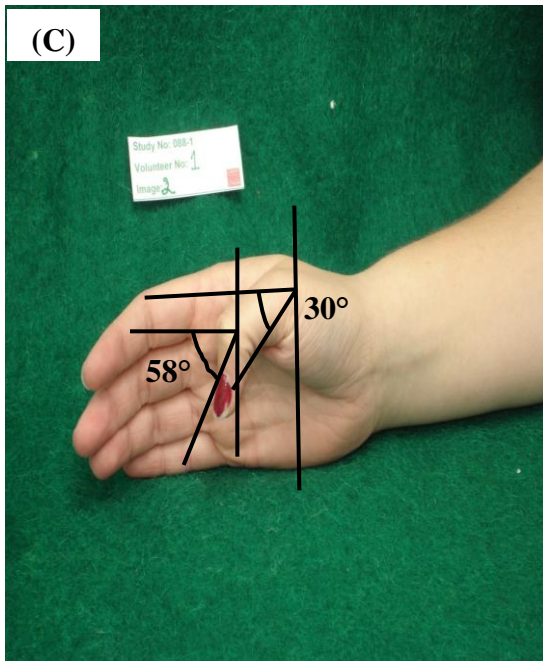
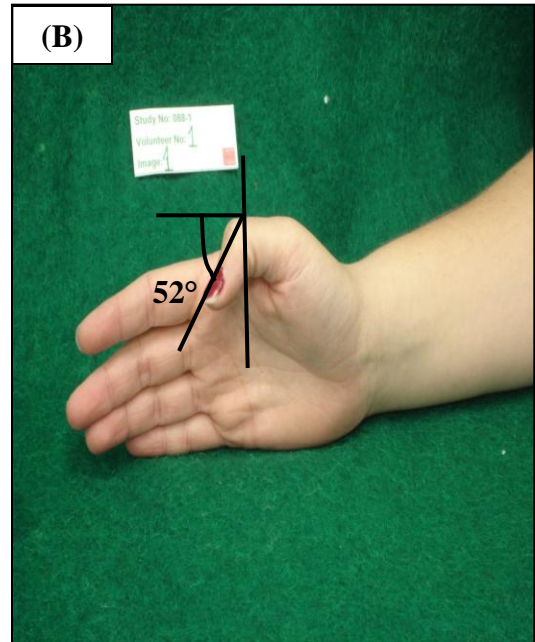
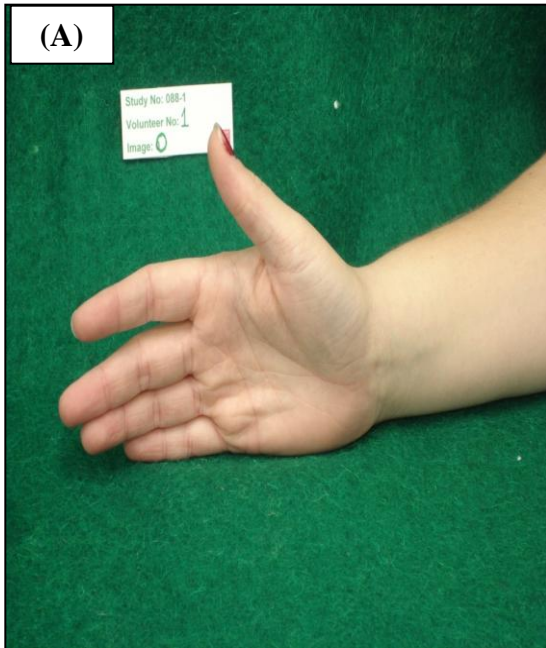

Figure 2.11: Demonstrating the different angles of flexion of the right thumb, index and middle fingers in mid prone position. (A) at rest, (B): initial movement, (C): mid position and (D) fully flexed.



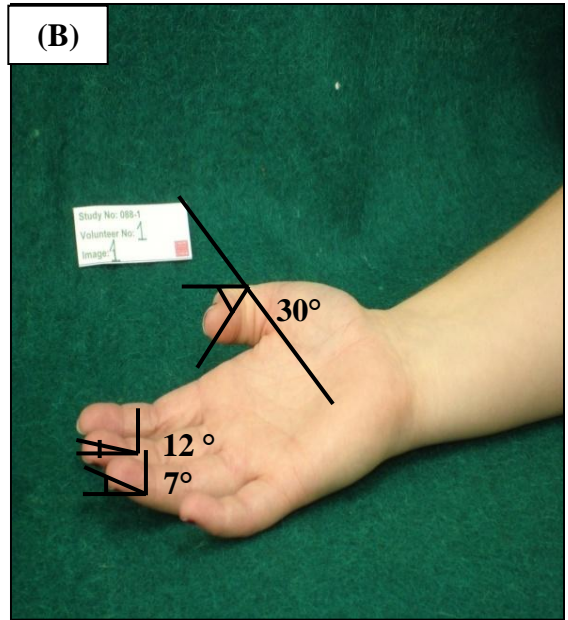
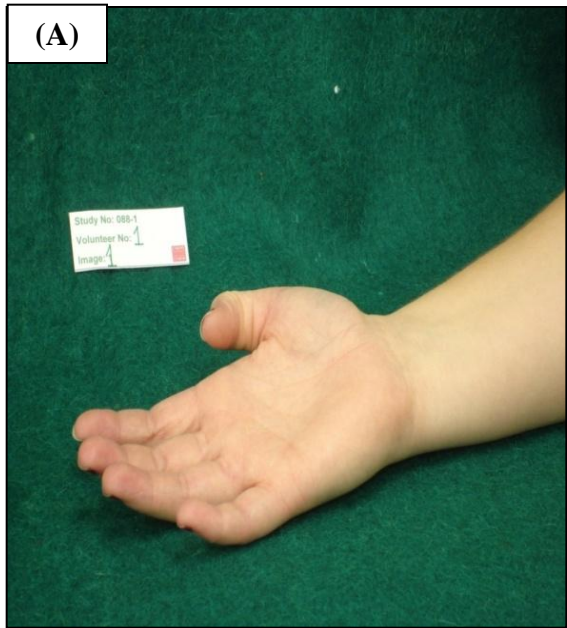


Figure 2.12: Demonstrating the different angles of flexion of the right thumb, index and middle fingers in supination position. (A) at rest, (B): initial movement, (C): mid position and (D) fully flexed.




FCR tendon removed 2cms above its bony insertion




FDP (index) tendon removed 2cms above the carpal tunnel



FPL tendon removed 2cms above the carpal tunnel

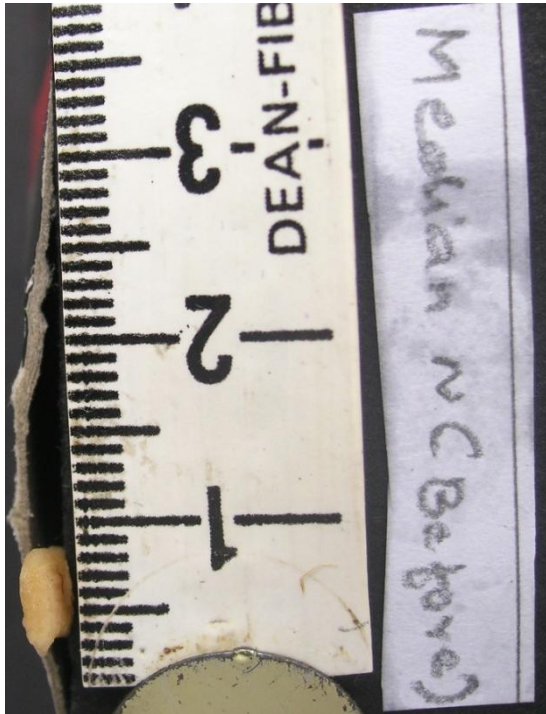


FDS (index) tendon removed 2cms above the carpal tunnel




FCU tendon removed 2cms above its bony insertion


Figure 2.13: Shows the five tendons that were used to calculate TCSA using the Image Pro-Plus software.



Median nerve **before** the carpal tunnel



Median nerve **at** the carpal tunnel



Measuring tape

Median nerve

Median nerve **after** the carpal tunnel

Figure 2.14: Shows the median nerve samples that were used to calculate the cross sectional area using the Image Pro-Plus software.

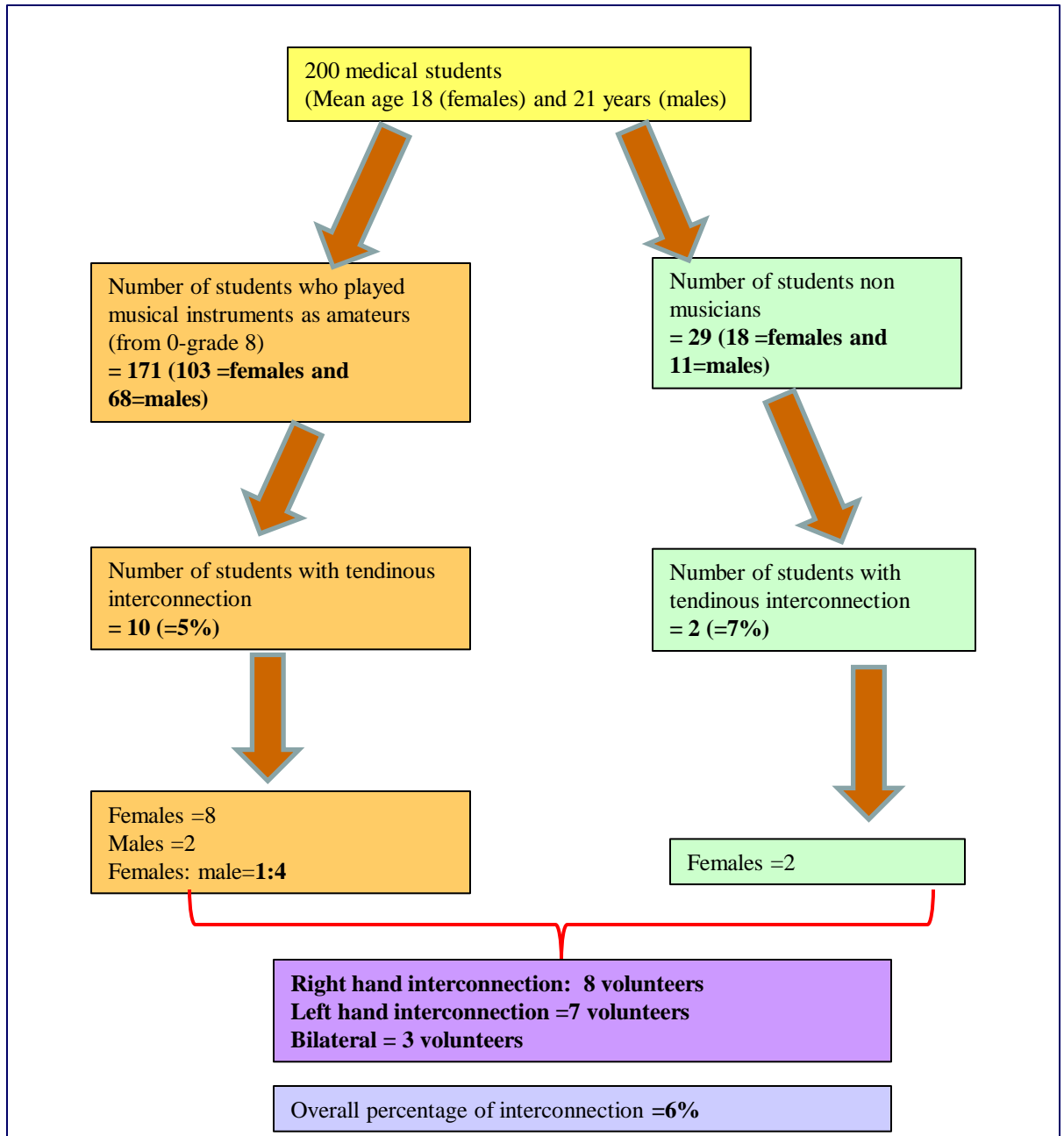


Table 3.1: Shows the general statistics of volunteer study.

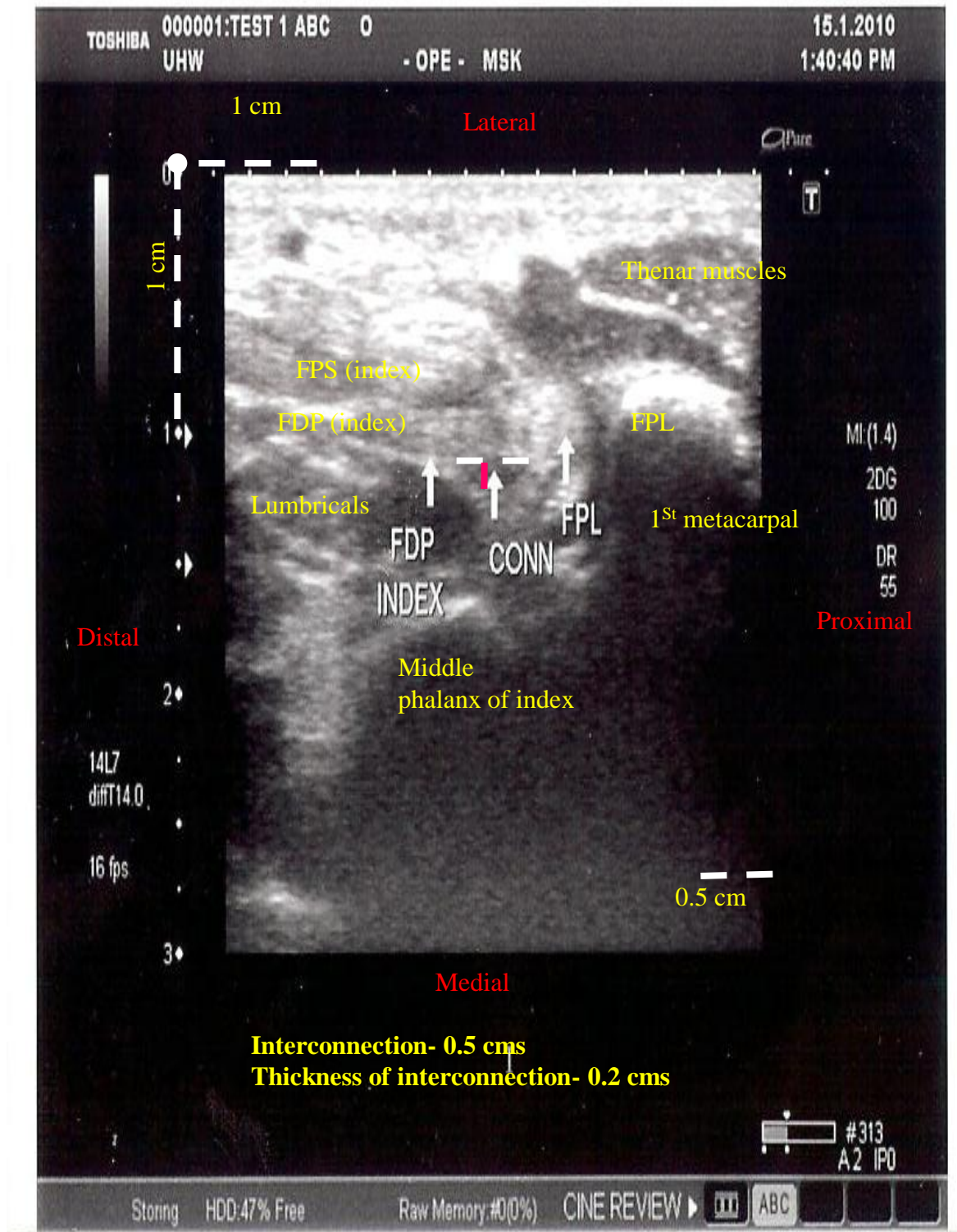
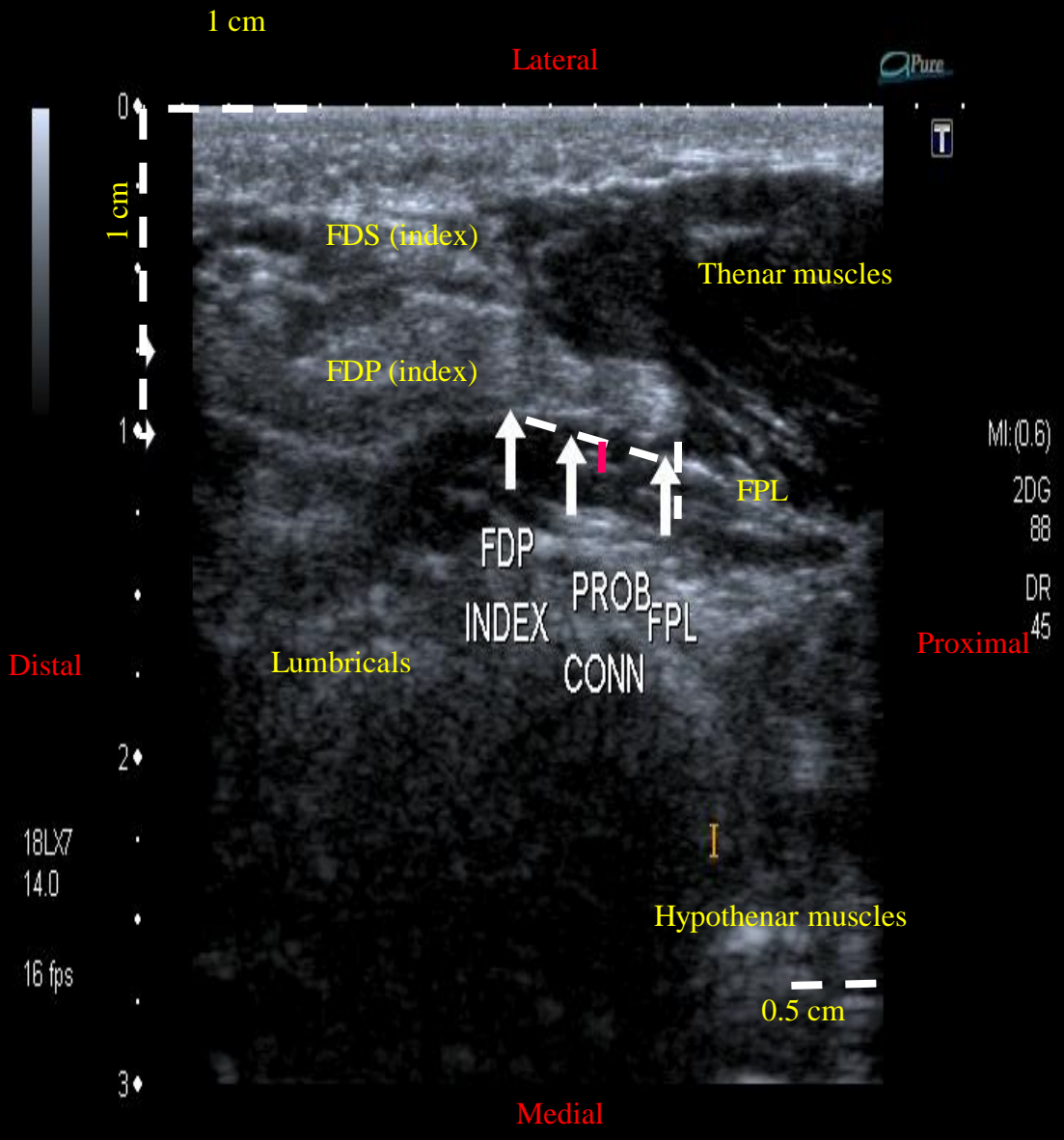


Figure 3.25: Illustrating the tenosynovial interconnection (Conn) between the FPL and FDP (Index) in the left hand of Volunteer '2'.



Interconnection- 0.8 cms
Thickness of interconnection- 0.2 cms

#389
A1 IPO

Figure 3.26: Illustrating the tenosynovial interconnection (Prob Conn) between the FPL and FDP (Index finger) in the left hand of Volunteer '3'.

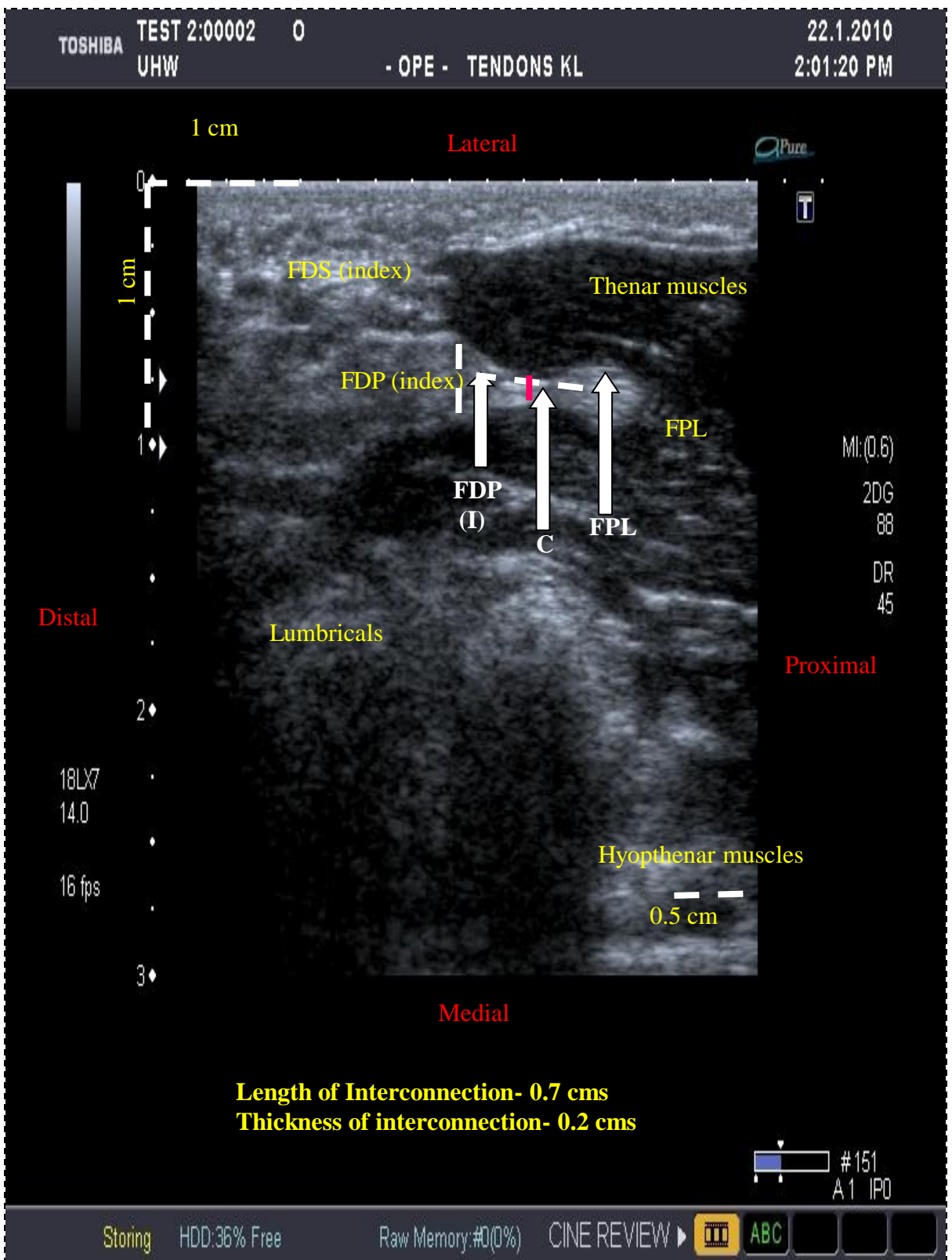


Figure 3.27 : Illustrating the probable tendinous interconnection (C) between the FPL and FDP (Index finger) in the right hand of Volunteer '9'. This was not very conclusive.

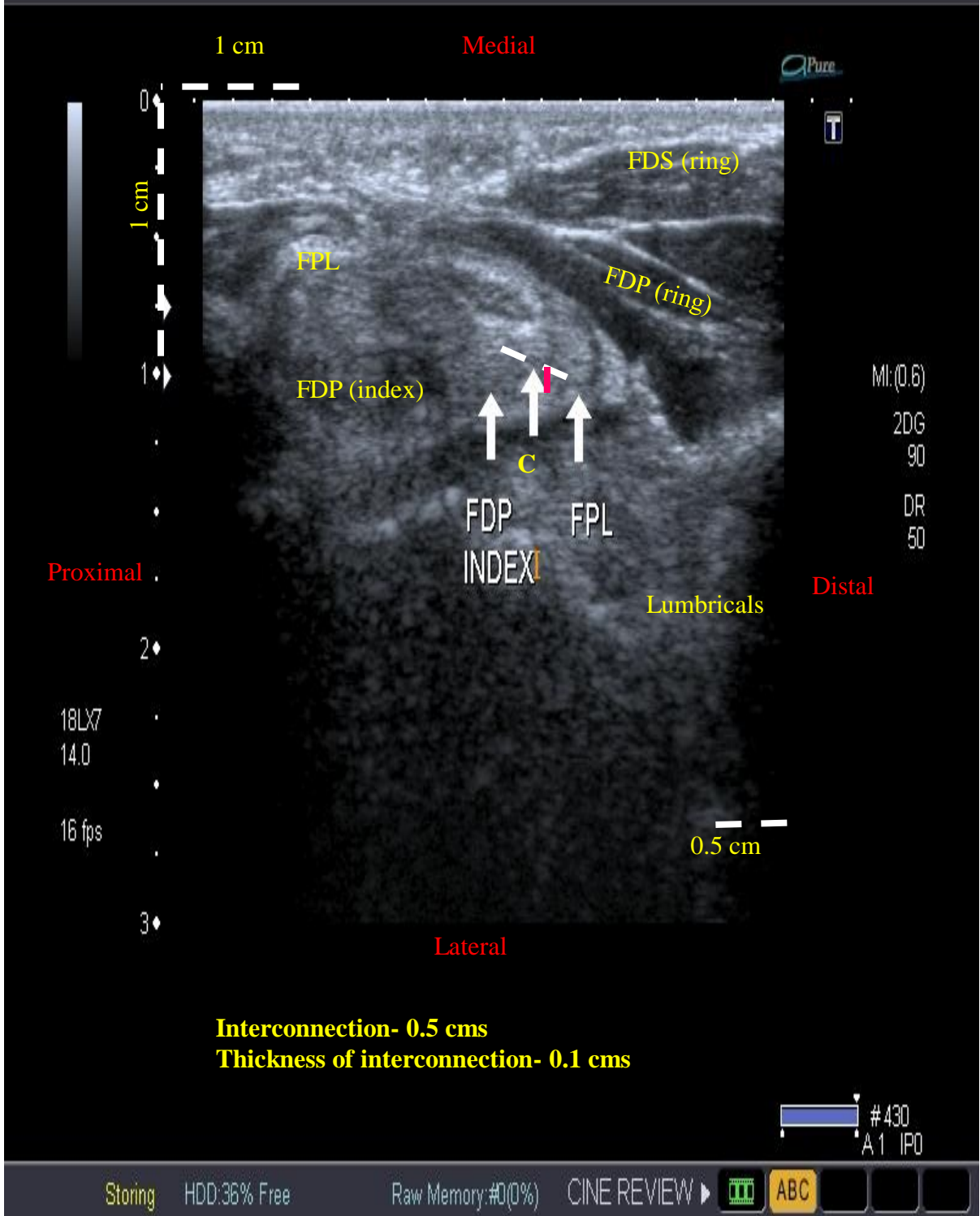


Figure 3.28: Illustrating the tendinous interconnection (C) between the FPL and FDP (Index finger) in the left hand of Volunteer '12'.

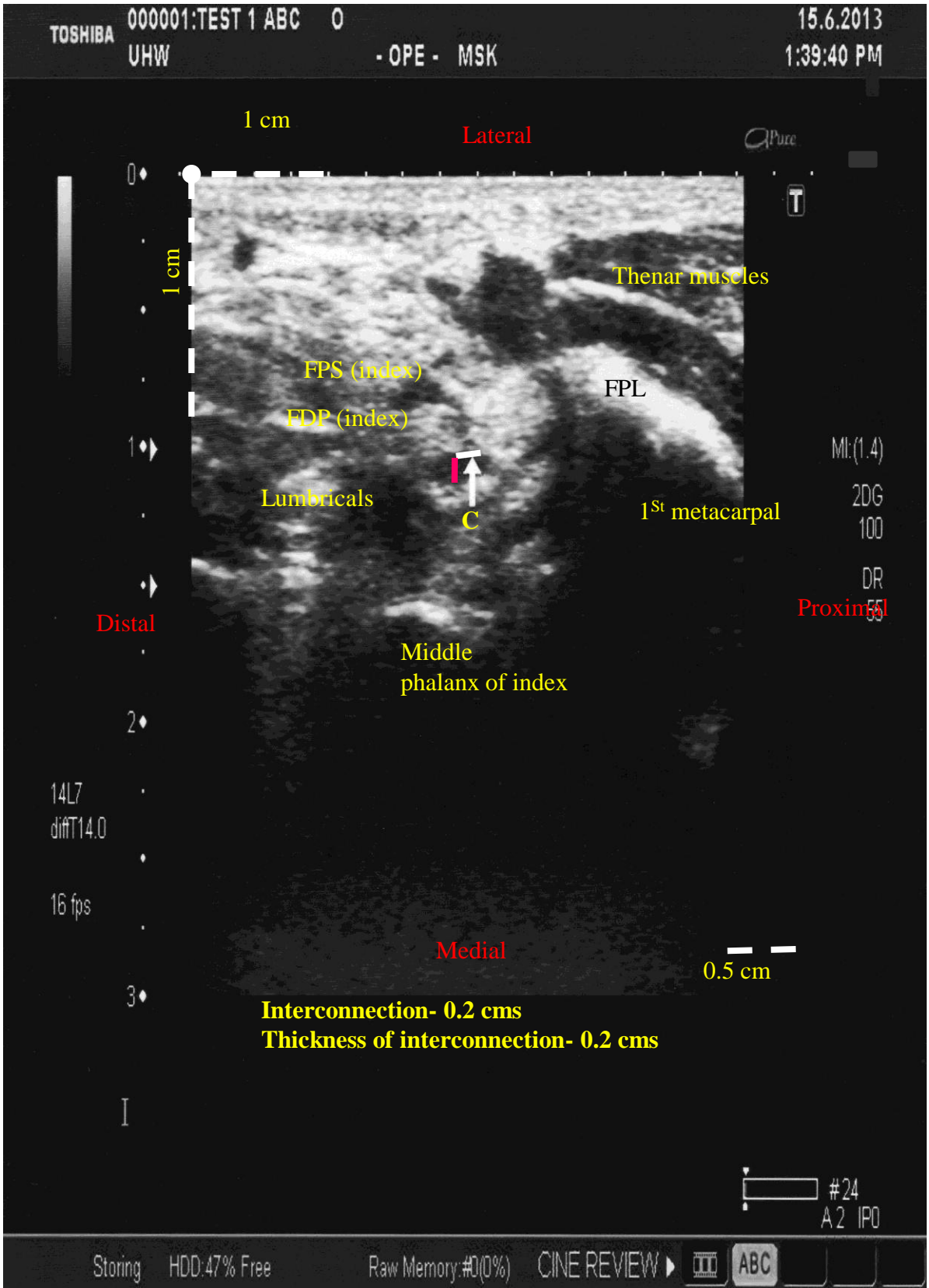


Figure 3.44: Illustrating the tendinous interconnection (C) between the FPL and FDP (Index finger) in the left hand of Volunteer '1'. Taken during repeatability and reliability study.