

Bound by  
**Abbey Bookbinding**



Unit 3 Clos Menter  
Gabaifa Workshops  
Western Avenue  
Cardiff CF14 3AY

T: +44 (0) 29 2062 3290  
F: +44 (0) 29 2062 5420

E: [info@abbeybookbinding.co.uk](mailto:info@abbeybookbinding.co.uk)  
W: [www.abbeybookbinding.co.uk](http://www.abbeybookbinding.co.uk)

# molecular mechanisms of human thyroid tumorigenesis



## Sir Herbert Duthie Library *Llyfrgell Syr Herbert Duthie*

University Hospital  
of Wales  
Heath Park  
Cardiff  
CF14 4XN

Ysbyty Athrofaol Cymru  
Parc y Mynydd Bychan  
Caerdydd  
CF14 4XN

029 2074 2875  
[duthieliby@cardiff.ac.uk](mailto:duthieliby@cardiff.ac.uk)



# **Molecular mechanisms of human thyroid tumorigenesis**

A thesis submitted for the degree  
of Doctor of Philosophy by:

**Elizabeth Louise Ball**

Department of Pathology  
School of Medicine, Cardiff University  
30<sup>th</sup> September, 2007

UMI Number: U584293

All rights reserved

INFORMATION TO ALL USERS

The quality of this reproduction is dependent upon the quality of the copy submitted.

In the unlikely event that the author did not send a complete manuscript and there are missing pages, these will be noted. Also, if material had to be removed, a note will indicate the deletion.



UMI U584293

Published by ProQuest LLC 2013. Copyright in the Dissertation held by the Author.  
Microform Edition © ProQuest LLC.

All rights reserved. This work is protected against  
unauthorized copying under Title 17, United States Code.




ProQuest LLC  
789 East Eisenhower Parkway  
P.O. Box 1346  
Ann Arbor, MI 48106-1346




## DECLARATION

This work has not previously been accepted in substance for any degree and is not concurrently submitted in candidature for any degree.

Signed  (candidate) Date 30.09.2007


## STATEMENT 1

This thesis is being submitted in fulfilment of the requirements for the degree of PhD.

Signed  (candidate) Date 30.09.2007


## STATEMENT 2

This thesis is the result of my own independent investigation, except where otherwise stated. Other sources are acknowledged by explicit references.

Signed  (candidate) Date 30.09.2007

## STATEMENT 3

I hereby give consent for my thesis, if accepted, to be available for photocopying and for inter-library loan, and for the title and summary to be made available to outside organisations.

Signed  (candidate) Date 30.09.2007

## SUMMARY

Thyroid cancer is the commonest endocrine malignancy. Several of the initiating genetic events in thyroid tumorigenesis have been identified, although the exact molecular mechanisms are unclear. Our thyrocyte model has demonstrated that p16<sup>INK4A</sup> is up-regulated in RAS-induced colonies which resemble follicular adenomas. Affymetrix microarrays revealed that many interferon-stimulated genes (ISGs) are also up-regulated in these colonies. I hypothesised that p16 expression would be induced in follicular adenomas and lost in follicular cancers, consistent with their escape from growth control, and that ISG expression (HLA-DR, PKR, MxA) would be induced in follicular adenomas. I tested these hypotheses using immunohistochemistry, and correlated p16 expression with cyclin D1 and p21 expression to further investigate growth control.

My original research demonstrates that p16 is expressed in adenomas, and surprisingly up-regulated in well-differentiated cancers. Loss of expression was only seen in poorly-differentiated carcinomas. Cyclin D1 expression increased during the transition from a benign to a malignant tumour, whereas p21 protein was expressed at a lower level in both adenomas and carcinomas. Unexpectedly, ISGS were not up-regulated in either the adenomas or carcinomas, but were expressed in some papillary carcinomas. PKR expression was positively correlated with p16 expression.

I speculate that there must be two or more growth inhibitory pathways involved in thyroid tumorigenesis, one of which involves p16, and both must be inactivated for progression to a more aggressive phenotype. The cyclin D1 result is explained as a result of growth stimulation during tumorigenesis, whereas the basis and implication of p21 expression is uncertain. Thyroid cancers are unusual because the majority are slow-growing yet potentially fatal despite continued p16 expression. Further work is needed to elucidate the nature of the additional pathways controlling tumour growth, which will improve our understanding of thyroid tumorigenesis, and may potentially lead to the development of novel treatment strategies.

## **ACKNOWLEDGEMENTS**

The author wishes to acknowledge the following people:-

Chris von Ruhland and the late Jeff Newman for showing me how to perform immunohistochemistry, and Ruth Pitman for cutting tissue sections.

Nigel Garrahan for showing me how to photograph my slides and create montages of my photographs.

Jane Bond for growing Ori3 and K1 cells for me to process into formalin-fixed cell pellets.

David-Scott Coombes for his help in designing the surgical consent form and providing me with thyroid tissue.

Professor David Wynford-Thomas for supervising my research project.

Finally, in no particular order, I would like to thank Alex, Michelle, Jane, Julia, Ceryn, Rebecca, Amy, Daniel, Megan, Peter, Matthew, Beth, Zara, DK, Colin, Kaye, Julie and Lawrence for their much-needed support, laughter and cakes.

**This work is dedicated to**

**my parents,**

**Keith and Isobel Ball**

## CONTENTS

<b>CHAPTER 1 INTRODUCTION .....</b>	<b>1</b>
<b>1.1 The thyroid gland .....</b>	<b>2</b>
<b>1.2 The pathology of thyroid cancer.....</b>	<b>4</b>
1.2.1 Follicular adenoma .....	4
1.2.2 Atypical adenoma .....	5
1.2.3 Papillary carcinoma .....	5
1.2.4 Follicular carcinoma.....	6
1.2.5 Insular carcinoma .....	7
1.2.6 Anaplastic carcinoma .....	8
<b>1.3 Diagnosis and treatment of thyroid cancer .....</b>	<b>9</b>
<b>1.4 Tumorigenesis.....</b>	<b>11</b>
<b>1.5 RET / RAS / BRAF / MAPK pathway.....</b>	<b>14</b>
1.5.1 RAS .....	15
1.5.2 BRAF .....	18
1.5.3 RET .....	20
<b>1.6 PAX8-PPAR<math>\gamma</math>.....</b>	<b>22</b>
<b>1.7 MET .....</b>	<b>24</b>
<b>1.8 PI3K / AKT pathway .....</b>	<b>25</b>
<b>1.9 The cell cycle .....</b>	<b>27</b>
1.9.1 p16 .....	30
1.9.2 p21 .....	33
<b>1.10 p53 pathway.....</b>	<b>34</b>
<b>1.11 <math>\beta</math>-Catenin.....</b>	<b>36</b>
<b>1.12 Overview of thyroid tumorigenesis .....</b>	<b>37</b>
<b>1.13 Thyrocyte tumour model .....</b>	<b>40</b>

<b>1.14 Aims and Hypothesis .....</b>	<b>44</b>
<b>CHAPTER 2 METHODS.....</b>	<b>47</b>
<b>2.1 Tissue samples .....</b>	<b>47</b>
2.1.1 Archived thyroid tissue from Cardiff.....	47
2.1.2 Acquisition of new Cardiff thyroid tissue .....	47
2.1.3 Acquisition of French thyroid tissue .....	48
<b>2.2 Preparation of tissue sections .....</b>	<b>49</b>
<b>2.3 Preparation of cultured cells for p16 immunohistochemistry .....</b>	<b>50</b>
<b>2.4 Immunohistochemistry protocol .....</b>	<b>52</b>
2.4.1 Antibody selection .....	52
2.4.2 Rehydration of slides .....	55
2.4.2.1 Manual technique .....	55
2.4.2.2 Automatic technique .....	55
2.4.3 Heat-Mediated Antigen Retrieval (HMAR).....	55
2.4.4 Pre-treatment with a peroxidase-blocking solution .....	56
2.4.5 Immunohistochemistry protocols .....	56
2.4.5.1 Manual technique .....	56
2.4.5.2 Automatic technique .....	57
2.4.6 Dehydration of slides and haematoxylin counter-staining.....	58
2.4.6.1 Manual technique .....	58
2.4.6.2 Automatic technique .....	58
<b>2.5 Scoring of antibody expression .....</b>	<b>59</b>
2.5.1 p16 .....	59
2.5.2 MCM2, cyclin A, p21.....	62
2.5.3 cyclin D1 .....	62

2.5.4	HLA-DR, PKR, MxA .....	63
<b>2.6</b>	<b>Statistical analysis .....</b>	<b>63</b>
<b>2.7</b>	<b>Photography .....</b>	<b>63</b>
<b>2.8</b>	<b>Scale bars .....</b>	<b>63</b>

<b>CHAPTER 3 AN IMMUNOHISTOCHEMICAL STUDY OF P16<sup>INK4A</sup></b>		
<b>EXPRESSION IN MULTISTEP THYROID TUMORIGENESIS .....</b>		<b>64</b>
<b>3.1</b>	<b>Introduction .....</b>	<b>64</b>
<b>3.2</b>	<b>Method .....</b>	<b>68</b>
3.2.1	Immunohistochemistry .....	68
3.2.2	Scoring of slides .....	68
3.2.2.1	p16 analysis .....	69
3.2.2.2	Cyclin A and MCM2 analysis .....	69
3.2.3	Statistical analysis .....	69
<b>3.3</b>	<b>Results .....</b>	<b>70</b>
3.3.1	anti-p16 antibody validation .....	70
3.3.2	Expression of p16.....	74
3.3.2.1	Normal thyroid .....	74
3.3.2.2	Follicular adenoma .....	74
3.3.2.3	Atypical adenoma .....	77
3.3.2.4	Follicular carcinoma.....	77
3.3.2.5	Papillary carcinoma.....	79
3.3.2.6	Insular carcinoma.....	79
3.3.2.7	Anaplastic carcinoma.....	84
3.3.3	MCM2 expression .....	88
3.3.3.1	Normal thyroid .....	88

3.3.3.2	Follicular adenoma .....	88
3.3.3.3	Atypical adenoma .....	88
3.3.3.4	Follicular carcinoma .....	88
3.3.3.5	Papillary carcinoma .....	89
3.3.3.6	Insular carcinoma .....	89
3.3.4	Cyclin A expression .....	92
3.3.4.1	Normal thyroid .....	92
3.3.4.2	Follicular adenoma .....	92
3.3.4.3	Atypical adenoma .....	92
3.3.4.4	Follicular carcinoma .....	92
3.3.4.5	Papillary carcinoma .....	93
3.3.4.6	Insular carcinoma .....	93
3.3.5	Co-expression of MCM2 and cyclin A .....	98
3.3.6	Co-expression of p16 and MCM2 .....	103
3.3.7	Co-expression of p16 and cyclin A .....	108
<b>3.4</b>	<b>Discussion .....</b>	<b>113</b>
<b>3.5</b>	<b>Conclusions .....</b>	<b>133</b>
<b>3.6</b>	<b>Further work .....</b>	<b>134</b>

<b>CHAPTER 4 AN IMMUNOHISTOCHEMICAL STUDY OF P21<sup>WAF1/Cip1</sup> AND CYCLIN D1 EXPRESSION IN MULTISTEP THYROID TUMORIGENESIS</b>	<b>135</b>
<b>4.1 Introduction .....</b>	<b>135</b>
<b>4.2 Method .....</b>	<b>139</b>
4.2.1 Immunohistochemistry.....	139
4.2.2 Scoring of slides .....	139
4.2.2.1 cyclin D1 .....	139



4.2.2.2	p21.....	140
<b>4.3</b>	<b>Results .....</b>	<b>141</b>
4.3.1	Expression of cyclin D1 .....	142
4.3.2	Expression of p21 .....	148
4.3.3	Co-expression of cyclin D1and p21 .....	154
4.3.4	Co-expression of cyclin D1and p16 .....	157
4.3.5	Co-expression of p21 and p16.....	159
4.3.6	Co-expression of cyclin D1 and MCM2 .....	162
4.3.7	Co-expression of cyclin D1 and cyclin A.....	164
4.3.8	Co-expression of p21 and MCM2.....	166
4.3.9	Co-expression of p21 and cyclin A .....	168
<b>4.4</b>	<b>Discussion .....</b>	<b>170</b>
<b>4.5</b>	<b>Conclusions .....</b>	<b>185</b>
<b>4.6</b>	<b>Further work .....</b>	<b>186</b>

## **CHAPTER 5 AN IMMUNOHISTOCHEMICAL STUDY OF INTERFERON-STIMULATED GENE EXPRESSION IN MULTISTEP THYROID**

<b>TUMORIGENESIS .....</b>	<b>187</b>
<b>5.1 Introduction .....</b>	<b>187</b>
<b>5.2 Method .....</b>	<b>191</b>
5.2.1 Immunohistochemistry.....	191
5.2.2 Scoring of slides .....	192
<b>5.3 Results .....</b>	<b>193</b>
5.3.1 anti-HLA-DR, PKR, MxA antibody validation .....	193
5.3.2 Expression of HLA-DR .....	193
5.3.3 Expression of PKR .....	198

5.3.4	Expression of MxA.....	201
5.3.5	Co-expression of p16 with HLA-DR, PKR, MxA .....	204
<b>5.4</b>	<b>Discussion .....</b>	<b>207</b>
<b>5.5</b>	<b>Conclusions .....</b>	<b>224</b>
<b>5.6</b>	<b>Further work .....</b>	<b>225</b>
<b>CHAPTER 6 OVERALL CONCLUSIONS .....</b>		<b>226</b>
<b>PUBLICATIONS ARISING FROM THIS WORK .....</b>		<b>244</b>
<b>APPENDIX I</b>	<b>Manufacturers and suppliers.....</b>	<b>245</b>
<b>APPENDIX II</b>	<b>Solutions .....</b>	<b>248</b>
<b>APPENDIX III</b>	<b>DAKO Autostainer set-up.....</b>	<b>249</b>
<b>APPENDIX IV</b>	<b>Tissue section and TMA results .....</b>	<b>251</b>
<b>REFERENCES .....</b>		<b>256</b>

## LIST OF CHARTS

<b>Chart 3.1</b>	Bar chart showing heterogeneity of p16 staining in TMA cores .	86
<b>Chart 3.2</b>	Box plot chart showing p16 expression in TMA cores .....	87
<b>Chart 3.3</b>	Box plot chart showing MCM2 expression in TMA cores .....	91
<b>Chart 3.4</b>	Box plot chart showing cyclin A expression in TMA cores .....	96
<b>Chart 3.5</b>	Scatter showing MCM2 and cyclin A expression in normal thyroid TMA cores .....	100
<b>Chart 3.6</b>	Scatter chart showing MCM2 and cyclin A expression in atypical adenoma TMA cores .....	100
<b>Chart 3.7</b>	Scatter chart showing MCM2 and cyclin A expression in follicular adenoma TMA cores .....	101
<b>Chart 3.8</b>	Scatter chart showing MCM2 and cyclin A expression in follicular carcinoma TMA cores .....	101
<b>Chart 3.9</b>	Scatter chart showing MCM2 and cyclin A expression in papillary carcinoma TMA cores .....	102
<b>Chart 3.10</b>	Scatter chart showing MCM2 and cyclin A expression in insular carcinoma TMA cores .....	102
<b>Chart 3.11</b>	Scatter showing p16 and MCM2 expression in normal thyroid TMA cores .....	105
<b>Chart 3.12</b>	Scatter chart showing p16 and MCM2 expression in atypical adenoma TMA cores .....	105
<b>Chart 3.13</b>	Scatter chart showing p16 and MCM2 expression in follicular adenoma TMA cores and tissue sections .....	106
<b>Chart 3.14</b>	Scatter chart showing p16 and MCM2 expression in follicular carcinoma TMA cores and tissue sections .....	106
<b>Chart 3.15</b>	Scatter chart showing p16 and MCM2 expression in papillary carcinoma TMA cores and tissue sections .....	107
<b>Chart 3.16</b>	Scatter chart showing p16 and cyclin A expression in insular carcinoma TMA cores .....	107

<b>Chart 3.17</b>	Scatter showing p16 and cyclin A expression in normal thyroid TMA cores .....	110
<b>Chart 3.18</b>	Scatter chart showing p16 and cyclin A expression in atypical adenoma TMA cores .....	110
<b>Chart 3.19</b>	Scatter chart showing p16 and cyclin A expression in follicular adenoma TMA cores and tissue sections .....	111
<b>Chart 3.20</b>	Scatter chart showing p16 and cyclin A expression in follicular carcinoma TMA cores and tissue sections .....	111
<b>Chart 3.21</b>	Scatter chart showing p16 and cyclin A expression in papillary carcinoma TMA cores and tissue sections .....	112
<b>Chart 3.22</b>	Scatter chart showing p16 and cyclin A expression in insular carcinoma TMA cores .....	112
<b>Chart 4.1</b>	Bar chart showing heterogeneity of cyclin D1 expression in follicular adenomas, follicular and papillary carcinomas .....	146
<b>Chart 4.2</b>	Boxplot showing cyclin D1 expression in follicular adenomas, follicular and papillary carcinomas .....	147
<b>Chart 4.3</b>	Bar chart showing heterogeneity of p21 expression in follicular adenomas, follicular and papillary carcinomas .....	152
<b>Chart 4.4</b>	Boxplot showing p21 expression in follicular adenomas, follicular and papillary carcinomas .....	153
<b>Chart 4.5</b>	Scatter chart showing cyclin D1 and p16 expression in follicular adenomas .....	156
<b>Chart 4.6</b>	Scatter chart showing cyclin D1 and p21 expression in follicular carcinomas .....	156
<b>Chart 4.7</b>	Scatter chart showing cyclin D1 and p21 expression in papillary carcinomas .....	156
<b>Chart 4.8</b>	Scatter chart showing cyclin D1 and p16 expression in follicular adenomas .....	158
<b>Chart 4.9</b>	Scatter chart showing cyclin D1 and p16 expression in follicular carcinomas .....	158

<b>Chart 4.10</b>	Scatter chart showing cyclin D1 and p16 expression in papillary carcinomas .....	158
<b>Chart 4.11</b>	Scatter chart showing p21 and p16 expression in follicular adenomas .....	160
<b>Chart 4.12</b>	Scatter chart showing p21 and p16 expression in follicular carcinomas .....	160
<b>Chart 4.13</b>	Scatter chart showing p21 and p16 expression in papillary carcinomas .....	160
<b>Chart 4.14</b>	Scatter chart showing cyclin D1 and MCM2 expression in follicular adenomas .....	163
<b>Chart 4.15</b>	Scatter chart showing cyclin D1 and MCM2 expression in follicular carcinomas .....	163
<b>Chart 4.16</b>	Scatter chart showing cyclin D1 and MCM2 expression in papillary carcinomas .....	163
<b>Chart 4.17</b>	Scatter chart showing cyclin D1 and cyclin A expression in follicular adenomas .....	165
<b>Chart 4.18</b>	Scatter chart showing cyclin D1 and cyclin A expression in follicular carcinomas .....	165
<b>Chart 4.19</b>	Scatter chart showing cyclin D1 and cyclin A expression in papillary carcinomas .....	165
<b>Chart 4.20</b>	Scatter chart showing p21 and MCM2 expression in follicular adenomas .....	167
<b>Chart 4.21</b>	Scatter chart showing p21 and MCM2 expression in follicular carcinomas .....	167
<b>Chart 4.22</b>	Scatter chart showing p21 and MCM2 expression in papillary carcinomas .....	167
<b>Chart 4.23</b>	Scatter chart showing p21 and cyclin A expression in follicular adenomas .....	169
<b>Chart 4.24</b>	Scatter chart showing p21 and cyclin A expression in follicular carcinomas .....	169

**Chart 4.25** Scatter chart showing p21 and cyclin A expression in papillary carcinomas ..... 169

## LIST OF FIGURES

<b>Figure 3.1</b>	Immunohistochemical staining of Ori 3 cell pellet with anti-p16 antibody and antibody diluent.....	72
<b>Figure 3.2</b>	Immunohistochemical staining of K1 cell pellet with anti-p16 antibody and antibody diluent .....	72
<b>Figure 3.3</b>	Immunohistochemical staining of a cervical carcinoma with anti-p16 antibody .....	73
<b>Figure 3.4</b>	Degradation of intensity of p16 staining of a cervical carcinoma over time .....	73
<b>Figure 3.5</b>	Immunohistochemical staining of two normal thyroid tissue sections and two TMA cores with anti-p16 antibody .....	75
<b>Figure 3.6</b>	Immunohistochemical staining of two follicular adenoma tissue sections with anti-p16 antibody .....	76
<b>Figure 3.7</b>	Immunohistochemical staining of two follicular adenoma TMA cores with anti-p16 antibody .....	76
<b>Figure 3.8</b>	Immunohistochemical staining of an atypical adenoma TMA core with anti-p16 antibody .....	78
<b>Figure 3.9</b>	Immunohistochemical staining of two follicular carcinoma tissue and two TMA cores with anti-p16 antibody .....	78
<b>Figure 3.10</b>	Immunohistochemical staining of two micro-papillary carcinomas with anti-p16 antibody .....	80
<b>Figure 3.11</b>	Immunohistochemical staining of two micro-papillary carcinomas with anti-cyclin A antibody .....	80
<b>Figure 3.12</b>	Immunohistochemical staining of one papillary carcinoma tissue section and one TMA core with anti-p16 antibody .....	81
<b>Figure 3.13</b>	Immunohistochemical staining of a metastatic deposit from a papillary carcinoma with anti-p16 and anti-cyclin A antibody ....	81
<b>Figure 3.14</b>	Immunohistochemical staining of three insular carcinoma tissue sections with anti-p16 and anti-cyclin A antibody .....	82

- Figure 3.15** Immunohistochemical staining with anti-p16, anti-MCM2 and anti-cyclin A antibody of a representative follicular adenoma, atypical adenoma, follicular carcinoma, papillary carcinoma, p16 +ve and p16 –ve insular carcinoma TMA core ..... 83
- Figure 3.16** Immunohistochemical staining of an anaplastic cancer derived from a papillary carcinoma with anti-p16 antibody demonstrating the down-regulation of p16 expression in the anaplastic carcinoma ..... 85
- Figure 3.17** Immunohistochemical staining of two anaplastic cancers with anti-p16 antibody ..... 85
- Figure 3.18** Immunohistochemical staining of normal thyroid, follicular adenoma, follicular carcinoma and papillary carcinoma tissue sections with anti-MCM2 antibody ..... 90
- Figure 3.19** Immunohistochemical staining of normal thyroid, follicular adenoma, follicular carcinoma and papillary carcinoma tissue sections with anti-cyclin A antibody ..... 95
- Figure 4.1** Immunohistochemical staining of two normal thyroid tissue sections with anti-cyclin D1 antibody ..... 144
- Figure 4.2** Immunohistochemical staining of two follicular adenoma tissue sections with anti-cyclin D1 antibody ..... 144
- Figure 4.3** Immunohistochemical staining of two follicular carcinoma tissue sections with anti-cyclin D1 antibody ..... 145
- Figure 4.4** Immunohistochemical staining of two papillary carcinoma tissue sections with anti-cyclin D1 antibody ..... 145
- Figure 4.5** Immunohistochemical staining of two normal thyroid tissue sections with anti-p21 antibody ..... 150
- Figure 4.6** Immunohistochemical staining of two follicular adenoma tissue sections with anti-p21 antibody ..... 150
- Figure 4.7** Immunohistochemical staining of two follicular carcinoma tissue sections with anti-p21 antibody ..... 151



<b>Figure 4.8</b>	Immunohistochemical staining of two papillary carcinoma tissue sections with anti-p21 antibody .....	151
<b>Figure 4.9</b>	Immunohistochemical staining of a follicular adenoma, follicular carcinoma and a papillary carcinoma with anti-p16, anti-cyclin D1 and anti-p21 antibody .....	155
<b>Figure 5.1</b>	Immunohistochemical staining of normal tonsil tissue with anti-HLA-DR, anti-PKR and anti-MxA antibody .....	195
<b>Figure 5.2</b>	Immunohistochemical staining of normal tonsil tissue with anti-prolactin antibody and antibody diluent .....	195
<b>Figure 5.3</b>	Immunohistochemical staining of normal thyroid tissue with anti-HLA-DR antibody .....	196
<b>Figure 5.4</b>	Immunohistochemical staining of two follicular adenomas with anti-HLA-DR antibody .....	196
<b>Figure 5.5</b>	Immunohistochemical staining of two follicular carcinomas with anti-HLA-DR antibody .....	197
<b>Figure 5.6</b>	Immunohistochemical staining of two papillary carcinomas with anti-HLA-DR antibody .....	197
<b>Figure 5.7</b>	Immunohistochemical staining of normal thyroid tissue with anti-PKR antibody .....	199
<b>Figure 5.8</b>	Immunohistochemical staining of two follicular adenomas with anti-PKR antibody .....	199
<b>Figure 5.9</b>	Immunohistochemical staining of two follicular carcinomas with anti-PKR antibody .....	200
<b>Figure 5.10</b>	Immunohistochemical staining of two papillary carcinomas with anti-PKR antibody .....	200
<b>Figure 5.11</b>	Immunohistochemical staining of normal thyroid tissue with anti-MxA antibody .....	202
<b>Figure 5.12</b>	Immunohistochemical staining of two follicular adenomas with anti-MxA antibody .....	202
<b>Figure 5.13</b>	Immunohistochemical staining of two follicular carcinomas with anti-MxA antibody .....	203

- Figure 5.14** Immunohistochemical staining of two papillary carcinomas with anti- MxA antibody ..... 203
- Figure 5.15** Immunohistochemical staining of a follicular carcinoma with anti- HLA-DR, anti-PKR and anti-MxA antibody ..... 205
- Figure 5.16** Immunohistochemical staining of a papillary carcinoma with anti- HLA-DR, anti-PKR and anti-MxA antibody ..... 205

## LIST OF TABLES

<b>Table 2.1</b>	p16 antibody literature search .....	53
<b>Table 2.2</b>	Manufacturers' details of antibodies used .....	54
<b>Table 2.3</b>	Immunohistochemistry protocols .....	54
<b>Table 3.1</b>	p16 I.D. results for TMAs and tissue sections .....	97
<b>Table 3.2</b>	MCM2 L.I. results for TMAs and tissue sections .....	97
<b>Table 3.3</b>	cyclin A L.I. results for TMAs and tissue sections .....	97
<b>Table 4.1</b>	cyclin D1, p21 and p16 results for follicular adenomas.....	161
<b>Table 4.2</b>	cyclin D1, p21 and p16 results for follicular carcinomas.....	161
<b>Table 4.3</b>	cyclin D1, p21 and p16 results for papillary carcinomas.....	161
<b>Table 5.1</b>	HLA-DR, PKR, MxA and p16 results for follicular adenomas .	206
<b>Table 5.2</b>	HLA-DR, PKR, MxA and p16 results for follicular carcinomas	206
<b>Table 5.3</b>	HLA-DR, PKR, MxA and p16 results for papillary carcinomas	206
<b>Table IV.1</b>	Tissue section results for follicular adenomas .....	251
<b>Table IV.2</b>	Tissue section results for follicular carcinomas .....	251
<b>Table IV.3</b>	Tissue section results for papillary carcinomas .....	252
<b>Table IV.4</b>	TMA results for follicular adenomas .....	252
<b>Table IV.5</b>	TMA results for atypical adenomas .....	253
<b>Table IV.6</b>	TMA results for follicular carcinomas .....	253
<b>Table IV.7</b>	TMA results for papillary carcinomas .....	254
<b>Table IV.8</b>	TMA results for insular carcinomas .....	255

## LIST OF ABBREVIATIONS

AA	Atypical adenoma
APC	Adenomatous polyposis coli
CDK	Cyclin dependent kinase
CKI	Cyclin dependent kinase inhibitor
DAB	Diaminobenzidine
DNA	Deoxyribonucleic acid
DWT	David Wynford-Thomas (author's supervisor)
EB	Elizabeth Ball (author)
EDTA	ethylenediaminetetraacetic acid
eIF2- $\alpha$	Eukaryotic initiation factor 2- $\alpha$
ELISA	Enzyme-linked immunosorbent assay
EMT	Epithelial-mesenchymal transition
ERK	Extracellular signal-regulated kinase
FA	Follicular adenoma
FC	Follicular carcinoma
FNAC	Fine needle aspiration cytology
G	Gap phase
HGF	Hepatocyte growth factor
HMAR	Heat-mediated antigen retrieval
HPV	Human papilloma virus
IC	Insular carcinoma
ID	Intensity distribution
IFN	Interferon
Ig	Antibody
INK	Inhibit cdk4
IQR	Interquartile range
ISG	Interferon-stimulated gene

<b>kDa</b>	<b>kiloDalton</b>
<b>LI</b>	<b>Labelling Index</b>
<b>M</b>	<b>Mitosis phase</b>
<b>MAPK</b>	<b>Mitogen-Activated Phosphokinase</b>
<b>MCM</b>	<b>Minichromosome maintenance protein</b>
<b>MHC</b>	<b>Molecular histocompatibility complex</b>
<b>mRNA</b>	<b>Messenger ribonucleic acid</b>
<b>O/N</b>	<b>Overnight</b>
<b>PBS</b>	<b>Phosphate buffered saline</b>
<b>PC</b>	<b>Papillary carcinoma</b>
<b>pd</b>	<b>Population doubling</b>
<b>PPAR<math>\gamma</math></b>	<b>Peroxisome proliferators-activator receptor <math>\gamma</math></b>
<b>PTC</b>	<b>Papillary carcinoma</b>
<b>PTEN</b>	<b>Phosphate and tensin homologue</b>
<b>Rb</b>	<b>Retinoblastoma</b>
<b>RET</b>	<b>Rearranged during transfection</b>
<b>RNA</b>	<b>Ribonucleic acid</b>
<b>RT</b>	<b>Room temperature</b>
<b>S</b>	<b>Synthesis phase</b>
<b>SE</b>	<b>Standard error</b>
<b>siRNA</b>	<b>Small interfering ribonucleic acid</b>
<b>STAT-1</b>	<b>Signal transducer and activator of transcription-1</b>
<b>TCC</b>	<b>Transitional cell carcinoma</b>
<b>TMA</b>	<b>Tissue microarray</b>

## Chapter 1

### INTRODUCTION

Thyroid cancer is the commonest endocrine malignancy (Aldred et al., 2004), and is within the top twenty most common cancers for women in the United Kingdom. However it is rare in comparison to other tumours, and accounts for less than 1% of all cancers. Each year there are approximately 1,200 female and 390 male cases diagnosed each year, therefore thyroid cancer is three times more common in women. The age-standardised incidence rates for thyroid cancer are around two cases per 100,000 population, although the annual incidence has increased by 50% in the United States over the last 25 years (Hundahl et al., 1998). Thyroid cancer accounts for about 300 deaths per year and 64% of endocrine cancer deaths per year (Mallick and Charalambous, 2004), with a five-year survival rate in the United Kingdom of 65-75%. The ten-year survival rate in the United States is better by 20% (85-93%) (Kendall-Taylor, 2002). Thyroid cancer can affect all ages, but the highest incidence occurs in people aged between 20 and 55 years. This is different from most other malignancies, which become more prevalent with advancing age.

There is a geographic variation in thyroid cancer prevalence, with the Kuwaiti, Vietnamese and Filipino populations having a much higher incidence than that in the UK and America (Farid et al., 1994). There is an increased prevalence of follicular thyroid cancer in areas of iodine deficiency or a high incidence of

endemic goitre (Franceschi et al., 1991), whereas papillary carcinoma is more prevalent in iodine-sufficient regions. There is also a strong link between thyroid cancer and external radiation, for example from X-rays of the neck. Papillary carcinoma is associated with radiation exposure due to a nuclear fall-out, as seen in the survivors of the atomic bombs at Nagasaki, and the Chernobyl nuclear accident (Nikiforov, 2006).

There is also a genetic component to the development of follicular cancer, because a positive family history of thyroid cancer increases the risk of developing thyroid cancer by 3.2 – 6.2-fold (Hemminki et al., 2005). Finally, there are several tumour syndromes that predispose to thyroid carcinoma, including familial polyposis coli, Cowden syndrome (Sogol et al., 1983) and Gardner's syndrome (Thompson et al., 1983), the scope of which will not be covered in this work.

## **1.1 The thyroid gland**

Embryologically, the thyroid forms from an invagination in the floor of the pharynx between the first and second pharyngeal pouches, and this tissue migrates inferiorly to reach the final position in the neck, being dragged by the developing heart. The midline thyroid tissue fuses with tissues derived from the fourth and fifth branchial clefts, which combine to form the lateral lobes. These clefts bring neuroendocrine cells from the ultimobranchial body that form parafollicular (C) cells.

The thyroid gland is the largest human endocrine organ, and it regulates metabolism through the production of thyroid hormones. The thyroid gland consists of two lobes which lay either side of the trachea, and are joined by an isthmus. The lobes extend superiorly and inferiorly from the isthmus, with a butterfly appearance. Each lobe is covered by a fibrous capsule that sends septae into the gland, dividing it into lobules, and each lobule is further divided into 30-40 follicles. The follicle is a structural and a functional unit, consisting of a single layer of cells arranged around a gelatinous core of colloid, a proteinaceous material. The follicular thyroid cells are cuboidal, and their apex has a microvillous structure which interdigitates with the colloid, to facilitate the passage of molecules between the cell and the colloid.

The main constituent of the colloid is thyroglobulin, a 660kDa protein that is synthesised in the follicular cells and secreted into the colloid together with iodine. The cells absorb thyroglobulin back from the colloid and secrete the thyroid hormones tri-iodothyronine and thyroxine directly into the bloodstream. These hormones are involved in the regulation of the basal metabolic rate and their secretion is adjusted in response to alterations in the body's energy need, caloric supply and thermal environment. Each follicle is surrounded by a basement membrane, between which are the neuroendocrine parafollicular cells (C-cells) that secrete calcitonin, a peptide hormone necessary for calcium metabolism.

The thyroid gland epithelium is a "conditional renewal" epithelium. It normally has a very low proliferative rate, and on average a thyroid cell will turn over no more than five times throughout adulthood. However, the epithelium is



capable of a great increase in proliferation in response to an appropriate stimulus.

## **1.2 The pathology of thyroid cancer**

The vast majority of thyroid cancers are derived from the follicular cells, and can be broadly divided into two categories, benign (follicular and atypical) adenomas and malignant (follicular, papillary, insular and anaplastic) carcinomas, representing a multi-stage model of epithelial tumorigenesis with a low frequency of malignant progression (Williams, 1979; Lemoine et al., 1989). The remainder of the thyroid tumours are derived from the neuroendocrine C-cells, producing medullary thyroid cancers, which will not be covered in this work.

### **1.2.1 Follicular adenoma**

A follicular adenoma is an encapsulated, solitary benign thyroid neoplasm derived from the follicular cells. It lacks the characteristic invasiveness of follicular carcinomas, and the typical nuclear features of papillary carcinomas (Hedinger et al., 1989). By definition, capsular and vascular invasion are absent. The neoplastic cells are demarcated from the adjacent parenchyma by a well-defined, intact capsule, and the centre of the adenoma may show areas of haemorrhage and cystic changes. Thyroid adenomas can be divided on the basis of their microscopic appearance into two major groups: microfollicular adenomas which have very compact follicles and very little colloid, and macrofollicular adenomas, but these sub-divisions have little clinical significance.

### 1.2.2 Atypical adenoma

In 1950, Zimmerman et al., (1950) used the term 'malignant adenoma' to describe thyroid tumours that exhibited cellular pleomorphism and mitoses without vascular or capsular invasion. Hazard and Kenyon in 1954 used the term 'atypical adenoma' to describe thyroid adenomas with a more solid architecture than follicular adenomas, and with no evidence of invasion of the surrounding capsule or blood vessels. Atypical adenomas resemble thyroid carcinomas but do not have the invasive signs characteristic of follicular carcinoma or the clear overlapping nuclei characteristic of papillary carcinoma (Lang et al., 1980), and this suggests that they can precede either tumour type (Vasko et al., 2004a). The nature of these adenomas is unclear; however Tzen et al., (2003) suggested that atypical adenomas may represent a pre-invasive malignancy of the thyroid, as a precursor of anaplastic carcinoma.

### 1.2.3 Papillary carcinoma

This is the commonest thyroid tumour and has a peak incidence in the third and fourth decades. It occurs three times more frequently in women and accounts for 60-70% of all thyroid cancers in adults. There is an increased incidence in iodine-rich areas and previous neck irradiation, particularly in young people, may predispose to papillary thyroid cancer. This is an indolent, slow-growing tumour with a good prognosis. Papillary tumours usually present as a solitary thyroid nodule, although they are often bilateral and multi-focal. The tumours range phenotypically from well- to poorly-differentiated and the cancers tend to be infiltrative and primarily metastasise to lymph nodes. Encapsulation is rare. Micro-papillary carcinomas are papillary tumours that are less than one centimetre in size, and although they are not clinically

obvious, they have the ability to metastasise to regional lymph nodes. They are extremely common, and occur in up to 30% of autopsies (Fink et al., 1996).

Microscopically, there is typically a mixture of papillary projections and follicular structures. They are characterised by a complex branching structure in which neoplastic cells cover the surfaces of the papillary cores. The cuboidal cells have pale abundant cytoplasm and intranuclear cytoplasmic inclusions, nuclear overlapping and grooves (Orphan Annie cells), and these features are diagnostic of papillary carcinoma. Areas of lymphocytic infiltration and even extensive lymphocytic thyroiditis are common. Furthermore, chronic lymphocytic thyroiditis may be a potential precursor for thyroid cancer (Gasbarri et al., 2004). This suggests that immunological factors might be involved in thyroid tumour progression (Kondo et al., 2006).

#### 1.2.4 Follicular carcinoma

This thyroid tumour is also three times as common in women, is rare in children and has a peak incidence in the fifth decade. It accounts for 25% of all thyroid cancers in adults. It is a slow-growing tumour and usually presents as a solitary thyroid nodule. Follicular thyroid cancers tend to invade locally and metastasise distantly via the blood stream. Lymphatic spread is usually a late phenomenon. There is a higher incidence in iodine-deficient areas, and it can also be induced by previous irradiation.

Most tumours are composed of fairly uniform cells forming small follicles, although this differentiation may be less apparent in the more aggressive stages. They are defined as malignant epithelial tumours with evidence of

follicular cell differentiation but lacking the diagnostic nuclear features of papillary thyroid cancer. Invasion of blood vessels or the capsule, apart from metastasis, is the only reliable criterion of malignancy, and the only distinguishing feature between a follicular adenoma and a follicular carcinoma. However, this invasion may be limited to microscopic foci and therefore extensive histological sampling is required for a diagnosis in less clear cut cases. Follicular cancers that are widely invasive have a significant morbidity and mortality. Since follicular adenoma is distinguished from follicular carcinoma by the absence of clear-cut capsular or vascular invasion, by definition, lesions intermediate between adenoma and carcinoma do not exist. However pre-invasive malignancy of the thyroid should exist from a biological standpoint.

#### 1.2.5 Insular carcinoma

Thyroid carcinomas derived from follicular cells have traditionally been classified into a well-differentiated, prognostically favourable group (the papillary and follicular carcinomas) and an undifferentiated, prognostically unfavourable group (anaplastic carcinomas) (Fadare and Sinard, 2002). Carcangiu et al., (1984), firmly established the category of poorly-differentiated 'insular' thyroid carcinomas, previously described by Sakamoto et al., (1983), which were believed to be intermediate in biology and morphology between the well-differentiated follicular and papillary cancers, and the undifferentiated anaplastic cancers. To date, more than 150 patients with insular thyroid cancer have been described in the literature (Carcangiu et al., 1984; Flynn et al., 1988; Papotti et al., 1993; Pilotti et al., 1997). The overall incidence of insular carcinoma is around 3%.

These insular tumours were characterised histologically by the formation of solid clusters of small, uniform cells arranged in small follicles with variable mitotic activity and frequent necrotic foci (Lam et al., 2000). In the currently accepted model of non-medullary thyroid carcinogenesis a morphologic and biologic spectrum connects the well-, poorly- and undifferentiated tumours and the insular and anaplastic carcinomas are believed to arise from their well-differentiated follicular and papillary counterparts. Concomitant areas of follicular and papillary thyroid carcinomas have been noted in both insular and anaplastic tumours, strengthening the theory that the well-differentiated carcinomas can progress to insular and then to anaplastic carcinoma by de-differentiation (Ito et al., 1992; Ito et al., 1993).

#### 1.2.6 Anaplastic carcinoma

Anaplastic carcinoma is one of the most aggressive human neoplasms and accounts for 2-5% of all thyroid cancers. It occurs predominantly in the frail, elderly population with a peak incidence at 60-70 years of age. The tumour is slightly more common in women and has a higher incidence in endemic goitre areas. The tumour presents as a bulky mass in the neck that rapidly infiltrates local structures and metastasises via both the blood stream and lymphatic system. Foci of either papillary or follicular differentiation may be present, suggesting an origin from a previously unrecognised or un-treated well-differentiated tumour (Harada et al., 1977), and this is most frequently papillary thyroid carcinoma (Wiseman et al., 2003).

Microscopically the tumour contains bizarre giant multi-nucleated cells, spindle cells or squamous cells, with evidence of epithelial differentiation. The

prognosis is very poor due to rapid local invasion of structures such as the trachea, producing respiratory obstruction, and there is no effective treatment (Lo et al., 1999). By the time diagnosis is made, the disease has spread in most patients beyond the area that can be attacked surgically, and most patients die within six months from diagnosis.

### **1.3 Diagnosis and treatment of thyroid cancer**

The majority of thyroid tumours present clinically as a thyroid nodule, which may be picked up incidentally during a routine clinical examination, or the patient complains of a growing lump in the neck. Rarely the patient complains of hoarseness in the neck or difficulty in breathing and swallowing, because of local invasion of the recurrent laryngeal nerve, the trachea or the oesophagus. Thyroid tumours are diagnosed with careful clinical assessment and fine needle aspiration cytology (FNAC), which was first used in the early 1950s (Soderstrom, 1952). In experienced hands, this technique can accurately diagnose colloid nodules, thyroiditis, papillary, medullary and anaplastic carcinoma, and lymphoma. However this technique cannot differentiate between benign and malignant follicular lesions (Lowhagen et al., 1979), since this distinction depends on the histological criteria of vascular and capsular invasion. Because of this limitation of FNAC, all suspicious follicular lesions are excised, and subsequently 80-90% of patients will have unnecessary surgery for a benign tumour.

The treatment objectives of thyroid carcinoma are to remove the primary tumour, reduce the incidence of local or distant recurrence, and treat

metastatic deposits. Papillary carcinomas are divided into low- and high-risk groups in terms of long-term survival and recurrence. The vast majority of patients have a total thyroidectomy, because papillary carcinoma is predominantly multifocal, and local tumour recurrence carries a high risk of death. A total thyroidectomy also removes the risk of anaplastic transformation. Patients presenting with a suspicious follicular lesion are initially treated with a thyroid lobectomy. If the lesion is an invasive carcinoma, then the patient proceeds to a completion thyroidectomy. For patients presenting with anaplastic carcinoma, there is no effective treatment and most will die within six months of the diagnosis.

Despite the development of a multimodality approach for treating thyroid cancer, combining surgery with radio-iodine ( $I^{131}$ ) therapy, chemotherapy, radiotherapy and thyroid hormone suppression, the survival rates of thyroid cancer have not significantly improved (Spitzweg and Morris, 2004). The identification of potential markers that could indicate invasive or aggressive behaviour, metastasis or a worse clinical prognosis will greatly benefit patients.

Thyroid carcinomas encompass a broad spectrum of clinical behaviour, and the diagnosis and treatment options are not always clear-cut. An improved understanding of the potential for an indolent follicular or papillary carcinoma to transform into a poorly- or undifferentiated phenotype may lead to a better use of our clinical resources, and improved treatment options for patients. This information can partly be gained through analysis of the molecular biology of multi-step thyroid tumorigenesis, and relating this data to tumour behaviour and patient survival. This may eventually lead to the development of better

strategies and treatments (surgical, genetic or pharmacological), to help combat thyroid cancer.

#### **1.4 Tumorigenesis**

It is widely accepted that tumours develop by a step-wise accumulation of genetic events which eventually result in a population of tumour cells that exhibit uncontrolled proliferation. Several pre-malignant lesions, such as dysplasia and hyperplasia have been detected in many human organs prior to the development of a fully invasive cancer. These lesions can either be caused by genetic or environmental factors, and subsequent genetic alterations in these cells may eventually lead to the development of an invasive tumour. These genetic events can be an accumulation of inherited and / or somatic mutations involving the genes controlling cellular differentiation and growth.

Hanahan and Weinberg in 2000 proposed a biological basis for tumorigenesis, and outlined “six essential alterations in cell physiology that collectively dictate malignant growth”. These six changes that a cell must acquire were;

- (i) Self-sufficiency in growth signals
- (ii) Insensitivity to growth inhibitory signals
- (iii) Evasion of programmed cell death
- (iv) Unlimited replicative potential
- (v) Sustained angiogenesis
- (vi) Tissue invasion and metastasis



The alterations can be divided into two broad categories, those resulting from activation of oncogenes, and those resulting from inactivation of tumour suppressor genes. At any given time a cell has three options, to remain static, to divide or to apoptose. Oncogenes and tumour suppressor genes generate and interpret these intra- and extra-cellular signals to ensure a cell makes the right choice.

In a normal cell, proto-oncogenes encode for proteins which have a role in the regulation of cell differentiation and growth. These genes, which are normally silent, can be activated by chromosomal translocations or mutations, and this leads to uncontrolled growth and neoplasia. Oncogenes can be classified according to their function into the following groups – growth factors, growth factor receptors, transducers and nuclear factors (Wynford-Thomas, 1991). Generally the activation of one oncogene is not sufficient to produce malignant transformation, and a step-wise approach is needed, with the accumulation of further mutations of oncogenes involved in cellular growth pathways.

In addition to these positive genetic factors, tumorigenesis frequently involves the inactivation of tumour suppressor genes. The first tumour suppressor gene demonstrated was the Rb gene, which is implicated in the development of the hereditary retinoblastoma tumour. Children with bilateral tumours fitted with a one-mutation model, and children with a unilateral tumour fitted with a two-mutation model, implying that those children with bilateral tumours had already inherited a mutation in one of the Rb alleles (Knudson, 1971). The Rb gene has a fundamental role in cell cycle progression and will be reviewed later. The roles of tumour suppressor genes can be divided into two broad groups,

the “gatekeepers” and the “caretakers” (Kinzler and Vogelstein, 1997). Loss of a gatekeeper gene (Rb) causes deregulation of the cell cycle and uncontrolled cell proliferation, whilst loss of a caretaker gene (p53) leads to genetic instability and the acquisition of genetic mutations. Tumour suppressor genes can be altered by deletions (either homozygous or hemizygous), mutations (for example non-sense and frame-shift) and by methylation of CpG islands at promoter sequences.

Thyroid tumours represent an ideal model in which to study the molecular mechanism of tumorigenesis, as they comprise a broad spectrum of well-defined phenotypes. These include microscopic papillary carcinomas that are discovered incidentally, benign follicular adenomas, slow-growing and non-metastatic follicular and papillary carcinomas, which can also give rise to local and distant metastases with increased de-differentiation, and finally the very aggressive undifferentiated anaplastic carcinomas. Furthermore, most thyroid tumours are clonal, arising from a single precursor cell that has somehow gained a growth advantage over the other thyroid cells through genetic mutations (Namba et al., 1990a).

The genetic events that have been previously identified in thyroid carcinomas indicate that there are several cumulative alterations involved in the initiation, progression and de-differentiation of these tumours. The follicular adenomas and carcinomas have a high prevalence of loss of heterozygosity involving multiple chromosomal regions, and are frequently aneuploidal tumours. This contrasts with papillary carcinomas, which show less frequent loss of heterozygosity, and are diploid or near-diploid, and implies that the two types

of follicular-cell derived tumours arise from different molecular pathways. These genetic alterations can be sub-divided in several ways, either as alterations in oncogenes and tumour suppressor genes, or on the basis of the pathways affected by the genetic alterations. I will now review the major genetic alterations known to occur in thyroid cancer affecting the RET/RAS/BRAF/MAPK pathway, the PI3/AKT pathway, the control of the cell cycle via the pRb pathway, and alternative cellular pathways.

### **1.5 RET/RAS/BRAF/MAPK pathway**

The molecular events involved in the tumorigenesis of follicular and papillary cancer are still incompletely understood despite several recent advancements, as reviewed by Moretti et al., 2000, Bongarzone and Pierotti, 2003, and Segev et al., 2003. However, activating mutations of several genes in the RET/RAS/BRAF/mitogen-activated kinase (MAPK) / extracellular signal-regulated kinase (ERK) signal transduction pathway have been identified in both follicular and papillary carcinomas (Xing et al., 2005).

The RET/RAS/BRAF/MAPK pathway regulates cell proliferation, survival and differentiation in response to changing environmental conditions. The pathway is activated when peptide growth factors interact with receptor tyrosine kinases in the cell membrane, bringing about a series of events that lead to activation of several intracellular signalling pathways (Pawson, 2002). Stimulated receptor kinases activate RAS, a small G protein embedded in the inner leaflet of the plasma membrane. Activated RAS recruits the protein kinase RAF to the plasma membrane. RAF in turn activates the protein kinase MEK, which

activates the protein kinase ERK. ERK translocates to the nucleus and regulates gene expression and cellular metabolism by the phosphorylation of proteins such as transcription factors. The MAPK cascade is vital to the control of cellular responses to mitogens, and affects growth through the nuclear transcriptional regulation and via cytoskeletal processes. ERK can activate the synthesis of cyclin D1 and its assembly with cdk4, which has a major role to play in cell cycle progression. Therefore MAPK can control some of the checkpoints in the cell cycle in response to extra-cellular growth signals.

### 1.5.1 RAS

The RAS proteins are signal transducers that share properties with the G proteins. There are three different RAS genes (H-RAS, K-RAS and N-RAS) that synthesize a family of 21kDa proteins. RAS proteins are bound to the inner part of the cytoplasmic membrane, and function as GTPases. They have two forms, an inactive form linked to GDP, and an active form which is able to bind and subsequently hydrolyse GTP (as reviewed by Fagin, 1992 and Tallini, 2002). The function of RAS proteins is to convey signals that originate from tyrosine-kinase receptors in the cytoplasmic membrane to a cascade of mitogen-activated phosphokinases (MAPKs). This activates the transcription of target genes and results in cellular proliferation. RAS proteins are also involved in the pathways controlling cell survival and apoptosis. Oncogenic mutations of the RAS gene affect the GTP-binding domain and maintain the RAS protein in an active form, and these mutations play a major role in human tumorigenesis. They represent one of the commonest mutated oncogenes in human cancer development (Bos, 1989).

There is evidence to suggest that RAS mutations may have a role to play in the initiation of thyroid tumorigenesis, with the thyroid-specific expression of mutant K-RAS in transgenic mice being associated with the development of follicular thyroid cancer (Santelli et al., 1993). In vitro transfer experiments have also provided compelling evidence for the initiating role of RAS in thyroid tumorigenesis. Normal cultured thyrocytes proliferate slowly and stop dividing after a few passages in vitro (Bond et al., 1999). The infection of thyrocyte colonies in a monolayer culture with replication-defective retroviral vectors encoding H-Ras<sup>V12</sup> results in a dramatic stimulation of proliferation. This is sustained for up to 20-25 population doublings (Jones et al., 2000).

The expression of mutant RAS in these follicular cells does not inhibit the differentiation of thyroid epithelial cells, and this is consistent with the phenotype of an early follicular adenoma (Lemoine et al., 1989; Lemoine et al., 1990; Suarez et al., 1990; Wynford-Thomas, 1993a; Bond et al., 1994; Gire and Wynford-Thomas, 2000). However, the expression of mutant RAS is not sufficient alone for complete malignant transformation (Bond et al., 1994; Monaco et al., 1995), and RAS may exert its effects by increasing cellular chromosomal instability and therefore predisposing cells to accumulate further genetic alterations (Nikiforov, 2004). Ultimately this RAS-induced proliferation ceases in vitro, and this suggests the need for subsequent mutations either downstream in the RAS/RAF/MAPK pathway, or in separate pathways involved in the control of cell proliferation, for further malignant progression to occur.

Mutations in all three families of RAS oncogenes have been detected in both benign and malignant thyroid tumours (Suarez et al., 1988; Lemoine et al., 1989; Wright et al., 1989; Namba et al., 1990a; Namba et al., 1990b; Basolo et al., 2000; Nikiforova et al., 2003a). Mutations have been noted in up to 0-85% of follicular adenomas (Shi, Y.F. et al., 1991a), 14-82% of follicular carcinomas (Lemoine et al., 1988), up to 0-50% of papillary carcinomas (Naito et al., 1998) and in up to 60% of undifferentiated carcinomas (Garcia-Rostan et al., 2003), as reviewed by Vasko et al., (2003). Generally, oncogenic RAS mutations are more common in follicular than papillary carcinomas (Manenti et al., 1994). The majority of mutations have been found at codon 61 of H- and N-RAS genes. There are variations in the prevalence of RAS mutations among the different series, and this may be related to the differences in differentiation of the thyroid tumours analysed, as well as varying genetic mutations that were not investigated in the studies.

The prevalence of RAS mutations in 50% follicular adenomas (Lemoine et al., 1989; Namba et al., 1990b) continues to implicate this as an early event in thyroid tumorigenesis, and it may even be the founder event, particularly for follicular thyroid cancer. However several studies have implicated N-RAS mutations to be involved with tumour progression and an aggressive clinical behaviour (Basolo et al., 2000; Motoi et al., 2000). In accordance with this, over-expression of RAS in papillary carcinomas has been associated with a worse clinical prognosis (Basolo et al., 1994). A recent case report of an anaplastic carcinoma with areas of well-differentiated follicular cancer found RAS mutations in both tumour types, whereas p53 mutation was only observed in the anaplastic tumour (Asakawa and Kobayashi, 2002). This suggests that

the continued expression of RAS is important for tumour progression and metastasis (Tallini, 2002), and that oncogenic RAS may act as a mutator gene (Fagin, 2002), predisposing the cell to further genetic change.

### 1.5.2 BRAF

The RAF proteins are serine/threonine kinases that are intracellular effectors of the RAS/RAF/MAPK pathway, and they have a critical role in cell differentiation, proliferation and apoptosis. There are three isoforms in mammalian cells: A-RAF, B-RAF and C-RAF. B-RAF is the predominant isoform in thyroid follicular cells (B-type RAF kinase) and is the most potent RAF kinase activator of the MAPK pathway. Growth factors bind to cell membrane receptor tyrosine kinases, which then activate RAS. RAS then recruits RAF proteins to the membrane where they are activated, and this triggers the phosphorylation cascade of the MAPK pathway via the activation of MAPK/ERK kinase, which in turn activates ERK (Trovisco et al., 2006). Most oncogenic B-RAF mutations allow the formation of new interactions that fold the kinase enzyme into a catalytically competent structure. BRAF was first implicated in tumorigenesis by Davies, H. et al., 2002 who reported point mutations in colorectal carcinomas and malignant melanomas.

Although the aetiology of papillary thyroid cancer is not completely understood, activating mutations of three genes in the RET/RAS/BRAF/MAPK signal transduction pathway have been identified in the majority of papillary tumours. These three genetic alterations (RAS mutation, BRAF mutation, RET/PTC rearrangement) are mutually exclusive (Kimura et al., 2003; Soares et al.,

2003). Genetic changes in either one of these genes are believed to be one of the earliest initiating events in papillary carcinogenesis (Giordano et al., 2005).

BRAF mutations are unique to papillary tumorigenesis, and the BRAF mutation is the most prevalent of the three oncogenic mutations in papillary thyroid cancer. The mutation is almost exclusively the T1799A transversion mutation in exon 15. The high specificity and frequency of this mutation suggest that it plays a fundamental role in the development of papillary thyroid cancer. This is supported by the presence of BRAF mutations in 20-52% of micro-papillary carcinomas (Sedliarou et al., 2004; Kim, T.Y. et al., 2005). The mutation has been demonstrated in 29-83% papillary carcinomas (Kimura et al., 2003; Soares et al., 2003; Namba et al., 2003; Nikiforova et al., 2003b). Papillary carcinomas that have a BRAF mutation have been shown to have a more aggressive clinical course (Nikiforova et al., 2003b), a higher incidence of extra-thyroidal invasion and distant metastases (Namba et al., 2003). A larger study by Xing et al., (2005) demonstrated a significant association between BRAF mutations and a more aggressive papillary cancer, with a greater incidence of metastasis, invasion and recurrence in these patients.

BRAF mutations have also been detected in 0-13% poorly differentiated papillary carcinomas (Nikiforova et al., 2003b; Soares et al., 2004) and in 0-63% undifferentiated, anaplastic carcinomas (Nikiforova et al., 2003b; Soares et al., 2004). It has been demonstrated that BRAF mutations are much more prevalent in anaplastic tumours that have papillary cancer components. The presence of BRAF mutations in these undifferentiated, aggressive tumours suggests that continued BRAF expression has as a role to play in the



malignant disease progression of papillary tumorigenesis. However it cannot be the only driving force for anaplastic transformation as many anaplastic cancers do not harbour this mutation (Soares et al., 2004).

### 1.5.3 RET

The RET (RE-arranged during T-ransfection) gene was first identified in 1985 (Takahashi et al., 1985). It is located at 10q21 and encodes a tyrosine kinase receptor protein consisting of an extracellular domain with a ligand binding site, a transmembrane domain and an intracellular tyrosine kinase domain (Myers et al., 1995), whose ligands belong to the glial cell line-derived neurotropic factor family (Tallini, 2002). It operates as an intracellular signal transducer, and is expressed in human cells of neural crest origin. In a normal thyroid gland, RET is expressed in the parafollicular C-cells, and is not normally expressed in thyroid follicular cells. Ligand binding results in initiation of the signalling cascade, and by stimulating RAS activation, can directly stimulate the MAPK pathway. RET plays a critical role in the development and maturation of the peripheral nervous system (DeLellis, 2006).

A RET/PTC chromosomal rearrangement unique to papillary thyroid carcinoma links the N-terminal and promoter domains of unrelated genes to the C-terminal fragment of RET to produce a chimeric form of the protein that is constitutively active (Santoro et al., 2002). These fusion proteins are inappropriately expressed in papillary thyroid cancer and stimulate constitutive signalling, thus bypassing the need for receptor activation by growth signalling and therefore the cell is continually stimulated to proliferate. More than fifteen forms of RET rearrangement have been identified, with RET/PTC1 and

RET/PTC3 being the most common. RET/PTC1 is formed by a paracentric inversion of the long arm of chromosome 10, resulting in fusion with the H4 (D10S170) gene. RET/PTC3 is formed by fusion with the RFG/ELE1 gene (Fagin, 2004).

Activated RET/PTC is tumorigenic, and has been shown to induce proliferation in thyrocytes in vitro (Bond et al., 1994). The introduction of activated RET into thyroid follicular cells results in outgrowth of the proliferating thyrocyte colonies, which show phenotypical differences with the mutant RAS-induced colonies, including a migratory pattern of growth and the formation of papilliform structures. This suggests that the initial oncogenic event (either RAS or RET) may determine whether the resulting tumour has a follicular or a papillary phenotype (Wynford-Thomas, 1997).

There is a high frequency of RET/PTC rearrangements in papillary micro-carcinomas, which lends evidence to the in vitro work suggesting that the RET/PTC rearrangement is an early event in papillary thyroid tumorigenesis (Viglietto et al., 1995; Sugg et al., 1998). RET/PTC rearrangements are prevalent in 13-43% of papillary carcinomas (Bongarzone et al., 1989; Grieco et al., 1990; Fagin, 1992; Soares et al., 2003), and are the second commonest genetic abnormality found in papillary carcinomas. The wide variation in prevalence of RET/PTC rearrangements may be partly due to geographic variability, and the use of different methods to detect these rearrangements, as RET/PTC has been found in only a small fraction of papillary tumour cells, as well as almost all of a papillary cancer (Zhu et al., 2006).

In contrast, there is a low prevalence of these rearrangements in poorly- and undifferentiated thyroid carcinoma and a recent study demonstrated that papillary tumours with the RET/PTC rearrangement do not progress to become anaplastic carcinomas (Tallini et al., 1998). This suggests that the RET/PTC fusion proteins may only have a small role in the further development of thyroid tumorigenesis (Santoro et al., 2002), although this loss of expression in the aggressive cancers may be an epiphenomenon related to the cell de-differentiation in these tumours (Kondo et al., 2006).

Therefore the activation of the linear signalling RET/RAS/RAF/MAPK pathway has an initiating role in the development of papillary thyroid tumorigenesis, although the mutations and rearrangements of the RAS, RAF and RET genes are not sufficient alone to induce continued proliferation, tissue invasion and metastasis. These alterations will result in continuous stimulation of the cell to divide, however the cell must also bypass the tumour suppressor genes that control the cell cycle checkpoints, and develop the ability to induce angiogenesis and local and distant tissue invasion.

## **1.6 PAX8-PPAR $\gamma$**

PAX8 encodes a thyroid cell-transcription factor that is essential for the genesis and differentiation of thyroid follicular cell lineages and regulation of thyroid-specific gene expression such as thyroglobulin and thyroperoxidase (Tallini, 2002). Peroxisome proliferator-activator receptor- $\gamma$  (PPAR $\gamma$ ) is a member of the steroid nuclear-hormone-receptor super-family that forms heterodimers with retinoid receptors. It is best known for its differentiation

effects on adipocytes and insulin-mediated metabolic functions (Desvergne and Wahli, 1999), and it stimulates lipogenesis, inhibits growth, and induces terminal differentiation of cancer cell lines. Kroll et al., (2000) first identified a unique and interesting rearrangement in follicular thyroid carcinomas. This involves the translocation  $t(2;3)(q13;p25)$  that generates a chimeric gene encoding for the DNA-binding domain of PAX8 and the A-F domains of PPAR $\gamma$ . The PAX8-PPAR $\gamma$  rearrangement has a dominant-negative effect on the transcriptional activity of wild-type PPAR $\gamma$  and contributes to thyroid tumorigenesis with an oncogenic role by targeting several cellular pathways (Kondo et al., 2006).

PAX8-PPAR $\gamma$  rearrangements are seen in both follicular adenomas and follicular carcinomas; however the adenomas have a lower prevalence (0-31%) than the carcinomas (25-63%) (Marques et al., 2002; Cheung et al., 2003). The follicular cancers with the PAX8-PPAR $\gamma$  rearrangement are more likely to be overtly invasive (Nikiforova et al., 2003a). To date, the rearrangement has not been demonstrated in either poorly-differentiated follicular carcinoma or anaplastic carcinoma (Nikiforov et al., 2004), although the number of analysed cases is too small to reach a definitive conclusion. In a comparative study of RAS mutations and PPAR $\gamma$  rearrangements, 49% follicular cancers had RAS mutations, 35% had the PAX8-PPAR $\gamma$  rearrangement and only 3% of cases had both genetic alterations (Nikiforova et al., 2003a). Interestingly, 12% of the follicular cancers were negative for both, which implies that follicular cancers may develop through at least two separate pathways, including separately both the RAS/RAF/MAPK and the PPAR $\gamma$  pathway.

## 1.7 MET

The c-MET oncogene (7q13) encodes for a trans-membrane tyrosine kinase protein identified as the receptor for a polypeptide known as hepatocyte growth factor (HGF) (Bottaro et al., 1991). HGF is a potent mitogen for epithelial cells and HGF-MET signalling regulates cell proliferation and differentiation in a normal embryonic development. MET is not over-expressed in normal thyroid tissue; however HGF is present in the connective tissue stroma of the thyroid (Trovato et al., 1998).

Di Renzo et al., (1992) investigated MET expression in thyroid cancers with Western blot analysis, and reported that MET was over-expressed in 70% papillary cancers, and was negligible in follicular adenomas and carcinomas, and anaplastic carcinomas. HGF induces a significant increase in the invasiveness of thyroid tumour cells in vitro (Scarpino et al., 1999). HGF-MET signalling in papillary carcinomas has been shown to modulate the motility of the cancer cells and therefore promote invasion, metastasis and angiogenesis (Ruco et al., 2001; Scarpino et al., 2003). Scarpino et al., (2003) also discovered evidence that HGF-MET signalling plays a role in the recruitment of inflammatory cells to a tumour via the induction of cytokine release by the neoplastic cells. Whereas some studies have demonstrated an association between MET over-expression and a poor prognosis (Chen et al., 1999), other data has correlated a loss of MET expression with the development of aggressive, undifferentiated tumours.

This up-regulation of MET by papillary cancer cells is believed to partly sustain their continued growth through the paracrine stimulation of HGF, which is

found in thyroid stromal cells. Thyrocyte in vitro work has demonstrated a relationship between RAS and RET activation and MET over-expression in human thyroid follicular cells (Ivan et al., 1997), and this group suggested that the advantage gained from the activation of RAS and RET oncogenes could be due to sensitisation of the tumour epithelium to the paracrine secretion of HGF from the stroma. These results all suggest that MET over-expression may have a role to play in thyroid papillary tumorigenesis.

### **1.8 PI3K / AKT pathway**

The PI3-kinase / AKT pathway is involved in the control of cell growth and the inhibition of apoptosis, and its effects are mediated by the phosphorylation of downstream effectors by AKT, a serine threonine tyrosine kinase (Tallini, 2002). The PI3K/AKT pathway is negatively regulated by PTEN (phosphate and tensin homologue), and is activated by tyrosine kinases and RAS. There are three isoforms of AKT, AKT-1, AKT-2 and AKT-3, and all three isoforms are expressed in human thyroid tissue, although AKT-1 and AKT-2 are the predominant isoforms at both the mRNA and protein levels (Ringel et al., 2001). Downstream targets of AKT regulate cell cycle progression, apoptosis, proliferation, cytoskeletal motility and stability and energy metabolism (Brazil et al., 2004; Kada et al., 2004). The PI3K/AKT pathway may have a crucial role to play in the progression of thyroid cancer, since the oncogenic activation of RAS and tyrosine kinases such as RET/PTC have been shown to be initiating events in thyroid tumorigenesis.

The importance of the PI3K/AKT pathway was first highlighted when loss of PTEN expression was identified as the genetic cause for Cowden syndrome, mentioned earlier. Ten percent of patients with this disease develop thyroid cancer, in the form of a follicular adenoma or follicular carcinoma (Longy and Lacombe, 1996). However, PTEN mutations have also been described in up to 25% of sporadically occurring follicular adenomas and carcinomas, and less frequently in papillary carcinomas (Dahia et al., 1997; Halachmi et al., 1998; Bruni et al., 2000).

Ringel et al., 2001, demonstrated that follicular carcinomas have an increased expression of AKT-1 and AKT-2 isoforms, and increased levels of total AKT activity when compared to normal human thyroid tissue. This increase in AKT activity was also reported by Vasko et al., 2004b, and this increase in activity correlated with either activating mutations of RAS, or the PAX8-PPAR $\gamma$  rearrangement. Furthermore, loss of PTEN expression has also been described in follicular carcinomas (Halachmi et al., 1998; Bruni et al., 2000). This data indicates that activation of the PI3K/AKT pathway is an early event in follicular thyroid tumorigenesis, and occurs in both sporadic and inherited forms of the disease.

Papillary carcinomas can be divided into those tumours with a BRAF mutation, and those with a RET/PTC rearrangement or a RAS mutation. The PI3K/AKT pathway has only been shown to be activated in those cancers harbouring a RET/PTC rearrangement or RAS mutation, and BRAF mutations do not appear to activate the pathway (Vasko et al., 2004b).

The activation of AKT signalling in several human malignancies has been shown to be associated with an advanced tumour stage and tumour progression (Kim, D. et al., 2005). There is an association between increased thyroid tumour size and invasion, and increased AKT activity, for both follicular carcinomas and those papillary carcinomas with a RET/PTC rearrangement or RAS mutation (Shin et al., 2004; Vasko et al., 2004b). Therefore the PI3/AKT pathway is not only important in the early development of thyroid carcinoma, but also has a role to play in the progression of the disease.

## **1.9 The cell cycle**

When a cell is stimulated to divide, it begins a tightly regulated sequence of events known as the cell cycle. The purpose of the cell cycle is to replicate DNA, after allowing for repair of DNA damage, and to segregate the duplicated DNA into two daughter cells (Sherr, 2000). Quiescent cells remain in the resting G<sub>0</sub> phase of the cell cycle. This can be a temporary phase, and cells can re-enter the cycle at the G<sub>1</sub> phase if stimulated by mitogens. Alternatively, the quiescence can be permanent, as seen in terminally differentiated cells.

The cell cycle has several checkpoints to ensure that a cell does not replicate with damaged DNA, and the primary “restriction point” controls the transition from G<sub>1</sub> (Gap 1) to S (synthesis) phase (Pardee, 1989). At this stage a cell must determine whether to continue through the cell cycle, to become quiescent or to undergo apoptosis if the damage is irreparable. If a cell was to continue through the cell cycle, the continued accumulation of genetic defects and instability could lead to malignant transformation. Once a cell has



committed to the division process, it is committed to entering S phase, during which DNA synthesis begins, and the genome is duplicated. A second checkpoint occurs at the transition from G2 (Gap 2) to M (Mitosis) phase. If a cell successfully passes this restriction point, the replicated chromosomes are condensed and sister chromatids separate to form two nuclei, and the cytoplasm splits to form two daughter cells, marking the end of the cell cycle.

The transition from G1 to S phase is controlled by cyclin - cyclin dependent kinase (cyclin-cdk) complexes. The cdk subunit has a catalytic action and the cyclin subunit has a regulatory action. There are two families of enzymes, the cyclin D-dependent and the cyclin E-dependent kinases. Cyclins D1, D2 and D4 interact with cdk4 and cdk6. The D-type cyclins are inherently unstable, and their expression and function depends upon persistent growth factor signalling. Cyclin D has a short half-life, and after a cell has passed the G1/S phase checkpoint, it is degraded. Because the cdk4 and cdk6 enzymes are only active when cyclin D is bound, the expression of cyclin D is a rate-limiting step for entry into S-phase. The active cyclin D – cdk4/6 complexes are required to inactivate Rb protein, the major 'gatekeeper' of the cell cycle and the Rb pathway. This then allows the cell to progress to S phase.

During G1 phase, the Rb protein is initially active in a hypophosphorylated form. In this state it sequesters the E2F family of transcription factors (E2F 1, 2, 3). When cyclin D binds to cdk4/6 during G1 phase, this enzyme complex phosphorylates and subsequently inactivates Rb, which causes the release of E2F proteins and cancelling the growth-suppressive actions of Rb (Kato et al., 1993). The E2F factors are only active when they are released from Rb, and

they are essential for S phase transition. They up-regulate S-phase genes such as cyclins A and E, and promote progression of a cell through the G1/S phase checkpoint (reviewed by Nevins, 2001).

Formation of the cyclin D – cdk 4/6 complexes is followed by the up-regulation of cyclin E which itself forms complexes with cdk2 in late G1 phase, and further phosphorylates Rb (Koff et al., 1992; Lundberg and Weinberg, 1998). The cyclin E-cdk2 complex is not dependent on mitogenic stimulation, and therefore the cell is no longer dependent on extra-cellular growth factors at this stage of the cell cycle. Cyclin E-cdk2 activity reaches a peak at the G1-S phase transition point and is then degraded, when it is replaced by cyclin A expression during late G1 phase through to the M phase of the cell cycle. The formation of cyclin A – cdk2 complexes is an essential requirement for the S-phase of the cell cycle.

The thyroid cell turns over on average no more than 5 times through adulthood and there is a higher rate of turnover in early infancy and adolescence. Mature adult thyroid cells have a very low rate of both cell proliferation and cell death. However if the cells are exposed to an appropriate extrinsic or intrinsic mitogenic stimulus, they can mount a significant proliferative response (Wynford-Thomas, 1997). It is assumed that cycles of cell division are more frequent in benign or malignant thyroid tumours. Well-differentiated thyroid tumours (follicular adenomas and follicular and papillary carcinomas) have a low proliferative rate when compared with poorly- and undifferentiated thyroid tumours, as defined by the MIB-1 index. This has been reported as being 1-3% in well-differentiated cancers, 6-7% in poorly-differentiated cancers and 14-

52% in undifferentiated anaplastic thyroid cancers (Katoh et al., 1995; Basolo et al., 1997; Yoshida et al., 1999; Kjellman et al., 2003). Altered expression of both positive (e.g. cyclin D1, cdk4, cdk6, E2F) and negative (p16, p21, pRb, p53) cell cycle regulators govern these differences in tumour growth activity.

### 1.9.1 p16

There are two main inhibitors of the cell cycle during the G1/S phase restriction point; the INK4 and the Cip/Kip families of cyclin-dependent kinase inhibitors. The INK proteins (inhibit cdk4) specifically target and inhibit cyclin D-dependent kinases (reviewed by Sherr and Roberts, 1995), and there are 4 members, p16<sup>INK4A</sup>, p16<sup>INK4B</sup>, p18<sup>INK4C</sup> and p19<sup>INK4D</sup>.

The p16<sup>INK4A</sup> protein is a 148 amino acid protein encoded by exons 1 $\alpha$ , 2 and 3 in open reading frames of 125, 307 and 12 base pairs respectively, on the short arm of chromosome 9 (Kamb et al., 1994) at the CDKN2A locus. It was first isolated as cdk4-binding protein in a yeast two-hybrid system (Serrano et al., 1993). One molecule of p16 binds to each molecule of cdk4 or cdk6, and prevents cyclin D1 binding by competing for the cyclin D binding site, thus rendering this enzyme complex inactive, and therefore Rb remains in an active, hypophosphorylated state and the cell is unable to pass the G1/S phase checkpoint. There is evidence to suggest that the Rb pathway acts as a single target in tumorigenesis. Inactivation of the Rb and p16 genes is mutually exclusive in lung cancer (Shapiro et al., 1995) and bladder cancer (Benedict et al., 1999).

In order for p16 to exert its action, the cell must have a functional Rb protein (Guan et al., 1994; Lukas et al., 1995). When p16 expression is forced in cells with functional Rb in vitro, a reversible arrest of the cell cycle occurs (Lukas et al., 1999). Therefore the inactivation of both proteins would be of no advantage to a developing tumour and therefore would not be selected for.

Levels of p16 are regulated at the transcriptional level. Expression of p16 mRNA is very low in most tissues and it is also a very stable mRNA (Hara et al., 1996). We currently do not have a clear understanding of the signals that regulate p16 expression. However, tissue culture work using human dermal fibroblasts has shown that the p16 promoter is activated by the expression of Ets transcription factors. Oncogenic RAS has the ability to promote expression of the Ets factors, which are downstream targets of the RAS/RAF/MAPK signalling pathway (Ohtani et al., 2001).

The p16 gene is one of the most frequently altered genes involved in cell cycle regulation in human cancers (Sherr, 1996). The gene can be inactivated by point mutation, promoter methylation or deletion. Complete inactivation of the gene occurs when both alleles are deleted, or one allele is deleted (loss of heterozygosity) and the other allele is inactivated by promoter methylation or mutation, or if methylation and mutation occur on separate alleles. Partial inactivation by deletion, methylation or mutation of only one allele can also occur, causing haplo-insufficiency. However, it is the level of protein expression and not the genetic copy number that may exert a genotype – phenotype influence, and the protein expression may not directly relate to the

gene copy number if the p16 protein has been modified by post-transcriptional events.

Loss of p16 activity by gene deletion, mutation or transcriptional inactivation has been demonstrated in a wide range of human cancers (Nobori et al., 1994; Hiramata and Koeffler, 1995; Sherr, 1996; Ruas and Peters, 1998). The loss of p16 expression is expected to lead to inappropriate progression through the cell cycle and uncontrolled proliferation of a tumour.

Thyroid tumour cell lines have been shown to have deletions, point mutations and structural alterations of the p16 gene in both follicular- and papillary-derived cancer cell lines (Calabro et al., 1996; Jones et al., 1996) and cell lines from undifferentiated thyroid cancers (Elisei et al., 1998). This data suggests that p16 may have an important role to play in both follicular and papillary thyroid tumorigenesis.

In contrast, p16 genetic alterations are rare in thyroid tumours in vivo. Loss of heterozygosity and hypermethylation are more common than point mutations, but they are not as common as the cell studies would indicate (Calabro et al., 1996; Tung et al., 1996; Yane et al., 1996; Elisei et al., 1998). Our understanding of the frequency of the epigenetic and genetic events as a cause for p16 mutation in thyroid cancer is complicated by that fact that not every study analyses every possible mode of p16 gene inactivation in the same tumour panel.

Therefore we have to put together an overall view with results from different laboratories in different thyroid tumour panels from different geographic backgrounds. This may partly explain the different results seen by individual researchers. It is also possible for one tumour to have two or more co-existing modes of gene inactivation, such as methylation and point mutation. Thus a study that concentrates on just one mode could potentially give an inaccurate representation of the gene status for the tumour group. Furthermore, variations in the population of patients from which the thyroid tumours were obtained, such as differing geographical locations which have a higher or lower incidence of thyroid cancer, may be of relevance where the mode of gene inactivation can be influenced by environmental factors such as ionising radiation.

### 1.9.2 p21

The p21 protein belongs to the Cip/Kip family of cyclin-dependent kinase inhibitors (p21, p27, p57), and was the first cyclin-dependent kinase inhibitor to be identified (Harper et al., 1993). It inhibits cdk2, and is involved in the assembly of cyclin D-cdk4/6 complexes when a cell enters the cell cycle after a period of quiescence in response to mitogenic signals (Sherr, 2000). At low cellular concentrations, p21 facilitates the formation of cyclin D – cdk4/6 complexes and subsequent progression through the cell cycle. At higher concentrations, p21 inhibits the formation of both cyclin D-cdk4/6 and cyclin E-cdk2 complexes (Harper et al., 1995) and prevents the cell entering S phase. When p16 is expressed, it binds to cdk4/6, and liberates the bound p21 proteins. This increase in circulating p21 leads to an increase in cyclin E-cdk2 complex inhibition, thus ensuring cell cycle arrest (Sherr and Roberts, 1999).

p21 exerts its effects via p53-dependent pathways p21, as a direct transcriptional target of p53 (el-Deiry et al., 1994). However it is also activated through p53-independent pathways, and has a role to play in cellular differentiation and apoptosis.

Thyroid carcinomas in vivo demonstrate an up-regulation in follicular adenomas when compared to normal thyroid tissue, and a further up-regulation is seen in both follicular and papillary carcinomas (Ito et al., 1996; Zedenius et al., 1996; Pickett et al., 2005). There is some discordance with regards to the level of p21 protein expression in undifferentiated carcinomas, with both an increase (Okayasu et al., 1998) and a decrease in expression (Brzezinski et al., 2005) having been reported. In summary, both p16 and p21 appear to have a role to play in the development of thyroid tumours. However there must be other pathways controlling the cell cycle that are involved in thyroid tumorigenesis, because follicular and papillary carcinomas continue to proliferate in the face of both p16 and p21 expression.

### **1.10 p53 pathway**

The majority of mutations described so far involving the RET/RAS/RAF/MAPK are prevalent in well-differentiated thyroid cancers. Some of them appear to predispose to the progression of these tumours to a poorly- and undifferentiated tumour, although they are not sufficient alone to instigate this process, and additional mutations have to occur for this to happen. One of the candidates for this additional mutation is the tumour suppressor gene p53.

The p53 gene maps to chromosome 17p13 and encodes a nuclear phosphoprotein that, as a tetramer, acts as a transcription factor and has a central role in the regulation of the cell cycle. It is a key component in the cellular emergency response mechanism and converts both intra- and extra-cellular stress signals (such as DNA damage, activation of dominant oncogenes) into either growth arrest or apoptosis.

When DNA is damaged, p53 arrests the cell at the G1-S checkpoint of the cell cycle, which allows DNA repair mechanisms to correct the damage. It exerts these functions by activating the expression of several genes, such as p21, which can induce G1 arrest by inhibiting cyclin-cdk complexes. If the damage cannot be repaired, p53 promotes apoptosis, therefore avoiding the replication of abnormal clones of cells (Gottlieb and Oren, 1996). The function of p53 is altered in cancer cells either by point mutations (typically in exons 5-8), or by deletions, and this results in the accumulation of genetic damage, with the resulting cells having a selective advantage for clonal expansion. These alterations of the p53 tumour suppressor gene represent the most frequent genetic change in human cancer, and usually occur at a late stage in tumorigenesis (Tallini, 2002).

In thyroid tumorigenesis, point mutations of p53 have been demonstrated in a significant proportion of anaplastic (63.6-75%) and poorly-differentiated cancers (5-52.6%), and are rarely seen in the well-differentiated follicular and papillary cancers (Donghi et al., 1993; Fagin et al., 1993; Ito et al., 1993; Dobashi et al., 1994; Takeuchi et al., 1999). The differences in prevalence of p53 mutation in the series of poorly-differentiated thyroid carcinomas are



thought to be due to the differences in histological diagnostic criteria in identifying insular carcinomas. p53 mutations have also been reported in the metastatic counterparts of differentiated thyroid carcinomas (Sapi et al., 1995; Zedenius et al., 1996). Furthermore, Tzen et al., (2003), reported that p53 mutations are present in the atypical cells seen in thyroid atypical adenomas, and speculated therefore that atypical adenomas may represent an intermediate lesion between follicular and anaplastic carcinomas. There have also been several reports that when a tumour contains areas of both well-differentiated and undifferentiated tumour, p53 mutations are restricted to the undifferentiated areas (Nakamura et al., 1992; Matias-Guiu et al., 1996; Asakawa and Kobayashi, 2002).

The recovery of p53 function in cultured thyrocytes derived from human thyroid tumours is accompanied by a reduction in both tumorigenic activity and proliferation, and a return to a more differentiated phenotype (Fagin et al., 1996; Moretti et al., 1997). These data indicate that the mutational inactivation of the p53 gene is likely to play a key role in thyroid cancer de-differentiation and the progression from a differentiated to an undifferentiated tumour.

### **1.11 $\beta$ -Catenin**

$\beta$ -catenin is a cytoplasmic protein, encoded by the CTNNB1 gene on chromosome 3p22-21.3, which plays an important role in E-cadherin-mediated cell-cell adhesion by binding the cytoplasmic tail of cadherin proteins. It is also a downstream effector of the Wingless/Wnt signalling pathway, which targets cyclin D1, and is critical in regulating cell fate and differentiation during

embryogenesis (reviewed by Dierick and Bejsovec, 1999). Normal thyroid follicular cells express  $\beta$ -catenin.

For tumorigenesis to occur, epithelial cells must alter their adhesion properties to allow invasion and metastasis to occur. In the absence of Wnt signalling,  $\beta$ -catenin is located on the cell membrane and is present at a low level in the cytoplasm, where it is rapidly degraded by the adenomatous polyposis coli (APC) multi-protein complex. In the presence of Wnt,  $\beta$ -catenin is stabilised, translocates to the nucleus and up-regulates the transcriptional activity of genes such as cyclin D1 (Nikiforov, 2004). Point mutations in exon 3 of the gene stabilize the protein, bypassing Wnt, resulting in constitutive activation of target gene expression.

Point mutations in exon 3 have been reported in 25% poorly-differentiated thyroid tumours and in 66% anaplastic cancers, but are not present in well-differentiated thyroid cancers (Garcia-Rostan et al., 2001; Miyake et al., 2001). This data suggests that  $\beta$ -catenin mutations play a direct role in the de-differentiation of thyroid carcinomas, particularly in those follicular and papillary tumours that transform into anaplastic cancers.

### **1.12 Overview of thyroid tumorigenesis**

Thyroid tumorigenesis is the result of a step-wise progression of genetic changes, including activating mutations of oncogenes such as BRAF and RET/PTC, and genetic and epigenetic silencing of tumour suppressor genes such as p53, as previously described. Studies of allelic imbalances in well-

differentiated and poorly-differentiated thyroid cancer give further evidence for this stepwise progression. In many human neoplasms, there is a widespread loss and / or duplication of chromosomal regions and entire chromosomes in the late, poorly-differentiated stages and this reflects the destabilisation of the cancer's genome.

In thyroid tumorigenesis, both follicular and anaplastic thyroid cancers have a high rate of allelic losses and gains. In contrast, papillary cancers have only a mild degree or a lack of chromosomal instability (Ward et al., 1998; Hemmer et al., 1999; Kitamura et al., 2000; Kleer et al., 2000; Hunt et al., 2003; Nikiforov, 2004). The loss of identical chromosomal regions in both follicular and anaplastic carcinomas, and in both the well-differentiated and undifferentiated components of an individual thyroid tumour indicates that there is a connection between these two tumour phenotypes (Hunt et al., 2003). Wreesmann et al., 2002, analysed the chromosomal abnormalities in well-differentiated, poorly-differentiated and undifferentiated thyroid cancer with comparative genomic hybridization. They observed that the chromosomal abnormalities fell into three groups. All three thyroid cancers had gains of 5p15, 5q11-13, 8q23, 19p and 19q, and deletions of 8p and 22q. Secondly, the poorly- and undifferentiated cancers had gains of 1q34-36, 6p21, 9q34, 17q25 and 20q, and deletions of 1p11-31, 2q32-33, 4q11-13, 6q21 and 13q21-31. Finally, the anaplastic carcinomas had gains of 3p13-14 and 11q13, and loss of 5q11-31. The gains or losses of identical chromosomal regions in well-, poorly- and undifferentiated thyroid carcinoma indicate that there is a common genetic pathway linking these tumour phenotypes. Furthermore, there were no

chromosomal abnormalities that were unique to the mid-stage of thyroid tumorigenesis, the poorly-differentiated thyroid cancers.

During thyroid tumorigenesis, a single transformed cell appears to gain a growth advantage due to loss of proliferative regulation (Heaney et al., 2001). The ensuing genomic instability renders the cell prone to large scale chromosomal aberrations, amplifications, deletions and translocations, as described above. Thyroid neoplasms are quite unique, because a single normal follicular cell can give rise to two tumours with distinctly different histological characteristics, namely follicular and papillary carcinomas.

These tumours have different biological characteristics, and metastasise via two different pathways (papillary cancers invade via the lymphatic system and follicular cancers invade via the blood stream), yet both tumours have the potential to transform into an undifferentiated anaplastic carcinoma. Evidence for differing initiating events in the early tumorigenesis of these two cancers has already been described, such as RAS and PAX8-PPAR $\gamma$  mutations which predominate in follicular adenomas and malignant follicular carcinomas, and RET/PTC mutations which are unique to papillary thyroid carcinomas. However, the exact molecular mechanisms involved in thyroid tumorigenesis are still unclear.

Some of the genetic mutations have been correlated with an increased likelihood of de-differentiation to an anaplastic phenotype, as seen in the subset of papillary and follicular thyroid tumours with a BRAF mutation. Additional genetic changes are required for a tumour to transform into this

aggressive phenotype, and both p53 and  $\beta$ -catenin mutations are potential triggers of this process.

### **1.13 Thyrocyte tumour model**

Human thyroid follicular epithelial cells give rise to a range of well-defined stages, from benign adenomas to aggressive, undifferentiated carcinomas. There are also two distinct pathways of tumorigenesis which can arise from the same follicular cell, which differ in their clinical and pathological behaviour. This is therefore an excellent model to use for studying the molecular changes involved in multi-step human tumorigenesis. The early development of a thyroid tumour is closely correlated with mutations of RAS and RET genes, and these are each associated with a different tumour phenotype. There is therefore a strong phenotype – genotype association.

The thyroid has a distinct advantage over other tissues for developing a tissue culture tumour model. Firstly, thyroid cells can be easily obtained from surgical pathological material, and they remain viable in a simple monolayer culture with the same cell kinetics as those seen in the intact thyroid gland (Poghosyan and Wynford-Thomas, 2005). Secondly, thyroid tumorigenesis results in a dramatic increase in cellular proliferation in comparison to the normally quiescent thyroid gland, and is therefore simpler to model in tissue culture when compared to other human tissues which are continually renewing or differentiating.

The major principle of our 'in-house' tissue culture research is that RAS mutation occurs at an early stage (follicular adenoma) in thyroid tumorigenesis, that this is a common event and that the introduction of RAS mutations into thyrocytes can stimulate cellular proliferation in vitro, mimicking the development of an in vivo adenoma. By introducing mutant RAS and RET into thyrocytes, our laboratory has developed an in vitro model of human thyroid tumorigenesis. This model has demonstrated the influence of the initiating oncogene on the evolving phenotype of the resulting thyrocyte colonies.

Thyrocytes in tissue culture normally undergo two or three p.d. before entering a state of irreversible quiescence. The expression of mutant RAS V12 induces an increase in proliferation and the generation of thyrocyte colonies, which show a normal thyroid epithelium phenotype and grow in continuous cell sheets (Bond et al., 1994). This proliferative response ceases after 20-25 pd, mimicking an in vivo 'burnt out' follicular adenoma. The introduction of mutant RAS does not induce a de-differentiation of the thyrocytes, and they continue to express thyroid-specific proteins such as thyroglobulin, TTF-1 and PAX8 (Gire and Wynford-Thomas, 2000). Therefore the high frequency of RAS mutations seen in both benign and malignant follicular thyroid tumours (Lemoine et al., 1989; Suarez et al., 1990) is matched by the increase in thyrocyte proliferation seen in the RAS thyrocyte colonies. To summarise, the expression of mutant RAS in human thyrocytes generates a clonal expansion of cells which retain thyroid-specific gene expression and the resulting colonies demonstrate a phenotype that is consistent with a follicular adenoma, the first stage of follicular thyroid tumorigenesis.

Papillary thyroid cancers develop de novo from normal thyroid follicular cells, unlike their follicular counterparts. As previously described, the RET/PTC rearrangement is a frequent finding in papillary tumours (Santoro et al., 1992). Research performed in our laboratory has shown that the introduction of rearranged RET into human thyrocytes also leads to an increase proliferation, similar to that seen with RAS (Wynford-Thomas, 1993b; Bond et al., 1994).

The resulting colonies had a different phenotypical appearance to the RAS colonies, with a fenestrated appearance, cell-free zones and infoldings that resembled papillae (Bond et al., 1994). The colonies grew more slowly, and the demarcation from surrounding thyrocytes was less clear. This data demonstrates that the expression of a RET rearrangement in human thyrocytes induces proliferation, and the colonies have a different phenotype compared to RAS colonies, which resembles the in vivo papillary phenotype, and is consistent with the RET/PTC rearrangement being an initiating event for papillary thyroid tumorigenesis.

The introduction of mutant p53 into thyrocytes in vitro (Bond et al., 1994) failed to elucidate an increase in proliferation, contrasting the effects of mutant RAS and RET expression. Our in vitro data is therefore in accordance with in vivo data (Ito et al., 1992), where p53 mutation only confers a growth advantage to poorly- and undifferentiated, late-stage thyroid tumours. The findings of the experiments with mutant RAS, RET and p53 indicate that our 'in-house' thyrocyte tumour model is a good representation of the in vivo thyroid tumour model.

The majority of follicular adenomas eventually reach a quiescent end-point, and this has often been attributed to the inability to invade or promote new blood vessel formation. However, we have demonstrated that RAS-induced thyrocyte colonies, which resemble follicular adenomas, also reach a quiescent end-point in tissue culture. This data suggests that the mechanism responsible for the proliferation-barrier is cell-intrinsic, and independent of tissue architecture, since it occurs both in vivo and in vitro. The cyclin-dependent kinase inhibitor p16 has been postulated to have a role in mediating growth arrest, and mutations and deletions of this gene have been observed in many human cancers (Bos, 1989).

Jones et al., (2000) studied the expression of p16 in normal thyrocytes and in early and late-stage RAS-induced thyrocyte colonies by immunocytochemistry and Western blotting. They demonstrated that p16 is not expressed in normal thyrocytes, and that there is a 20-fold increase in p16 expression between early and late-stage RAS colonies, corresponding with the growth arrest of the late-stage thyrocytes colonies. This strongly suggests that p16 is a candidate gene for the proliferative lifespan barrier that limits tumour progression in epithelial cells.

To provide evidence to support this theory, Bond et al., (2004) designed a small interfering RNA (siRNA) that 'knocks down' p16 expression, and transfected this into RAS-induced thyrocytes colonies. This resulted in the outgrowth of proliferating clusters of cells, and the escape from the proliferation barrier normally seen in the RAS thyrocytes colonies. Therefore the abrogation of p16 expression is correlated with continued thyrocyte



proliferation. This data supports the theory that p16 has a role in limiting oncogene-driven clonal expansion in thyroid cancer, and therefore there is a valid selection pressure to account for the genetic and epigenetic loss of p16 seen in many human cancers.

#### **1.14 Aims and hypothesis**

Our thyrocyte cell culture studies suggest that at least one requirement for the progression from a benign adenoma to a clinically significant malignancy is the loss of p16 expression, and the resulting abrogation of an intrinsic 'fail-safe' mechanism which normally limits the proliferative lifespan of the RAS-induced clones.

There is great clinical interest in the molecular mechanisms involved in the transition from a follicular adenoma to a follicular carcinoma. Follicular adenomas and carcinomas often have a remarkably similar phenotype with respect to cytology, architecture, and cell kinetics and differentiation markers. Currently, it is only by painstaking histological examination of multiple tissue blocks for capsular or vascular invasion that malignancy can be diagnosed or excluded, and therefore patients with follicular adenomas undergo an unnecessary operation which is not without risk. Frustrating as this may be for the clinician, these tumours make an ideal pair for comparison of gene expression profiles since it maximises the chances that any observed differences will be linked directly to the malignant phenotype rather than to spurious changes secondary to altered differentiation states. Research in this area could potentially lead to the identification of a definitive marker for

distinguishing these two tumours in fine needle aspirates of thyroid nodules. This is a long-standing problem in the diagnosis and management of thyroid disease.

The overall strategy underlying my research is to analyse the expression of potential candidate genes involved in early thyroid tumorigenesis which are induced in the RAS thyrocytes colonies in our thyrocytes tumour model, and to compare this with the expression of these genes in human thyroid tumour samples. The human tissue samples will be drawn from existing archived tumour samples, from patients having surgery for thyroid cancer during the period of my research, and from colleagues' tissue archives in France. I will analyse differences in gene expression in every stage of human thyroid tumorigenesis, using normal thyroid tissue, atypical adenomas, follicular adenomas and carcinomas, micro-papillary and papillary carcinomas, insular and anaplastic carcinomas.

The initial candidate gene that I will be investigating is p16, on the basis of the results obtained in our laboratory on mutant RAS thyrocytes colonies. I will also investigate the expression of two other cell cycle genes, the oncogene cyclin D1, and the tumour suppressor gene p21. I will investigate the expression of p16, cyclin D1 and p21 proteins using immunohistochemistry on formalin-fixed, paraffin embedded tissue samples. Further candidate genes will be identified following the analysis of Affymetrix microarrays performed on the RAS thyrocytes colonies.

I hypothesise that p16 protein will not be expressed in normal thyroid tissue, and will be expressed in thyroid follicular adenomas. I expect this to be matched with a small increase in expression of the proliferation markers MCM2 and cyclin A. In the follicular and papillary carcinomas, I hypothesise that p16 expression will be down-regulated, in keeping with the progression to a malignant tumour, and that this will be matched by a further increase in expression of MCM2 and cyclin A, correlating with the increase in proliferation seen in these cancers. I expect there to be further loss of p16 expression in the poorly-differentiated and un-differentiated aggressive thyroid carcinomas, correlated with a greater increase in expression of MCM2 and cyclin A.

I also hypothesise that p21 expression will be correlated with p16 expression in the follicular adenomas, follicular and papillary carcinomas, with both proteins acting as tumour suppressors in the early stages of thyroid tumorigenesis. I expect the expression of cyclin D1 to be greater in the carcinomas than the adenomas, and that this will be correlated with the predicted loss of expression of both p16 and p21.

My research has the potential to provide novel information regarding the expression of cell cycle markers in thyroid tumorigenesis, and may also identify novel or unsuspected pathways, that are involved in malignant progression. Furthermore, these genes may be indicative of malignant follicular thyroid transformation and could potentially differentiate follicular adenomas from follicular carcinomas, thus solving one of the major problems in the treatment of thyroid cancer.

## **CHAPTER 2**

### **METHODS**

#### **2.1 Tissue samples**

##### **2.1.1 Archived thyroid tissue from Cardiff**

Archived thyroid tissue was available as formalin-fixed, paraffin-embedded specimen blocks that had previously been collected for research purposes, after obtaining appropriate consent, by the University Hospital of Wales Pathology department. The samples comprised a selection of normal thyroid tissue, thyroid follicular adenomas, follicular carcinomas and papillary carcinomas, a normal tonsil, and a cervical carcinoma.

##### **2.1.2 Acquisition of new Cardiff thyroid tissue**

I developed a consent form after collaborating with the Pathology Department, University Hospital of Wales, Cardiff, UK and with Mr D Scott-Coombes, Consultant Endocrine Surgeon, University Hospital of Wales, Cardiff, UK. The local Research Ethics Committee approved the consent form. I collected thyroid samples from patients who had surgery for a suspected or proven thyroid carcinoma in 2003 - 2005, after the patient and the consultant surgeon had signed the consent form. Specimens from the tumour and / or the background normal thyroid tissue were fixed in formalin and embedded in paraffin following a standard protocol in the University Hospital of Wales Histopathology department.

### 2.1.3 Acquisition of French thyroid tissue

We had access to tissue sections from a variety of normal thyroids and thyroid tumours, which were donated to us by two French colleagues (addresses in Appendix I). Catherine de Micco sent us tissue sections of follicular, papillary, insular and anaplastic carcinomas. Brigitte Franc sent us tissue sections of four micropapillary carcinomas and five sections from six Tissue Micro-Arrays (TMAs) comprising normal thyroid, follicular and atypical adenoma, and follicular, papillary and insular carcinoma samples. All tissue was obtained after appropriate local consent was sought for the use of tissue for research purposes.

The concept of TMAs was first described by Kononen et al., (1998). A TMA is a slide containing multiple cores of several tissues on a single slide, allowing many tumours to be analysed in a short space of time. The TMAs that we used consisted of 1mm cores of tissue in triplicate of either thyroid tumours, or thyroid tumours with matched normal thyroid tissue. In total, we were able to analyse 68 normal thyroid specimens, 16 follicular adenomas, 10 atypical adenomas, 8 follicular carcinomas, 26 papillary carcinomas and 17 insular carcinomas. The TMA slides were stained and then scored by two people who were blinded to the pathology of each core (Elizabeth Ball and Professor Wynford-Thomas). The results of the immunostaining were sent to Brigitte Franc, who then sent us the key to identify the pathology of each core. Finally, the tissue cores were reviewed by both Brigitte Franc and Professor Wynford-Thomas, together with our immunohistochemistry results and the final pathology reports, and a couple of tissue cores that had been incorrectly diagnosed were identified and their histology re-confirmed.

## **2.2 Preparation of tissue sections**

I cut tissue sections from the formalin-fixed, paraffin-embedded tissue blocks using a microtome, after placing the blocks on ice for thirty minutes to aid cutting. After trimming the specimen block, I cut four micrometer-thick sections and floated them on a water-bath at 45°C using a paintbrush. Each section was lifted from the water-bath using a Surgipath Snowcoat X-tra™ pre-cleaned microslide (Surgipath Europe Limited), and incubated in an oven at 60°C overnight. I cut preliminary tissue sections from cervical carcinoma and thyroid follicular adenoma sample blocks that I used to validate the p16 antibody. Ruth Pitman (Electron Microscopy Laboratory, Histopathology department, University Hospital of Wales, Cardiff) cut all the remaining tissue sections.

In order to ensure accurate analysis of the antibodies used to immunostain a given tumour, only the minimum number of tissue sections was cut from a tissue block at a given time. This ensured that serial sections were stained, there was no wastage of tissue, and that the next time the tumour was studied with a different antibody group, the results could be accurately compared with those from the previous study. There would however be some loss of tumour and difference in microscopic appearance between research projects because the tumour blocks need to be trimmed prior to sectioning.

### **2.3 Preparation of cultured cells for p16 immunohistochemistry**

I used cultured Ori 3 cells (human thyroid follicular epithelial cells transfected with SV40) as a "biological" positive control for p16 immunostaining. These cells express SV40 large T, and therefore as expected express large quantities of p16, confirmed with Western blotting by Jones et al., 1996 and Lemoine et al., 1989. Cultured K1 cells (human papillary thyroid carcinoma cells expressing wild-type p53) were used as a "biological" negative control for p16 immunostaining. They have a p16 gene deletion, demonstrated by Wyllie et al., 1995 and Jones et al., 1996. The Ori 3 and K1 cells were grown in our laboratory under standard tissue culture conditions by Jane Bond (Henry Wellcome Building, University Hospital of Wales, Cardiff).

I fixed and embedded the Ori 3 and K1 cells in paraffin blocks according to the following established protocol described by Morgan (2001).

- Centrifuge  $10 \times 10^6$  cells, wash and re-suspend in 10ml 10% formalin in isotonic phosphate buffered saline (PBS, pH 7) and allow to sediment for 2 hours.
- Discard the excess formalin, place the cell volume (1-1.5ml) to a 1.5ml microcentrifuge tube, and allow to sediment for 20-30 minutes.
- Remove the formalin supernatant, leaving the cells in a 10-50 $\mu$ l volume.
- Remove the part of the barrel of a 1ml syringe to which a needle would be attached. The piston assembly of the syringe forms the base of the mould and will be used to extrude the set mould.

- Melt 4% agar (made in deionised water) in a water bath at 95°C and then transfer to a second water bath set at 60°C. Heat the microcentrifuge tube containing the cells in the same 60°C water bath using a foam float for 2-3 minutes.
- Transfer 20µl of agar to the tube using a plastic disposable pipette (diameter 3-4mm) that has been pre-warmed on a hot plate set at 45°C. Mix the suspension carefully with the same pipette by taking it up and extruding it twice into the same tube, whilst holding the tube in the water bath.
- Quickly transfer the quantity of agar-cell mix, without air bubbles, to the mould. Allow the agar to set at room temperature for five minutes and then place in a refrigerator (4°C) for a further 2-3 minutes.
- Extrude the agar from the mould using the syringe piston, and leave the plug in formalin-PBS for two hours at room temperature before placing in a standard paraffin-processing cassette.
- Dehydrate the plug in a step-wise fashion by transferring it to a 10% ethanol solution for two 30-minute washes, repeated with 20-100% ethanol solutions in steps of 10%. From 100% ethanol, process the plug through several changes of xylene over two hours and then process in paraffin, again with several changes.

The reason for processing the cells into paraffin blocks is that there is some controversy in the literature regarding the scoring of p16 immunohistochemistry (see Chapter 2.5.1). Some authors believe that only nuclear staining is a true indicator of p16 expression, whereas others believe that both nuclear and



cytoplasmic staining should be considered. Our Ori 3 cells in tissue culture show strong nuclear expression of p16, whilst a tissue block of cervical carcinoma (known p16-positive tissue, see Chapter 3.3.1) showed strong nuclear and cytoplasmic expression. I wanted to know whether the cytoplasmic expression of p16 was the result of tissue fixation and processing.

## **2.4 Immunohistochemistry Protocol**

### **2.4.1 Antibody selection**

I performed a literature search to find studies using immunohistochemistry to detect each of the proteins that I was interested in (p16, cyclin A, MCM2, p21, cyclin D1, HLA-DR, PKR, MxA). After critically reviewing the literature, I chose two or three antibodies specific for each protein and trialled them at varying concentrations, incubation temperatures and incubation times, with both positive and negative controls (where available), using the protocols most commonly used in the selected papers. Where external positive and negative control tissues were not available, I used antibodies that had been thoroughly trialled in the literature with Western blotting and immunohistochemistry (p21, cyclin D1). A summary of the anti-p16 antibody literature search is given in Table 2.1. Table 2.2 provides information regarding the suppliers of my selected antibodies, and Table 2.3 describes the immunohistochemistry protocols that I used.

Table 2.1 A table showing the results of the literature search for p16 immunohistochemistry protocols

Author	Ig Source	Ig Clone	Dilution	HMAR	Incubation
Geisler, 2002	Neomarkers	ZJ11	1:60	yes	4°C, O/N
Leversha, 2003	Neomarkers	16PO4	1:100	yes	RT, 60 mins
Geradts, 1995	Pharmingen	rabbit	1:400	no	4°C, O/N
Sakaguchi, 1996	Pharmingen	rabbit	1:800	no	4°C, O/N
Talve, 1997	Pharmingen	G175-405	1:100	yes	4°C, O/N
Hu, 1997	Pharmingen	G175-405	5µg/ml	yes	4°C, O/N
Takeuchi, 1997	Pharmingen	G175-405	5µg/ml	yes	RT, 60 mins
Emig, 1998	Pharmingen	G175-405	1:200	yes	RT, 30 mins
Matsuda, 1999	Pharmingen	rabbit	1:400	no	4°C, O/N
Niehans, 1999	Pharmingen	G175-405	2µg/ml	yes	RT, O/N
Geradts 2000	Pharmingen	G175-405	2µg/ml	yes	RT, O/N
Huang, 2000	Pharmingen	G175-405	1:100	yes	4°C, O/N
Hodges, 2002	Pharmingen	G175-405	1:25	yes	RT, 60 mins
Hilton, 2002	Pharmingen	rabbit	1:1000	yes	RT, O/N
Gerdes, 2002	Pharmingen	G175-405	1:50	yes	4°C, O/N
Murphy, 2003	Pharmingen	G175-405	1:75	yes	RT, 60 mins
Svensson, 2003	Pharmingen	G175-405	1:200	yes	RT, 60 mins
Lee, 1999	Oncogene	Ab-1	2µg/ml	yes	4°C, O/N
Mariatos, 2000	Santa Cruz	F-12	1:100	yes	4°C, O/N
Straume, 2000	Santa Cruz	SC-467	1:200	no	no
Cheng, 2003	Santa Cruz	F-12	1:50	yes	yes

Abbreviations used in table:

Ig – Antibody

HMAR – Heat-mediated antigen retrieval

RT – room temperature

O/N - overnight

Table 2.2 Manufacturer's details for the antibodies that I used

<b>Protein</b>	<b>Antibody Clone</b>	<b>Antibody Type</b>	<b>Manufacturer</b>
p16	G175-405	Mouse monoclonal	Pharmingen
MCM2	Anti-MCM2	Mouse monoclonal	GH Williams, UCL, London
cyclin A	NCL - cyclin A	Mouse monoclonal	Novocastra
p21	SX118	Mouse monoclonal	DAKO
cyclin D1	DCS-6	Mouse monoclonal	DAKO
HLA-DR	TAL.1B5	Mouse monoclonal	DAKO
PKR	sc-6282	Mouse monoclonal	Santa Cruz
MXA	n/a	Mouse monoclonal	G Kochs, Universität Freiburg, Germany

Table 2.3 The immunohistochemistry protocols for each antibody that I used

<b>Antibody</b>	<b>Antibody dilution</b>	<b>Peroxidase block</b>	<b>HMAR</b>	<b>EDTA pH</b>	<b>Incubation details</b>
p16	1:50	yes	yes	7.0	60 minutes at RT
MCM2	1:1000	yes	yes	7.0	60 minutes at RT
cyclin A	1:50	yes	yes	7.0	60 minutes at RT
p21	1:50	yes	yes	9.0	60 minutes at RT
cyclin D1	1:50	yes	yes	9.0	60 minutes at RT
HLA-DR	1:200	yes	yes	7.0	60 minutes at RT
MXA	1:1000	yes	no	n/a	60 minutes at RT
PKR	1:50	yes	yes	7.0	60 minutes at RT

Abbreviations used in table:

RT - room temperature

HMAR – Heat-mediated antigen retrieval

## 2.4.2 Rehydration of slides

### 2.4.2.1 Manual technique

During 2002 – 2005, I rehydrated the slides manually. Slides were immersed in three changes of xylene and a series of ethanol solutions (100%, 90%, 70%, 50% and 30%) for five minutes per solution, followed by immersion in a slow-running cold water bath for ten minutes. The alcohol and xylene solutions used for rehydration and dehydration of slides were freshly prepared on a weekly basis.

### 2.4.2.2 Automatic technique

During 2005 – 2006, I rehydrated the slides using the Shandon Varistain Gemini machine (Thermo Electron Corporation). In order to ensure that the machine produced identical results to the manual technique, I processed four separate sets of slides using both techniques. I used the cervical carcinoma (positive control for p16) and each technique produced identical results. I programmed the machine as follows: - 3 x 2 minutes xylene, 3 x 1 minute 100% ethanol, 3 x 1 minute running water bath, followed by distilled water for five minutes.

## 2.4.3 Heat-Mediated Antigen Retrieval (HMAR)

After rehydration of the slides, and prior to incubation with the primary antibody, I used heat-mediated antigen retrieval when staining for the following antibodies: p16, cyclin A, p21, cyclin D1, HLA-DR and PKR. For p16, cyclin A, HLA-DR and PKR staining, the slides were inserted into a plastic slide rack, placed in a plastic jug containing one litre of 10mM EDTA at pH 7.0 and covered with cling-film wrap. The jug was micro-waved in a microwave oven for

20 minutes at 800W. For p21 and cyclin D1, the EDTA solution used had a pH of 9.0 instead of 7.0. HMAR, initially described by Shi, S.R. et al., (1991) is a technique used to improve the reactivity of antigen epitopes that are masked during the process of formalin fixation, and most antibody–antigen reactions can be enhanced by this method (McQuaid et al., 1995).

#### 2.4.4 Pre-treatment with a peroxidase-blocking solution

I pre-treated all slides with a peroxidase-blocking solution (DakoCytomation) prior to primary antibody incubation to minimise background staining. Each tissue section was outlined using a water-limiting pen (DAKO) to obtain more uniform immunohistochemical staining. Each slide was incubated with 200µl of the solution, and then rinsed with a buffer solution (DakoCytomation). Horseradish peroxidase is the most commonly used enzyme label, and is visualised using diaminobenzidine, which precipitates in a brown reaction end product, and it is this brown reaction that is scored. A peroxidase-blocking solution ensures that the brown reaction is not a product of endogenous peroxidase in the tissue.

#### 2.4.5 Immunohistochemistry protocols

##### 2.4.5.1 Manual technique

The initial p16, cyclin A, MCM2, p21 and cyclin D1 work during 2002 – 2005 was done by hand. After HMAR and incubation with the peroxidase-blocking solution, the primary antibody was diluted to the desired concentration using DAKO antibody diluent (DakoCytomation). I then incubated the slides with 200µl of the diluted antibody for 60 minutes at room temperature in a humidified slide chamber. Separate slides containing tissue from each tumour

studied were also incubated with mouse prolactin antibody and antibody diluent as negative controls, and a section of a known positive control tissue was tested in each batch of slides (apart from p21 and cyclin D1 staining). Finally, the slides were rinsed in three coplin jars containing a buffer solution (DakoCytomation), for five minutes per rinse.

The secondary antibody used was the Envision<sup>+</sup>™ solution (DakoCytomation). The Envision<sup>+</sup> system is based on a horseradish peroxidase-labelled polymer which is conjugated with secondary antibodies. The labelled polymer does not contain biotin or avidin, and therefore non-specific staining resulting from endogenous biotin is eliminated or significantly reduced (Sabattini et al., 1998). Thyroid tissue has a considerable amount of endogenous biotin, and therefore this system greatly reduces background staining of biotin. I incubated the slides with 200µl of the Envision<sup>+</sup>™ solution for 30 minutes at room temperature in a humidified slide chamber prior to rinsing in buffer solution (DakoCytomation) as before. The slides were then incubated with 200 µl of diaminobenzidine (DAB) solution (DakoCytomation) for five minutes, and rinsed with distilled water for five minutes.

#### 2.4.5.2 Automatic technique

The interferon-based work (HLA-DR, PKR, MxA) and all follow-up p16, cyclin A, MCM2, p21 and cyclin D1 work in 2005-2006 was stained using the Dako Autostainer Plus machine (DakoCytomation). This technique was trialled several times against the manual technique using p16 on the positive cervical control tissue, and both techniques gave identical staining patterns. Details of the programming are listed in Appendix III.

## 2.4.6 Dehydration of slides and haematoxylin counter-staining

### 2.4.6.1 Manual technique

For the initial p16, MCM2, cyclin A, p21 and cyclin D work, I dehydrated the slides manually. After exposure to filtered Mayer's haematoxylin for ten seconds the slides were placed in a slow running water bath for ten minutes, and then taken through a series of five graduated ethanol solutions of increasing strength (from 30% to 100%) and three changes of xylene, for five minutes per solution. The slides were then mounted with coverslips using a mounting solution (DakoCytomation).

### 2.4.6.2 Automatic technique

For the interferon-based work (HLA-DR, PKR, and MxA) and all sections stained during 2005 - 2006, I dehydrated the slides using the Shandon Varistain Gemini machine (Thermo Electron Corporation). I validated this technique by performing several runs using p16 staining with the positive cervical control against the manual technique, and each protocol gave comparable results. The machine was programmed as follows: - 1 minute slow running water, 10 seconds in filtered Haematoxylin solution, 10 minutes slow running water, 2 x 2 minutes 100% ethanol, 3 x 2 minutes xylene. The slides were mounted with coverslips using DAKO mounting solution (DakoCytomation).

## **2.5 Scoring of antibody expression**

### **2.5.1 p16**

There are three different ways to interpret the results of immunohistochemical staining. The first method is to record the percentage area of tissue stained, as used by Taga et al.,(1997), Emig et al., (1998), Huang et al., (2000), Hilton et al., (2002), and Murphy et al., (2003). This simplistic method makes no allowances for differences in p16 staining intensity or heterogeneity within a sample, and could lead to false conclusions when interpreting results. For antibodies such as cyclin A where most tissues have an 'all-or-nothing' staining intensity, this scoring method is appropriate.

A second scoring system used records the intensity of staining, as used by Sakaguchi et al., (1996), Matsuda et al., (1999), and Geradts et al., (2000). This is another simple method that attributes a score for weak/absent, moderate and strong staining intensity, but again could lead to false conclusions. It gives no information regarding the percentage of tumour that has positive staining, and makes it difficult to compare a tumour with 5% cells with a high score, and a tumour with 100% cells with a low score.

The third method of immunohistochemical scoring records the staining index, as used by Straume et al., (2000), and Pizzi et al., (2003). The staining index is calculated by multiplying a score given for the intensity of staining with a score for the percentage of cells stained. It is a more accurate representation of the true staining picture, and does make some allowance for heterogeneity of both the area of staining and the intensity of staining within a sample, although it too has some limitations. A tumour with a mosaic distribution of staining will still be



represented by a single score, although this is a more accurate representation when compared with the previous two scoring systems. Therefore, care has to be taken when depicting results.

Finally, many papers quote the mean score for a given tumour group. This will give a reasonable representation of the scores for the tumours in that group, if the scores are normally distributed. However, I noted that this was often not the case, and therefore analysed the mean and median scores, as well as the range of scores, to get the most accurate interpretation of my results.

There is some discrepancy with regards to what is a positive result for p16 expression. In the studies that scored a variety of human tumours on the basis of area, some papers accredited tumours with a positive result if more than 10% of the cells showed staining (Taga et al., 1997; Lee et al., 1999; Huang et al., 2000; Cheng et al., 2003), whilst others used different cut-off points, ranging from 1% (Shi et al., 2000), to 5% (Hu et al., 1997; Gerdes et al., 2002) and 80% (Takeuchi et al., 1997). The various cut-offs also depended on whether the normal tissue studied was positive or negative for p16. With any scoring system, the difficulty lies in deciding when you accept a “weakly positive” or a “weakly negative” result as a valid finding, and what score constitutes a positive result.

We noted that normal thyroid tissue is negative for p16, and having observed heterogeneous staining in the majority of tumour sections, decided that scoring both the area and the intensity of staining would give the most accurate

representation of the immunohistological picture, rather than an arbitrary cut-off value for negative and positive p16 expression.

Secondly, there is not a consensus in the literature concerning whether cytoplasmic staining is a true positive result for p16 expression. The majority of papers discounted cytoplasmic staining as non-specific staining (Niehans et al., 1999; Shi et al., 2000; Straume et al., 2000; Pizzi et al., 2003), and only considered nuclear staining above background cytoplasmic staining as a positive result. However, there were a group of papers that did count cytoplasmic staining as a true positive result (Papdimitrakopoulou et al., 1997; Murphy et al., 2003; Svensson et al., 2003). Svensson reasoned that because the majority of cells with cytoplasmic staining of p16 also had nuclear p16 staining, than the cytoplasmic staining indicated true p16 reactivity.

Immunocytochemistry performed in our laboratory on Ori 3 cells demonstrated strong positive nuclear staining. However, when the Ori 3 cells were processed into paraffin blocks to resemble tissue, both the nucleus and cytoplasm were stained (Chapter 3, Figure 3.1A). I therefore attributed both cytoplasmic and nuclear staining as a positive result.

Two independent observers (blinded to the histological diagnosis) scored all slides, as previously described. For the TMA sections, five hundred cells per tissue core were counted. All three cores were scored for every tumour represented on the TMA slides, and an average I.D. score was calculated for each tumour. For the remaining tissue sections, five hundred cells representative of the tumour were counted. The cells were assigned to an

intensity category of 0 (absent), 1 (weak), 2 (moderate), or 3 (strong). The percentage of cells in each intensity category was determined as  $N_0$ ,  $N_1$ ,  $N_2$ , and  $N_3$  respectively.

A weighted average intensity distribution (I.D.) score was calculated -

$$\text{I.D.} = [(N_0 \times 0) + (N_1 \times 1) + (N_2 \times 2) + (N_3 \times 3)] / 100$$

The I.D. score therefore ranged from 0 (absent staining in all cells) to a maximum of 3 (100% cells having a staining intensity of 3).

### 2.5.2 MCM2, cyclin A, p21

Since no background cytoplasmic staining was seen, only nuclear staining was taken as a positive result. There was no obvious gradation of nuclear intensity, with the vast majority of positive nuclei having the same intensity of staining. For the TMAs, five hundred cells per tissue core were counted. For the remaining tissue sections, five hundred cells representative of the tumour were counted, and the percentage of positive-staining nuclei (labelling index, L.I.) calculated.

### 2.5.3 cyclin D1

I observed both cytoplasmic and nuclear staining of cyclin D1 in the thyroid tumours studied. Each tissue section was scored using the Intensity Distribution score, by calculating the percentage of cells with positive staining, and the intensity of the staining, using the calculation given in 2.5.1. Five hundred cells representative of each tumour were counted.

#### 2.5.4 HLA-DR, PKR, MxA

We observed primarily cytoplasmic staining in this group of antibodies, which was generally of a uniform intensity. I counted five hundred cells representative of the tumour. However, the percentage of positively scoring cells for HLA-DR was generally in single figures, therefore I recorded the percentage of positive cells, and the intensity of staining in those cells (weak, moderate, strong) where appropriate.

### 2.6 Statistical analysis

All statistical analyses were performed using SPSS version 11.0 software (SPSS Inc., Chicago, IL). A p-value of <0.05 was taken to indicate a statistically significant relationship.

### 2.7 Photography

All slides were photographed using an Olympus BX51 microscope (Olympus UK Ltd., London) and a Leica DFC 320 camera, using Leica IM50 Image Manager Software (Leica Microsystems UK Ltd., Milton Keynes).

### 2.8 Scale bars

Photographs were taken of a graticule graduated in  $\mu\text{ms}$  using the 4x, 10x and 20x optics – the same magnifications at which my photographs were taken, using the same pixel density as the actual slide photographs. I made an Adobe Photoshop file with a black bar to correlate with 200  $\mu\text{ms}$  in length, and this was copied and pasted directly onto the Adobe photoshop pictures of the slides, correlating the 4x bar / 4x photograph, 10x bar / 10x photograph, 20x bar / 20x photograph.

## CHAPTER 3

### AN IMMUNOHISTOCHEMICAL STUDY OF p16<sup>INK4a</sup> EXPRESSION IN MULTISTEP THYROID TUMORIGENESIS

#### 3.1 Introduction

The first aim of this chapter is to establish a protocol for p16 immunohistochemistry and validate an anti-p16 antibody, using “biological” positive and negative controls. The second major aim is to analyse the immunohistochemical expression of p16 in normal thyroid tissue and at every stage in thyroid tumorigenesis, including follicular and atypical adenomas, well-differentiated (micro-papillary, papillary and follicular) carcinomas, and poorly-differentiated (insular and anaplastic) carcinomas. This will enable me to correlate the in vivo thyroid staining with the in vitro results produced in our laboratory using an established thyrocyte tumour model. This research will provide new information regarding p16 expression in thyroid tumorigenesis, and also help to confirm whether our thyrocyte culture model is indeed a valid representation of early thyroid tumorigenesis. The third aim of this chapter is to assess the proliferation of the benign and malignant thyroid tumours using anti-MCM2 and anti-cyclin A antibodies, and compare this with the p16 status of each tumour.

A key requirement for a cell to become neoplastic is to escape from the normal controls of cell proliferation (Hanahan and Weinberg, 2000). One such control that appears to be critical in limiting tumour development in many cell types operates through the tumour suppressor gene p16<sup>INK4A</sup>. p16 is a tumour

suppressor gene and was first identified by Serrano et al., (1993). This protein is a cyclin-dependent kinase inhibitor, which acts as a negative regulator of cell cycle progression (Koh et al., 1995; Lukas et al., 1995). The p16 protein binds and inactivates cyclin-dependent kinases (cdks) 4 and 6, which are the catalytic partners for cyclins D1, D2 and D3.

When p16 binds to cdk4 and 6, it blocks the cyclin-dependent phosphorylation of the Retinoblastoma gene product, Rb (Sherr, 1996) and thus blocks the exit from the G1 phase of the cell cycle by preventing the initiation of DNA replication (Ohtani et al., 2004). Consistent with this, loss of p16 activity by gene deletion, mutation or transcriptional inactivation has now been found in a wide range of human cancers of both epithelial and mesenchymal origin (Nobori et al., 1994; Okamoto et al., 1994; Hirama and Koeffler, 1995; Sherr, 1996; Talve et al., 1997, Ruas and Peters, 1998), at a frequency rivalling that of p53 mutation (Baylin et al., 1998).

The RAS family of GTPase proteins are involved in the regulation of cell growth and differentiation by signal transduction (Crespo and Leon, 2000). Mutations of the RAS oncogene family occur at a high frequency in several human epithelial tumour types, notably those of the pancreas, colon and thyroid (Bos, 1989; Jones et al., 2000; Skinner et al., 2004). RAS oncogene mutations were first reported in thyroid tumours in 1988 (Lemoine et al., 1988) and a meta-analysis by Vasko et al., (2003) showed that RAS mutations are more frequent in follicular compared with papillary thyroid tumours. The mutations may also be a marker for aggressive tumour behaviour, as suggested by Garcia-Rostan et al., (2003).

RAS oncogene activation has been shown to be an early event in thyroid tumorigenesis (Lemoine et al., 1989; Namba et al., 1990b). Our laboratory has obtained strong experimental support for this using retroviral gene transfer studies in vitro. Whereas normal thyrocytes exhibit a very low proliferative rate, RAS oncogene activation drives proliferation (Bond et al., 2004), in sharp contrast to its growth-inhibitory effect on mesenchymal cells. The resulting epithelial clones retain thyroid-specific gene expression and display a phenotype consistent with that of a follicular adenoma.

Thyrocyte proliferation does not continue indefinitely however, terminating in a state resembling replicative senescence. Immunocytochemical and Western blot analyses showed that expression of the cyclin-dependent kinase inhibitor p16<sup>INK4a</sup> increases in 'late-stage' thyrocyte colonies, and this is closely correlated with a decrease in proliferative rate, therefore suggesting that p16 expression has a role in limiting oncogene-driven clonal expansion in this human epithelial tumour model.

In vivo, the vast majority of thyroid adenomas also appear to reach a self-limiting quiescent end-point, which is often ascribed to insufficient ability to promote new blood vessel formation and/or mechanical restriction by the tumour capsule. The similarity between this self-limiting growth in vivo and our observations in tissue culture however raises the alternative possibility that a cell-intrinsic mechanism independent of tissue architecture is responsible, and that this may be mediated at least partly by up-regulation of p16 expression.

I hypothesized from our thyrocyte results that p16 immunohistochemical expression would increase in vivo at the follicular adenoma stage, and further, that the escape from self-limiting growth that occurs in follicular and papillary cancers would be accompanied by a loss of p16 expression. I tested this hypothesis by performing immunohistochemical analysis on multiple samples of thyroid tissue, at multiple stages of thyroid tumorigenesis.



## 3.2 Method

### 3.2.1 Immunohistochemistry

I performed immunohistochemistry on formalin-fixed, paraffin-embedded tissue sections and tissue microarrays (TMAs) following heat-mediated antigen retrieval in 10mM EDTA pH 7.0, using a microwave (20 minutes at 800W). I pre-treated the slides with a DAKO peroxidase "blocking" solution (DakoCytomation) prior to incubation (one hour at room temperature) with one of the following antibodies: -

- (i) mouse monoclonal anti-p16 antibody clone G175-405, (BD Biosciences Pharmingen, San Diego, CA, USA) at a dilution of 1:50 (10 $\mu$ g/ml)
- (ii) mouse monoclonal anti-MCM2 antibody (kindly donated by Prof. GH Williams, Dept of Pathology, University College London, London), at a dilution of 1:1000
- (iii) mouse monoclonal anti-cyclin A antibody (clone NCL-Cyclin A, Novacastra Labs Ltd, Newcastle-upon-Tyne, UK) at a dilution of 1:50

Secondary amplification was accomplished using the DAKO Envision<sup>+</sup>™ kit (DakoCytomation), and I visualised antibody binding using DAB chromogen (DakoCytomation), followed by counterstaining with haematoxylin.

### 3.2.2 Scoring of slides

Two independent observers (blinded to the histological diagnosis) scored all the slides (EB and DWT). We scored the three TMA cores representing each tumour, and calculated the average score for each tumour. This average score was used for statistical analysis.

### 3.2.2.1 p16 analysis

The observers assigned five hundred cells per sample to an intensity category of 0 (absent), 1 (weak), 2 (moderate), or 3 (strong) and the percentage of cells in each intensity category was determined as  $N_0$ ,  $N_1$ ,  $N_2$ , and  $N_3$  respectively. A weighted average score was then calculated (Intensity Distribution, I.D. score, range 0 - 3) as follows:-

$$\text{I.D.} = [(N_0 \times 0) + (N_1 \times 1) + (N_2 \times 2) + (N_3 \times 3)] / 100$$

### 3.2.2.2 Cyclin A and MCM2 analysis

The observers counted five hundred cells per sample, and calculated the percentage of positive-staining nuclei (labelling index, L.I.).

### 3.2.3 Statistical analysis

I performed all statistical analyses using SPSS version 11.0 software (SPSS Inc., Chicago, IL). I used the Mann-Whitney U test to calculate p-values for differences between thyroid tumours, and the Spearman rank correlation coefficient to correlate cyclin A and p16 values in a given thyroid tumour set.

### 3.3 Results

#### 3.3.1 anti-p16 antibody validation

I performed a literature search to identify anti-p16 antibodies that had been previously used for immunohistochemical analysis of formalin-fixed, paraffin-embedded tissues (Table 2.1). After trialling both the Pharmingen rabbit polyclonal and Pharmingen mouse monoclonal antibodies, I selected the mouse monoclonal anti-p16 antibody clone G175-405 (Pharmingen) at a dilution of 1:50 (10mcg/ml). At this dilution, the monoclonal anti-p16 antibody produced the most consistent, reproducible results, with negligible background staining.

I fixed and embedded Ori 3 cells in paraffin blocks to mimic tissue (Morgan, 2001) and used them as a "biological" positive control. These cells express SV40 large T, and therefore as expected express large quantities of p16, confirmed by Western blotting (Jones et al., 1996; Lemoine et al., 1989). I also similarly fixed and embedded K1 cells, which have been shown to have a p16 gene deletion (Wyllie et al., 1995; Jones et al., 1996) to use as a "biological" negative control. A cervical carcinoma-in-situ was used as an additional positive control tissue (Murphy et al., 2003). For additional negative controls, I also stained slides with isotype-matched mouse monoclonal anti-prolactin antibody (Pharmingen), at a concentration of 1:50, and antibody diluent solution (DAKO).

The Ori 3 cells showed a strong cytoplasmic and nuclear reaction at an anti-p16 antibody dilution of 1:50 (Figure 3.1A). The K1 cells did not demonstrate a positive reaction (Figure 3.2A). The cervical carcinoma showed strong positive

staining in the neoplastic area only, with absent staining in the surrounding normal cervical tissue (Figure 3.3). Neither the Ori 3 or K1 cell pellets (Figure 3.1B, 3.2B), nor the cervical carcinoma demonstrate a positive reaction when stained with the anti-prolactin antibody or the antibody diluent.

I did however observe a reduction in the intensity of staining of the cervical tissue. This was proportional to the time delay between preparing and staining each slide. I noticed that the longer the interval, the greater the reduction in staining intensity (Figure 3.4), and subsequently all slides were stained with anti-p16 antibody within one week from the date that the slide was prepared.

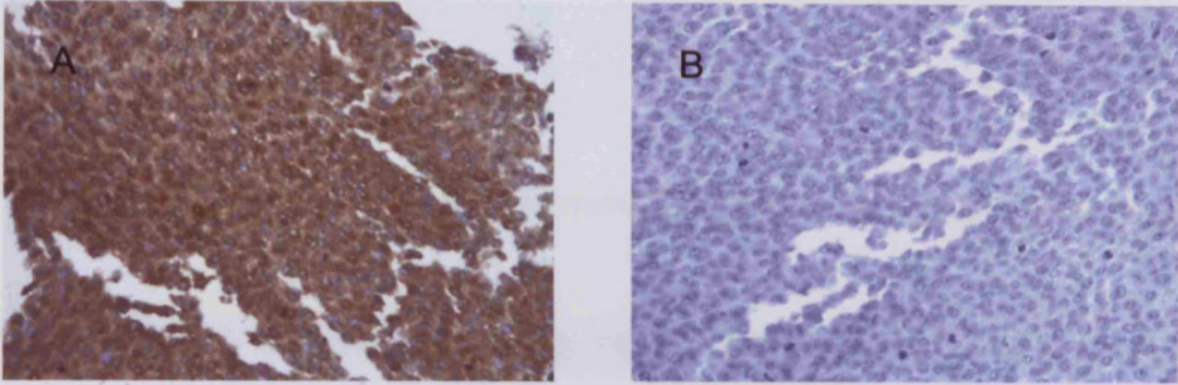


Figure 3.1 A Immunohistochemical staining with anti-p16 antibody of an Ori 3 cell pellet showing a strong positive cytoplasmic and nuclear reaction.

Figure 3.1 B Immunohistochemical staining with antibody diluent of an Ori 3 cell pellet showing the absence of a positive reaction.

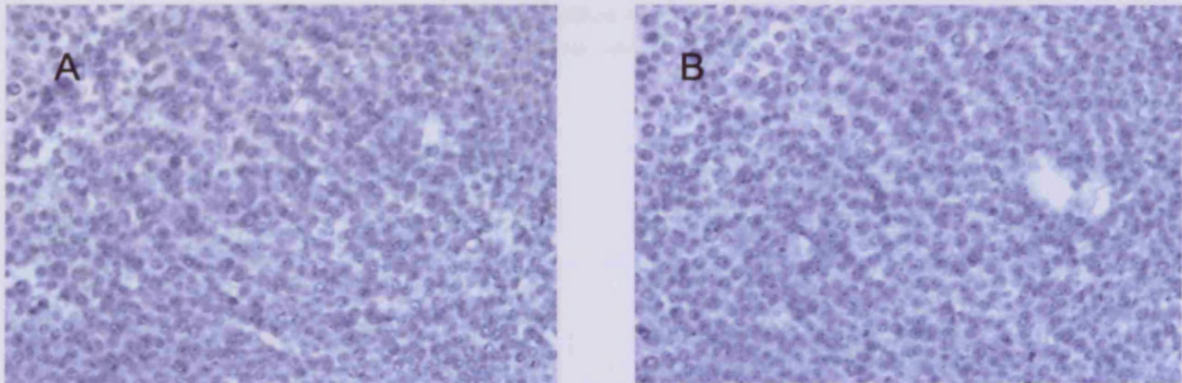


Figure 3.2 A Immunohistochemical staining with anti-p16 antibody of a K1 cell pellet showing the absence of a positive reaction.

Figure 3.2 B Immunohistochemical staining with antibody diluent of a K1 cell pellet showing the absence of a positive reaction.



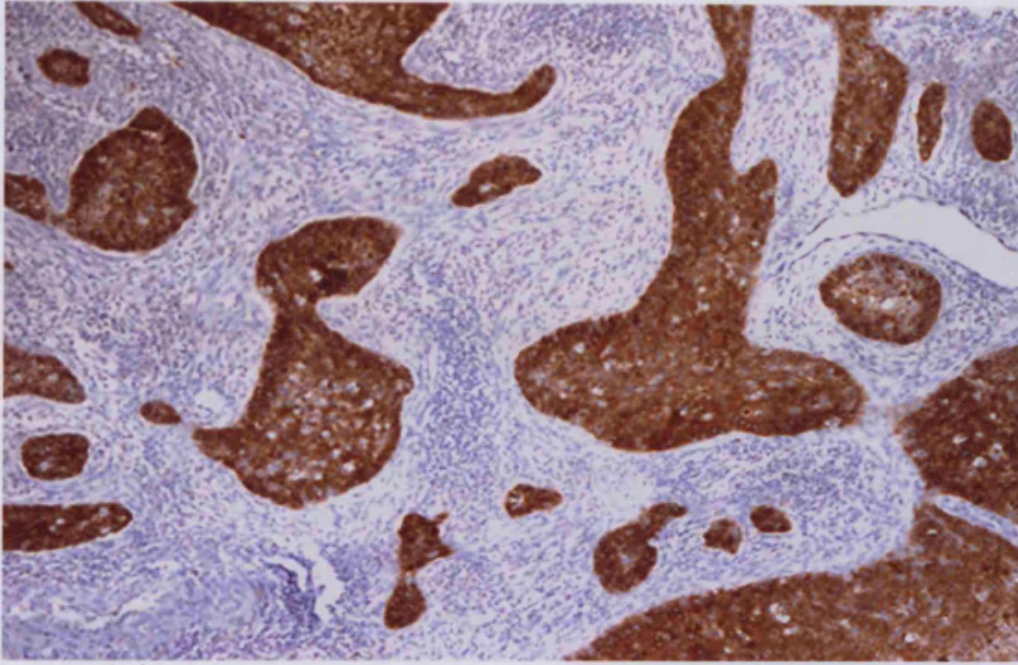


Figure 3.3 Immunohistochemical staining with anti-p16 antibody of an HPV-positive cervical carcinoma showing a strong positive reaction in the carcinoma, and a negative reaction in the surrounding normal cervical tissue.

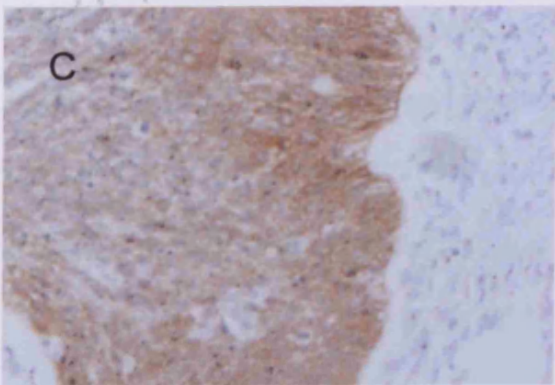
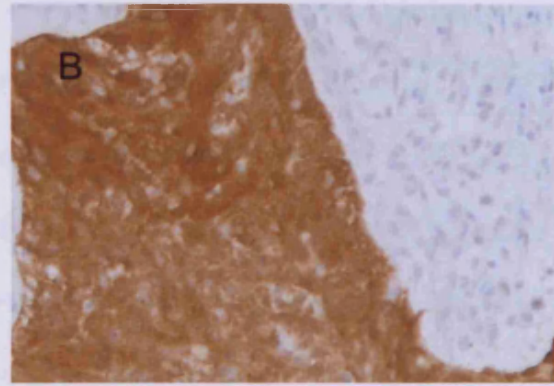
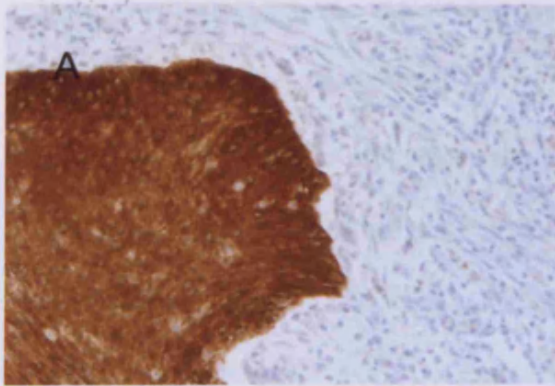


Figure 3.4 Immunohistochemical staining with anti-p16 antibody of an HPV-positive cervical carcinoma demonstrating the reduction in staining intensity proportional to the time interval between slide preparation and slide staining.

A = 1 day, B = 2 weeks, C = 2 months.

### 3.3.2 p16 expression

#### 3.3.2.1 Normal thyroid

All four normal thyroid tissue sections were negative for p16 expression (Fig 3.5 A, B). There were 68 normal thyroid tissue TMA cores, and the vast majority also showed no immunostaining for p16 (median I.D. score 0.05, range 0 - 1.7) (Fig 3.5 C, D). There were four cases with p16 I.D. scores greater than 1.5 times the inter-quartile range in this group, and the pathology report for these cases described the thyroid sections as 'not cancer', compared to the remainder of cases which were described as normal thyroid tissue.

#### 3.3.2.2 Follicular adenoma

All ten follicular adenoma tissue samples showed an up-regulation of p16 staining when compared to normal thyroid tissue (median I.D. score 0.55, range 0.2 – 1.4). The adenomas could be divided into two groups. Five (50%) cases had weak p16 staining, and five (50%) cases had a moderate intensity of staining (Figure 3.6 A, B). There were sixteen follicular adenoma TMA cores, and as predicted by our hypothesis, there was an increase in p16 staining in this group when compared to normal thyroid tissue, with approximately 50% of cases showing weak to moderate staining in the majority of cells (Figure 3.7 A, B), (median I.D. score 0.45, range 0 - 1.9). This is a statistically significant increase compared to the normal group ( $p = 0.017$ ).

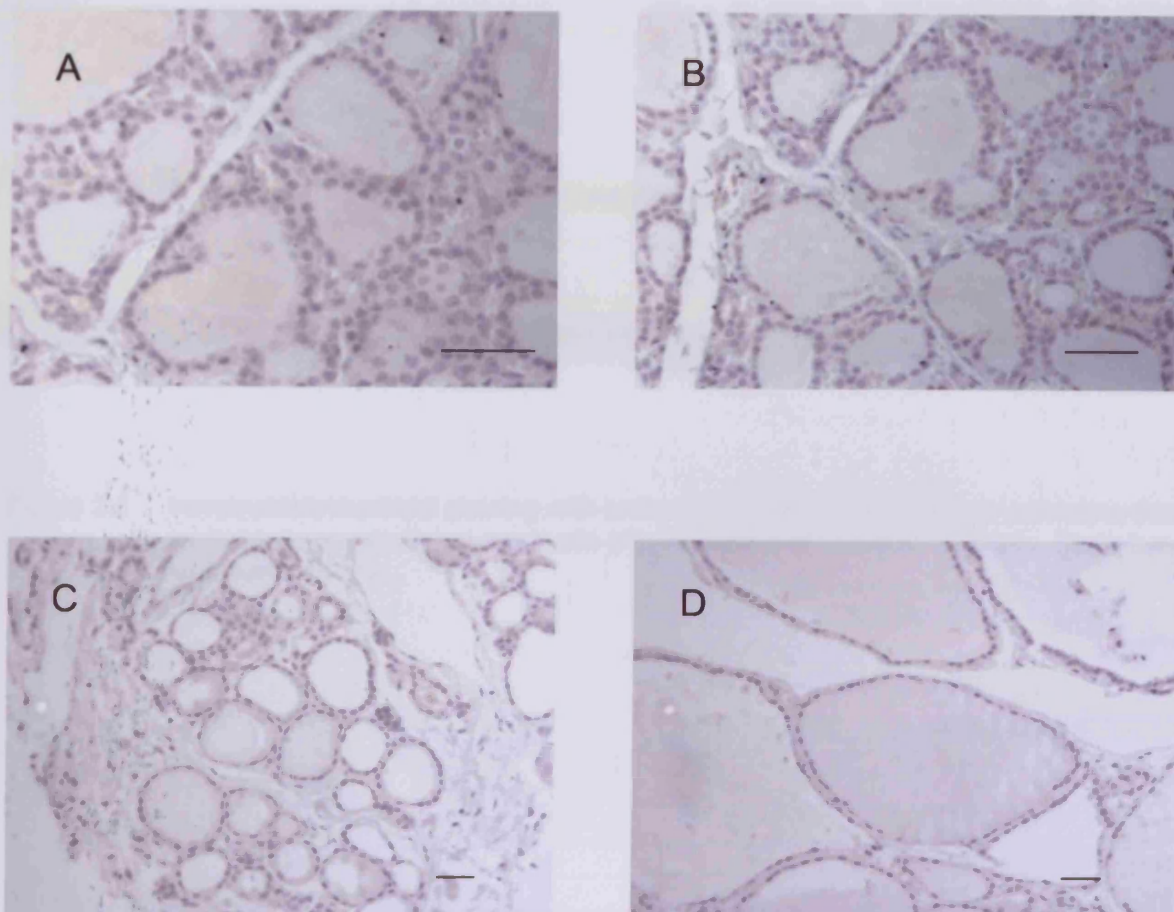


Figure 3.5 Immunohistochemical staining with anti-p16 antibody of two normal thyroid tissue sections (A,B) and two TMA cores (C,D) demonstrating the absence of a positive reaction. Scale bar represents 200 $\mu$ m.



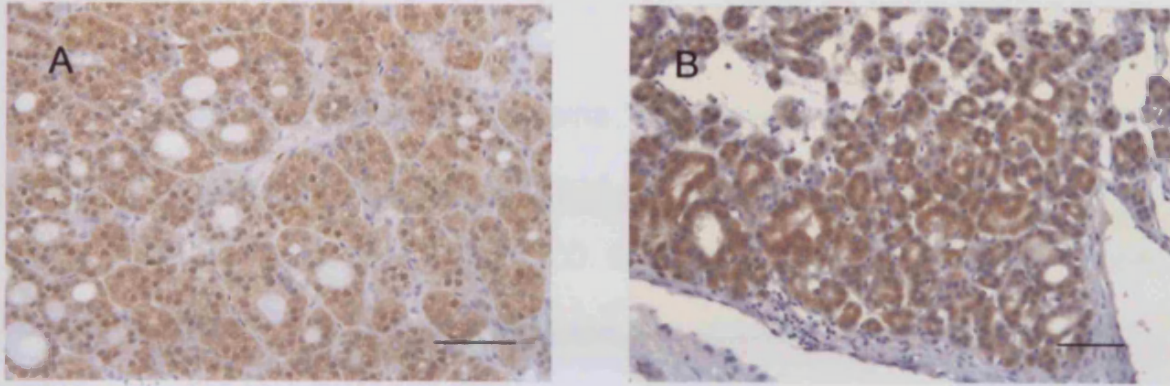


Figure 3.6 Immunohistochemical staining with anti-p16 antibody of two follicular adenoma tissue sections demonstrating a moderate (A) and strong (B) positive reaction. Scale bar represents 200 $\mu$ m.

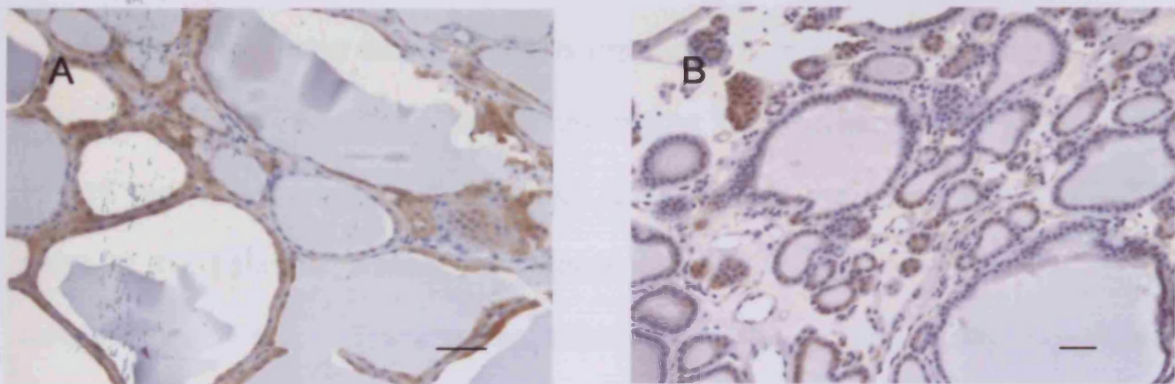


Figure 3.7 Immunohistochemical staining with anti-p16 antibody of two follicular adenoma tissue TMA cores demonstrating a positive reaction. Scale bar represents 200 $\mu$ m.

### 3.3.2.3 Atypical adenoma

A total of ten atypical adenoma TMA cores were stained and these tumours also showed an increase in p16 expression when compared to normal thyroid tissue (Figure 3.8), (median I.D. score 1.6, range 0.25 - 2.95). Despite the wide spread of values, this increase was statistically significant ( $p < 0.001$ ) when compared to normal thyroid tissue.

### 3.3.2.4 Follicular carcinoma

Eight follicular carcinoma tissue sections were stained, and all of these cancers showed a further up-regulation in p16 expression when compared to the follicular adenoma tissue sections (median I.D. score 1.5, range 1.0 – 2.4) (Figure 3.9 A, B). All eight follicular carcinoma TMA cores showed an increase in p16 expression, and this was also greater than the up-regulation of p16 seen in the follicular adenomas (Figure 3.9 C, D) (median I.D. score 1.00, range 0.1 - 1.95). This up-regulation was also a statistically significant increase ( $p < 0.001$ ) compared to the normal group.

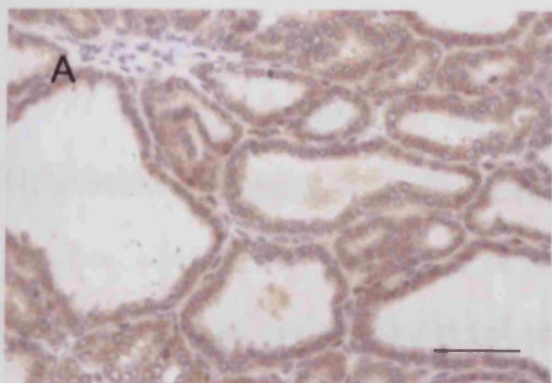


Figure 3.8 Immunohistochemical staining with anti-p16 antibody of an atypical adenoma TMA core demonstrating a moderate staining reaction. Scale bar represents 200 $\mu$ m.

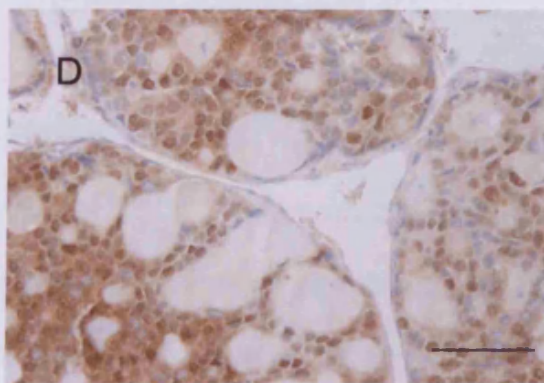
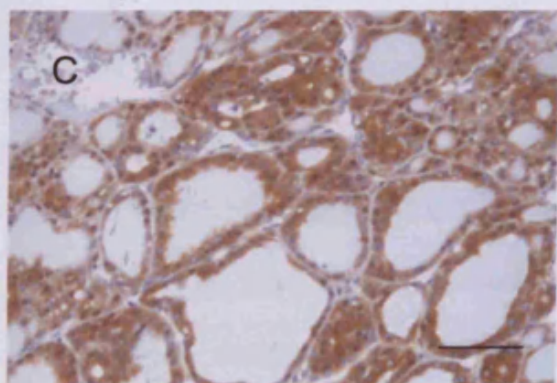
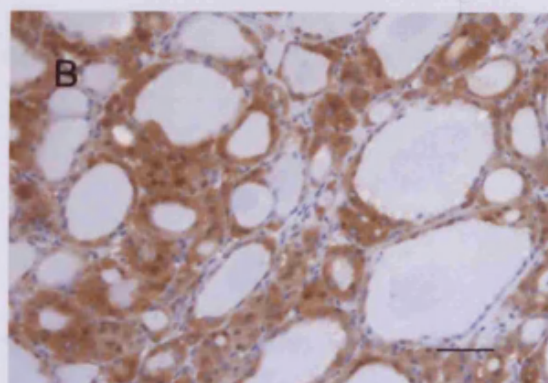
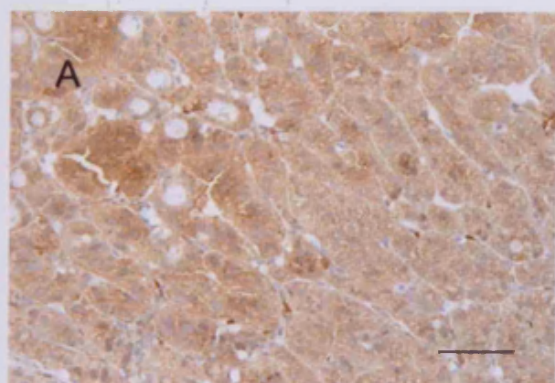


Figure 3.9 Immunohistochemical staining with anti-p16 antibody of two follicular carcinoma tissue sections (A,B) and two TMA cores (C,D) demonstrating a moderate / strong positive reaction. Scale bar represents 200 $\mu$ m.

### 3.3.2.5 Papillary carcinoma

Two micro-papillary carcinomas showed an up-regulation of p16 expression (Figure 3.10 A, B). Eight papillary carcinoma tissue sections were stained, and these also demonstrated an up-regulation of p16 expression when compared to normal thyroid (median I.D. score 1.7, range 1.1 – 2.7). Six cancers showed intense p16 staining in 60-80% cells (Figure 3.12 A), and two showed weak / moderate staining in 50-70% cells. I stained 26 papillary carcinomas TMA cores, and this tumour group also showed a considerable up-regulation of p16 expression when compared to normal thyroid (median I.D. score 0.4, range 0-2.4), (Fig 3.12B), and this was statistically significant ( $p=0.001$ ). A metastatic deposit from a papillary cancer also showed an up-regulation of p16 over-expression (Figure 3.13 A).

### 3.3.2.6 Insular carcinoma

Six insular carcinoma tissue sections were stained, and these could be divided into two groups; three tumours showed intense p16 staining, (Fig 3.14 A1) and three tumours did not have p16 expression (Figure 3.14 B1, C1). I stained 17 insular carcinoma TMA cores, and as a whole, this tumour group showed an up-regulation of p16 staining when compared to normal thyroid tissue (median I.D. score 1.00, range 0 - 2.7,  $p<0.001$ ). Although the median p16 I.D. score was similar to that of the follicular cancer group, there was a much wider range of values. Approximately one quarter of the insular carcinomas had intensely positive p16 staining (Figure 3.17 E1), half had weak to moderate p16 staining and the final quarter did not show any p16 expression (Figure 3.17 F1).



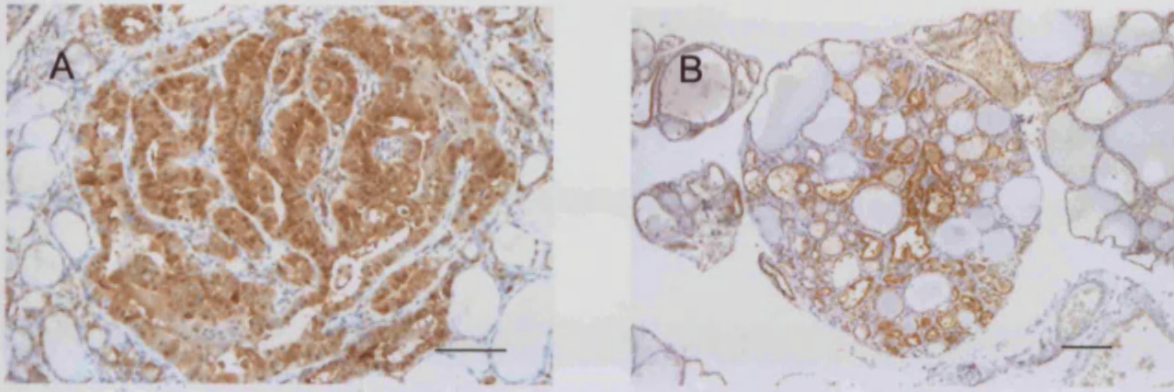


Figure 3.10 Immunohistochemical staining with anti-p16 antibody of two micro-papillary thyroid carcinomas, demonstrating a strong positive reaction. Scale bar represents 200µm.

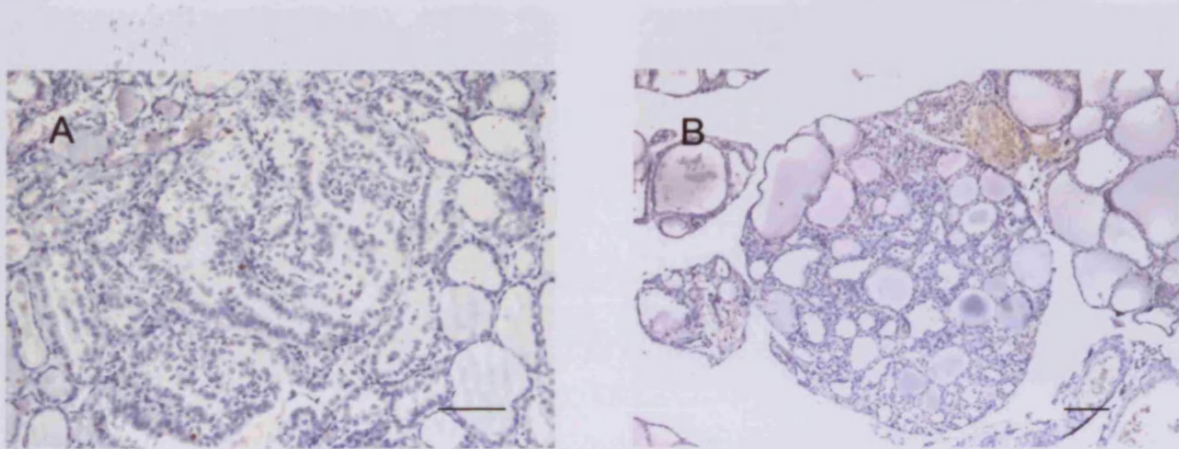


Figure 3.11 Immunohistochemical staining with anti-cyclin A antibody of two micro-papillary thyroid carcinomas. Case A shows two positive nuclei, and case B does not show a positive reaction. Scale bar represents 200µm.

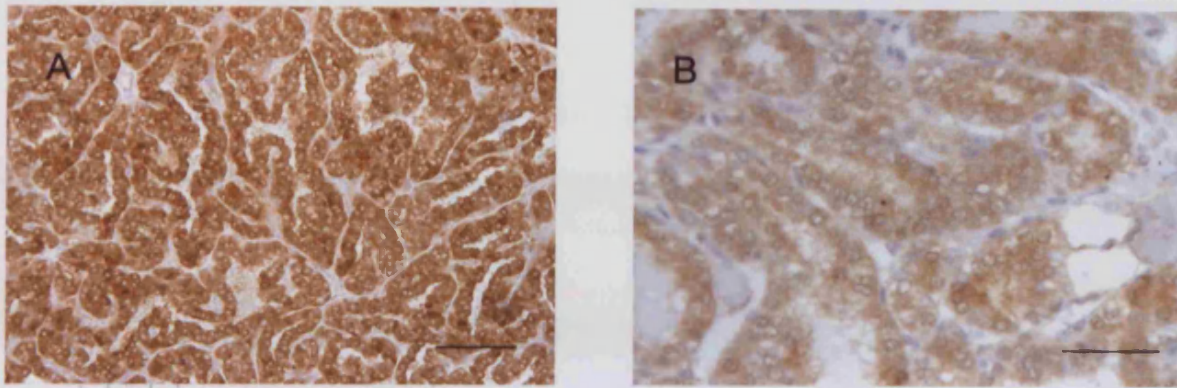


Figure 3.12 Immunohistochemical staining with anti-p16 antibody of a papillary carcinoma tissue section (A) and a papillary carcinoma TMA core (B) demonstrating a strong positive reaction. Scale bar represents 200 $\mu$ m.

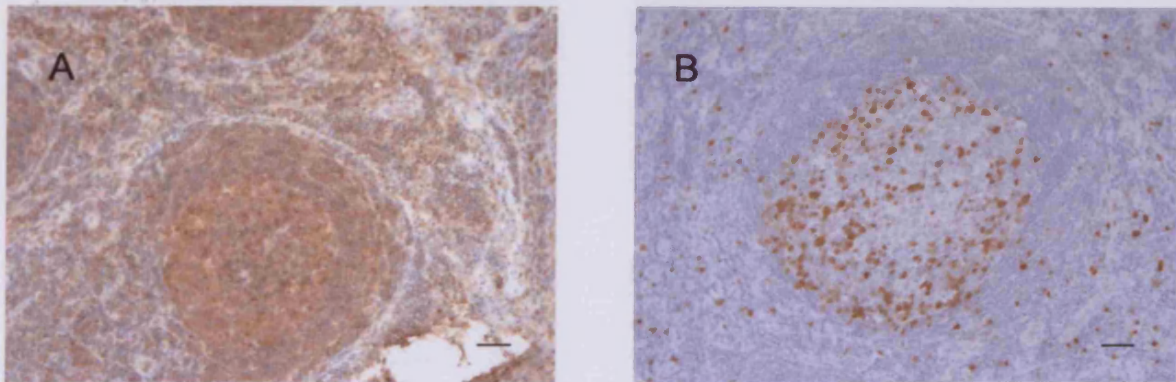


Figure 3.13 Immunohistochemical staining with anti-p16 antibody (A) and anti-cyclin A antibody (B) of a metastatic deposit from a papillary carcinoma, showing up-regulation of both p16 and cyclin A expression. Scale bar represents 200 $\mu$ m.



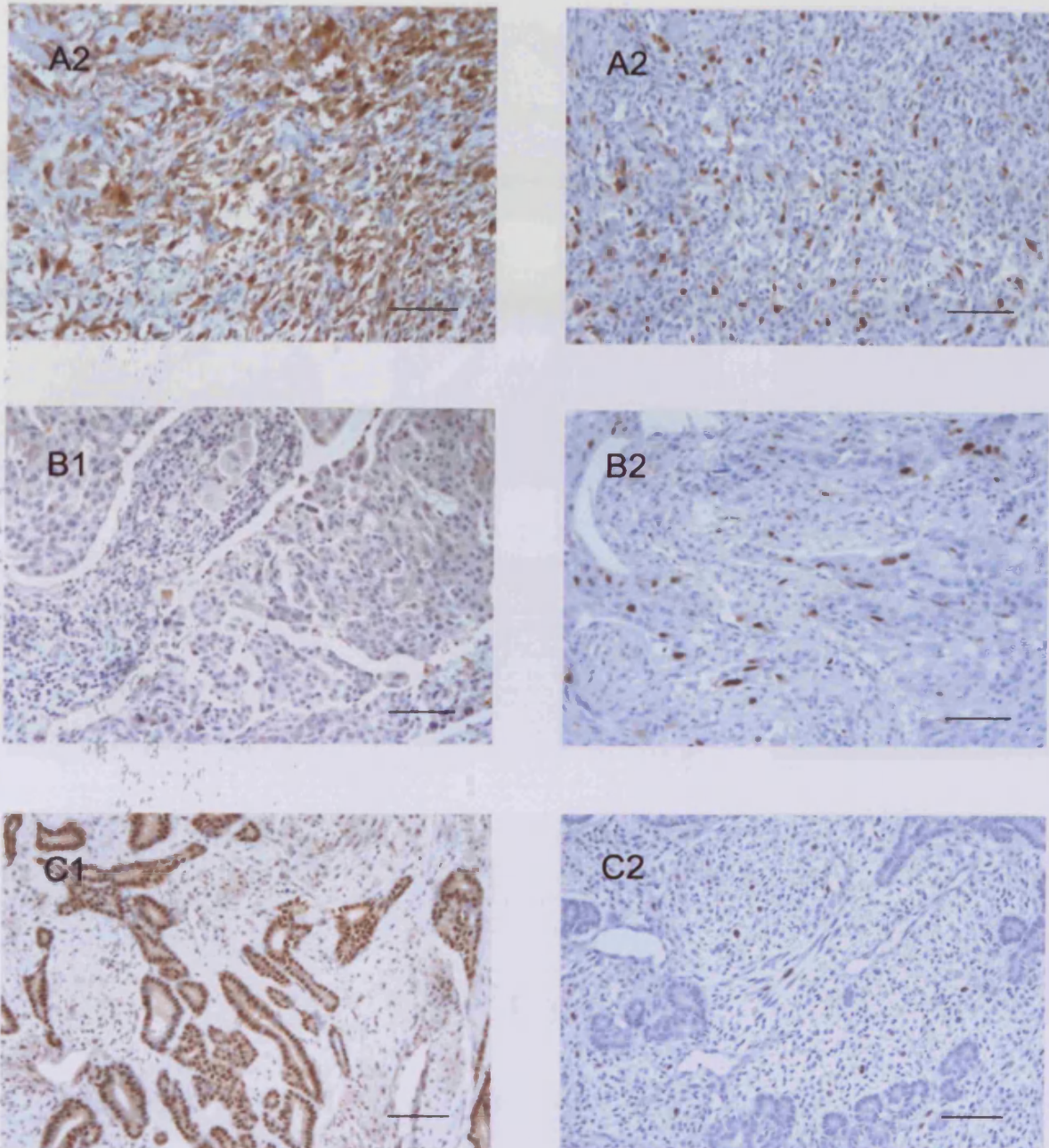


Figure 3.14 Immunohistochemical staining with anti-p16 antibody (A1, B1, C1) and anti-cyclin A antibody (A2, B2, C2) of three insular carcinoma tissue sections. Case A demonstrates a strong positive p16 and cyclin A reaction. Case B demonstrates a loss of p16 and an up-regulation of cyclin A expression. Case C demonstrates a positive p16 reaction in the background follicular carcinoma, and a loss of p16 expression and up-regulation of cyclin A expression in the insular carcinoma. Scale bar represents 200 $\mu$ m.



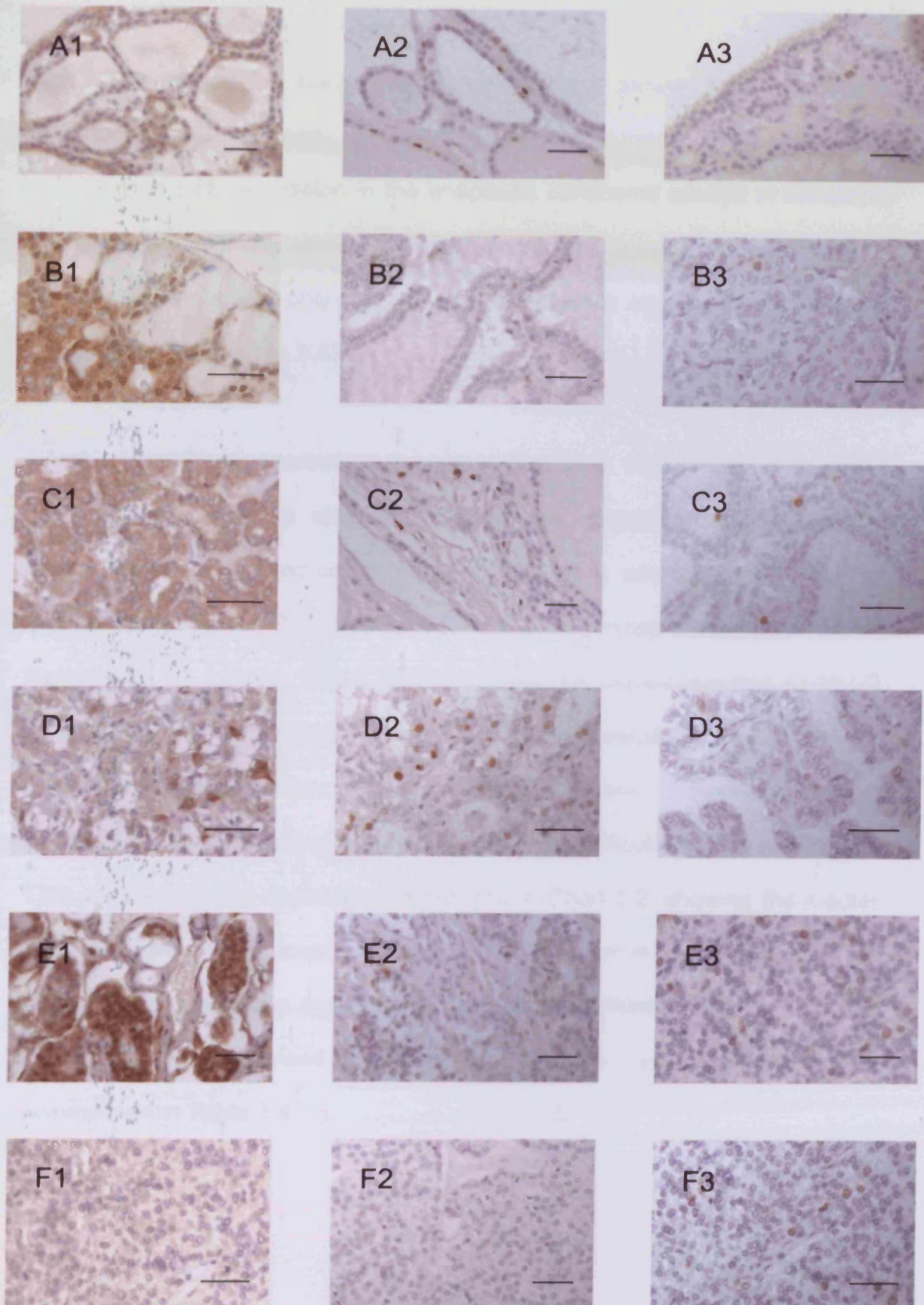


Figure 3.15 Immunohistochemical staining with anti-p16 antibody (series 1), anti-MCM2 antibody (series 2) and anti-cyclin A antibody (series 3) of TMA cores representing the following tumour groups: A - follicular adenoma, B - atypical adenoma, C - follicular carcinoma, D - papillary carcinoma, E - p16-positive insular carcinoma, F - p16-negative insular carcinoma. Scale bar represents 200 $\mu$ m.



### 3.3.2.7 Anaplastic carcinoma

Two anaplastic carcinoma tissue sections arising from a papillary carcinoma were analysed. These cancers demonstrated a dramatic down-regulation in p16 expression in the anaplastic carcinoma section in contrast to the strong p16 staining seen in the papillary carcinoma section (Figure 3.16).

Both tumours showed only a very weak cytoplasmic staining in a minority of the tumour cells (Figure 3.17).

Chart 3.1 graphically represents the range of p16 I.D. values of the TMA cores for each tumour group studied. Clearly, the adenomas and carcinomas demonstrated an up-regulation of p16 expression when compared to the normal thyroid tissue. The atypical adenomas and insular carcinomas had the highest p16 I.D. scores. Whilst 75% of the follicular carcinomas had a p16 I.D. score between 0.9-1.2, there was a greater range of values in the papillary and insular carcinoma groups, with a greater percentage of tumours showing weaker or stronger staining than that seen in the follicular cancers. The p16 TMA results are also depicted as a box plot in Chart 3.2, showing the median p16 I.D. score and the inter-quartile range for the normal thyroid, follicular and atypical adenomas, and the follicular, papillary and insular carcinomas. The TMA data is summarised in Table 3.1, and the tissue section data is summarised in Table 3.4.

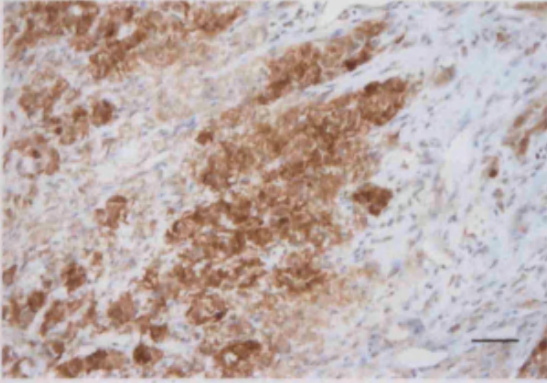


Fig 3.16 Immunohistochemical staining with anti-p16 antibody showing an anaplastic carcinoma derived from a papillary carcinoma demonstrating strong p16 expression in the papillary region and a down-regulation of p16 expression in the anaplastic section. Scale bar represents 200 $\mu$ m.

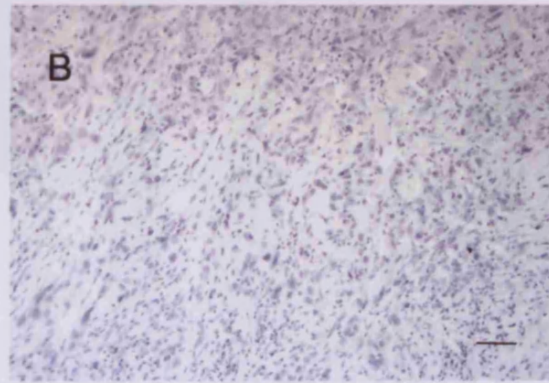
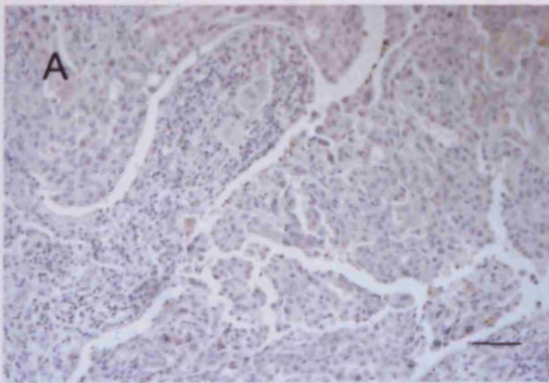
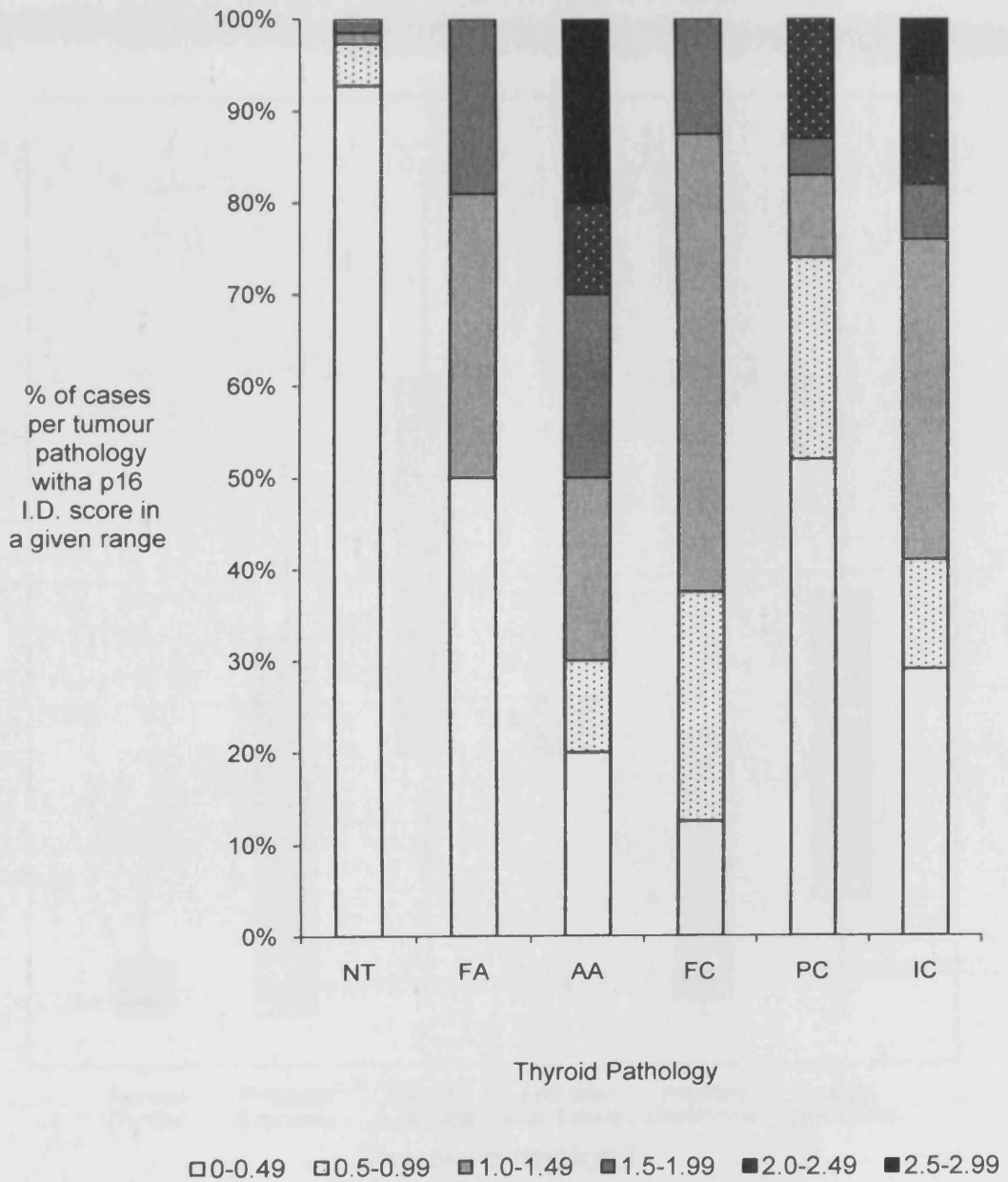


Fig 3.17 Immunohistochemical staining with anti-p16 antibody showing two cases of an anaplastic carcinoma demonstrating the absence of p16 expression. Scale bar represents 200 $\mu$ m.

Chart 3.1 Bar chart demonstrating the range of p16 I.D. scores in the normal thyroid, follicular and atypical adenoma, and follicular, papillary and insular carcinoma TMA cores. The stacked bars represent the percentage of cases per thyroid pathology group with a p16 I.D. score in a given range (0-0.49, 0.5-0.99, 1.0-1.49, 1.5-1.99, 2.0-2.49, 2.5-2.99).



NT = normal thyroid

FA = follicular adenoma

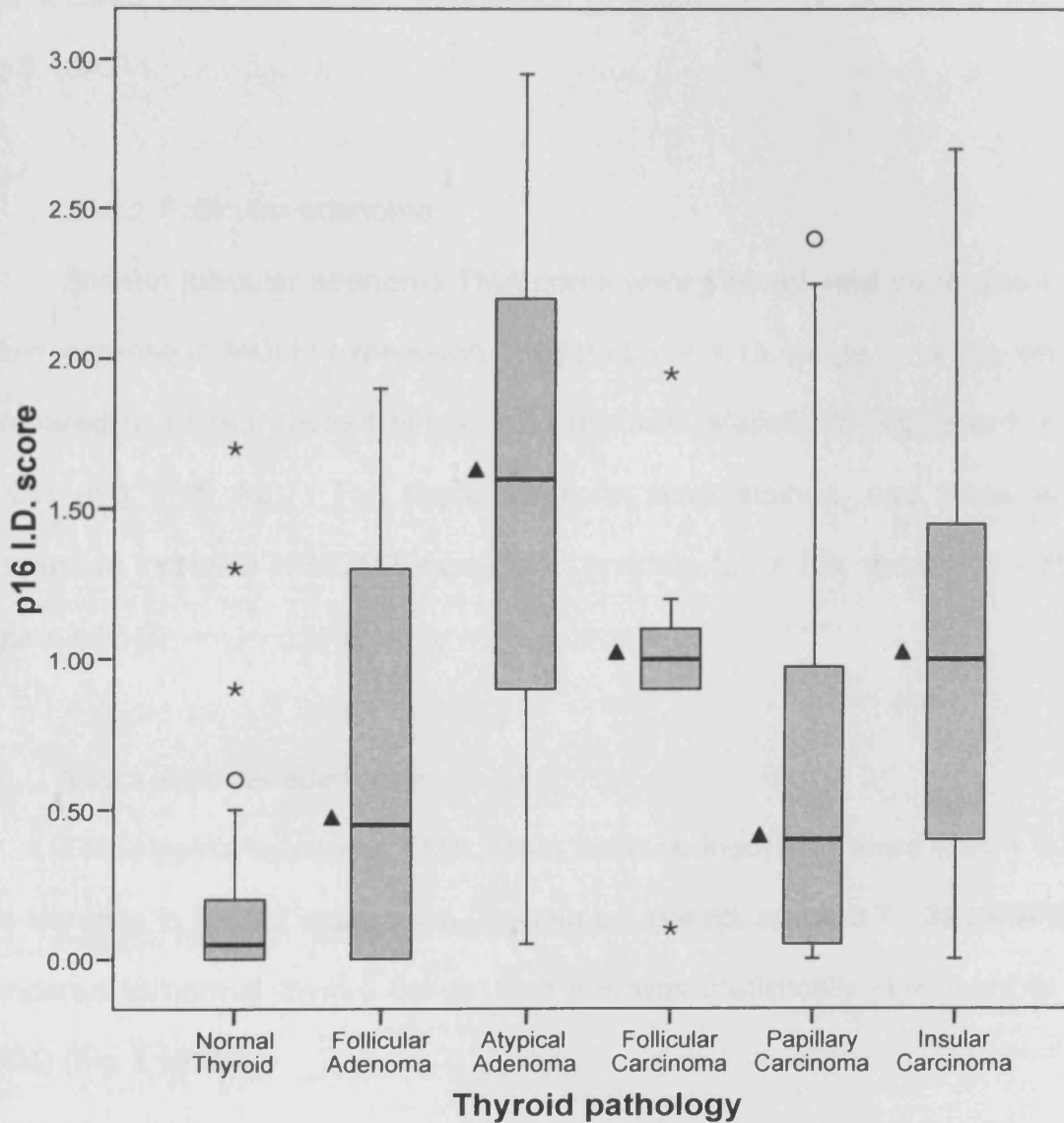
AA = atypical adenoma

FC = follicular carcinoma

PC = papillary carcinoma

IC = insular carcinoma

Chart 3.2 Box plot chart showing the range of p16 I.D. scores for cases within the first and third quartiles, and median values for the p16 I.D. score for normal thyroid, follicular and atypical adenoma, and follicular, papillary and insular TMA cores. The 'whiskers' represent the range of I.D. values of cases that fall within 1.5 times the inter-quartile range (IQR), 'O' represent the I.D score of 'outlier' cases whose I.D score is 1.5 – 3 times the IQR and '\*' represent the I.D. scores of 'extreme' cases whose I.D. value is >3 times the IQR.



▲ = statistically significant result compared to normal thyroid (p < 0.05)

### 3.3.3 MCM2 expression

#### 3.3.3.1 Normal thyroid

A total of 68 normal thyroid TMA cores were stained with anti-MCM2 antibody, and MCM2 expression was very low in this group (median L.I. = 0, range 0 - 14.3). Four normal thyroid tissue sections were also immunostained, and showed negligible MCM2 expression (median L.I. = 0, range = 0 – 0.8), Fig 3.18A.

#### 3.3.3.2 Follicular adenoma

Sixteen follicular adenoma TMA cores were stained, and there was a 7-8-fold increase in MCM2 expression (median L.I. = 4.15, range 0 - 41.2), when compared to normal thyroid tissue, and this was statistically significant ( $p < 0.001$ ) (Fig 3.15 A2). Ten tissue sections were stained, and these also showed an increase in MCM2 expression (median L.I. = 5.0, range = 1 - 25), Figure 3.18 B.

#### 3.3.3.3 Atypical adenoma

Ten atypical adenoma TMA cores were stained, and there was a 7-8-fold increase in MCM2 expression (median L.I. = 4.65, range 0.7 - 32.3), when compared to normal thyroid tissue, and this was statistically significant ( $p < 0.001$ ) (Fig 3.15 B2).

#### 3.3.3.4 Follicular carcinoma

A total of eight follicular carcinoma TMA cores were stained, and this group showed a smaller (5-fold) though still significant increase in MCM2 expression when compared to normal thyroid tissue (median L.I. = 1.35, range

0 - 29.7,  $p=0.002$ ) (Fig 3.15 C2). A further eight tissue sections were stained, and similarly these tumours showed an increase in MCM2 expression which was smaller than that seen in the follicular adenomas (median L.I. = 1.75, range = 0 - 14), Figure 3.18C.

#### 3.3.3.5 Papillary carcinoma

A total of 26 papillary carcinoma TMA cores were stained, and these cancers showed the greatest increase in MCM2 staining when compared to normal tissue (median L.I. = 7.35, range 0 - 63,  $p < 0.001$ ), as shown in (Fig 3.15 D2). Seven papillary carcinoma tissue sections were also stained, and this group also showed a greater increase in MCM2 expression when compared to normal thyroid tissue and the follicular tumours (median L.I. = 12.0, range = 2 – 53), Figure 3.18D.

#### 3.3.3.6 Insular carcinoma

A total of 17 insular carcinoma TMA cores were stained. These tumours showed a 5-fold increase in MCM2 expression when compared to normal thyroid tissue, and this was also statistically significant (median L.I. = 5, range 0 - 20,  $p < 0.001$ ) (Fig 3.15 E2, F2).

Chart 3.3 graphically represents as a box plot the range of MCM2 L.I. scores in the TMA cores for the follicular and atypical adenomas, and follicular, papillary and insular carcinomas. The vast majority of both benign and malignant tumours had a low MCM2 score ( $<10$ ). However, the papillary carcinoma group had the highest MCM2 L.I. scores ( $>40$ ). The TMA data is summarised in Table 3.2 and the tissue section data in Table 3.5.



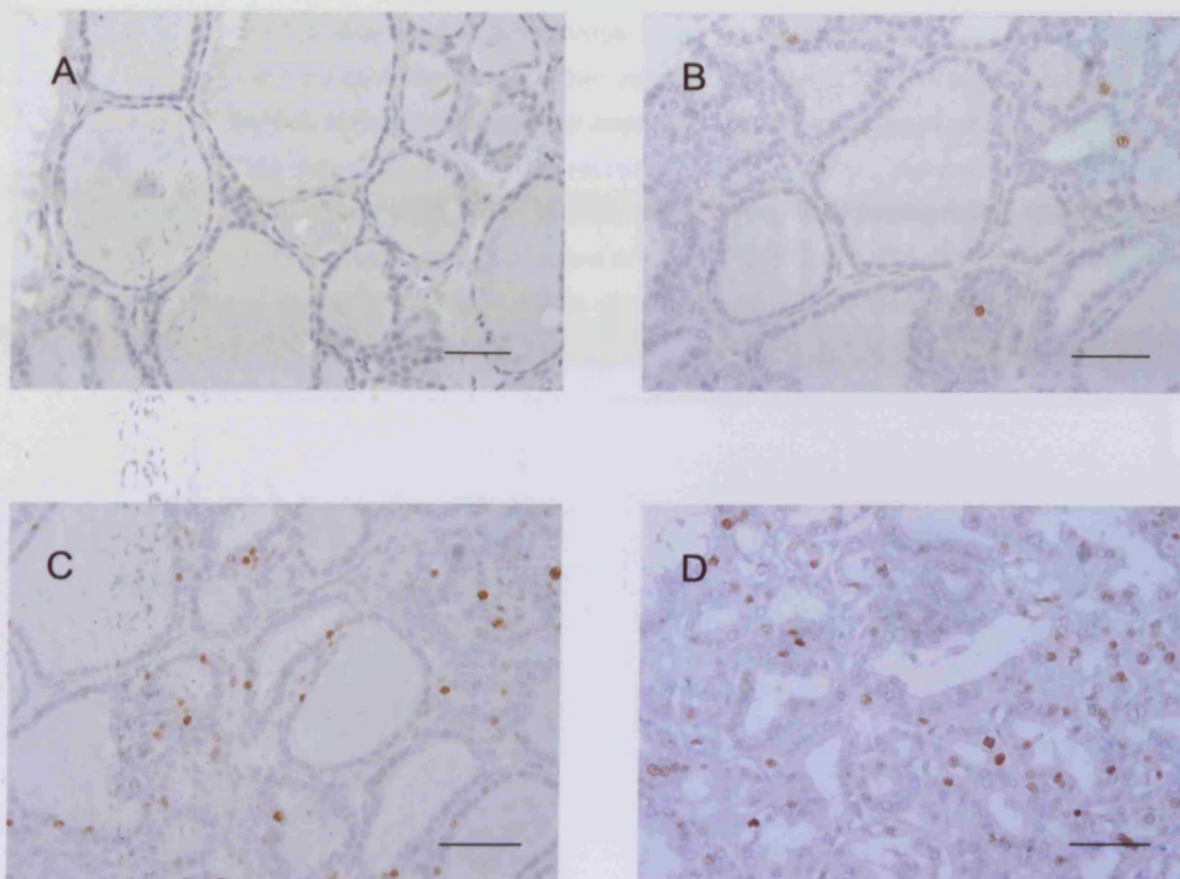
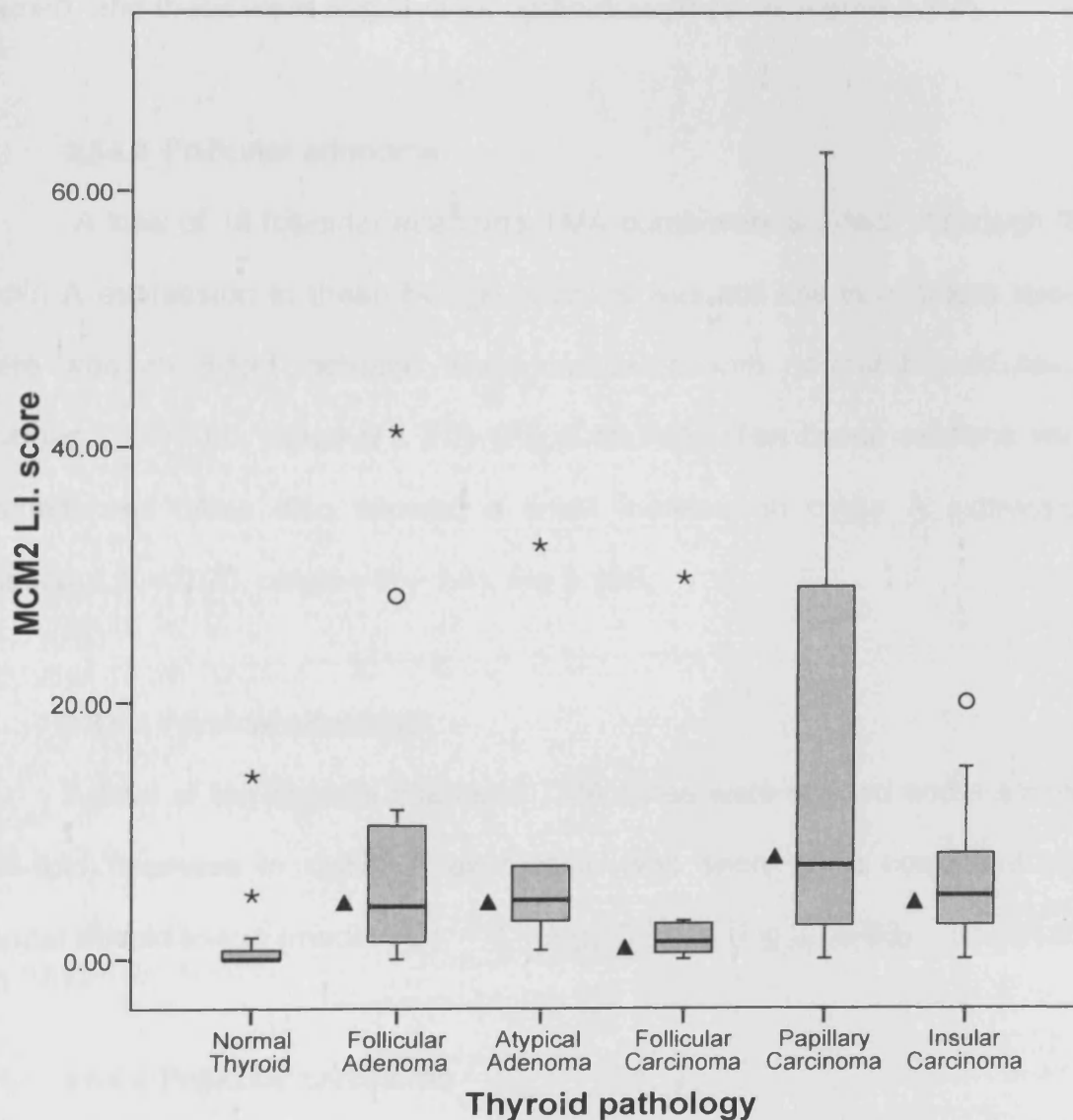


Figure 3.18 Immunohistochemical staining with anti-MCM2 antibody of normal thyroid tissue (A), follicular adenoma (B), follicular carcinoma (C) and papillary carcinoma (D) tissue sections. Scale bar represents 200 $\mu$ m.

Chart 3.3 Box plot chart showing the range of MCM2 L.I. scores for cases within the first and third quartiles, and median values for the MCM2 L.I. score for normal thyroid, follicular and atypical adenoma, and follicular, papillary and insular TMA cores. The 'whiskers' represent the range of L.I. values of cases that fall within 1.5 times the inter-quartile range (IQR), 'O' represent the L.I. score of 'outlier' cases whose L.I. score is 1.5 – 3 times the IQR and '\*' represent the L.I. scores of 'extreme' cases whose L.I. value is >3 times the IQR.



▲ = statistically significant result compared to normal thyroid ( $p < 0.05$ )



### 3.3.4 Cyclin A expression

#### 3.3.4.1 Normal thyroid

A total of 68 normal thyroid TMA cores were stained with anti-cyclin A antibody, and cyclin A expression was very low in normal thyroid tissue (median L.I. = 0, range 0 – 0.7). Four normal thyroid tissue sections were also stained, and these were negative for cyclin A expression, Figure 3.19A.

#### 3.3.4.2 Follicular adenoma

A total of 16 follicular adenoma TMA cores were stained. Although the cyclin A expression in these benign tumours was still low in absolute terms, there was an 8-fold increase when compared with normal thyroid tissue (median L.I. = 0.5, range 0 - 3.7) (Fig 3.15 A3). Ten tissue sections were stained, and these also showed a small increase in cyclin A expression (median L.I. = 0.20, range = 0 – 1.1), Fig 3.19B.

#### 3.3.4.3 Atypical adenoma

A total of ten atypical adenoma TMA cores were stained and a smaller (5-6-fold) increase in cyclin A expression was seen when compared with normal thyroid tissue (median L.I. = 0, range 0 - 3.3) (Fig 3.15 B3).

#### 3.3.4.4 Follicular carcinoma

A total of eight follicular carcinoma TMA cores were stained and a 5-6 - fold increase in cyclin A expression was seen when compared to normal thyroid tissue (median L.I. = 0.15, range 0 - 2) (Fig 3.15 C3). A further eight follicular carcinoma tissue sections were stained, and these showed a

comparable increase in cyclin A expression when compared to normal thyroid tissue (median L.I. = 0.10, range = 0 – 1.8), Figure 3.19C.

#### 3.3.4.5 Papillary carcinoma

I stained two micro-papillary carcinoma tissue sections with anti-cyclin A antibody, and observed a small up-regulation in cyclin A expression when compared to the surrounding normal tissue (Figure 3.11 A, B). I also stained a metastatic deposit from a papillary carcinoma, and this showed a considerable up-regulation of cyclin A in the tumour when compared to the surrounding normal tissue (Figure 3.13 B). A total of 26 papillary carcinoma TMA cores were stained and these tumours showed a greater up-regulation of cyclin A expression when compared to the follicular carcinomas (median L.I. = 0.5, range 0 - 6.7) (Fig 3.15 D3). Seven papillary carcinoma tissue sections were also stained, and these similarly showed a greater increase in cyclin A expression when compared to both normal thyroid tissue and the follicular tumours (median L.I. = 1.20, range = 0 – 5), Figure 3.19D.

#### 3.3.4.6 Insular carcinoma

I stained six insular carcinoma tissue sections, and all tumours showed an up-regulation of cyclin A expression when compared to normal thyroid tissue (Figure 3.14 A2, B2, and C2). A total of 17 insular carcinoma TMA cores were stained. These carcinomas showed a much greater increase in cyclin A expression than the other thyroid tumour groups studied, with a 20-fold increase in cyclin A expression when compared to normal thyroid tissue (median 1.00, range 0 - 21.7,  $p < 0.001$ ) (Figure 3.15 E3, F3). This did not

correlate with the low in comparison up-regulation of MCM2 expression seen in the insular carcinomas.

Chart 3.4 graphically represents as a box plot the range of cyclin A L.I. scores in the TMA cores for the follicular and atypical adenomas, and follicular, papillary and insular carcinomas. The vast majority of both benign and malignant tumours had a low cyclin A L.I. score (<5). However, the insular cancer group had tumours with much higher cyclin A L.I. scores when compared to the well-differentiated carcinomas. The TMA data is summarised in Table 3.3 and the tissue section data is summarised in Table 3.6.

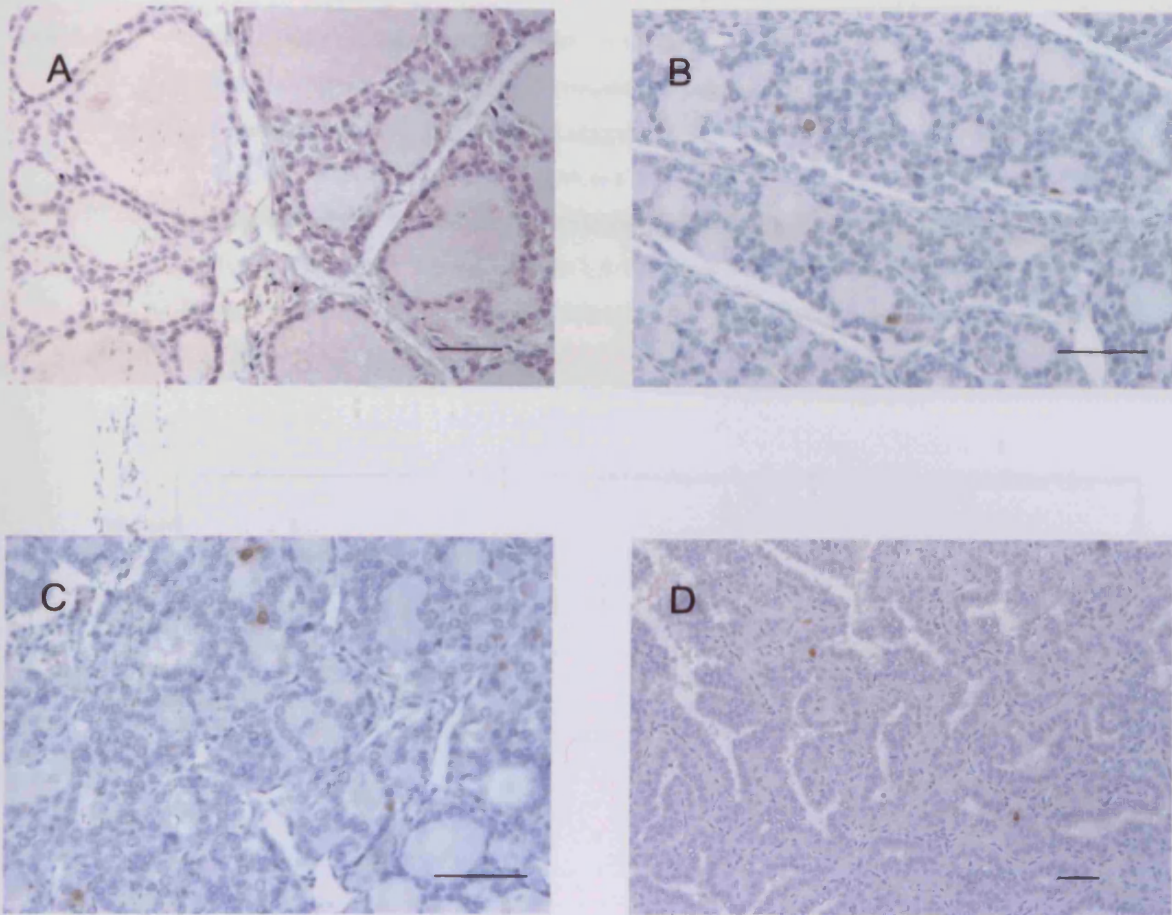
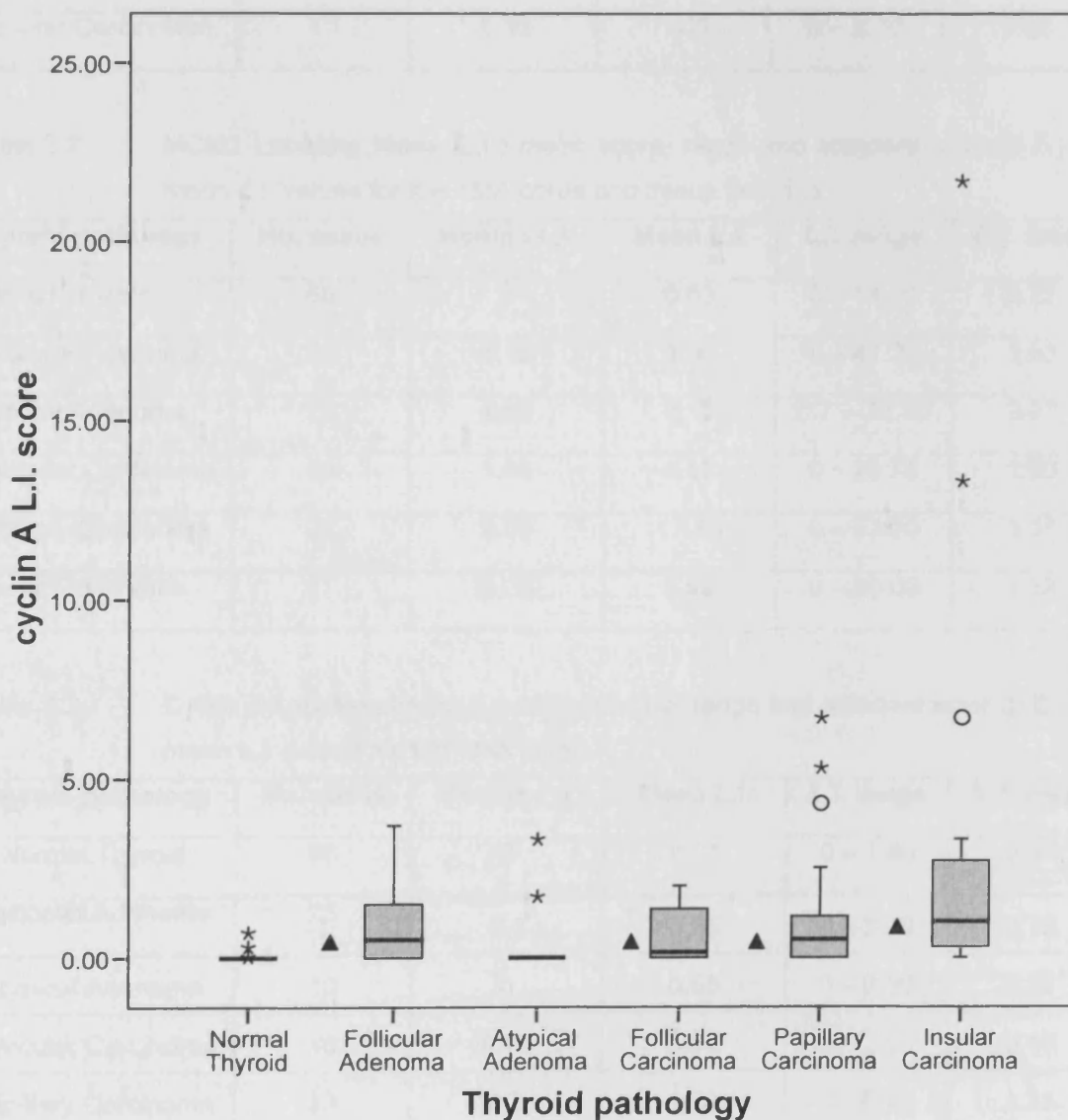


Figure 3.19 Immunohistochemical staining with anti-cyclin A antibody of normal thyroid tissue (A), follicular adenoma (B), follicular carcinoma (C) and papillary carcinoma (D) tissue sections. Scale bar represents 200 $\mu$ m.

Chart 3.4 Box plot chart showing the range of Cyclin A L.I. scores for cases within the first and third quartiles, and median values for the Cyclin A L.I. score for normal thyroid, follicular and atypical adenoma, and follicular, papillary and insular TMA cores. The 'whiskers' represent the range of L.I. values of cases that fall within 1.5 times the inter-quartile range (IQR), 'O' represent the L.I. score of 'outlier' cases whose L.I. score is 1.5 – 3 times the IQR and '\*' represent the L.I. scores of 'extreme' cases whose L.I. value is >3 times the IQR.



▲ = statistically significant result compared to normal thyroid (p < 0.05)

Table 3.1 p16 Intensity Distribution (I.D.) mean score, range and standard error (S.E.) of mean I.D. values for the TMA cores and tissue sections

Thyroid pathology	No. cases	Median I.D.	Mean I.D.	I.D. range	S.E. mean
Normal Thyroid	68	0.05	0.17	0 – 1.70	0.04
Follicular Adenoma	16	0.50	0.70	0 – 1.90	0.12
Atypical Adenoma	10	1.60	1.52	0.25 – 0.95	0.31
Follicular Carcinoma	16	1.15	1.26	0.10 – 2.40	0.13
Papillary Carcinoma	33	0.75	0.93	0 – 2.70	0.16
Insular Carcinoma	17	1.00	1.06	0 – 2.70	0.20

Table 3.2 MCM2 Labelling Index (L.I.) mean score, range and standard error (S.E.) of mean L.I. values for the TMA cores and tissue sections

Thyroid pathology	No. cases	Median L.I.	Mean L.I.	L.I. range	S.E. mean
Normal Thyroid	68	0	0.63	0 – 14.30	0.23
Follicular Adenoma	26	4.15	8.00	0 – 41.20	1.93
Atypical Adenoma	10	4.65	7.15	0.7 – 32.30	2.87
Follicular Carcinoma	16	1.45	4.13	0 – 29.70	1.90
Papillary Carcinoma	33	9.00	17.85	0 – 63.00	3.31
Insular Carcinoma	17	5.00	5.92	0 – 20.00	1.32

Table 3.3 Cyclin A Labelling Index (L.I.) mean score, range and standard error (S.E.) of mean L.I. values for the TMA cores

Thyroid pathology	No. cases	Median L.I.	Mean L.I.	L.I. range	S.E. mean
Normal Thyroid	68	0	0.04	0 – 1.40	0.02
Follicular Adenoma	26	0.3	0.65	0 – 3.70	0.18
Atypical Adenoma	10	0	0.50	0 – 3.30	0.35
Follicular Carcinoma	16	0.10	0.54	0 – 2.00	0.18
Papillary Carcinoma	33	0.7	1.28	0 – 6.70	1.29
Insular Carcinoma	17	1.00	3.34	0 – 21.70	1.40

### 3.3.5 Co-expression of MCM2 and cyclin A

The majority of normal thyroid tissue sections and TMA cores did not express either MCM2 or cyclin A protein. There was no significant correlation between these two proliferative markers (Spearman rank  $-0.108$ ,  $p = 0.384$ ), Chart 3.5.

Whilst MCM2 was slightly up-regulated in the atypical adenomas, cyclin A expression was negligible in eight out of 10 adenomas (Spearman rank  $0.196$ ,  $p = 0.588$ ), Chart 3.6.

The follicular adenoma tissue sections and TMA cores showed a much larger increase in MCM2 expression compared to normal thyroid tissue. Cyclin A was also up-regulated in this tumour group in comparison to normal thyroid tissue, although the increase was low in comparison to that of MCM2. There was a statistically significant correlation between the expression of these proteins in the follicular adenomas (Spearman rank  $0.627$ ,  $p = 0.001$ ), Chart 3.7.

The follicular carcinoma group also expressed MCM2 at a higher level than normal thyroid tissue, but the increase was smaller than that seen in the follicular adenomas. Cyclin A was also up-regulated, at a similar level to the follicular adenomas. There was no significant correlation between the expression of these proteins (Spearman rank  $0.208$ ,  $p = 0.446$ ), Chart 3.8.

The papillary carcinomas had the greatest up-regulation of MCM2 expression out of all the tumour groups analysed, and this was seen in both the tissue sections and the TMA cores. There was also an increase in cyclin A

expression when compared to the follicular tumours, but this was not correlated with MCM2 expression (Spearman rank -0.179,  $p = 0.361$ ), Chart 3.9.

In contrast, the insular carcinomas had a lower level of MCM2 expression when compared to the other tumour groups, but had the highest level of cyclin A expression (Spearman rank -0.078,  $p = 0.086$ ), Chart 3.10. However the two tumours with the highest cyclin A scores had the highest and the lowest MCM2 scores.



Chart 3.5 Scatter chart showing MCM2 and cyclin A expression in the normal thyroid TMA cores

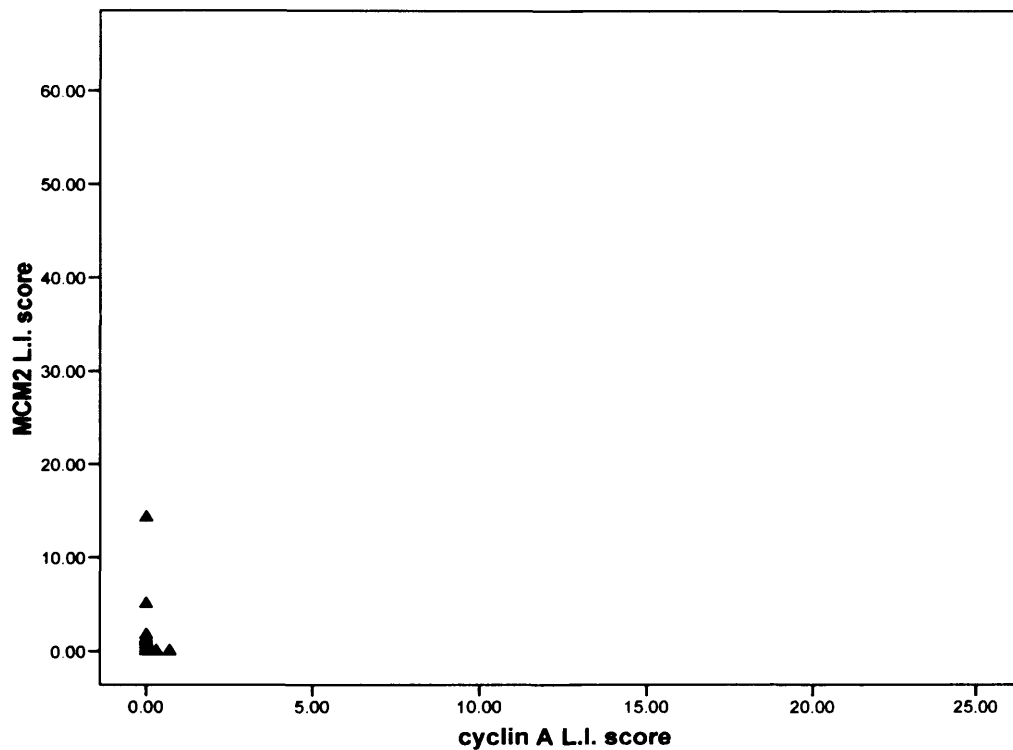


Chart 3.6 Scatter chart showing MCM2 and cyclin A expression in the atypical adenoma TMA cores

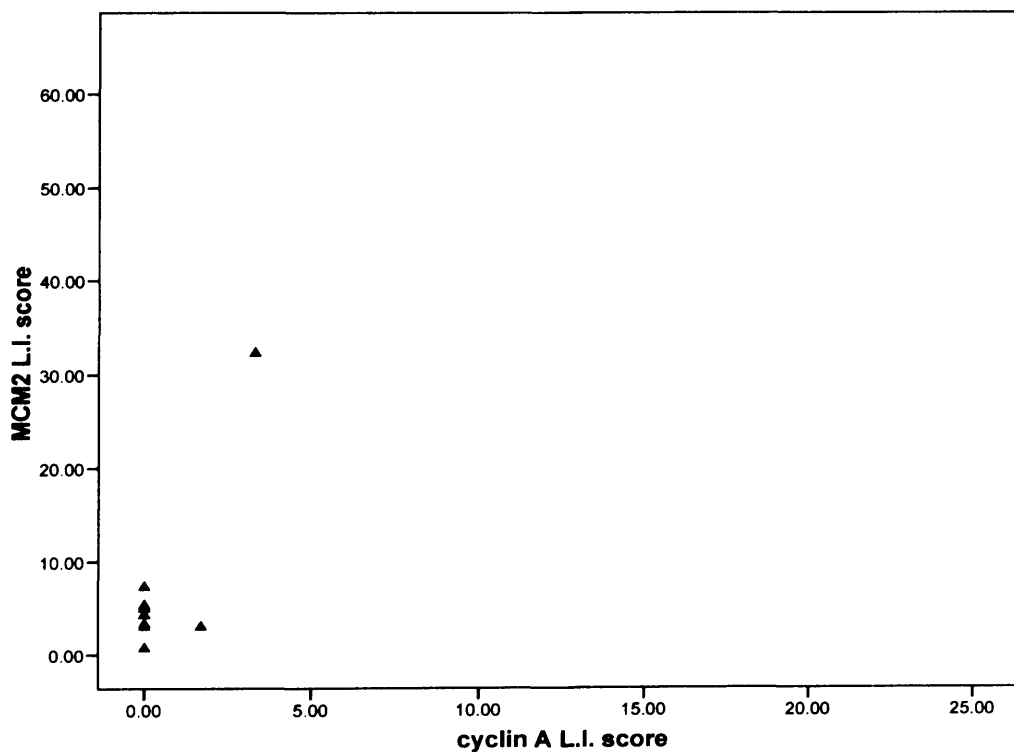


Chart 3.7 Scatter chart showing MCM2 and cyclin A expression in the follicular adenoma tissue sections (o) and TMA cores (▲)

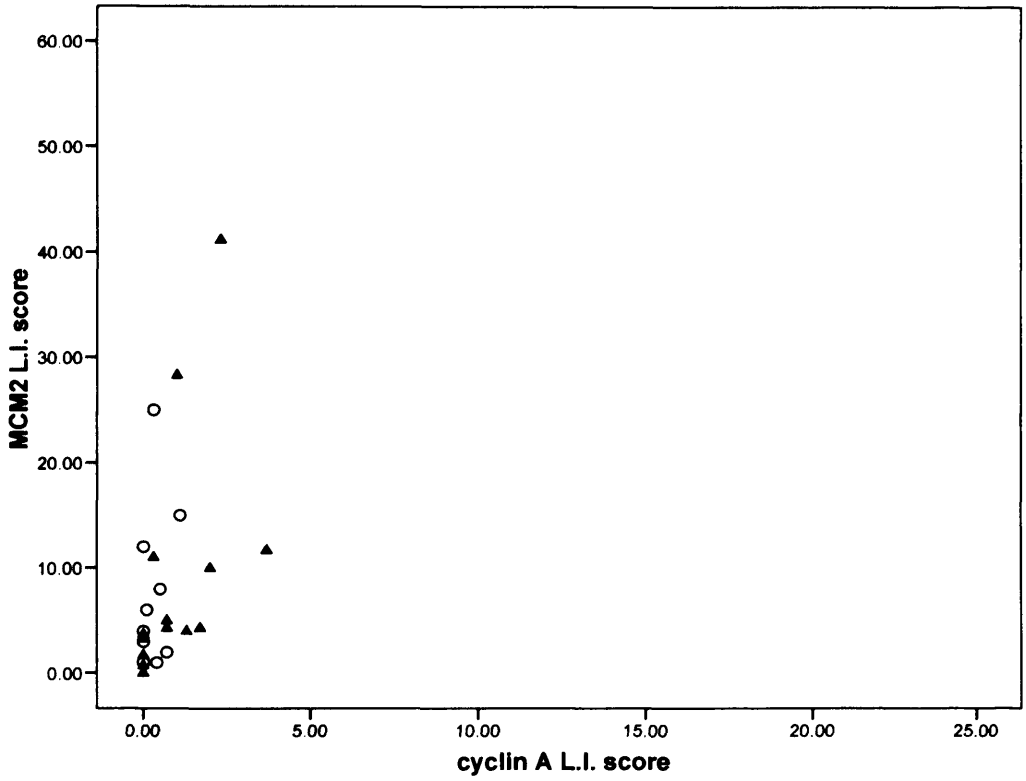


Chart 3.8 Scatter chart showing MCM2 and cyclin A expression in the follicular carcinoma tissue sections (o) and TMA cores (▲)

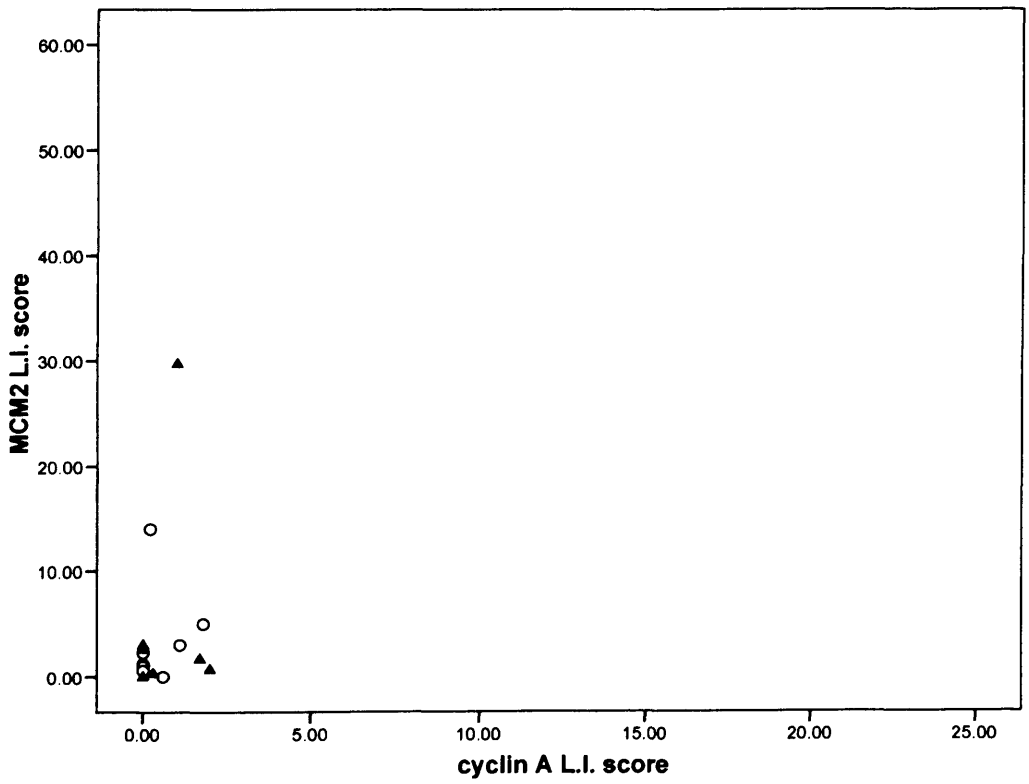


Chart 3.9 Scatter chart showing MCM2 and cyclin A expression in the papillary carcinoma tissue sections (o) and TMA cores (▲)

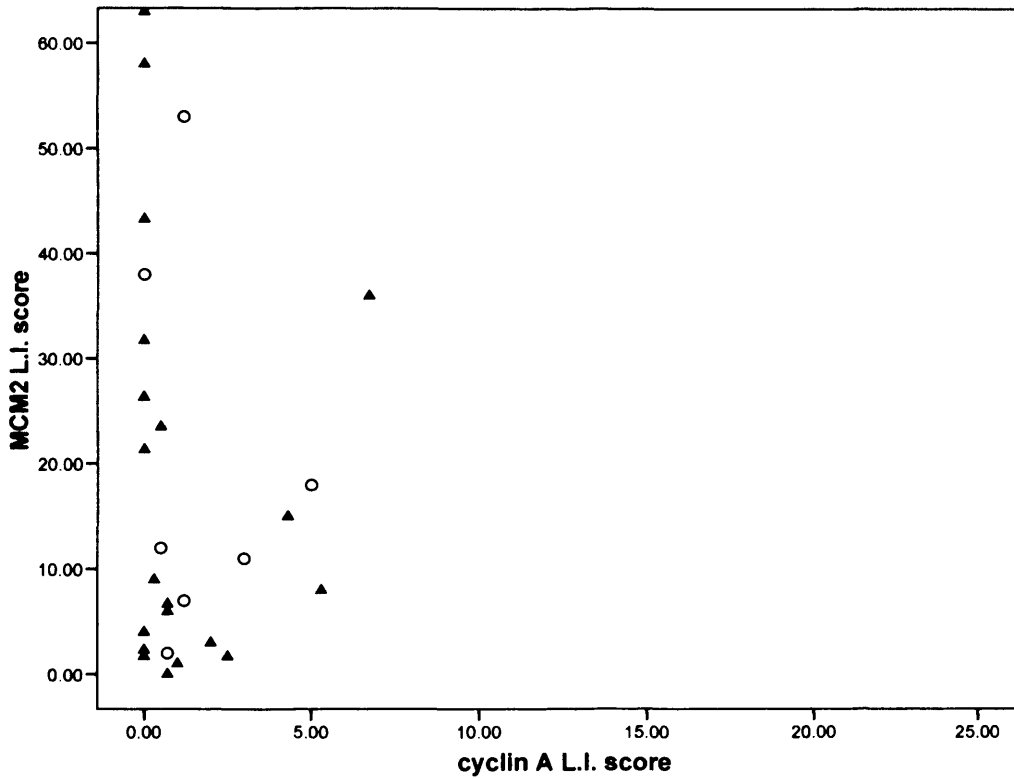
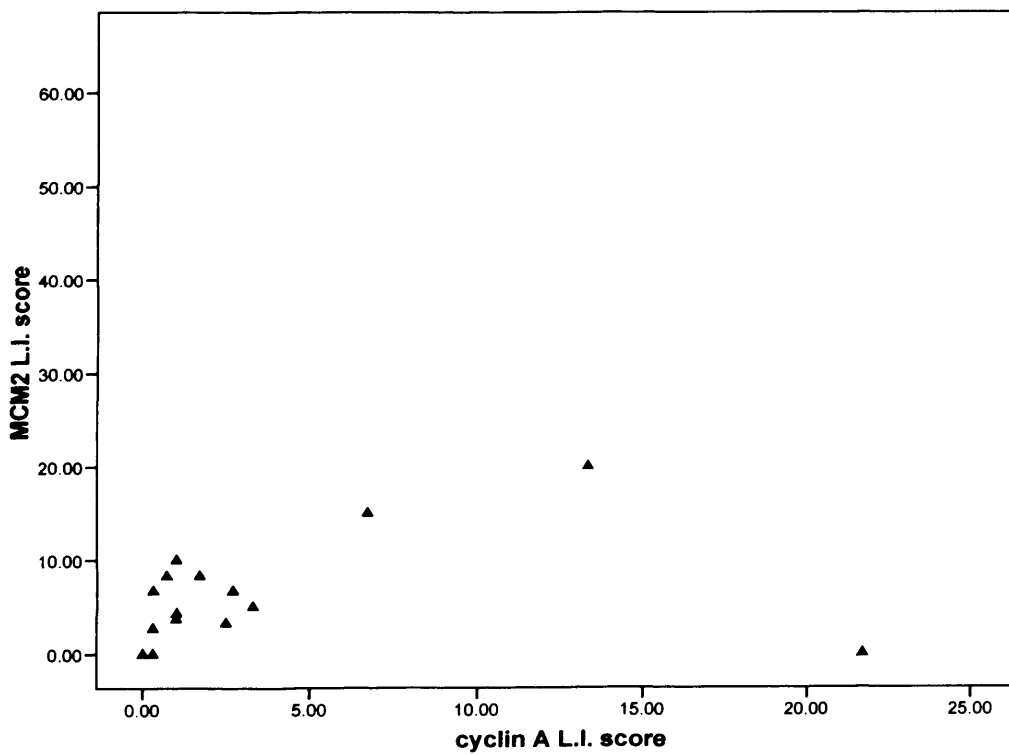


Chart 3.10 Scatter chart showing MCM2 and cyclin A expression in the insular carcinoma TMA cores



### 3.3.6 Co-expression of p16 and MCM2

The vast majority of normal thyroid tissue sections and TMA cores did not express either MCM2 or p16 protein. There were a couple of cases which expressed p16, and this was not correlated with an increase in MCM2 expression, Chart 3.11.

p16 was up-regulated in the atypical adenoma TMA cores compared to normal thyroid tissue, there was only a small increase in MCM2 expression, and this was not a significant correlation (Spearman rank -0.018,  $p = 0.96$ ) Chart 3.12.

There was a similar increase of both p16 and MCM2 expression in the follicular adenoma tissue sections and TMA cores, Chart 3.13. This was a negative (but not statistically significant) correlation (Spearman rank -0.054,  $p = 0.793$ ).

The follicular carcinomas, in contrast to the follicular adenomas, had a smaller up-regulation of MCM2 when compared to the adenomas, and this was observed in both the tissue sections and the TMA cores. The increase in MCM2 expression was not correlated with the observed increase in p16 expression (Spearman rank 0.084,  $p = 0.757$ ), Chart 3.14.

The papillary carcinoma tissue sections and TMA cores had the highest increase in MCM2 expression when compared to normal thyroid tissue, and this could not be correlated with the increase in p16 expression in these tumours, since the cases with the highest MCM2 L.I. scores either very high or very low p16 I.D. scores (Spearman rank 0.116,  $p = 0.548$ ), Chart 3.15.

The insular carcinomas showed a small increase in MCM2 expression when compared to the papillary carcinomas, and this group had the widest range of p16 I.D. scores, and there was no significant correlation between expression of these proteins in this tumour group (Spearman rank 0.422,  $p = 0.92$ ), Chart 3.16.

Chart 3.11 Scatter chart showing p16 and MCM2 expression in the normal thyroid TMA cores

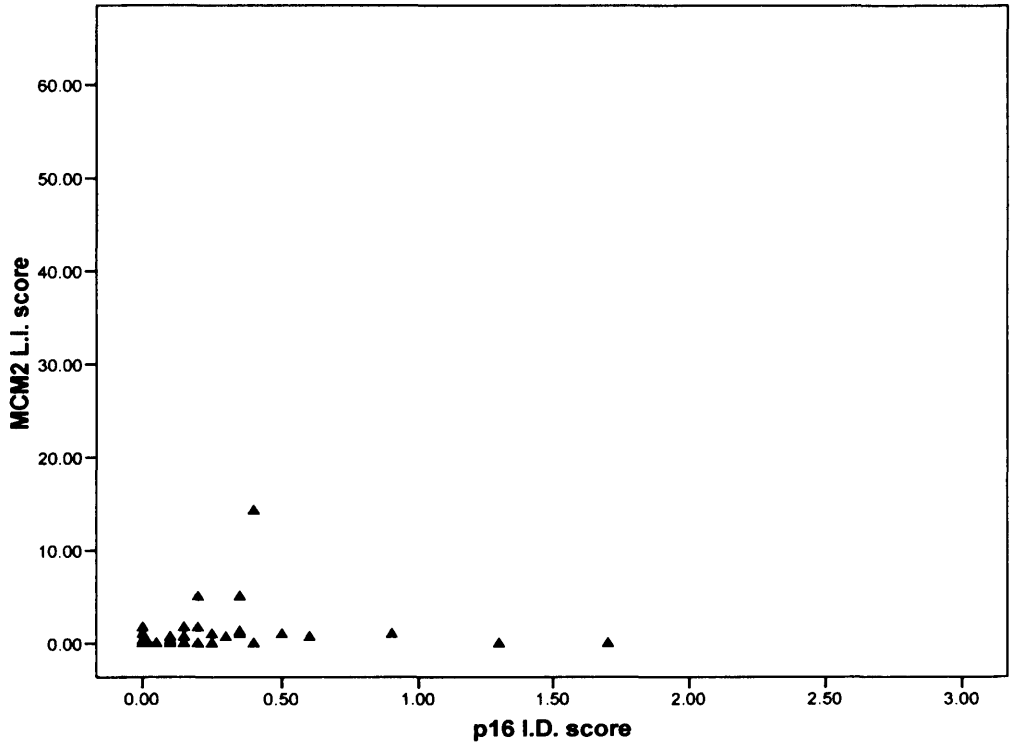


Chart 3.12 Scatter chart showing p16 and MCM2 expression in the atypical adenoma TMA cores

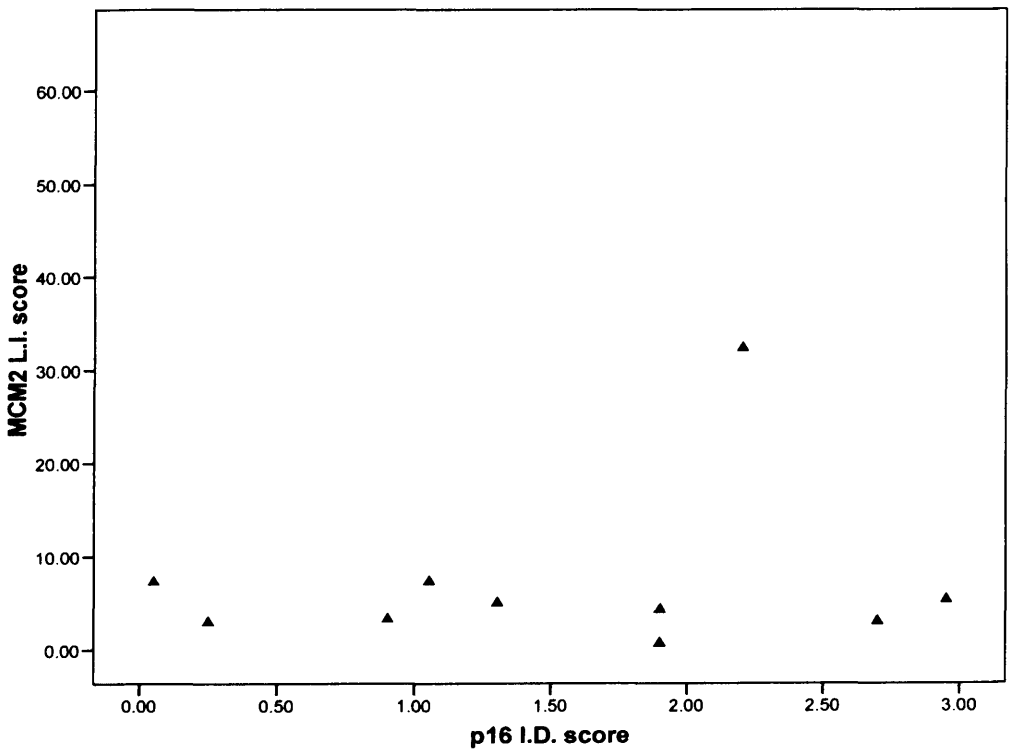


Chart 3.13 Scatter chart showing p16 and MCM2 expression in the follicular adenoma tissue sections (o) and TMA cores (▲)

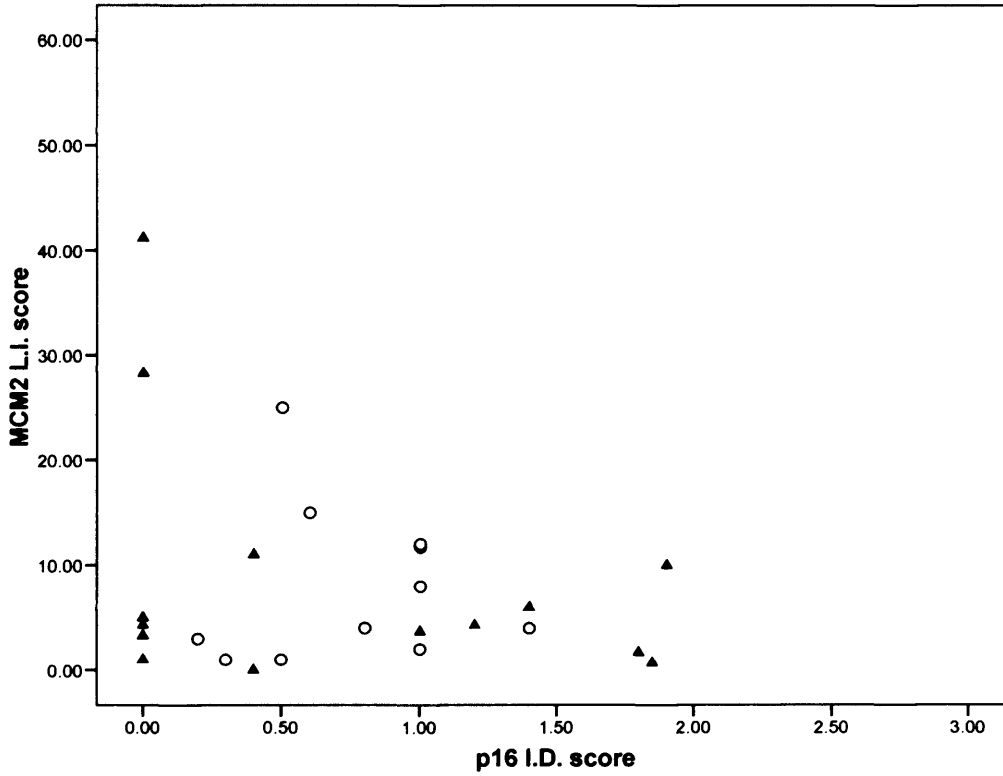


Chart 3.14 Scatter chart showing p16 and MCM2 expression in the follicular carcinoma tissue sections (o) and TMA cores (▲)

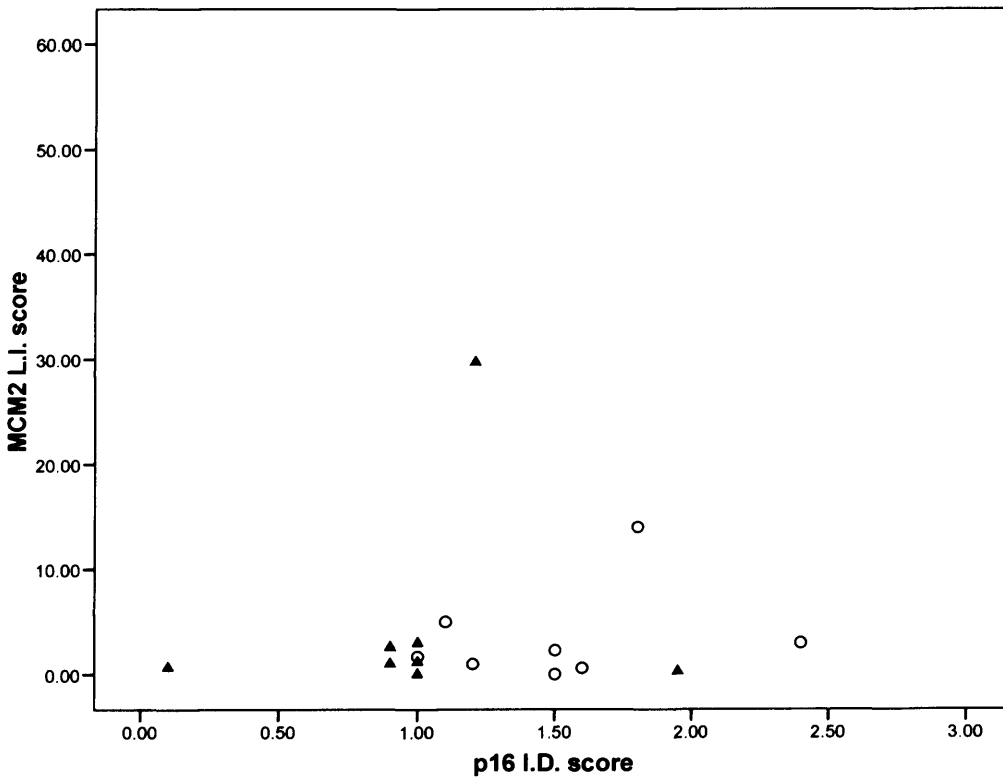


Chart 3.15 Scatter chart showing p16 and MCM2 expression in the papillary carcinoma tissue sections (o) and TMA cores (▲)

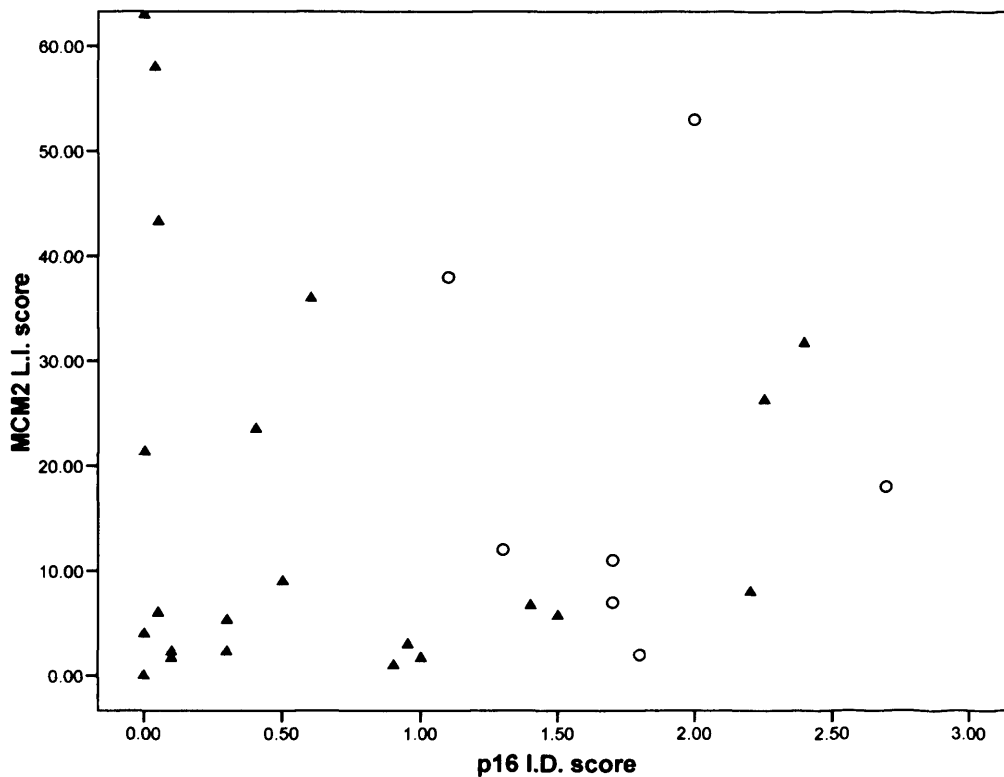
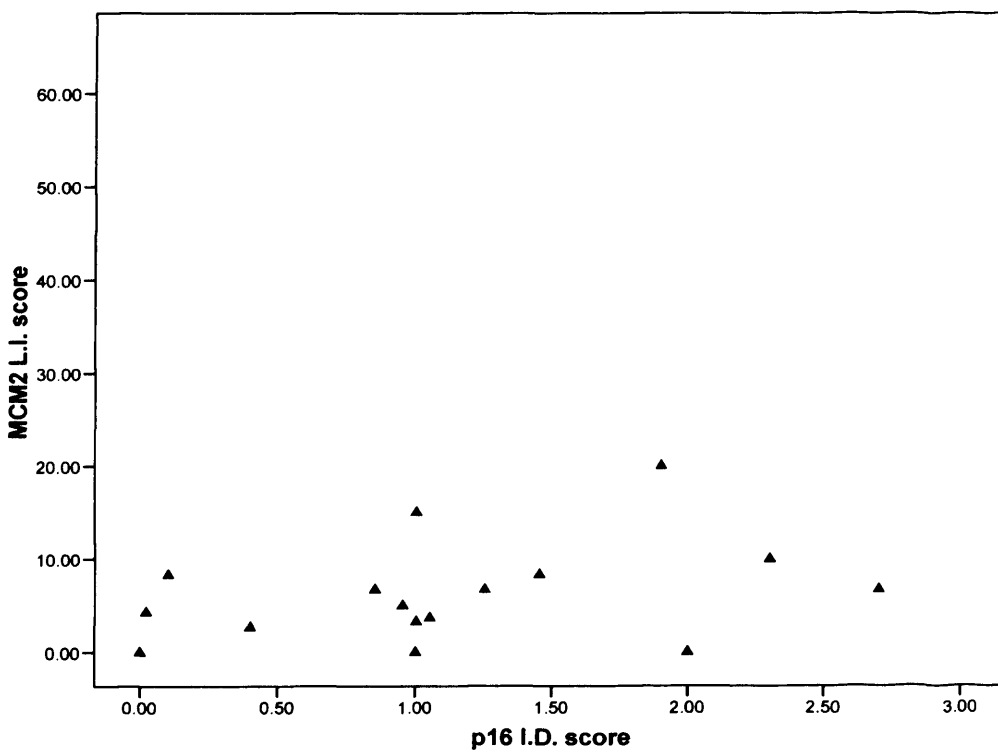


Chart 3.16 Scatter chart showing p16 and MCM2 expression in the insular carcinoma TMA cores





### 3.3.7 Co-expression of p16 and cyclin A

The vast majority of normal thyroid TMA cores and all four tissue sections did not express cyclin A expression, and most of these cases were also negative for p16 expression. There were a couple of TMA cores that did express p16, and the pathological report for these specimens simply labelled them as 'not cancer' (Chart 3.17).

p16 was up-regulated in the atypical adenomas whilst cyclin A expression remained low, with eight out of 10 adenomas not expressing cyclin A (Spearman rank -0.035,  $p = 0.924$ ) (Chart 3.18).

There was a small increase in cyclin A expression in the follicular adenoma tissue sections and TMA cores when compared to normal thyroid tissue, and this was not significantly correlated with the observed up-regulation of p16 seen in these tumours (Spearman rank 0.062,  $p = 0.763$ ) (Chart 3.19).

The follicular carcinoma group also showed a small increase in cyclin A expression, at a similar level to that seen in the follicular adenomas. Similarly, this was not correlated with the significant increase in p16 expression seen in these cancers (Spearman rank 0.099,  $p = 0.715$ ) (Chart 3.20).

There was also an up-regulation of both p16 and cyclin A expression in the papillary carcinoma tissue sections and TMA cores. However, unlike the follicular adenomas and carcinomas, this was a statistically significant positive correlation (Spearman rank 0.47,  $p = 0.012$ ), (Chart 3.21).

The insular carcinoma group also expressed p16 and cyclin A at a higher level than that seen in normal thyroid tissue, although there was not a significant correlation between the two proteins (Spearman rank -0.078,  $p = 0.767$ ) (Chart 3.22). One case had a much higher level of cyclin A expression, and this was in an insular carcinoma that did not express p16, as shown on the scatter chart. This tumour was identified as being a particularly aggressive tumour with a p53 mutation (cyclin A L.I. = 21.7, p16 I.D. = 0).

Chart 3.17 Scatter chart showing p16 and cyclin A expression in the normal thyroid TMA cores

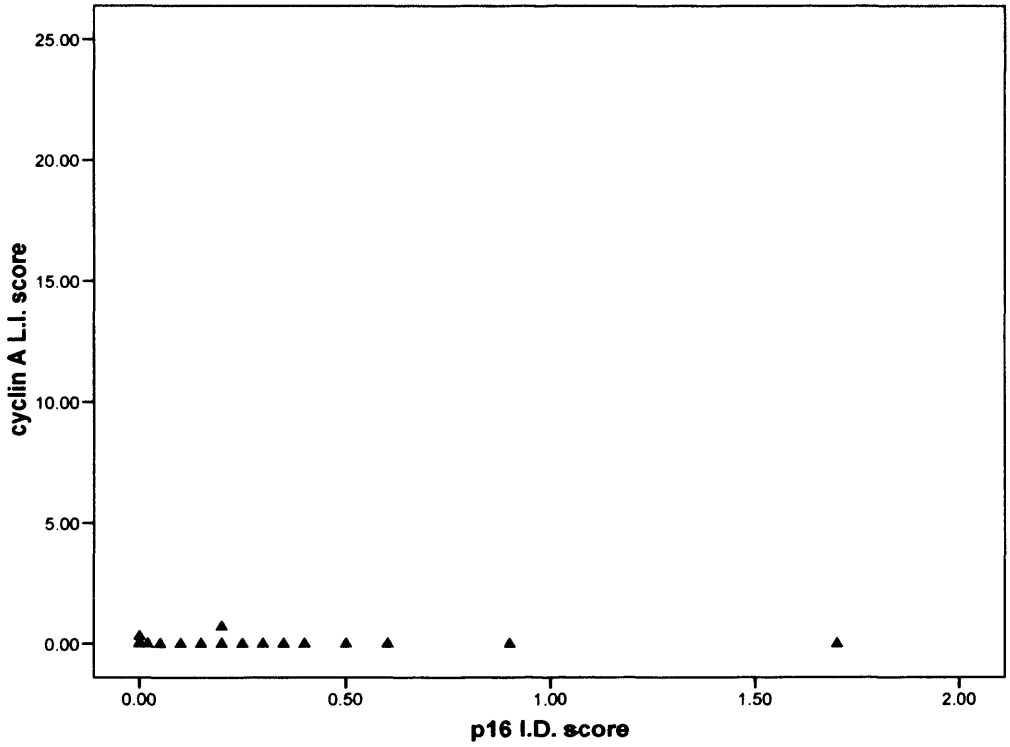


Chart 3.18 Scatter chart showing p16 and cyclin A expression in the atypical adenoma TMA cores

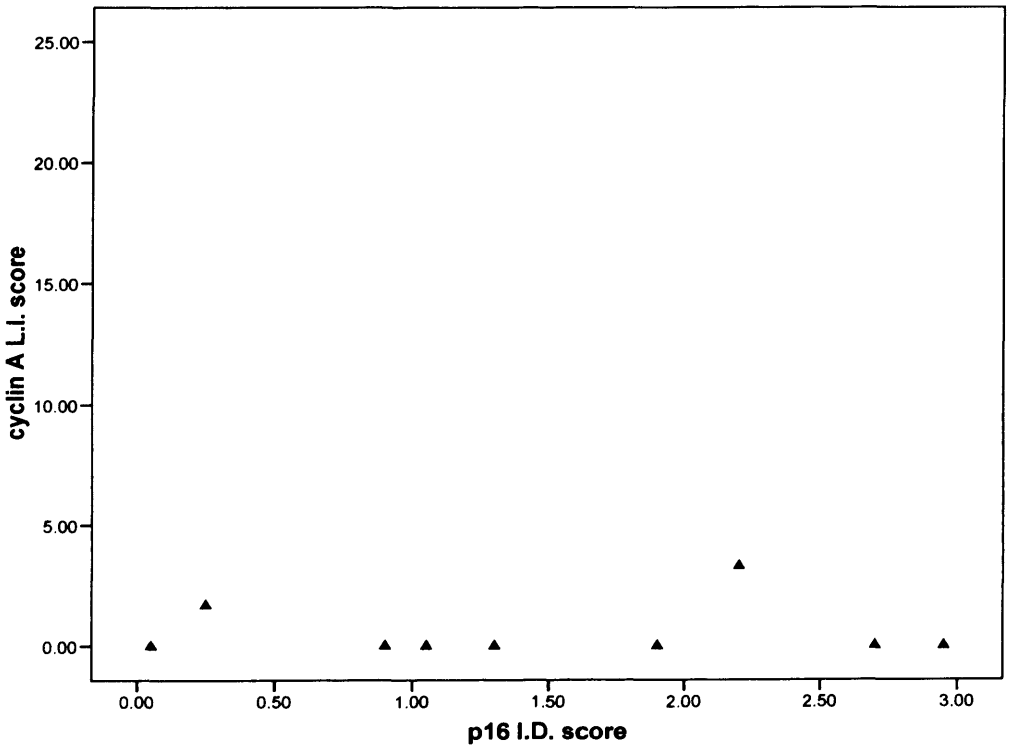


Chart 3.19 Scatter chart showing p16 and cyclin A expression in the follicular adenoma tissue sections (o) and TMA cores (▲)

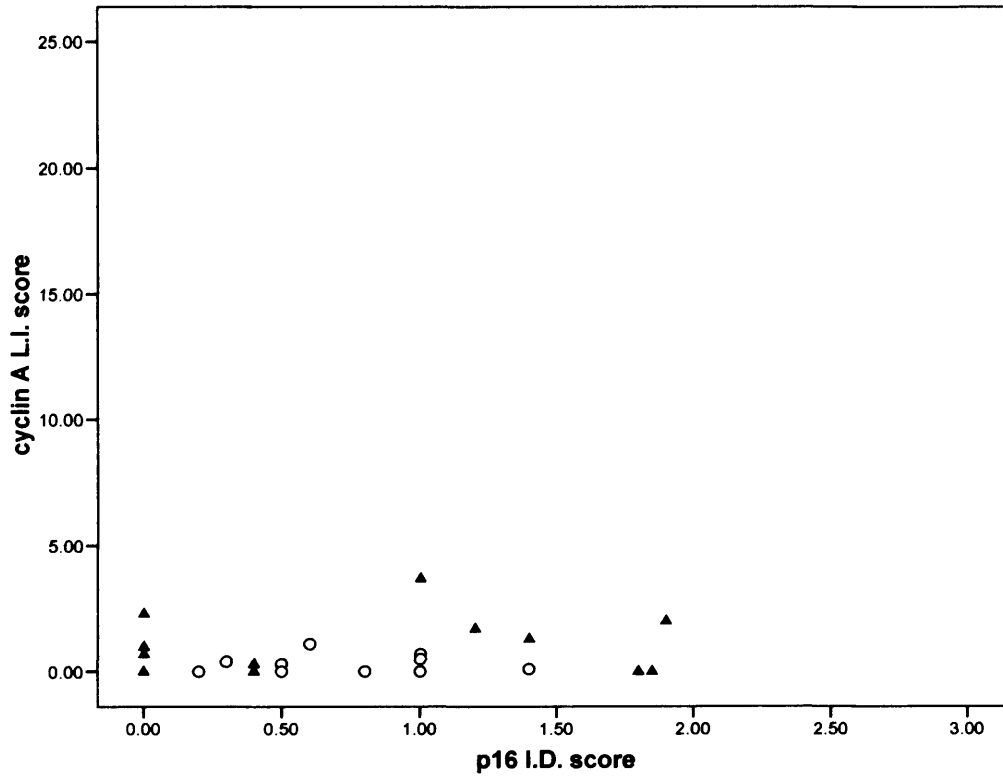


Chart 3.20 Scatter chart showing p16 and cyclin A expression in the follicular carcinoma tissue sections (o) and TMA cores (▲)

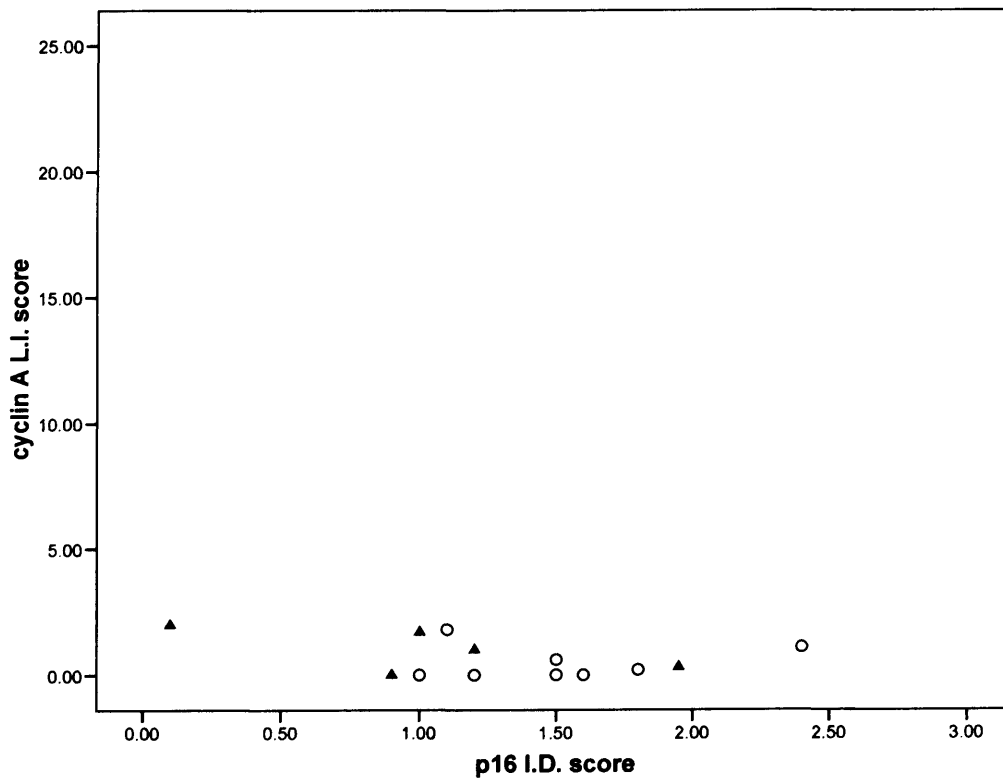


Chart 3.21 Scatter chart showing p16 and cyclin A expression in the papillary carcinoma tissue sections (o) and TMA cores (▲)

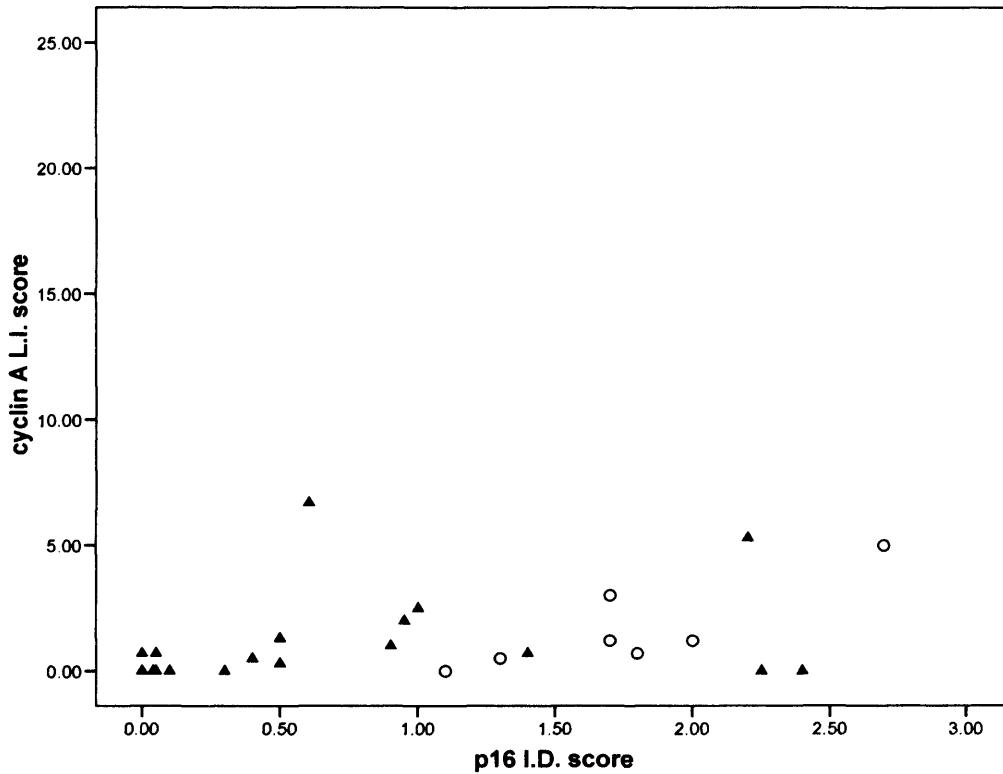
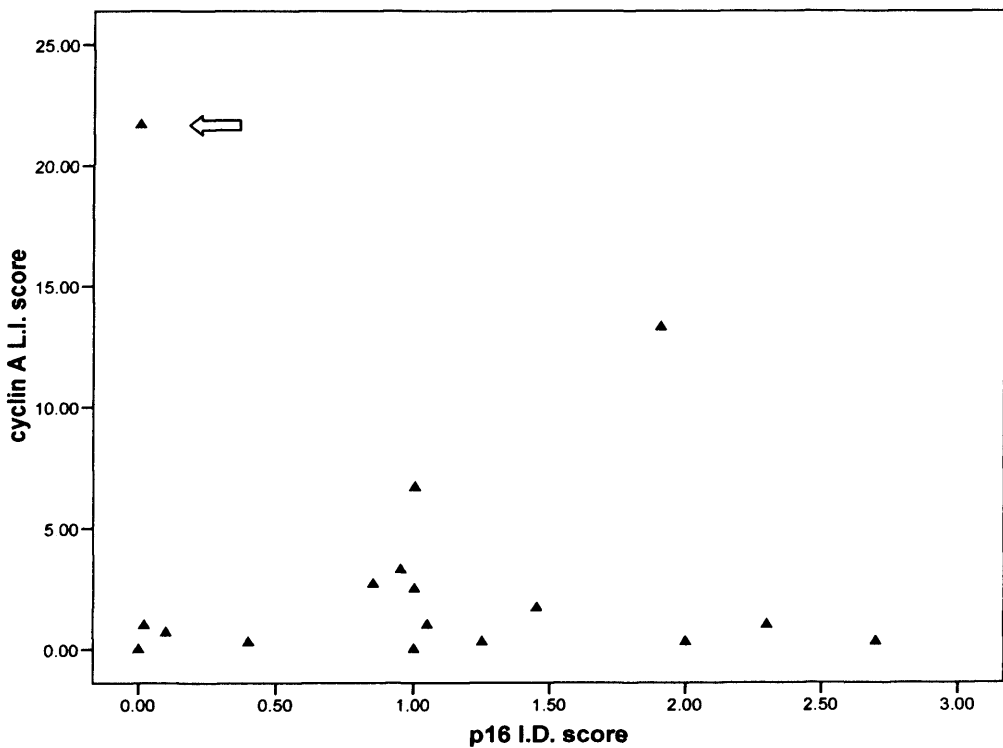


Chart 3.22 Scatter chart showing p16 and cyclin A expression in the insular carcinoma TMA cores. The highlighted point (⇐) represents a particularly aggressive tumour with a p53 mutation



### 3.4 Discussion

Our study is the first to define p16 protein expression patterns in vivo throughout the neoplastic progression of thyroid tumours, and to correlate this with p16 expression in an in vitro thyrocyte tumour model. This study is also the first to demonstrate the down-regulation of p16 expression in insular and anaplastic carcinomas. The panel of thyroid tumours that I studied represents the largest tumour group to date that has been investigated for p16 protein expression.

I investigated the complete thyroid tumorigenesis pathway, starting with a thyrocyte culture model, progressing from normal thyroid tissue through to undifferentiated anaplastic thyroid carcinoma. I also correlated p16 expression with the proliferation status of the thyroid tumour groups by analysing the expression of the proliferation markers MCM2 and cyclin A, to confirm whether loss of p16 expression is related to an increase in tumour proliferation.

I initially hypothesised that p16 expression would be induced in vivo in follicular adenomas, and that this expression would be down-regulated in follicular and papillary carcinomas, in keeping with tumour progression to a malignant phenotype. Consistent with this hypothesis generated by our in vitro studies, the data presented here show that p16 protein expression is indeed switched on in early stage thyroid tumorigenesis.

I had access to a large number of normal thyroid tissue specimens, and the vast majority of these did not show p16 expression, with a median p16 I.D. score of 0.05. The TMA cores and the full tissue sections had equivalent

results. There were four cases of normal thyroid tissue in the TMA group that did show an up-regulation of p16 protein expression. The pathology report for these cases simply listed them as 'not cancer' instead of normal thyroid tissue; therefore it is difficult to draw conclusions regarding the mechanism for the up-regulation in these cases.

In agreement with my hypothesis, the follicular adenomas demonstrated an up-regulation in p16 protein expression, to correspond with the increase in p16 expression seen in RAS-induced thyrocyte colonies which genotypically and phenotypically resemble follicular adenomas. This was weak or moderate expression in both the TMA cores and the full tissue sections, with a mean TMA I.D. score of 0.50.

The atypical adenomas as a group also demonstrated a statistically significant up-regulation in p16 expression, with a mean p16 I.D. score of 1.6 ( $p < 0.001$ ), although there was a wide variety in the I.D. scores for these tumours. Some cases only had very weak staining in a small proportion of cells, whereas others had very intense staining, and some of the highest p16 I.D. scores out of all the tumour groups studied. The exact biological nature of atypical adenomas is unclear, as phenotypically they resemble thyroid carcinomas but do not have the invasive features of either follicular or papillary cancers. Tzen et al., (2003) suggested that they may represent a direct precursor of anaplastic carcinoma. This pre-malignant behaviour might explain the wide range of values for this tumour group.

Following on from our in vitro work, I hypothesised that p16 expression would be down-regulated in thyroid carcinomas, and that this would be correlated with an increase in tumour proliferation, as has been reported in many epithelial tumours. Contrary to the hypothesis, however, there was no evidence of any fall-off in p16 expression between the follicular adenomas and the well-differentiated follicular carcinomas.

p16 staining was still present in the follicular cancer group, and this expression was seen in the majority of the TMA cores and tissue sections, with almost 90% cases showing moderate p16 staining (median p16 I.D. score 1.15). There was a statistically significant increase in p16 expression when compared with normal thyroid tissue ( $p < 0.001$ ). Surprisingly, the follicular carcinomas also showed an increase in p16 expression when compared to the follicular adenomas, and this was unexpected.

The two micro-papillary carcinomas showed an up-regulation of p16 expression. These tumours are occult, indolent carcinomas, and therefore behave similarly to the follicular adenomas, although they do have the potential to invade and metastasise. The up-regulation in p16 expression in these carcinomas is consistent with the hypothesis that p16 is induced in pre-malignant or early stages of tumorigenesis, and therefore I initially predicted that p16 would be down-regulated in the papillary carcinomas.

However, like the follicular carcinomas, both the papillary carcinoma TMA cores and tissue sections showed an up-regulation in p16 expression compared to normal thyroid, with a median I.D. score of 0.75, ( $p = 0.001$ ). This



tumour group had a wider range of p16 I.D. scores than the follicular carcinomas, and also had higher p16 I.D. scores than those seen in the follicular cancer group. There was a group of papillary TMA cores that demonstrated a down-regulation or loss of p16 expression.

Papillary carcinomas develop from a different set of genetic mutations than the follicular tumours. Together with RAS mutations, they also arise from BRAF mutations and RET/PTC rearrangements. This may be one of the reasons for the greater variation in p16 I.D. scores in the papillary carcinomas, and the level of up- or down-regulation of p16 expression may depend on whether the tumour has a RAS, BRAF or RET mutation.

One reason for the down-regulation or loss of p16 expression seen in a subgroup of the papillary carcinomas could be the difference in differentiation between this group and the remainder of the cancers. Papillary carcinomas can be either well- or poorly-differentiated, with the poorly-differentiated cancers having a worse clinical prognosis. If p16 is lost at a later stage in thyroid tumorigenesis, I would expect the poorly-differentiated tumours to lose p16 expression. I am not able to confirm whether this hypothesis is correct, because the pathology reports for the TMA cores do not mention whether each tumour is well- or poorly differentiated.

Insular carcinomas are poorly-differentiated tumours, and develop at a later stage in the thyroid tumorigenesis pathway. They are therefore a more aggressive tumour with a higher proliferation rate than the well-differentiated follicular and papillary tumours. This tumour group, like the atypical adenomas

demonstrated a wide range of p16 I.D. values. As a group, there was a statistical increase in p16 expression in the insular carcinoma TMA cores when compared to normal thyroid tissue (median p16 I.D. score 1.00,  $p < 0.001$ ).

However, the insular cancers could be divided into three groups based on their p16 I.D. scores. Half the tumours showed weak or moderate staining similar to that seen in the follicular and papillary carcinomas. One quarter of the tumours demonstrated intense p16 staining, at a level comparable to that of the atypical adenomas, and these tumours had higher scores than either the follicular or papillary carcinomas. The final quarter of cases had either a down-regulation or loss of p16 expression, similar to that seen in the subgroup of papillary cases. The analysis of the insular carcinoma full tissue sections also demonstrated two sub-groups, one with an increase in p16 expression compared to the follicular and papillary carcinomas, and one with a complete loss of p16 expression.

Finally, I also performed p16 immunohistochemistry on two anaplastic carcinomas, both derived from a papillary carcinoma, with both anaplastic and papillary tumours represented on each slide. The papillary carcinoma sections showed an up-regulation in p16 expression, and the anaplastic carcinoma sections showed a down-regulation in p16 expression compared to the neighbouring papillary tumour. The data from the insular and anaplastic carcinomas suggests that a down-regulation or loss of p16 expression is only seen at a late stage in thyroid tumorigenesis, in the poorly- or undifferentiated carcinomas.

I correlated the expression of p16 to the proliferation status of the thyroid tissue using two proliferation markers, MCM2 and cyclin A. MCM2 belongs to a family of six proteins (MCM 2 – 7) that are essential for the initiation and regulation of DNA replication (Mendez and Stillman, 2000; Labib et al., 2001). They were first discovered in yeast, and form part of the replicative complexes (Meng et al., 2001) ensuring that chromatin is competent for replication. After S phase, the MCM proteins irreversibly dissociate from chromatin, so that DNA replication only occurs once during each cell cycle.

The proteins are expressed in all phases of the cell cycle, and their expression depends on the proliferative state of the cell. They are not present in quiescent or terminally differentiated cells (Madine et al., 2000; Stoeber et al., 2001). The presence of MCM2 protein expression implies that a cell is either replicating, or has the potential to replicate. Their expression level has been inversely correlated with the degree of tumour differentiation (Stoeber et al., 2001).

MCM2 expression was negligible in normal thyroid specimens, and this was expected since the thyroid is a quiescent tissue. The follicular and atypical adenoma groups both showed a seven-to-eight fold increase in MCM2 expression, and this was a significant increase when compared to normal thyroid tissue.

The follicular carcinoma group also demonstrated an up-regulation of MCM2 expression. Although this was smaller than that seen in the adenoma groups, it was still significantly greater than normal thyroid tissue. The papillary

carcinoma group had the greatest up-regulation of MCM2 expression, with a 20-fold increase compared to normal thyroid tissue, suggesting that papillary carcinomas have a greater potential to proliferate than follicular carcinomas. The insular carcinomas also had an up-regulation of MCM2 expression, but this was similar to that seen in the follicular adenomas and carcinomas.

The expression of MCM2 protein has been assessed in the literature as a potential marker to identify neoplasia. Freeman et al., (1999), analysed MCM2 expression in a wide variety of normal and malignant tissues, and showed that in normal tissues, MCM2 protein expression was confined to proliferative compartments, whilst it was expressed in the majority of dysplastic and malignant tissues. MCM2 proteins may have an important role in tumour detection, with Williams et al., (1998), using positive MCM2 staining to identify both low-grade and high-grade pre-malignant cervical carcinomas from normal cervical tissue. MCM2 staining has also been used to detect bladder carcinoma cells in urine (Stoeber et al., 1999). It has been highlighted as a potential molecular marker of clinical outcome in prostate carcinoma (Meng et al., 2001) and breast carcinoma (Gonzalez et al., 2003), and as a tool for detection of colorectal carcinoma in stool (Davies, R.J. et al., 2002).

My data suggests that the observed up-regulation of MCM2 expression seen in the follicular adenomas and follicular and papillary carcinomas could potentially be used as a molecular marker to identify thyroid neoplasms from normal thyroid tissue. However it is unlikely that MCM2 could be used to accurately identify follicular carcinomas from follicular adenomas, since both tumour groups had similar levels of MCM2 expression.

The second proliferation marker that I used was cyclin A. This protein is maximally expressed during the S-phase of the cell cycle (Pines and Hunter, 1989, Yam et al., 2002). Cyclin A is synthesized during DNA replication and at the G2/M transition point of the cell cycle (Bukholm et al., 2003). It is involved in both transcription and replication, and is a marker for cells that are in the S-phase of the cell cycle (Pagano et al., 1992; Zindy et al., 1992), and therefore is expressed in cells that are actively proliferating.

Cyclin A expression, like MCM2 expression, was negligible in normal thyroid specimens, and this was expected because the thyroid is a quiescent tissue. The follicular adenoma group showed an eight fold increase in cyclin A expression. This was also expected because follicular adenomas are slow-growing, indolent tumours. Surprisingly, eight out of ten atypical adenomas did not express cyclin A protein. These tumours are thought to be an intermediate phase between normal thyroid tissue and anaplastic tissue, and I therefore expected them to have a higher proliferation rate than the benign adenomas. One explanation for the low proliferation rate is that the atypical adenomas are being kept 'in check' until further genetic mutations are acquired before de-differentiation and a subsequent increase in proliferation rate.

The follicular cancers, like the follicular adenomas, showed a small increase in cyclin A expression when compared to normal thyroid tissue (median L.I. = 0.10). The two micro-papillary carcinomas that were analysed over-expressed cyclin A when compared to the adjacent normal thyroid tissue, and the TMA papillary carcinomas also over-expressed cyclin A, although this was also at a low level, similar to that seen in the follicular adenomas and carcinomas. This

data is in keeping with the indolent nature of both of these thyroid cancer types.

In the insular carcinoma group however there was a much larger, 20-fold increase in cyclin A expression when compared to normal thyroid tissue, in contrast to the relatively low levels of MCM2 protein expression seen in this tumour group. The insular carcinoma full issue sections also demonstrated a considerable up-regulation of cyclin A expression when compared to the adjacent normal thyroid tissue. This data is in keeping with the more aggressive nature of these tumours, and their higher proliferative rate.

Cyclin A expression has been studied in the literature as an alternative molecular marker of neoplasia or clinical prognosis. Scott et al., (2003), analysed cyclin A expression in colorectal carcinomas, and observed an increase in the expression of cyclin A in colonic adenomas and carcinomas when compared to normal colonic tissue, which suggests an increased entry into S-phase for malignant colonic cells. Scott's study compared cyclin A expression with MCM2 expression in colorectal tumours, and observed an increase in MCM2 expression from 54.9% to 66.8% when comparing normal colon with adenocarcinoma, and an increase in cyclin A expression from 19.7% to 37.4%, with a significant positive correlation between the two proliferative markers. Furihata et al., (1997) showed an increase in cyclin A expression in transitional cell carcinoma (TCC) of the renal pelvis, and over-expression was related to a poorer prognosis. Cyclin A over-expression was also noted in dysplastic lesions, indicating that this may be an early event in TCC carcinogenesis.

My analysis of these two proliferation markers in thyroid adenomas and carcinomas has added to the few studies in the literature using MCM2 and cyclin A expression to assess thyroid cancer proliferation. Mehrota et al., (2006), observed an up-regulation of MCM2 expression in papillary and follicular carcinomas when compared to follicular adenomas, and Guida et al., (2005) showed an up-regulation of MCM5 and MCM7 in anaplastic thyroid carcinoma, with negligible staining in normal thyroid tissue and papillary carcinomas. Ito et al., (2002), observed that cyclin A over-expression was significantly linked to carcinoma differentiation, with anaplastic carcinomas having a greater expression than follicular and papillary carcinomas, suggesting that this protein is involved in the rapid progression of poorly-differentiated and un-differentiated thyroid tumours.

My data suggests that the observed up-regulation of cyclin A expression could not be reliably used as a molecular marker of neoplasia, because of the negligible expression of cyclin A protein in the follicular adenomas. It also appears that cyclin A expression would not be a useful indicator of clinical prognosis, because the expression levels were generally similar in the well-differentiated and the poorly-differentiated tumours, although several of the insular carcinomas did have far greater levels of cyclin A expression than the follicular and papillary carcinomas.

There was not a significant correlation between the expression of p16 and both MCM2 and cyclin A in the follicular adenomas and follicular carcinomas. This was expected because both of these tumours are slow-growing with a low

proliferative rate. I demonstrated a significant positive correlation between p16 expression and cyclin A expression in the papillary carcinomas, although the level of cyclin A expression remained at a low level when compared to the insular carcinomas.

It is only at the more aggressive stages of poorly-differentiated (insular) or undifferentiated (anaplastic) carcinoma that our data suggests the presence of abnormalities of the p16 pathway, as evidenced by loss of expression in some tumours or, paradoxically by very high-level expression in others, the latter being a well-recognised secondary response to downstream defects such as loss of pRb function. Unfortunately, these relatively rare tumours have not been sufficiently investigated at the genetic level to provide corroborating evidence.

The suggestion that the inhibitory effect of p16 is lost in these cancers is highly consistent with their dramatically increased proliferative rate. The analysis of the insular carcinoma group lends some evidence towards this. Those insular tumours with a high p16 I.D. score had a low cyclin A L.I. value, and vice versa, suggesting that loss of p16 expression correlates with an increase in proliferation. Interestingly, this increase in cyclin A expression in the poorly-differentiated carcinomas was not matched by the expression of MCM2, which was elevated in all stages of thyroid tumorigenesis. One explanation for this may be that MCM2 expression, unlike cyclin A, can be elevated in cells which although exited from G0 are arrested in G1 and are not actively cycling (Stoeber et al., 2001).



There are potential problems that can arise when analysing TMA cores, because only a tiny portion of the tumour is represented with each core. To improve the accuracy of immunohistochemical results, three cores were taken from each tumour and an average p16 I.D. or MCM2 / cyclin A L.I. score was calculated for each tumour. I assumed that the cores are an accurate representation of the original tissue. However, if a tumour only has a small area of focal staining, which is not included in a core, that core will not provide a true depiction of p16 protein expression in that tumour. Conversely, if a core is taken from such a focus of staining in an otherwise negatively-staining tumour, that core will also falsely represent the staining pattern in that tumour. By performing immunohistochemistry on full tissue sections I was able to corroborate my results with those of the TMA cores, and both sets of slides produced similar patterns of p16 expression in follicular adenomas, follicular and papillary carcinomas.

I only had access to a limited number of TMA slides, and was therefore unable to repeat the staining to confirm results that were either a lot higher or lower than those obtained for the rest of the cores within a tumour group. I was blinded to the pathological diagnoses of each TMA core to reduce bias when scoring each core for p16, MCM2 and cyclin A expression. However I was not blinded to the pathology of the full tissue sections, and this is a potential source of bias when interpreting the immunostaining for these slides.

Care must also be taken when comparing my data with that of other published studies. The presence of conflicting results in the literature can be attributed to different immunohistochemistry protocols and the use of different antibodies.

Another factor that can produce discrepant results between studies is the use of different scoring systems to interpret the staining pattern. Therefore conclusions can only accurately be drawn when comparing studies that used the same methodology and scoring systems, and this can be hindered if these are not accurately described.

Several genetic analyses of p16 in thyroid tumour cell lines and primary thyroid tumours have been published. The majority of these studies reported that a structural alteration of the p16 gene was common in thyroid tumour cell lines. Calabro et al., (1996), reported deletions, point mutations and structural gene alterations in four thyroid cancer cell lines, and Jones et al., (1996), observed homozygous deletion of the entire p16 coding sequence in both follicular and papillary cancer cell lines. Elisei et al., (1998), reported point mutations, deletions and loss of heterozygosity in cell lines from poorly and undifferentiated thyroid carcinoma cell lines. This suggests that p16 may be a key tumour suppressor gene in early thyroid tumorigenesis, although Yane et al., (1996), found no evidence of gene deletion or mutation in thyroid cancer cell lines.

In contrast, alteration of the p16 gene appears to be a rare event in primary well-differentiated thyroid tumours. Elisei et al., (1998), observed a point mutation in one of 12 papillary carcinomas and no mutations in follicular adenomas. Neither Yane et al., (1996), nor Calabro et al., (1996), found evidence of p16 genetic abnormalities in primary follicular, papillary and anaplastic thyroid carcinomas. Similarly, Tung et al., (1996), only found p16

mutation (loss of heterozygosity) in the minority of follicular and papillary thyroid tumours; however this study reported p16 mutations in two out of four anaplastic tumours.

Hypermethylation is an alternative mechanism for gene inactivation. Boltze et al., (2003), used a methylation-specific polymerase chain reaction to analyse p16 methylation in thyroid tumorigenesis. They detected this in 13% normal thyroid tissue, 33% follicular adenomas, 44% papillary and 50% follicular carcinomas, and in 85% undifferentiated carcinomas and this correlated with the loss of p16 protein expression. Their data suggests that p16 methylation is a common early event in thyroid tumorigenesis, and is associated with dedifferentiation of thyroid cancers. They also demonstrated p16 immunohistochemical expression in 87% normal tissue, in contrast to my own results. Hoque et al., (2005) also studied p16 promoter hypermethylation in follicular adenomas and follicular and papillary carcinomas. This group failed to detect p16 hypermethylation in either the adenomas or the carcinomas, in contrast to the results obtained by Boltze's group.

Although hypermethylation of the p16 gene has been detected by Boltze et al., (2003), in both well-differentiated and undifferentiated thyroid carcinomas, Hoque et al., (2005) were unable to detect hypermethylation well-differentiated carcinomas, and it is therefore difficult to ascertain the true prevalence of p16 promoter hypermethylation in thyroid tumorigenesis in light of such conflicting results.

Our published observations with regard to p16 expression in thyroid tumours (Ball et al., 2007) are consistent with several published studies at the DNA and RNA level, which indicate that genetic abnormalities of p16 such as point mutations and loss of heterozygosity in benign tumours and well-differentiated cancers are rare (Calabro et al., 1996; Tung et al., 1996; Yane et al., 1996; Elisei et al., 1998), in contrast to the frequent inactivation of p16 by gene deletion, mutation or methylation in thyroid cancer cell lines in vitro (Wyllie et al., 1995; Calabro et al., 1996; Elisei et al., 1998). Although hypermethylation of the p16 gene in vivo has been detected by Boltze et al., (2003), in both well-differentiated and undifferentiated thyroid carcinomas, Hoque et al., (2005) were unable to detect hypermethylation in well-differentiated carcinomas, and it is therefore difficult to ascertain the true prevalence of p16 promoter hypermethylation in thyroid tumorigenesis in light of such conflicting results.

Our results are also in agreement with a more limited, immunohistochemical study of p16 in thyroid tumours (Ferenc et al., 2004a). This group detected p16 protein over-expression in 19.3% follicular adenomas and 66.7% follicular carcinomas. Several studies have been published that have analysed p16 expression using immunohistochemistry in thyroid tumours following the submission of my own work for publication. Barroeta et al., (2006), analysed 53 benign and 37 malignant follicular-derived thyroid tumours, and reported p16 expression in 2% adenomas and 46% carcinomas. One reason for the low rate of expression in the benign tumour group is their high cut-off point for a positive result of 25% cells showing positive staining. Ferru et al., (2006), reported similar results to my own findings, with over-expression of p16 in follicular adenomas, and follicular and papillary carcinomas. Lam et al.,

(2007), analysed 44 cases of papillary thyroid carcinoma and observed p16 over-expression in 89% cases. This data gives support to my own data which shows that p16 is genuinely up-regulated in early thyroid tumorigenesis, and that this expression of the protein increases in well-differentiated thyroid tumours.

Although it was initially speculated that these alterations of the p16 gene may be due to a cell culture artefact, loss of p16 function and/or expression has been clearly demonstrated in many primary carcinomas. In non-small cell lung carcinomas, loss of p16 expression is demonstrated in 36.3 – 43% of tumours, and is associated with a worse clinical prognosis (Kashiwabara et al., 1998; Huang et al., 2000; Cheng et al., 2003; Geradts, 2003). Hu et al., (1997), Schutte et al., (1997), Kawesha et al., (2000) and Gerdes et al., (2002) showed loss of p16 expression in 41.9 - 87% pancreatic carcinomas, and an association with worse histological grade, shorter survival times and metastasis in those cases with loss of p16 expression.

Our finding that the loss of p16 expression / function is correlated with relatively “late” stages of tumorigenesis is also consistent with data from other tumour types, notably colorectal cancer and malignant melanoma. Palmqvist et al., (2000), and Zhao et al., (2003) demonstrated low p16 expression in normal colonic mucosa, an up-regulation of p16 expression in colorectal adenomas, and a further increase in p16 staining intensity in the majority of colorectal carcinomas although a select sub-group of colorectal cancers did show loss of p16 expression, and Palmqvist questioned whether this loss of

p16 expression was a lack of initial up-regulation rather than a genuine down-regulation of expression.

This finding was also demonstrated by Dai et al., (2000), who analysed cyclin A and p16 expression in colonic neoplasms, and reported that colorectal cancers demonstrated an up-regulation in p16 expression which correlated inversely with cyclin A expression and therefore proliferation. The increase in cyclin A expression was also correlated with a worse prognosis, and p16 and cyclin A staining were mutually exclusive, suggesting that p16 is functional in inhibiting the G1/S phase checkpoint of the cell cycle and thereby preventing proliferation of a tumour.

Likewise, in malignant melanomas both Reed et al., (1995), and Polsky et al., (2001), observed that loss of p16 expression was not essential for tumour progression, with the majority of melanomas-in-situ and primary invasive tumours retaining p16 protein expression. Reed showed that loss of p16 expression was related to the ability for a melanoma to metastasise, with 52% primary invasive tumours and 72% metastatic tumours showing a partial or complete loss of p16 expression.

There are several potential explanations for the variations seen in p16 expression over the spectrum of thyroid tumorigenesis. Because p16 is not normally expressed in human tissues, the up-regulation seen in adenomas and carcinomas in a wide range of human malignancies must at least partly be in response to the oncogenic events involved in tumour initiation. Expression of

the p16 protein appears to be driven by features of the neoplastic state. This may simply be in response to an increase in proliferation of the tumour cells, and therefore p16 stalls the cells at the G1/S phase checkpoint, allowing the cell the chance to repair initiating neoplastic genetic alterations, or p16 may act through other pathways, as it has been linked to angiogenesis and anoikis (loss of epithelial cell anchorage) from in vitro studies, as reviewed by Rocco and Sidransky (2001).

Another suggestion is that the cells lose the expression of a downstream protein in the Rb pathway, such as Rb protein itself. Cells without a p16 mutation would continue to over-express p16, but this would be ineffectual in the presence of abnormal Rb protein. However those cells that had acquired a p16 mutation would not have a selective advantage because of the downstream mutation in the Rb pathway. Alternatively, there may be an alternative pathway implicated in tumorigenesis that functions independently of the Rb pathway, and therefore a p16 gene mutation would also give the clone of cells a selective advantage.

It is of course possible that the changes in p16 observed here do not reflect any causal role in tumour progression. However, this seems extremely unlikely, given the wealth of experimental evidence both from in vitro and experimental animal studies supporting the importance of p16 as a tumour suppressor gene and indeed the albeit-indirect evidence here for abnormality of the pathway in late stage thyroid tumours. We propose therefore the following model.

We suggest that p16 expression is induced in early stage tumours as a response to oncogene activation (e.g. RAS or RET) and / or an inappropriately extended proliferative lifespan (Jones et al., 2000; Skinner et al., 2004). The expression of this cell cycle inhibitor reaches a level sufficient to severely limit, but not to totally block oncogene-induced proliferation. This restraint is maintained even if and when further oncogenic events result in malignant transformation (conferring the ability to invade and metastasise) hence explaining the characteristically slow growth of well-differentiated thyroid cancers. In rare cases however, loss of the p16 pathway subsequently occurs, either through loss of p16 expression itself, or through downstream lesions (resulting in paradoxical increase in expression) which allows a much more rapid and aggressive pattern of tumour growth as seen in insular and anaplastic cancers.

One striking feature of thyroid tumorigenesis that this simple model does not adequately explain, however, is the rarity with which progression from the slowly-proliferating well-differentiated to the rapidly growing insular or undifferentiated cancers occur in practice. This would not be expected if p16 were the only rate limiting step in this process since firstly there would clearly be an extremely strong selection pressure for loss of p16, and secondly, loss of p16 expression (notably through promoter methylation) appears to be a particularly high-frequency genetic event in human cancers in general.

To complete the model, we speculate therefore that in thyroid tumorigenesis, as opposed to many tumour types, either there is an unusually low spontaneous frequency of p16 inactivation, or more likely, that there is



redundancy in growth control, such that p16 is just one of two (or more) growth inhibitory pathways, all of which must be inactivated within the same cell in order for progression to the aggressive phenotype to occur. Such a “belt and braces” regulatory system would neatly explain why most thyroid cancers carry such a favourable prognosis.

### 3.5 Conclusions

- p16 is not normally expressed in normal thyroid tissue
- Consistent with our in vitro data, p16 expressed in follicular adenomas and micro-papillary carcinomas
- P16 continues to be over-expressed in follicular and papillary carcinomas, and the increase in expression in comparison with the follicular adenomas is statistically significant
- Loss of p16 expression was only seen at a late stage of tumorigenesis, in a sub-group of insular carcinomas, and in anaplastic carcinomas
- A dramatic increase in cyclin A expression, and therefore tumour proliferation, was only seen in the insular carcinomas, and correlated with loss of p16 expression.
- This work represents the most comprehensive study to date regarding p16 expression and proliferation in multi-step thyroid tumorigenesis
- We speculate that another pathway must also be involved in the progression from well- to poorly- and un-differentiated thyroid carcinomas, which may be p16-dependent or ip16-independent

### **3.6 Further work**

In order to investigate whether the immunohistochemical expression of p16, MCM2 or cyclin A is associated with a worse clinical prognosis or the presence of metastatic disease, long-term clinical follow-up is needed of the patients who donated thyroid tissue for research purposes. In order to fully assess whether p16 is truly down-regulated in anaplastic carcinomas, the study should ideally be repeated with larger numbers of anaplastic carcinomas, and equivalent numbers of cases for all the thyroid tumour groups studied. However, this may be difficult to achieve because of the low incidence of thyroid cancer, as stated in chapter 1, and because of the rarity of transformation of thyroid cancers to the undifferentiated phenotype.

Since the role of the Rb pathway in early thyroid tumorigenesis is still unclear, the immunohistochemical analysis of the expression of other proteins in this pathway, such as p21 and cyclin D1, will further elucidate the function of this pathway in thyroid tumorigenesis, and this will form the basis of chapter 4. In order to investigate potential candidates for the second, as yet undiscovered pathway involved in early thyroid tumour progression, our laboratory is analysing gene expression in thyrocyte end-stage RAS colonies. This has the potential to highlight unexpected genes that may be involved in this pathway, and chapter 5 concerns the protein expression of some of these genes in benign and malignant thyroid tumours.

## CHAPTER 4

### AN IMMUNOHISTOCHEMICAL STUDY OF p21<sup>WAF1/Cip1</sup> AND CYCLIN D1 EXPRESSION IN MULTISTEP THYROID TUMORIGENESIS

#### 4.1 Introduction

Having previously investigated p16 expression in thyroid cancers and identified that loss of p16 expression was not a key event in early thyroid tumorigenesis, I looked at the protein expression of the following two potential candidates, cyclin D1 and p21<sup>WAF1/Cip1</sup>, in follicular adenomas, and follicular and papillary carcinomas, which had previously analysed for p16 expression. This novel research will contribute to the existing knowledge regarding the function of these proteins in thyroid tumorigenesis, and explore the potential relationships between p16 and cyclin D1 / p21 expression in the progression from benign to malignant thyroid cancers.

The loss of regulation and control of the cell cycle, leading to uncontrolled cell proliferation, is a hallmark of cancer (Hanahan and Weinberg, 2000). Progression through the cell cycle is driven by the sequential activation and inactivation of cyclin-dependent kinases (CDK). These enzymes are activated when they bind to cyclins, their regulatory subunits (Hartwell and Kastan, 1994). The cyclin D – cdk4/6 complexes phosphorylate pRB protein, releasing E2F transcription factors and allowing the cell to progress from G1 to S phase (Nevins, 2001). These events also enable the activation of cyclin E-cdk2 and cyclin A - cdk2, which are essential for S phase. There are several key checkpoints which control the cell cycle, with one of the most important

checkpoints at the G1/S phase stage of the cell cycle (Murray, 1994). The p53 protein is one of the most important proteins controlled by the G1/S phase checkpoint. If a cell has genomic abnormalities or DNA damage, the p53 pathway is activated to arrest the cell in G1 until the DNA is repaired or the cell undergoes apoptosis (Vogelstein and Kinzler, 1992). Inactivation of both the Rb and the p53 pathways is a key requirement for tumorigenesis in most human malignancies.

The cyclin proteins therefore control the passage of the cell through the G1/S phase checkpoint (Sherr, 1995; Hall and Peters, 1996; Pestell et al., 1999). The connection between cyclin D and tumorigenesis was made with the discovery of over-expression of the PRAD1 (cyclin D1) gene, located at 11q13, in parathyroid adenomas (Motokura et al., 1991). Over-expression of cyclin D1, by either translocation or amplification of the gene, has been implicated in the development of several human malignancies (Ewen and Lamb, 2004), such as breast (Buckley et al., 1993; Zhu et al., 1998), bladder (Takagi et al., 2000), oesophageal (Jiang et al., 1992) and head and neck carcinomas (Smith et al., 2001). This up-regulation is thought to overwhelm the checkpoints of the normal cell cycle, and lead to uncontrolled cell proliferation (Dirks and Rutka, 1997). Cyclin D1 over-expression has been associated with a higher incidence of lymph node metastases, a poor clinical prognosis and more aggressive tumour behaviour (Khoo et al., 2002a).

Alternatively, instead of over-expression of positive growth regulators such as the cyclins, under-expression of cyclin-dependent kinase inhibitors (cki) such as p16 and p21 leads to uncontrolled cell proliferation. Our tissue culture work

on p16 expression in thyrocytes led us to believe that p16 was a key tumour suppressor gene in early thyroid tumorigenesis; however my work in chapter 3 did not confirm this. Another candidate tumour suppressor gene for is p21.

The p21<sup>WAF1/Cip1</sup> gene was the first cki to be identified (el-Deiry et al., 1993; Harper et al., 1993), and is a direct regulator of cdk activity and a mediator of p53-induced growth arrest. The actions of p21 have been thoroughly reviewed by Sherr and Roberts (1999), and Dotto, (2000). p21 is a direct transcriptional target of p53, and it mediates the growth-inhibitory effects of p53 by arresting the cell cycle in G1 phase (el-Deiry et al., 1994). At low cellular concentrations, it facilitates the formation of cyclin D1 – cdk4/6 complexes, whilst at higher concentrations it inhibits cyclin D1 - cdk4/6 and cyclin E - cdk2 complexes (Harper et al., 1995) and prevents the cell entering S phase. P21 is also activated by p53-independent mechanisms and is involved in terminal differentiation, cellular senescence and apoptosis (Zeng and el-Deiry, 1996; Lundberg and Weinberg, 1999). Therefore a decreased expression of p21 would be expected in human tumours, with a resulting increase in cell proliferation.

Having previously established that p16 is up-regulated during the transition from normal thyroid tissue to a follicular adenoma, I hypothesised that p21 would also be up-regulated in follicular adenomas, acting as a tumour suppressor gene to prevent uncontrolled cellular proliferation. However, because of the unexpected continued up-regulation of p16 in both follicular and papillary carcinomas, I was uncertain whether p21 would also be expressed in these tumours, and what the relationship between these two

tumour suppressor genes would be at this stage of thyroid tumorigenesis. I also hypothesised that cyclin D1 expression would be induced in the follicular adenomas, in response to the increase in cell proliferation, and that cyclin D1 would be further up-regulated in both the follicular and papillary carcinomas. Additionally, this suggested increase in cyclin D1 expression in the carcinomas could be correlated with a reciprocal down-regulation in p21 expression. By correlating both cyclin D1 and p21 expression with p16 expression in benign and malignant thyroid tumours, I will be able to provide new information regarding the function of this molecular pathway in thyroid tumorigenesis.

## 4.2 Method

### 4.2.1 Immunohistochemistry

I performed immunohistochemistry on formalin-fixed, paraffin-embedded tissue sections and tissue microarrays (TMAs) following heat-mediated antigen retrieval in 10mM EDTA pH 9.0, using a microwave oven (20 minutes at 800W). I pre-treated the slides with a DAKO peroxidase-blocking solution (DakoCytomation) prior to incubation for one hour at room temperature with one of the following antibodies: -

- (i) mouse monoclonal anti-cyclin D1 antibody clone DCS-6 (DakoCytomation) at a dilution of 1:50
- (ii) mouse monoclonal anti-p21 antibody clone SX118 (DakoCytomation) at a dilution of 1:50

Secondary amplification was accomplished using the DAKO Envision<sup>+</sup>™ kit, and I visualised antibody binding using DAB chromogen (DakoCytomation), followed by counterstaining with haematoxylin.

### 4.2.2 Scoring of slides

#### 4.2.2.1 cyclin D1

I assigned five hundred cells per sample to an intensity category of 0 (absent), 1 (weak), 2 (moderate), or 3 (strong) and the percentage of cells in each intensity category was determined as  $N_0$ ,  $N_1$ ,  $N_2$ , and  $N_3$  respectively. I then calculated a weighted average (Intensity Distribution, I.D. score, range 0 - 3) as follows:-



$$\text{I.D.} = [(N_0 \times 0) + (N_1 \times 1) + (N_2 \times 2) + (N_3 \times 3)] / 100$$

#### 4.2.2.2 p21

I counted five hundred cells per sample, and calculated the percentage of positive-staining nuclei (labelling index, L.I.). All cells showed the same degree of staining intensity therefore this was not factored into the scoring system.

### 4.3 Results

I performed a literature search to identify anti-cyclin D1 and anti-p21 antibodies that had been used for immunohistochemistry of formalin-fixed, paraffin-embedded tissues. I selected an anti-cyclin D1 and an anti-p21 antibody that had both been thoroughly validated in the literature.

Bartkova et al., (1994), developed the mouse monoclonal antibody DCS-6 against cyclin D1 and validated it by immunoblotting. This antibody showed strong reactivity with recombinant cyclin D1, and a lack of cross- reaction both with cyclins D2 and D3, and in human cell lines not expressing cyclin D1 mRNA. The antibody has since been widely used in the literature for immunohistochemistry on formalin-fixed, paraffin-embedded tissues.

The p21 antibody, clone SX118, was generated by Fredersdorf et al., (1996), and validated against cell lines known to be positive and negative for p21 using an enzyme-linked immunosorbent assay (ELISA), which provided a molecular basis for the SX118 antibody to immunoblot and immunoprecipitate human p21. They then used this antibody to analyse p21 expression in human tissues, including normal thyroid tissue, using immunohistochemistry, and only observed a positive reaction in occasional thyroid epithelial cells.

For both cyclin D1 and p21 immunohistochemistry I used isotype-matched mouse monoclonal anti-prolactin antibody at an equivalent dilution (1:50), and antibody diluent solution (DakoCytomation) as negative controls.

#### 4.3.1 Expression of cyclin D1

Four normal thyroid tissue sections did not show cyclin D1 staining (Figure 4.1). I analysed ten follicular adenomas, and the majority (80%) showed an up-regulation in cyclin D1 expression when compared to normal thyroid tissue (median cyclin D1 I.D. score = 0.43). Two out of the ten cases did not show cyclin D1 expression, four cases showed weak cyclin D1 expression (I.D. range 0.2 - 0.45), and four cases had moderate cyclin D1 expression (I.D. range 1.1 - 1.7). Examples of two follicular adenomas with moderate cyclin D1 staining are shown in Figure 4.2.

Eight follicular carcinomas all showed an up-regulation of cyclin D1 expression compared to normal thyroid tissue and the follicular adenomas (median cyclin D1 I.D. score = 1.35). Three of the eight cases had weak cyclin D1 expression (I.D. range 0.4 - 0.8), four of the eight cases had moderate cyclin D1 expression (I.D. range 1.3 - 1.5), and the remaining case showed strong cyclin D1 expression (I.D. 2.3). Examples of two follicular carcinomas with moderate and strong cyclin D1 staining are shown in Figure 4.3.

The seven papillary carcinomas, like the follicular carcinomas, also showed an up-regulation of cyclin D1 expression when compared with normal thyroid tissue and the adenomas (median cyclin D1 I.D. score = 1.2). One tumour was negative, two of the seven cases had weak cyclin D1 expression (I.D. range 0.5-0.6), and four tumours had moderate cyclin D1 expression (I.D. range 1.2-1.7). Examples of two papillary carcinomas with moderate cyclin D1 staining are shown in Figure 4.4.

Chart 4.1 graphically represents the range of cyclin D1 I.D. values of the follicular adenomas, and the follicular and papillary carcinomas. All three tumour groups over-expressed cyclin D1 when compared to normal thyroid tissue, which did not show cyclin D1 expression. However, the follicular and papillary carcinomas had a higher median cyclin D1 I.D. score than the follicular adenomas.

The median cyclin D1 values for the follicular adenomas, follicular and papillary carcinomas, together with the first and third quartiles are represented as a box plot in Chart 4.2. This graph clearly demonstrates the increase in cyclin D1 expression observed in the transition from adenoma to carcinoma. The cyclin D1 results for every tumour analysed in this study are summarised in Tables 4.1, 4.2 and 4.3.

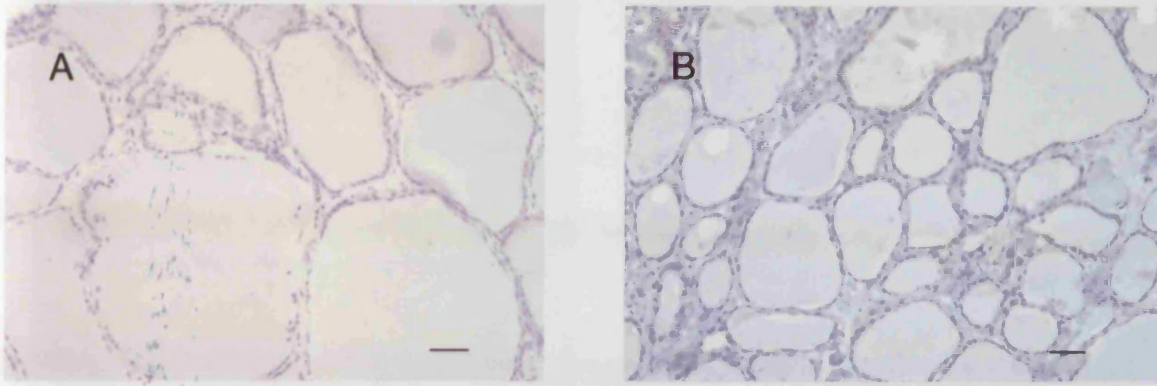


Figure 4.1 Immunohistochemical staining with anti-cyclin D1 antibody of two samples of normal thyroid tissue, showing the absence of cyclin D1 expression. Scale bar represents 200  $\mu\text{m}$ .

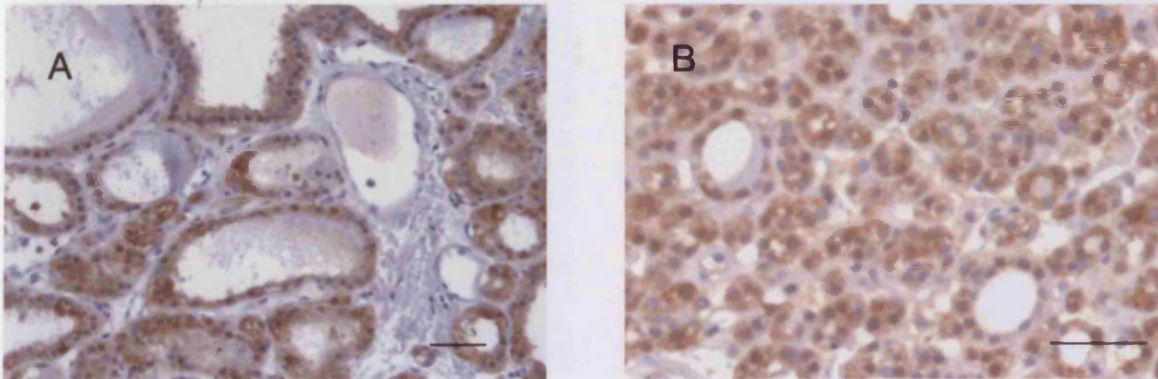


Figure 4.2 Immunohistochemical staining with anti-cyclin D1 antibody of two cases of a follicular adenoma, showing one adenoma with moderate staining (A), and one with both weak and moderate staining (B). Scale bar represents 200  $\mu\text{m}$ .



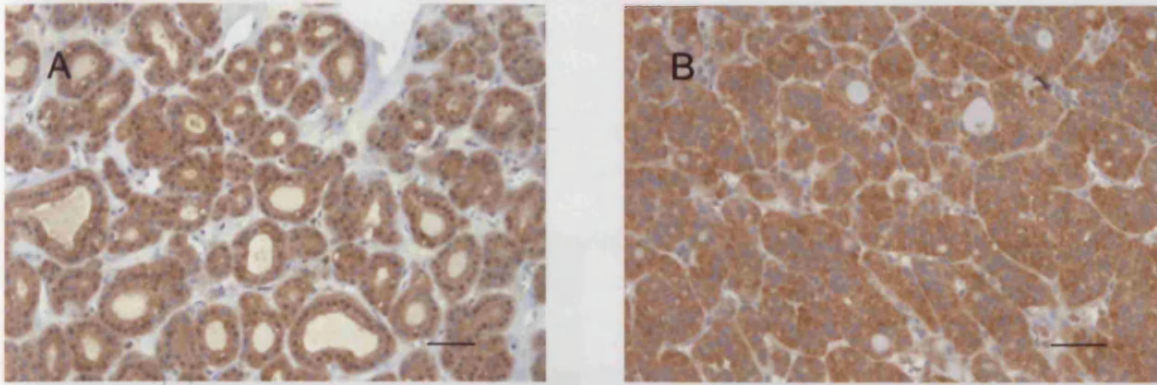


Figure 4.3 Immunohistochemical staining with anti-cyclin D1 antibody of two cases of a follicular carcinoma. Case A shows moderate cyclin D1 expression, and case B shows strong cyclin D1 expression. Scale bar represents 200  $\mu\text{m}$ .

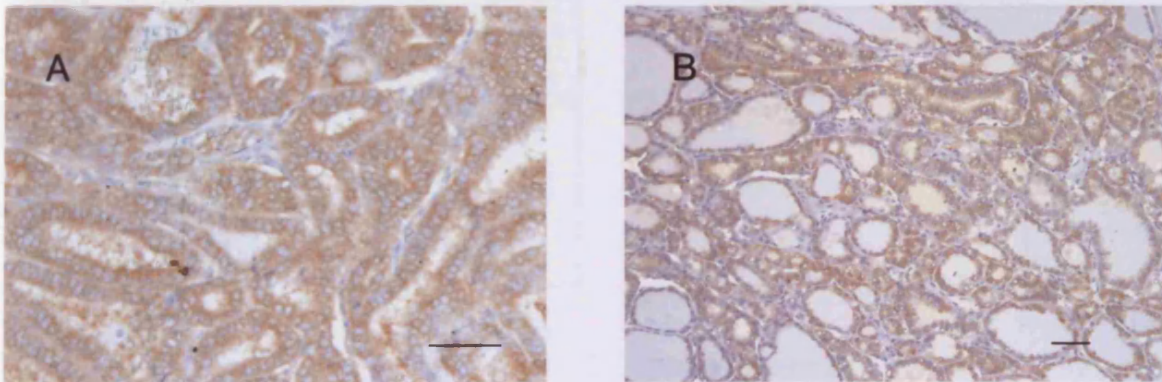
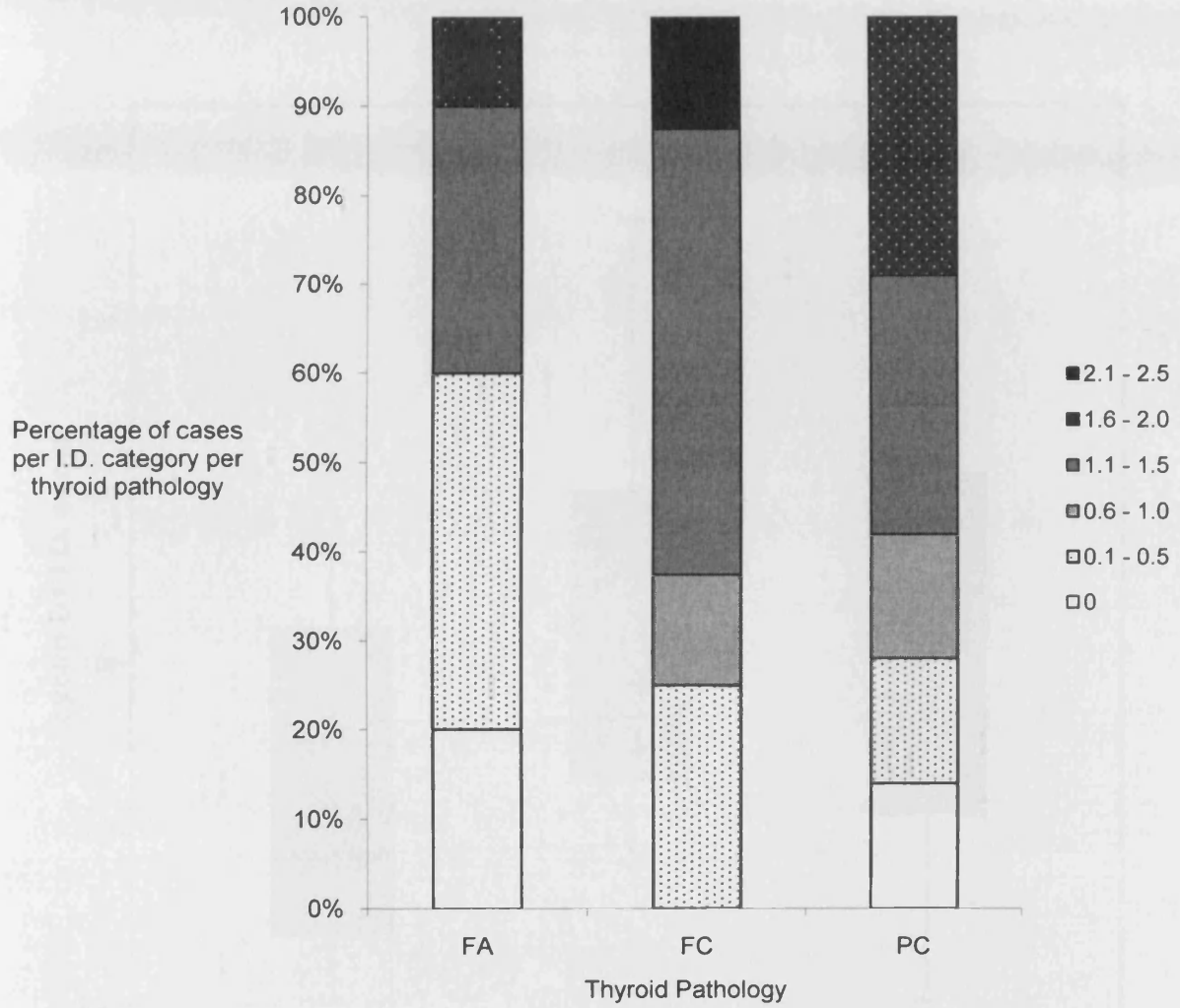


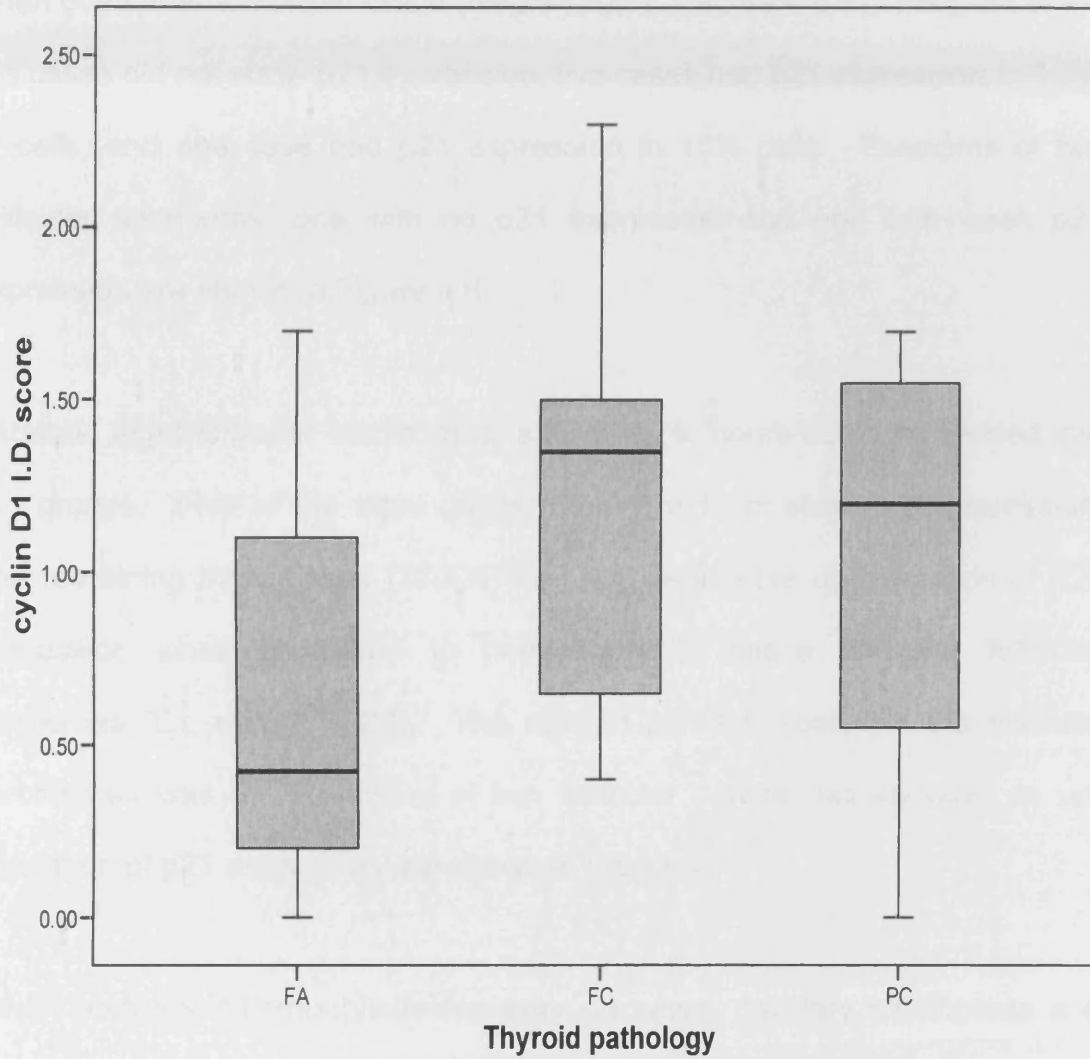
Figure 4.4 Immunohistochemical staining with anti-cyclin D1 antibody of two cases of a papillary carcinoma. Cases A and B show moderate cyclin D1 expression. Scale bar represents 200  $\mu\text{m}$ .

Chart 4.1 Bar chart demonstrating the heterogeneity of cyclin D1 staining of thyroid follicular adenomas, follicular and papillary carcinomas. The stacked bars represent the percentage of cases with a cyclin D1 I.D. score in a given range (0, 0.1-0.5, 0.6-1.0, 1.1-1.5, 1.6-2.0, 2.1-2.5)



FA Follicular adenoma  
 FC Follicular carcinoma  
 PC Papillary carcinoma

Chart 4.2 Box plot chart showing the first and third quartiles and median values for the cyclin D1 I.D. score for the follicular adenomas, follicular and papillary carcinomas. The 'whiskers' represent the range of I.D. values of cases that fall within 1.5 times the inter-quartile range (IQR).



FA Follicular adenoma

FC Follicular carcinoma

PC Papillary carcinoma



#### 4.3.2 Expression of p21

The four normal thyroid tissue sections that were stained did not show p21 expression (Figure 4.5). I performed immunohistochemistry on ten follicular adenomas, and these tumours showed a small up-regulation in p21 expression when compared to normal tissue (median p21 L.I. score = 0.5). Four out of the ten cases did not show p21 expression, five cases had p21 expression in 1-3% of cells, and one case had p21 expression in 15% cells. Examples of two follicular adenomas, one with no p21 expression and one with weak p21 expression are shown in Figure 4.6.

I stained eight follicular carcinomas, and these tumours could be divided into two groups. Five of the eight cases (62.5%) did not show p21 expression. The remaining three cases (37.5%) had a considerable up-regulation of p21 expression when compared to normal thyroid tissue and the follicular adenomas (L.I. range 10-20). The median p21 L.I. score for the follicular carcinomas was 0. Examples of two follicular carcinomas showing an up-regulation of p21 expression are shown in Figure 4.7.

I then performed immunohistochemistry on seven papillary carcinomas and like the follicular carcinomas, these also showed an up-regulation of p21 expression when compared with the follicular adenomas (median p21 L.I. score = 10). Two tumours were negative, and the remaining five tumours had between 5-20% cells showing p21 immunopositivity. Examples of two papillary carcinomas showing an up-regulation of p21 expression are shown in Figure 4.8.

Chart 4.3 graphically represents the range of p21 I.D. values of the follicular adenomas, and the follicular and papillary carcinomas. All three tumour groups over-expressed p21 when compared to normal thyroid tissue, which did not show p21 expression. Although all three tumour groups had cases that did not show p21 expression, overall the follicular and papillary carcinoma cases that did show p21 expression had higher p21 I.D. values than the follicular adenomas.

The median p21 values for the follicular adenomas, follicular and papillary carcinomas, together with the first and third quartiles are represented as a box plot in Chart 4.4. This graph demonstrates the increase in p21 expression observed in the transition from adenoma to carcinoma. The p21 results for every tumour analysed in this study are summarised in Tables 4.1, 4.2 and 4.3.

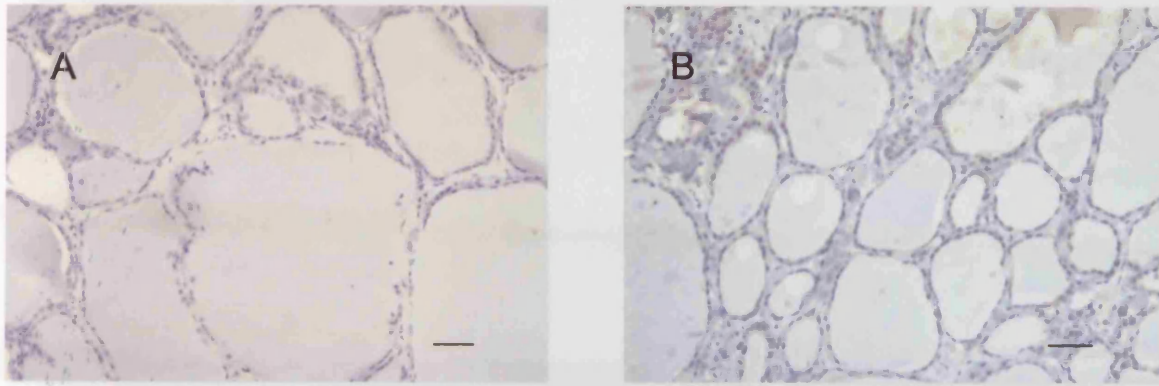


Figure 4.5 Immunohistochemical staining with anti-p21 antibody of two samples of normal thyroid tissue, showing the absence of p21 expression. Scale bar represents 200 $\mu$ m.

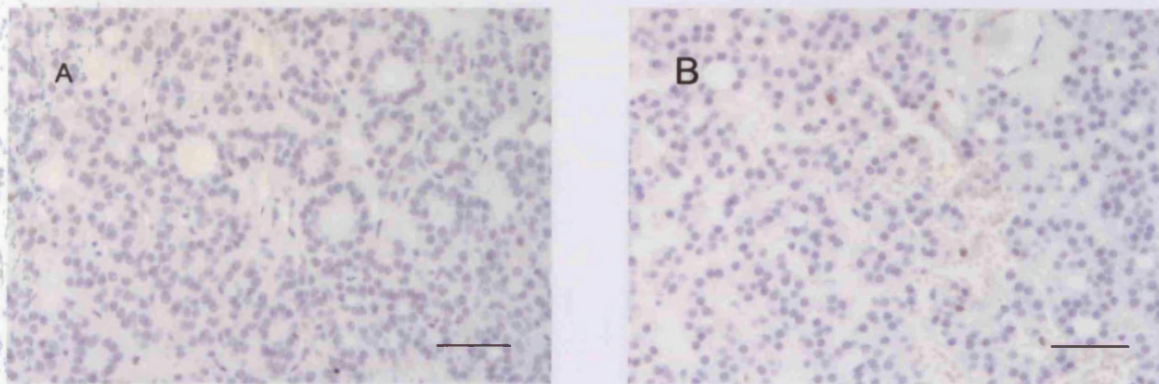


Figure 4.6 Immunohistochemical staining with anti-p21 antibody in two cases of a follicular adenoma. Case A does not show p21 expression, and case B has weak p21 expression, with 3% cells demonstrating a positive nuclear reaction. Scale bar represents 200  $\mu$ m.

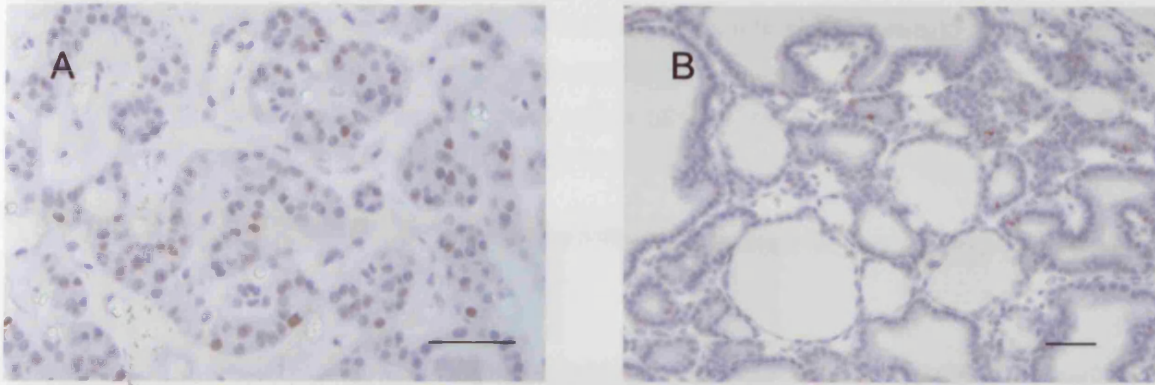


Figure 4.7 Immunohistochemical staining with anti-p21 antibody of two samples of a follicular carcinoma. Cases A and B show an up-regulation of p21 expression with 10-20% cells expressing p21. Scale bar represents 200 $\mu$ m.

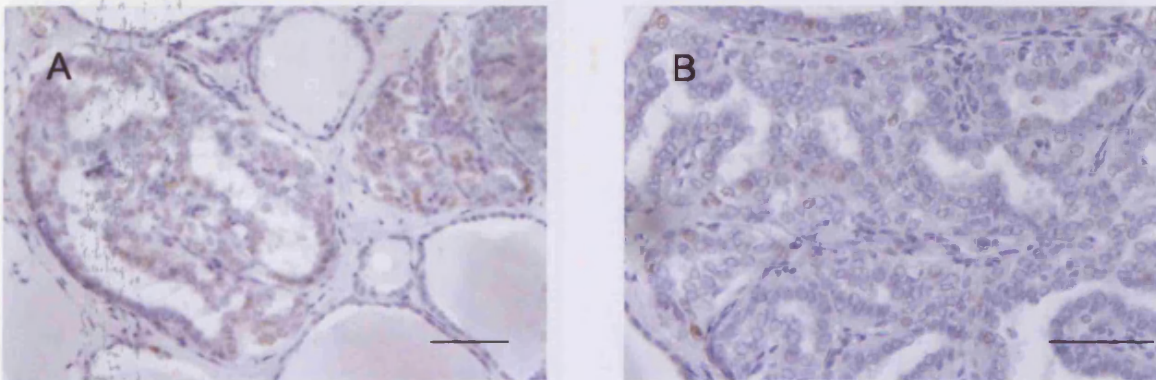
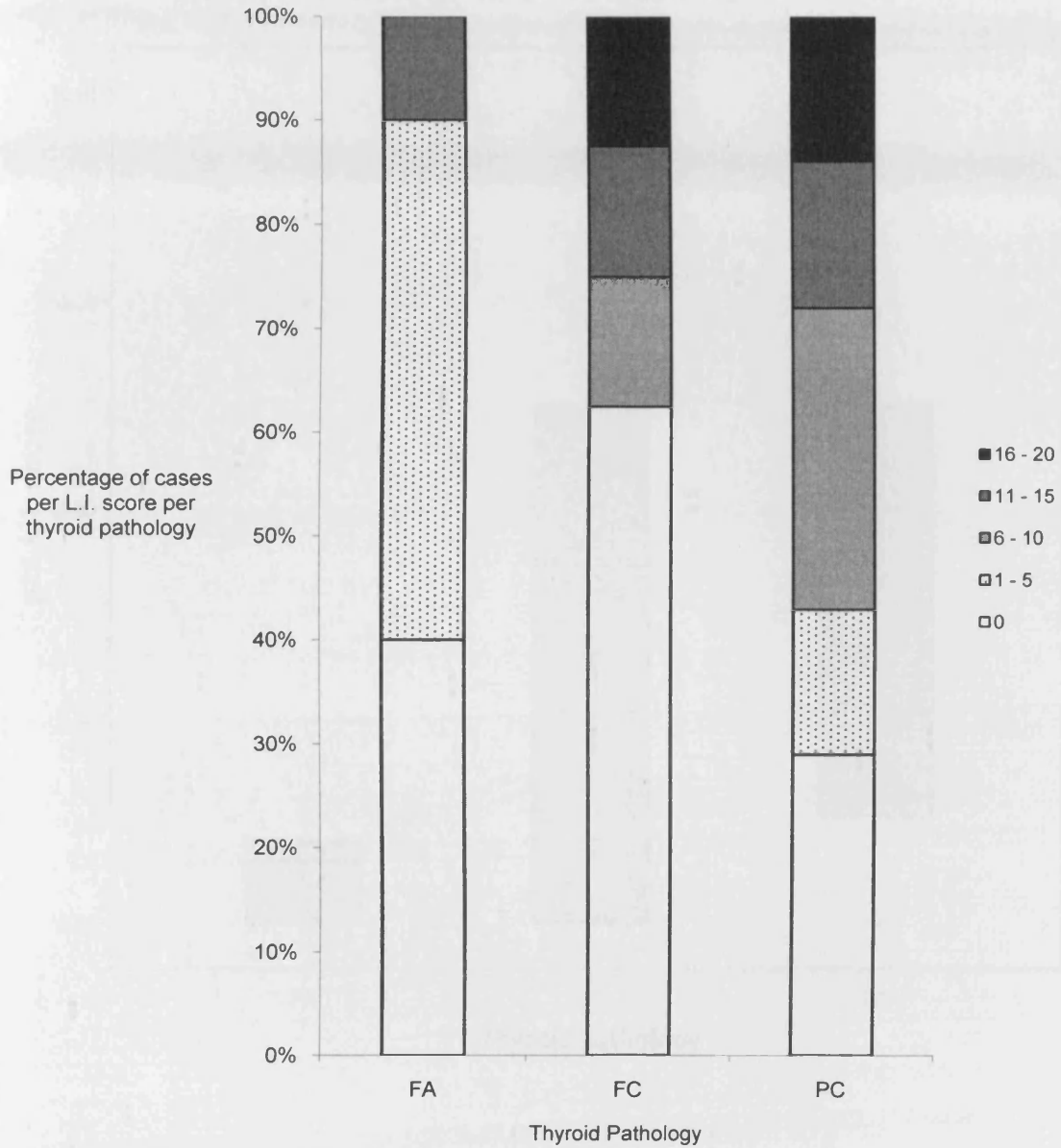


Figure 4.8 Immunohistochemical staining with anti-p21 antibody in two cases of a papillary carcinoma. Cases A and B show an up-regulation of p21 expression, with 10-20% cells demonstrating a positive nuclear reaction. Scale bar represents 200  $\mu$ m.

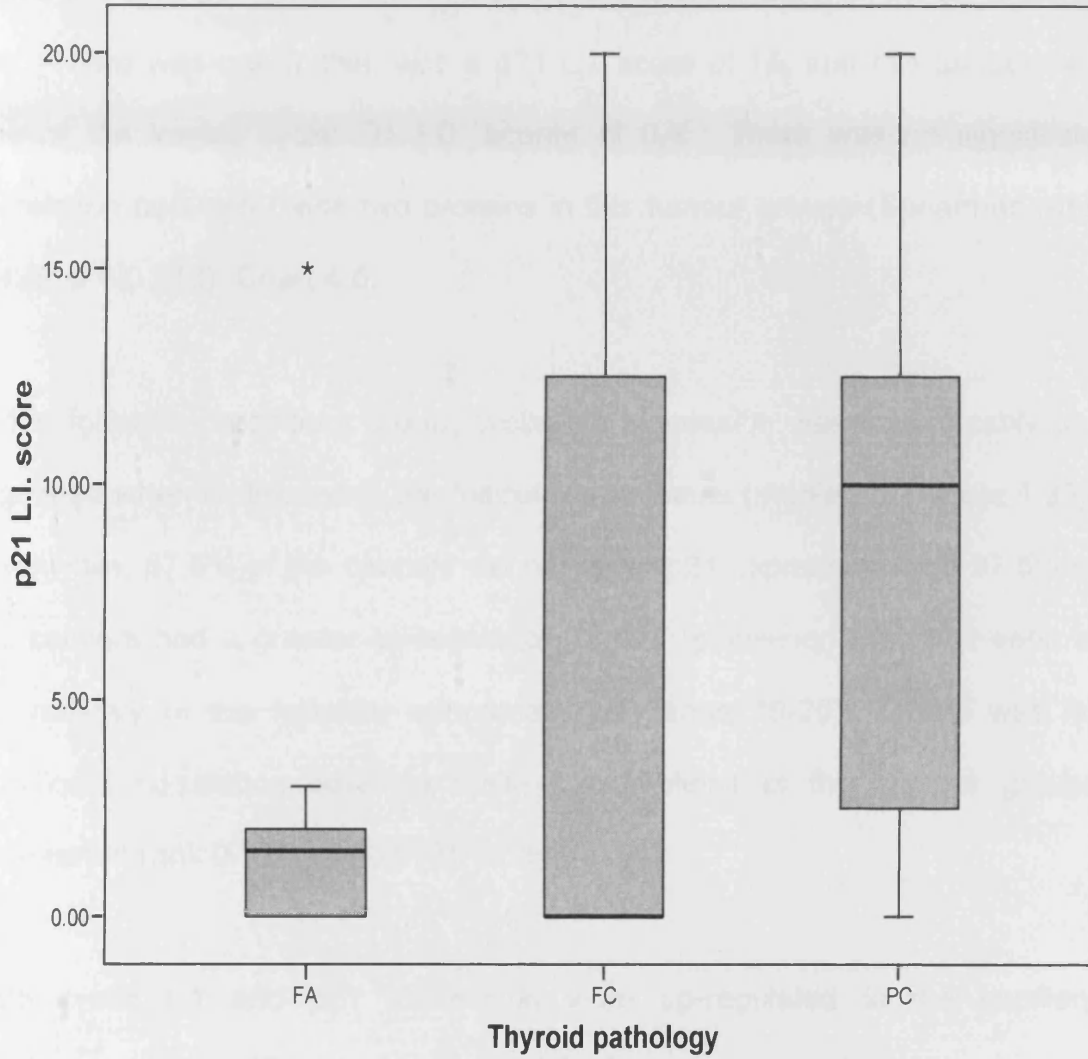
Chart 4.3 Bar chart demonstrating the heterogeneity of p21 staining in thyroid follicular adenomas, follicular and papillary carcinomas. The stacked bars represent the percentage of cases with a p21 L.I. score in a given range (0, 1-5, 6-10, 11-15, and 16-20)



FA Follicular adenoma  
 FC Follicular carcinoma  
 PC Papillary carcinoma



Chart 4.4 Box plot chart showing the first and third quartiles, and median values for the p21 L.I. score for follicular adenomas, follicular and papillary carcinomas. The 'whiskers' represent the range of I.D. values of cases that fall within 1.5 times the inter-quartile range (IQR), and the '\*' represents the I.D. score of an 'extreme' case whose I.D. value is >3 times the IQR.



FA Follicular adenoma  
FC Follicular carcinoma  
PC Papillary carcinoma

### 4.3.3 Co-expression of cyclin D1 and p21

Cyclin D1 expression was up-regulated in the follicular adenomas, with a median I.D. score of 0.45. p21 expression remained low in the adenomas, with 0-3% cells per tumour showing p16 expression, and a median L.I. score of 0.5. There was one outlier, with a p21 L.I. score of 15, and this tumour had one of the lowest cyclin D1 I.D. scores of 0.4. There was no significant correlation between these two proteins in this tumour groups (Spearman rank 0.428,  $p = 0.218$ ), Chart 4.5.

In the follicular carcinoma group, cyclin D1 expression was considerably up-regulated when compared to the follicular adenomas (median I.D. score 1.35). Meanwhile, 67.5% of the cancers did not show p21 expression, and 37.5% of the cancers had a greater up-regulation of p21 expression than that seen in the majority of the follicular adenomas (L.I. range 10-20). There was no significant correlation between these two proteins in this tumour groups (Spearman rank 0.178,  $p = 0.673$ ), Chart 4.6.

Both cyclin D1 and p21 expression were up-regulated in the papillary carcinoma group. The median cyclin D1 I.D. score was 1.2 and the median p21 L.I. score was 10. There was no significant correlation between these two proteins in this tumour groups (Spearman rank 0.436,  $p = 0.328$ ), Chart 4.7, as tumours with a high cyclin D1 score had either a high or a low p21 L.I. score.

Figure 4.9 shows cyclin D1, p21 and p16 staining in a representative follicular adenoma, follicular carcinoma and papillary carcinoma.

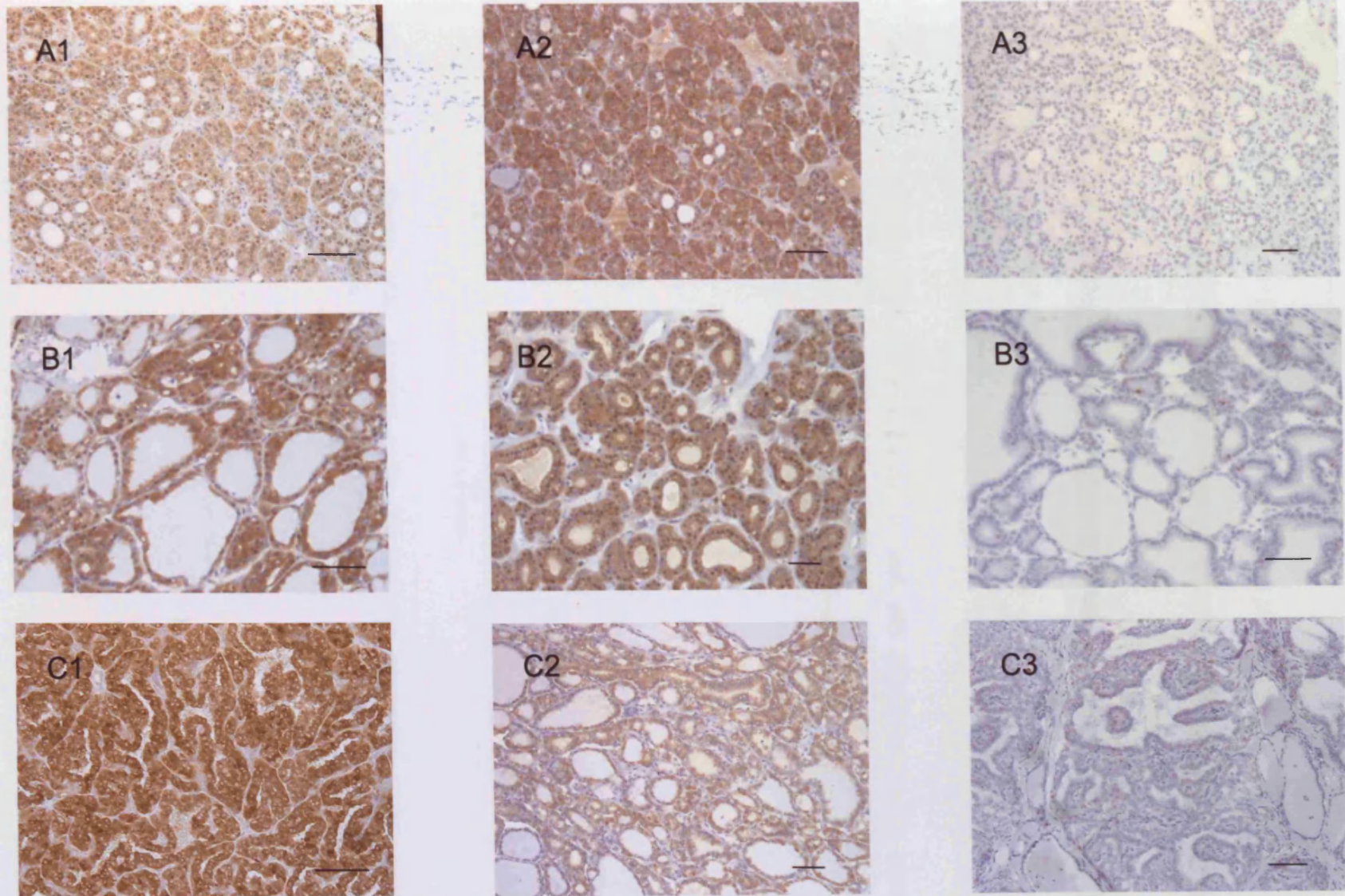


Figure 4.9 Immunohistochemistry showing p16 (A1,B1,C1), cyclin D1 (A2,B2,C2) and p21 (A3,B3,C3) expression in a thyroid follicular adenoma (A), follicular carcinoma (B) and papillary carcinoma (C). Brown staining represents a positive reaction. Scale bar represents 200 $\mu$ m.



Chart 4.5 Scatter chart showing cyclin D1 and p21 expression in the follicular adenomas

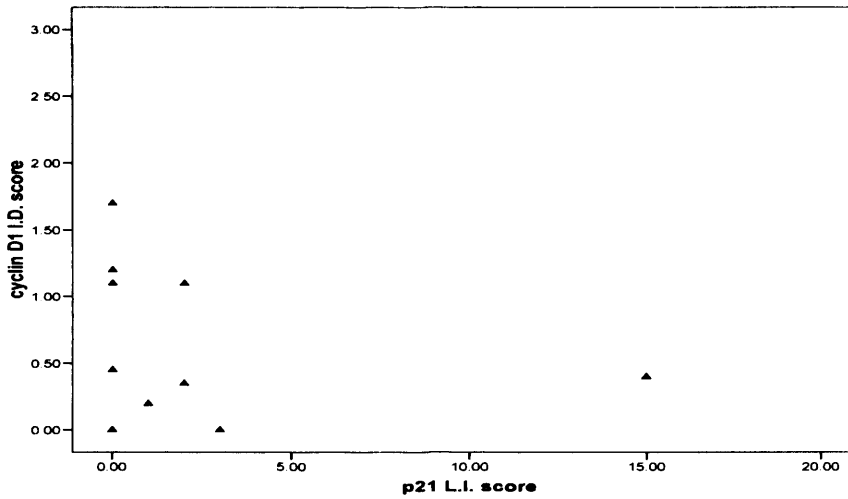


Chart 4.6 Scatter chart showing cyclin D1 and p21 expression in the follicular carcinomas

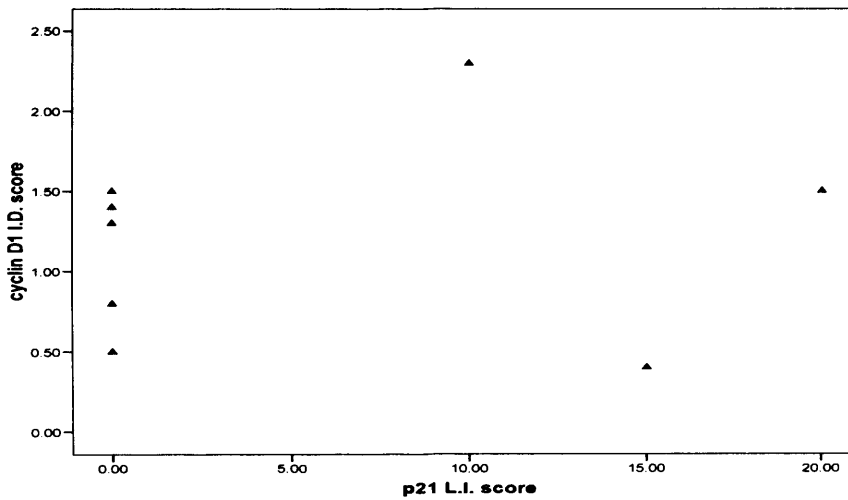
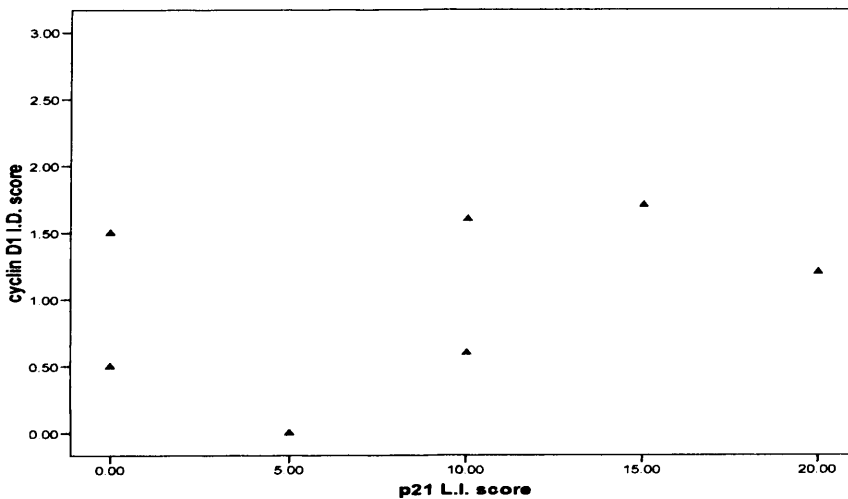


Chart 4.7 Scatter chart showing cyclin D1 and p21 expression in the papillary carcinomas



#### 4.3.4 Co-expression of cyclin D1 and p16

In the follicular adenoma tumour group, the cyclin D1 I.D. score ranged from 0–1.7, and the p16 I.D. score ranged from 0.2-1.4. Generally, the adenomas with the higher p16 I.D. scores also had a higher level of cyclin D1 expression, although there was one case that had a high p16 I.D. score (1) and a low cyclin D1 I.D. score (0.2) (Chart 4.8). There was a positive correlation between p16 and cyclin D1 expression (Spearman rank 0.721,  $p = 0.19$ ) which neared statistical significance.

The follicular carcinomas (Chart 4.9) also showed an up-regulation of both cyclin D1 and p16 expression, and this correlation was statistically significant (Spearman rank = 0.789,  $p = 0.02$ ). Similarly the papillary carcinomas (Chart 4.10) demonstrated an up-regulation of cyclin D1 and p16 expression, and this was also a statistically significant correlation (Spearman rank = 0.793,  $p = 0.033$ ).

Chart 4.8 Scatter chart showing cyclin D1 and p16 expression in the follicular adenomas

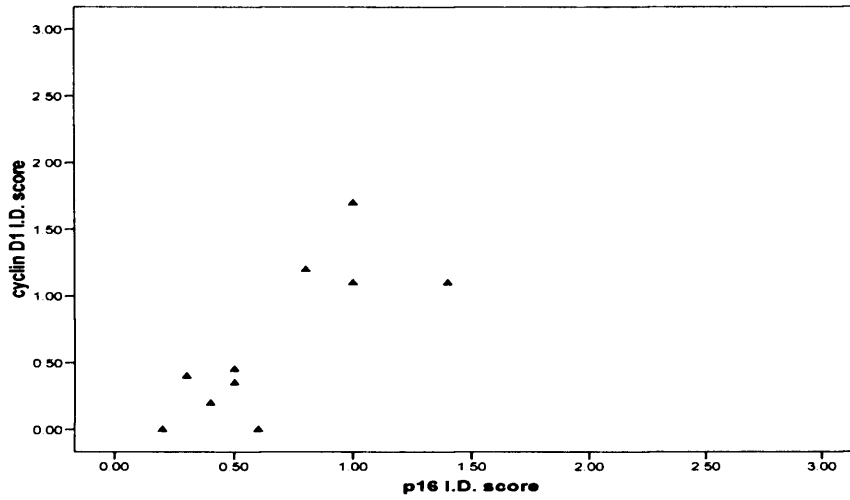


Chart 4.9 Scatter chart showing cyclin D1 and p16 expression in the follicular carcinomas

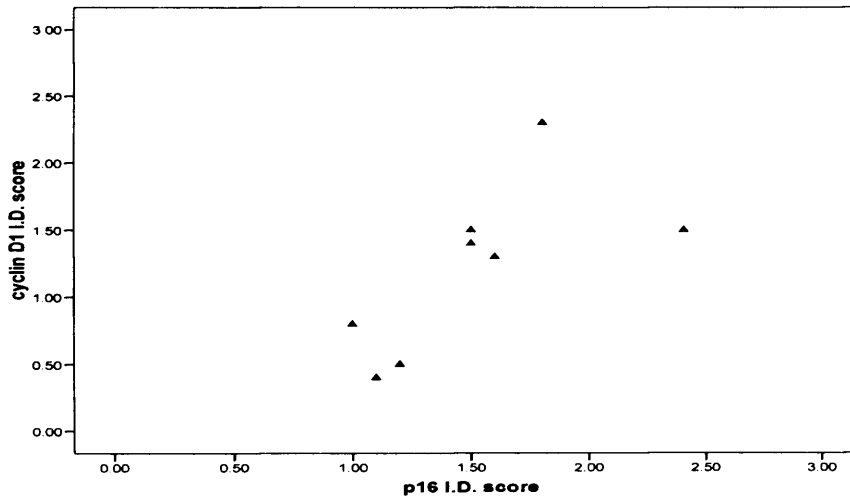
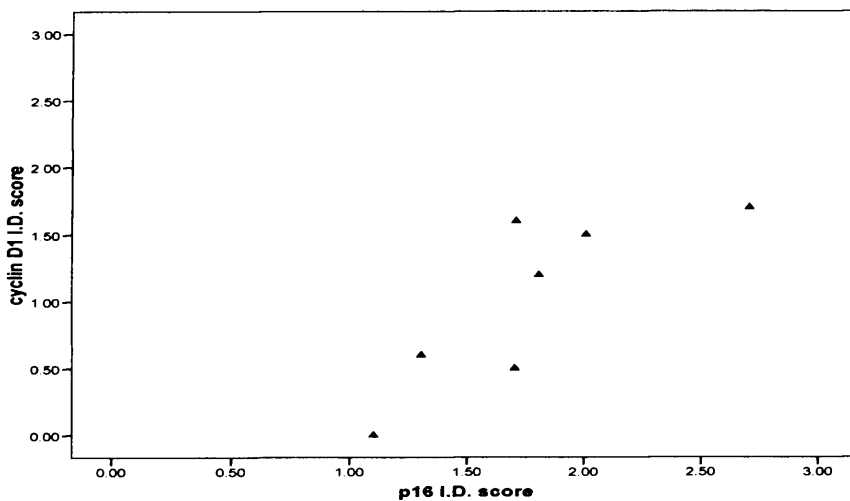


Chart 4.10 Scatter chart showing cyclin D1 and p16 expression in the papillary carcinomas



#### 4.3.5 Co-expression of p21 and p16

In the follicular adenoma tumour group, p21 expression was negligible, with 90% tumours having 0-3% cells showing p21 expression. In contrast, p16 protein was over-expressed when compared to normal thyroid tissue (Chart 4.11). One adenoma had a higher p21 L.I. score (15), and this case had one of the lowest p16 I.D. scores (0.3). There was a negative correlation between these two proteins in the follicular adenomas, although this was not significant (Spearman rank -0.261,  $p = 0.466$ ).

The follicular carcinomas all showed an up-regulation of p16 expression when compared to normal thyroid tissue. However, just over half of the tumours did not express p21, whilst the remaining cases had a considerable up-regulation of p21 expression when compared to normal thyroid tissue (Chart 4.12). There was not a significant correlation between p16 and p21 in the follicular cancer tumour group (Spearman rank 0.412,  $p = 0.311$ ).

The papillary carcinomas also showed an up-regulation of p16 expression when compared to normal thyroid tissue. There was also an up-regulation of p21 expression when compared to the follicular adenomas, as 75% tumours had an L.I. score ranging from 5-20. However, two of the cancers with the highest p16 I.D. scores did not show p21 expression (Chart 4.13). There was not a significant correlation between p16 and p21 in the papillary cancer tumour group (Spearman rank 0.257,  $p = 0.578$ ).

Chart 4.11 Scatter chart showing p21 and p16 expression in the follicular adenomas

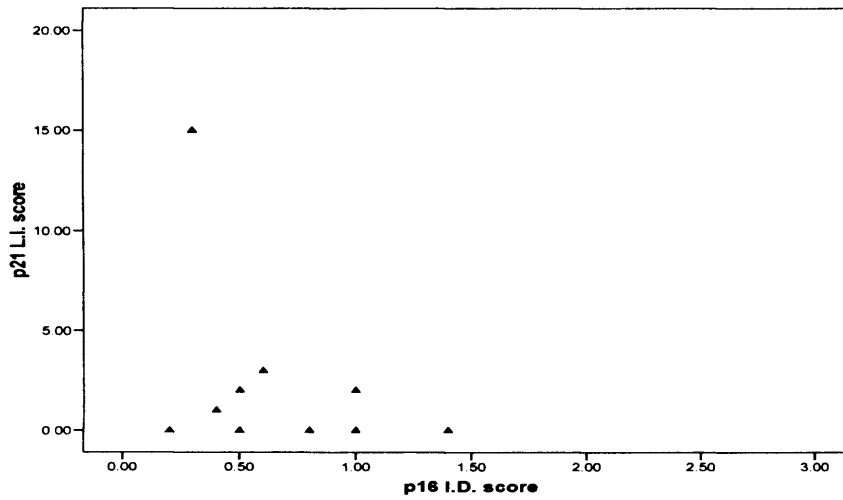


Chart 4.12 Scatter chart showing p21 and p16 expression in the follicular carcinomas

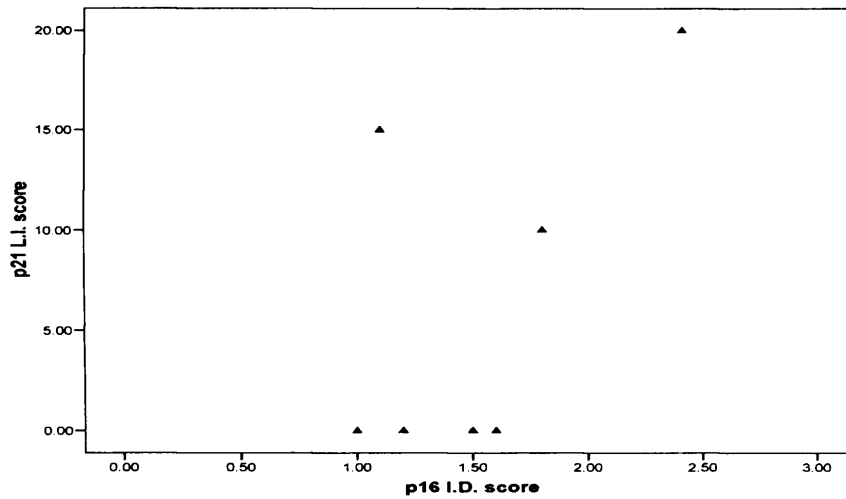


Chart 4.13 Scatter chart showing p21 and p16 expression in the papillary adenomas

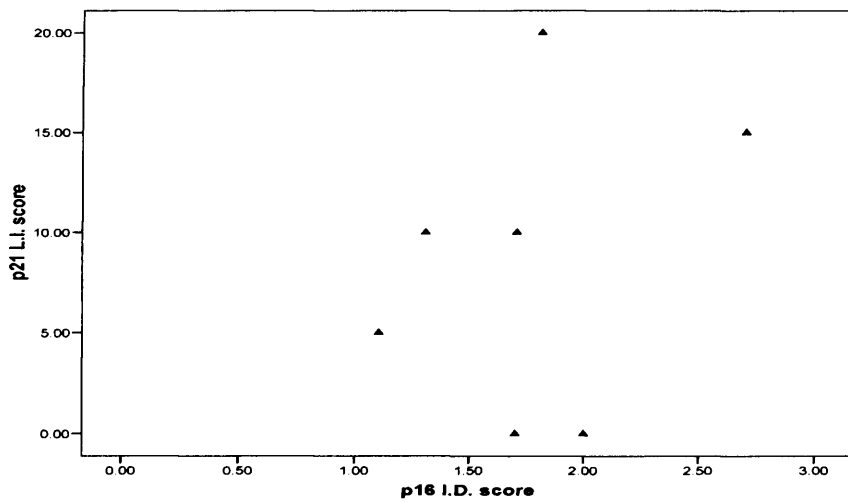


Table 4.1 Immunohistochemistry results for cyclin D1, p21 and p16 expression in thyroid follicular adenomas (FA)

Pathology	cyclin D1 I.D. score	p21 L.I. score	p16 I.D. score	MCM2 L.I. score	cyclin A L.I. score
FA	0	0	0.2	3	0
FA	0.4	15	0.3	1	0.4
FA	0.35	2	0.5	25	0.3
FA	0.45	2	0.5	1	0
FA	0	3	0.6	15	1.1
FA	1.2	0	0.8	4	0
FA	0.2	1	1	2	0.7
FA	1.1	2	1	8	0.5
FA	1.7	0	1	12	0
FA	1.1	0	1.4	6	0.1

Table 4.2 Immunohistochemistry results for cyclin D1, p21 and p16 expression in thyroid follicular carcinomas (FC)

Pathology	cyclin D1 I.D. score	p21 L.I. score	p16 I.D. score	MCM2 L.I. score	cyclin A L.I. score
FC	0.8	0	1	1.2	0
FC	0.4	15	1.1	5	1.8
FC	0.5	0	1.2	1	0
FC	1.4	0	1.5	2.3	0
FC	1.5	0	1.5	0	0.6
FC	1.3	0	1.6	0.6	0
FC	2.3	10	1.8	14	0.2
FC	1.5	20	2.4	3	1.1

Table 4.3 Immunohistochemistry results for cyclin D1, p21 and p16 expression in thyroid papillary carcinomas (PC)

Pathology	cyclin D1 I.D. score	p21 L.I. score	p16 I.D. score	MCM2 L.I. score	cyclin A L.I. score
PC	0	5	1.1	38	0
PC	0.6	10	1.3	12	0.5
PC	0.5	0	1.7	7	1.2
PC	1.6	10	1.7	11	3
PC	1.2	20	1.8	2	0.7
PC	1.5	0	2	53	1.2
PC	1.7	15	2.7	18	5

#### 4.3.6 Co-expression of cyclin D1 and MCM2

In the follicular adenoma tumour group, cyclin D1 expression was up-regulated compared to normal thyroid tissue, with a median I.D. score of 0.45. MCM2 expression was also higher in this group when compared to normal thyroid tissue, with a median L.I. score of 5 (range 1-25). There was no statistically significant correlation between the expression of these proteins in the follicular adenomas studied (Spearman rank 0.055,  $p = 0.880$ ) (Chart 4.14).

The follicular carcinomas expressed cyclin D1 at a greater level than that seen in the follicular adenomas, with a median I.D. score of 1.35. However, MCM2 protein was expressed at a similar level to the follicular adenomas, with a median L.I. score of 1.75 (range 0 – 14). There was no statistically significant correlation between the expression of these proteins in the follicular carcinomas studied (Spearman rank 0.419,  $p = 0.301$ ) (Chart 4.15).

The papillary carcinomas expressed cyclin D1 at a level similar to that seen in the follicular carcinoma group, with a median I.D. score of 1.2. Interestingly, MCM2 expression was much higher in the papillary carcinomas when compared to both benign and malignant follicular tumours, with a median L.I. score of 12.0 (range 2 – 53), although there was not a significant correlation between the expression of these proteins in the papillary carcinomas studied (Spearman rank -0.500,  $p = 0.253$ ) (Chart 4.16).

Chart 4.14 Scatter chart showing cyclin D1 and MCM2 expression in the follicular adenomas

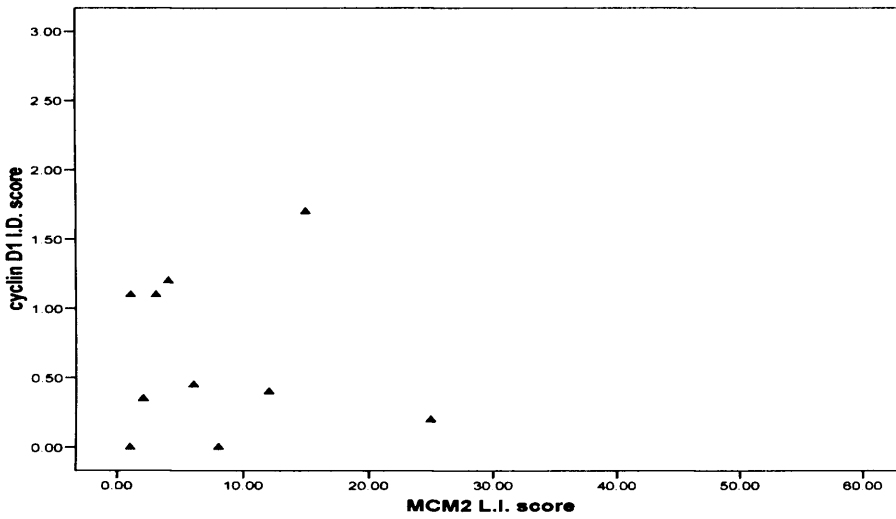


Chart 4.15 Scatter chart showing cyclin D1 and MCM2 expression in the follicular carcinomas

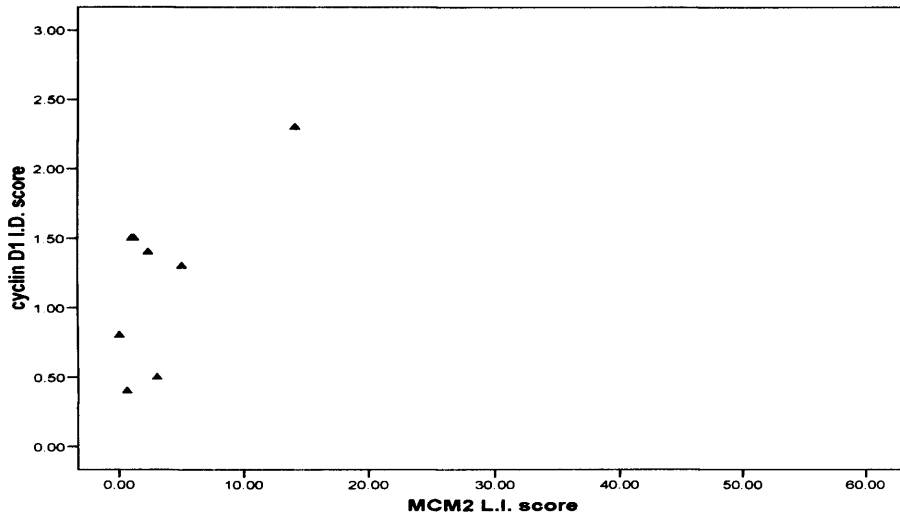
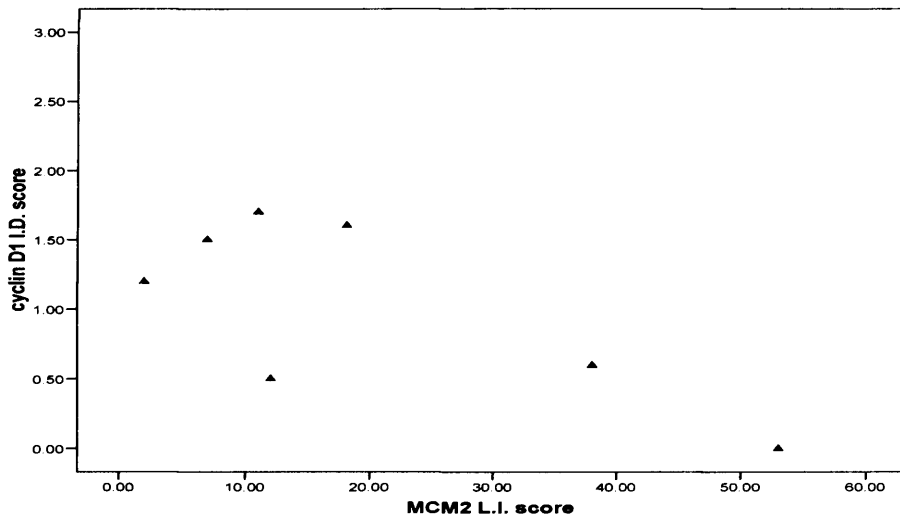


Chart 4.16 Scatter chart showing cyclin D1 and MCM2 expression in the papillary carcinomas





#### 4.3.7 Co-expression of cyclin D1 and cyclin A

As stated previously, in the follicular adenoma tumour group, cyclin D1 expression was up-regulated compared to normal thyroid tissue. The expression of cyclin A was induced in the follicular adenomas when compared to normal thyroid tissue, but this was at a low level (median L.I. score 0.2, range 0 – 1.1). There was no statistically significant correlation between the expression of these proteins in the follicular adenomas studied (Spearman rank 0.044,  $p = 0.904$ ) (Chart 4.17).

Cyclin D1 was expressed at a higher level in the follicular carcinomas when compared to the adenomas, as previously described. Cyclin A was also expressed in this group of tumours, but this was at a low level similar to that shown in the follicular adenomas (median L.I. score 0.10, range 0 – 1.8). There was no statistically significant correlation between the expression of these proteins in the follicular carcinomas studied (Spearman rank -0.268,  $p = 0.521$ ) (Chart 4.18).

The papillary carcinomas also showed an up-regulation of cyclin D1 expression when compared to normal tissue. Interestingly, cyclin A expression was slightly higher in the papillary carcinomas when compared to both benign and malignant follicular tumours, with a median L.I. score of 1.20 (range 0 – 5), although there was not a significant correlation between the expression of these proteins in the papillary carcinomas studied (Spearman rank 0.649,  $p = 0.115$ ) (Chart 4.19).

Chart 4.17 Scatter chart showing cyclin D1 and cyclin A expression in the follicular adenomas

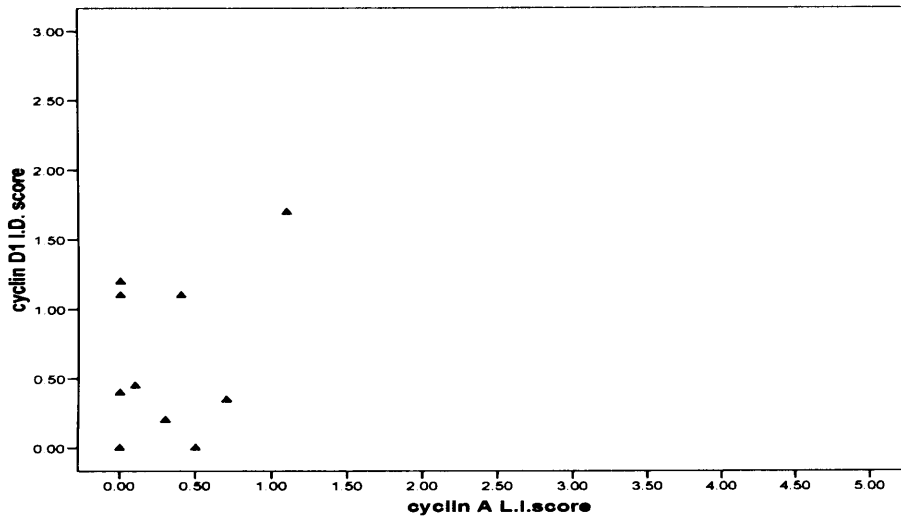


Chart 4.18 Scatter chart showing cyclin D1 and cyclin A expression in the follicular carcinomas

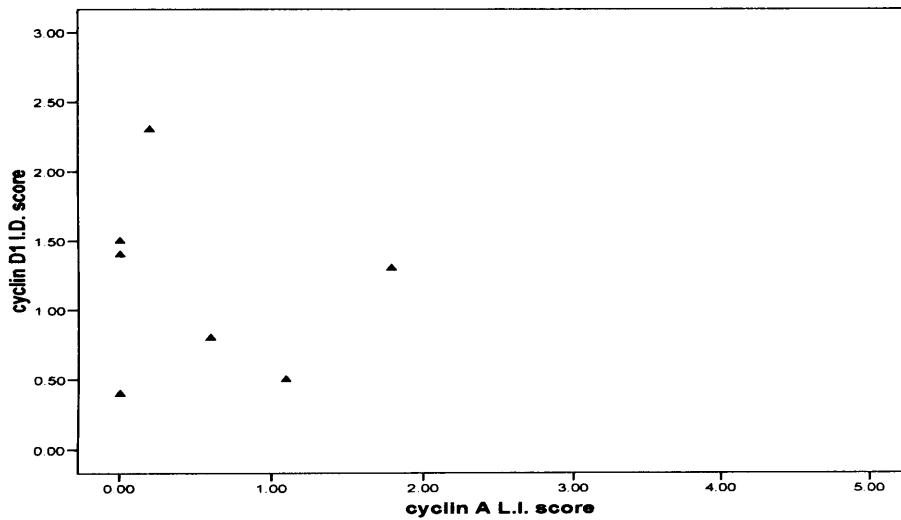
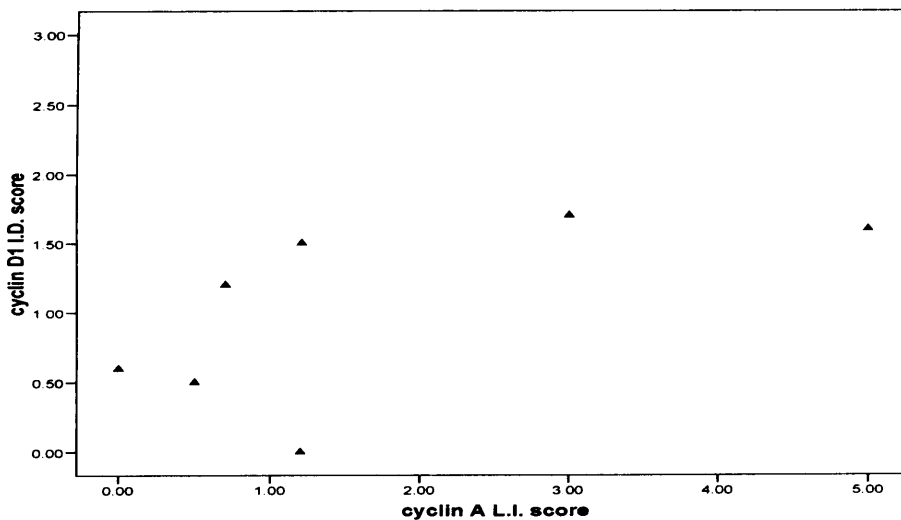


Chart 4.19 Scatter chart showing cyclin D1 and cyclin A expression in the papillary carcinomas



#### 4.3.8 Co-expression of p21 and MCM2

The expression of p21 was minimally induced in the follicular adenomas when compared to normal thyroid tissue, and only one tumour had an L.I. score >10. MCM2 expression was induced higher in these tumours when compared to normal thyroid tissue, but this was also at a low level, with a median L.I. score of 5 (range 1-25). There was no statistically significant correlation between the expression of these proteins in the follicular adenomas studied (Spearman rank 0.286,  $p = 0.423$ ) (Chart 4.20).

Five out of the eight follicular carcinomas did not express p21, and the remaining three tumours expressed p21 with an L.I. score > 10. MCM2 protein was induced at a similar level to that seen in the follicular adenomas, with a median L.I. score of 1.75 (range 0-14). There was no statistically significant correlation between the expression of these proteins in the follicular carcinomas studied (Spearman rank -0.191,  $p = 0.651$ ) (Chart 4.21).

The papillary carcinomas as a group had the greatest percentage of tumours expressing p21, although the level of expression was similar to that seen in the follicular carcinomas. However, MCM2 protein was expressed at a much higher level than that seen in the follicular tumours, and there was a negative correlation between the expression of these proteins in the papillary carcinomas studied (Spearman rank -0.273,  $p = 0.554$ ) (Chart 4.22).

Chart 4.20 Scatter chart showing p21 and MCM2 expression in the follicular adenomas

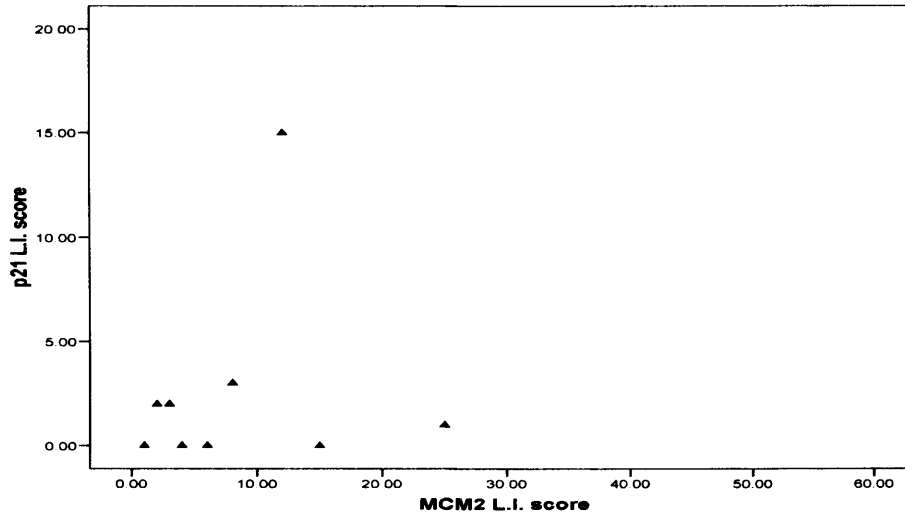


Chart 4.21 Scatter chart showing p21 and MCM2 expression in the follicular carcinomas

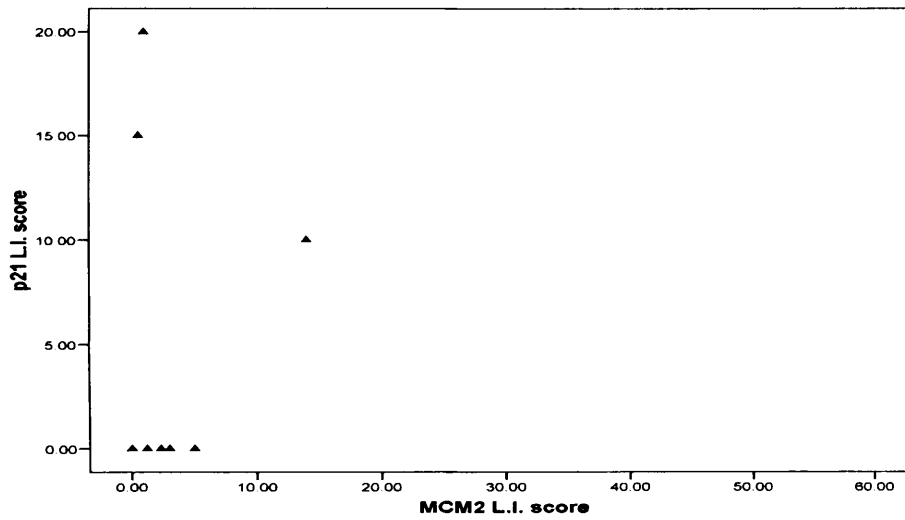
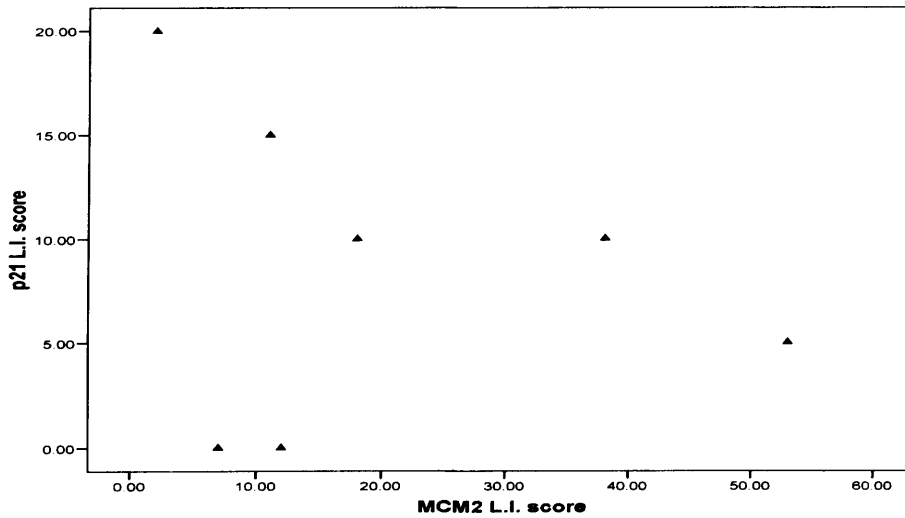


Chart 4.22 Scatter chart showing p21 and MCM2 expression in the papillary carcinomas



#### 4.3.9 Co-expression of p21 and cyclin A

As stated previously, the expression of p21 was minimally induced in the follicular adenomas when compared to normal thyroid tissue, and only one tumour had an L.I. score  $>10$ . Cyclin A was induced in the follicular adenomas when compared to normal thyroid tissue, but this was also at a low level (median L.I. score 0.2). There was a negative correlation between the expression of these proteins in the follicular adenomas studied (Spearman rank  $-0.030$ ,  $p = 0.934$ ) (Chart 4.23).

Only three out of the eight follicular carcinomas expressed p21, although these tumours had higher L.I. scores than the follicular adenomas. Cyclin A was also expressed in this group of tumours, but at a similarly low level to that shown in the follicular adenomas (median L.I. score 0.10). There was also a negative correlation between the expression of these proteins in the follicular carcinomas studied (Spearman rank  $-0.480$ ,  $p = 0.229$ ) (Chart 4.24).

Five out of the seven papillary carcinomas expressed p21, although the level of expression was similar to that seen in the follicular carcinomas. However, cyclin A expression was higher in the papillary carcinomas when compared to both benign and malignant follicular tumours, with a median L.I. score of 1.20. Interestingly, there was a positive correlation (instead of a negative correlation) between the expressions of these proteins in the papillary carcinomas studied (Spearman rank  $0.156$ ,  $p = 0.738$ ) (Chart 4.25).

Chart 4.23 Scatter chart showing p21 and cyclin A expression in the follicular adenomas

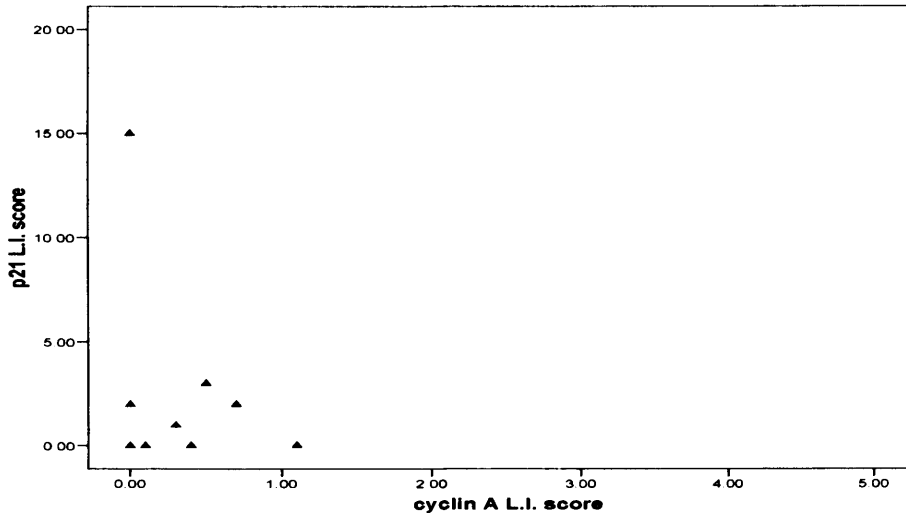


Chart 4.24 Scatter chart showing p21 and cyclin A expression in the follicular carcinomas

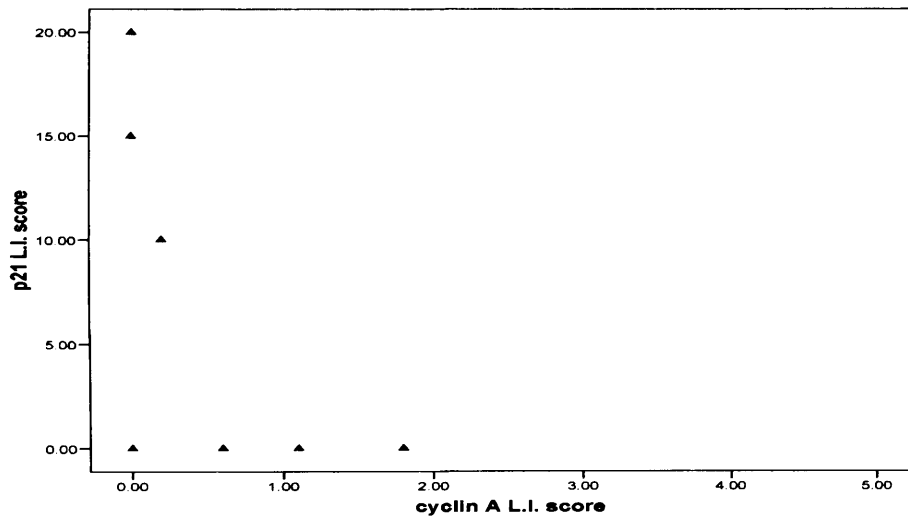
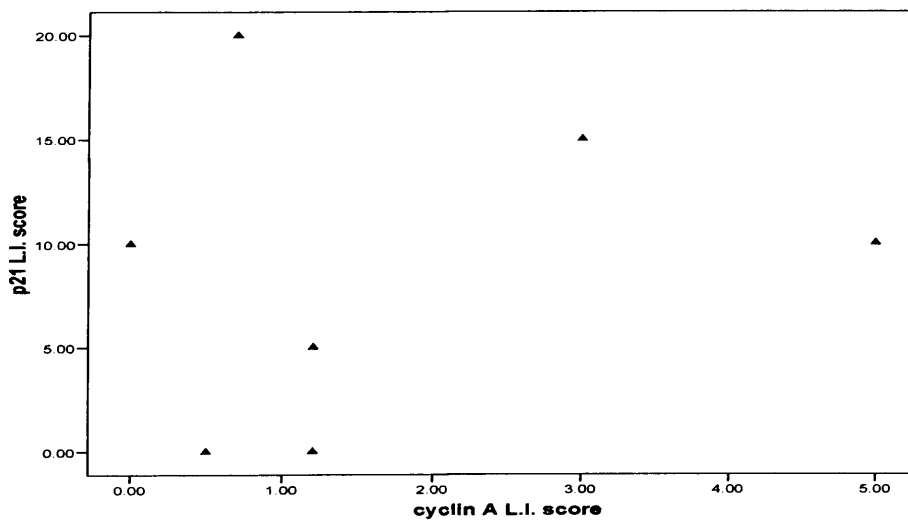


Chart 4.25 Scatter chart showing p21 and cyclin A expression in the papillary carcinomas



#### 4.4 Discussion

The study of the molecular genetics of a tumour is important in developing treatment strategies for the disease. It helps us understand the natural progression of the disease, and potentially lead to a cure or a method to diagnose the tumour at an earlier stage. It can also allow us to determine the predicted behaviour of a tumour, for example the likelihood of metastases or a shortened survival time, and tailor treatment accordingly.

One of the major checkpoints that have to be overcome during neoplastic transformation is the G1-S phase cell cycle checkpoint. Three major genes that are involved in control of this checkpoint via the Rb pathway are p16, cyclin D1 and p21. Our study is the first to define cyclin D1 and p21 expression in thyroid follicular adenomas, follicular and papillary carcinomas, and to correlate their expression with the expression of p16 in the same tumour groups.

I hypothesised that cyclin D1 would be up-regulated in the follicular adenomas, and my results support this hypothesis. Cyclin D1 was not expressed in normal thyroid tissue, and was up-regulated in the follicular adenomas with 80% cases demonstrating weak or moderate cyclin D1 expression (median L.I. score 0.43). Furthermore, there was an up-regulation of cyclin D1 expression in both the follicular and papillary carcinomas when compared to the follicular adenomas. The follicular carcinomas had a median L.I. score of 1.35, and the papillary carcinomas had a median L.I. score of 1.2, and there was no obvious difference in cyclin D1 expression between the two tumour groups. The increase in cyclin D1 expression during transition from an adenoma to a

carcinoma was expected, because of their malignant phenotype and the increase in proliferative rate seen in the carcinomas, as shown in chapter 3.

My immunohistochemical results are comparable with those previously published. Ferenc et al., (2005), reported an increase in cyclin D1 expression in 13 of 57 (23%) follicular adenomas and in 3 of 12 (25%) follicular carcinomas. Lazzereschi et al., (1998), observed cytoplasmic cyclin D1 expression in 72% of the follicular adenomas and 63% of the papillary carcinomas studied. Both Wang et al., (2000), and Saiz et al., (2002), demonstrated cyclin D1 over-expression in thyroid tumours, with the carcinomas staining more strongly than the adenomas and Wang reported that cyclin D1 expression was greatest in the poorly- and undifferentiated cancers. However, Temmim et al., (2006), only observed small areas of focal staining with surrounding weak or negative tissue in 23 out of 50 follicular and papillary tumours, with the remaining tumours not showing cyclin D1 expression.

Lantsov et al., (2005), demonstrated cyclin D1 expression in micro-papillary carcinomas and a further increase in cyclin D1 expression in papillary carcinomas when compared to normal thyroid tissue. Khoo et al., (2002b), reported that 20 out of 22 micro-papillary carcinomas that had metastasised had widespread cyclin D1 expression, whilst only three out of 34 micro-papillary carcinomas without metastases showed cyclin D1 expression. All the authors reported that normal thyroid tissue did not express cyclin D1 protein.

In summary, the data in the literature suggests that cyclin D1 staining is negligible in normal thyroid tissue, and that follicular and papillary carcinomas



demonstrate an up-regulation in cyclin D1 expression when compared with follicular adenomas, although Temmim et al., (2006), only demonstrated weak expression in these tumours. Finally, the more aggressive poorly or undifferentiated tumours have the highest levels of cyclin D1 expression.

The differences in immunohistochemical expression of cyclin D1 seen in these studies can be partly attributed to the different cut-off points used to determine what counts as a positive result and what constitutes as over-expression of cyclin D1. Another reason for these differences is the use of different immunohistochemical protocols and antibodies in the quoted papers. It is only feasible to compare results and therefore draw accurate conclusions about cyclin D1 expression in thyroid tumorigenesis by analysing only those studies that used the same antibodies, immunohistochemical protocols and scoring systems.

I observed that p21 was not expressed in normal human thyroid tissue. There was a minimal up-regulation of p21 expression in follicular adenomas, with nine out of ten tumours only having 0-3% positive cells, and a median L.I. score of 0.5. This was surprising, and was not consistent with my hypothesis that the tumour suppressor gene p21, like p16, would be up-regulated in the follicular adenoma group.

However, p21 was up-regulated in a sub-group of both the follicular and papillary carcinomas. 37.5% of the follicular carcinomas expressed p16 (L.I. range 10-20), although the median L.I. score for this group was 0. However the tumours that did express p21 had a greater percentage of positively

staining cells when compared to the follicular adenomas. Five out of the seven papillary carcinomas also showed an up-regulation in p21 expression, and the range of L.I. values was similar to that seen in the follicular carcinomas (L.I. range 5-20). There was no obvious difference in p21 expression between the follicular and the papillary cancers.

My results are similar to those previously published by Ito et al., (1996), Zedenius et al., (1996), Hermann et al., (2001), and Pickett et al., (2005). These authors demonstrated an up-regulation in p21 expression in both follicular and papillary carcinomas when compared to follicular adenomas, with an average of 12-53% cells per tumour showing p21 expression. In contrast, Ferenc et al., (2004b), observed similar levels of p21 expression in follicular adenomas and carcinomas, with approximately 14% cells in each tumour staining positively for p21.

Okayasu et al., (1998), showed a significant up-regulation of p21 expression in poorly-differentiated papillary and anaplastic thyroid cancers when compared to well-differentiated papillary cancers and follicular adenomas, with an average of 80% cells showing p21 immunopositivity in the more aggressive tumour group. In contrast, Brzezinski et al., (2005), reported a significant decrease in p21 expression in well- and poorly-differentiated papillary carcinomas when compared to indolent micro-papillary tumours, and only the micro-papillary tumour group showed over-expression of p21.

In summary, the data in the literature suggests that p21 is not expressed in normal thyroid tissue, and is expressed in follicular adenomas, and in both

well- and poorly-differentiated carcinomas. There is some discrepancy regarding whether p21 is up-regulated or down-regulated during the transition from a well- to a poorly-differentiated tumour. The differences in p21 expression in these studies can be also be partially attributed to the different scoring systems used. For example, Hermann et al., (2001), used >10% cells as a cut-off point for a positive result, Ferenc et al., (2004b), used >20% cells as a cut-off point, and Brzezinski et al., (2005), scored 11-50% cells as a positive result and >50% cells as over-expression of p21. Also, as before, a range of different antibodies and immunohistochemistry protocols were used, so it is therefore difficult to accurately compare results between papers. Finally, most studies, like my own, analysed only small numbers of cases for each tumour group, and therefore repeating these experiments with a much larger sample group, and with similar numbers of cases in each tumour group, would give a more accurate result.

One of the original findings in this study is the correlation of cyclin D1 and p16 staining in the follicular adenomas, follicular and papillary carcinomas. I demonstrated a positive correlation between cyclin D1 and p16 expression in the follicular adenomas, and this finding was consistent with my hypotheses from chapters 3 and 4. I also demonstrated a statistically significant positive correlation between the expression of cyclin D1 and p16 in the follicular carcinomas ( $p = 0.02$ ) and the papillary carcinomas (0.033). Although the increase in p16 expression in the carcinomas was unexpected, the increase in cyclin D1 expression was not. If the reason for cyclin D1 over-expression in these slow-growing indolent tumours is because of the neoplastic drive to proliferate, p16 could be over-expressed as a mechanism to keep these

tumours 'in-check', and therefore prevent uncontrolled proliferation until other genetic mutations are acquired which result in a more poorly-differentiated tumour phenotype.

I have shown in chapter 3 that p16 is down-regulated in the poorly- and undifferentiated thyroid tumours, and suggested that this is related to the considerable increase in proliferation in these aggressive cancers, as well as their increasing potential to metastasise and invade, and their worse clinical prognosis. Therefore I would expect cyclin D1 to be expressed at an even higher level in these poorly-differentiated cancers, as shown by Wang et al., (2000).

The second original finding in this study is the correlation of p21 and p16 staining in the follicular adenomas, follicular and papillary carcinomas. There was a very low level of p21 expression in the follicular adenomas with 90% of cases having 1-3% positively staining cells. In contrast, there was a much greater increase in p16 expression in the adenomas when compared to normal thyroid tissue, consistent with the hypothesis from chapter 3.

Whilst p16 continued to be over-expressed in both the follicular and papillary carcinomas, at a level higher than that seen in the follicular adenomas, a similar up-regulation of p21 expression was not seen in these cancers. Over half of the follicular carcinomas did not express p21. The follicular carcinomas that did express p21 had between 10-20% positively staining cells. However these three cases had the lowest and the highest p16 I.D. scores, and there

was therefore not a statistically significant relationship between the expression of these two proteins in follicular carcinomas.

Similarly, in the papillary carcinoma group, there was an up-regulation of p21 expression, at a similar level to that seen in the follicular carcinomas. However a significant relationship between p21 and p16 expression could also not be demonstrated for this tumour group. The tumours that did not express p21 had high p16 I.D. scores, and the tumours that did express p21 had both high and low p16 I.D. scores.

This data suggests that p21 does not have a major role to play in cell cycle control in the progression from a benign to a malignant well-differentiated thyroid tumour. This is because of the minimal up-regulation in p21 expression seen between the follicular adenomas and the follicular and papillary carcinomas, and the lack of correlation with p16 expression, suggesting that p16 is a more important tumour suppressor gene in thyroid tumorigenesis. These results may also help to explain why there is such a wide variation in immunohistochemical expression of p21 in thyroid tumours in the literature.

The immunohistochemical expression of both cyclin D1 and p21 has been widely studied in several human malignancies. In colorectal tumorigenesis, colorectal adenomas show an increase in p21 expression (Doglioni et al., 1996), with a mean of 10.5% cells per adenoma showing p21 expression. They demonstrated a considerable increase in cyclin D1 expression in the colorectal carcinomas studied, with 50% cases showing p21 over-expression in heterogenous small clusters. In contrast, Sinicrope et al., (1998), and

McKay et al., (2000), observed a down-regulation of p21 expression in colon carcinomas when compared to adenomas, and they suggested that this loss of p21 expression in colorectal tumours may be responsible for unrestrained proliferation. In correlation with the reduction in p21 expression seen in colon cancer, McKay et al., (2000), observed an increase in cyclin D1 expression in 52.4% carcinomas, and an over-expression of cyclin D1 in 26% primary tumours and 38% metastatic deposits.

Jung et al., (2001), observed an up-regulation of cyclin D1 expression in 30% cells at the invasive front of colorectal carcinomas. The majority of these cells were not actively proliferating, and many were also positive for p16 expression. This was unexpected, since cyclin D1 promotes and p16 inhibits passage through the cell cycle. They hypothesised that the dual expression of p16 and cyclin D1 kept the cells in a state of quiescence, which may allow them to differentiate to a mesenchymal or more malignant phenotype, and that the future loss of p16 may lead to unrestrained cell proliferation. This is similar to my own results in well-differentiated, slow-growing thyroid tumours, in which both cyclin D1 and p16 were up-regulated.

Guner et al., (2003), studied p21, p16 and cyclin D1 expression in oesophageal carcinomas, and demonstrated a mean of 10% tumour cells staining positively for p21. In the same tumour group, a mean of 30% cells per tumour were positive for cyclin D1 expression. The tumours with a high p16 and a low cyclin D1 expression (presumed to indicate an intact Rb pathway), had an excellent prognosis, whilst those tumours with over-expression of cyclin D1 and loss of either p16 or p21 had a shorter overall survival, implicating that

the Rb pathway is crucial in the development of oesophageal carcinoma. Takeuchi et al., (1997), reported similar findings, with cyclin D1 over-expression and p16 loss being correlated with metastatic spread and a shorter survival time.

Several authors have studied p21 expression in gastric carcinomas, and the majority report that loss of p21 expression is linked to a poor prognosis, shorter survival time and a more aggressive tumour phenotype (Liu et al., 2001; Noda et al., 2001; Noda et al., 2002), although some papers found no correlation between prognosis and p21 expression (Kaye et al., 2000). Noda's group (2002) also noted that loss of p21 expression contributed to an increase in proliferation in patients with early stage gastric carcinoma, highlighting the tumour suppressor gene function of p21.

Normal prostatic tissue does not show p21 expression. Doganavsargil et al., (2006), found that p21 was over-expressed in both carcinoma-in-situ and prostate cancers, and that p21 expression was greatest in those tumours with extra-prostatic invasion which was contrary to expectations. Since p21 is a tumour suppressor, the loss of its activity is expected to correlate with increased tumour proliferation and therefore a worse prognosis. Drobnjak et al., (2000), studied cyclin D1 expression in prostate carcinomas, and found that it was over-expressed in 11% primary tumours and 68% bony metastases, with a significant correlation between cyclin D1 over-expression and an increase in tumour proliferation. These results suggest that cyclin D1 over-expression is an indicator of a poor outcome.

Li et al., (2006), reviewed p21 and cyclin D1 expression in malignant melanomas. They summarised that p21 expression is over-expressed in both primary malignant melanomas and in metastases, although there was a down-regulation in the metastases when compared with the primary tumours. Cyclin D1 is also up-regulated in melanocyte cell lines, malignant melanomas and in melanotic metastases at a frequency ranging from 35-61%, suggesting that up-regulation of cyclin D1 together with loss of p21 is associated with metastatic spread and a worse prognosis.

In summary, in oesophageal, gastric and some colorectal cancers, the loss of p21 expression and an increase in cyclin D1 expression is associated with a worse prognosis. In malignant melanoma and prostate carcinoma, an increase in both cyclin D1 and p21 expression is seen in primary cancers and their metastases, and is therefore associated with a worse prognosis. The increase in expression of both p21 and cyclin D1 seen in melanoma and prostate cancer is in keeping with the published findings in thyroid cancer.

Mitra et al., (1999), studied sarcoma cell lines and observed that expression of p16 and the corresponding inhibition of the cell cycle were associated with a post-transcriptional induction of p21. Therefore p16 inhibited cyclin D-cdk4/6 complexes, and p21 inhibited cyclin E-cdk2 complexes, and this functional cooperation between these two tumour suppressor genes constitutes another level of regulation of cell growth via the cell cycle, and a common element in the Rb and p53 pathways. This induction of p21 in the cell lines could be a possible explanation for the limited up-regulation of p21 expression seen in thyroid tumours that I analysed. The continued expression of p16 in these



well-differentiated tumours acts by keeping the tumours 'in check', and simultaneously induces p21 expression as another means of regulating the G1-S phase checkpoint. However, p21 mutations are only seen at low levels in human tumours in comparison to other tumour suppressor genes such as p16, which gives more support to p21 having a limited role to play in the regulation of the cell cycle in neoplasia.

I also correlated the expression of cyclin D1 and p21 with that of two markers of proliferation, namely MCM2 and cyclin A, described in Chapter 3. As stated previously, cyclin D1 is not expressed in normal thyroid tissue, is expressed in thyroid follicular adenomas, and at a higher level in both follicular and papillary carcinomas. In keeping with the oncogenic role of cyclin D1 expression, I hypothesized that MCM2, a marker of cells that are capable of proliferating, would be positively correlated with cyclin D1 expression. This was true for the follicular adenomas and carcinomas; however there was a negative correlation between cyclin D1 and MCM2 expression in the papillary carcinomas, although this was not statistically significant.

The analysis of p21 and MCM2 expression produced similar findings. The expression of p21 protein was up-regulated in the follicular adenomas, and further up-regulated in the follicular and papillary carcinomas. The expression of MCM2 was also induced in the adenomas and to a greater extent in the carcinomas, however there was a negative correlation between p21 and MCM2 expression in both the follicular and papillary carcinomas. This may be in keeping with the tumour suppressor action of p21, although I have suggested that p21 has a minimal role in early thyroid tumorigenesis.

Cyclin D1 and cyclin A, a marker of the S-phase of the cell cycle, were expressed in the follicular adenomas at a higher level than that seen in normal thyroid tissue, and the expression of both proteins was higher still in the follicular and papillary carcinomas. There was no statistically significant correlation between these two proteins for either the benign or malignant tumours. I have already described that the expression of cyclin D1 and p16 are significantly correlated, and suggested that both proteins are keeping the cell 'in check', until further mutations are acquired which eventually lead to uncontrolled proliferation, and therefore I did not expect to see a significant positive correlation between cyclin D1 and cyclin A in these tumour groups. I hypothesise that there should be a positive correlation between these two proteins in the poorly-differentiated and undifferentiated thyroid carcinomas, in keeping with the increase in proliferation seen in these tumours.

Both p21 and cyclin A were expressed at low levels in the follicular adenomas, and there was no significant correlation in this tumour group. However, there was a negative correlation between the two proteins in the follicular carcinoma group, with the three cases that expressed p21 having very low levels of cyclin A expression. This negative correlation may be in keeping with the role of p21 as a tumour suppressor gene. This negative correlation was not observed in the papillary carcinoma group, and there was no significant correlation between cyclin A and p21 in these tumours.

While analysing my results, I had to take several factors into consideration. I was not blinded to the pathology of the tumour sections prior to staining with anti-cyclin D1 and anti-p21 antibodies, and this is a source of bias. I also only

had access to small numbers of cases for each tumour group (follicular adenomas, follicular carcinomas and papillary carcinomas), which meant that my potential conclusions and statistical analyses might be different if a larger sample size was analysed. I assessed both the intensity and area of positive staining when scoring cyclin D1 expression to give a more accurate representation of the cyclin D1 status for each tumour, rather than using an arbitrary value to designate a 'positive' or 'negative' result, as has been used in previously published studies.

I have contributed to the existing knowledge regarding the Rb pathway and cell cycle control in early thyroid tumorigenesis by demonstrating a positive, statistically significant correlation between cyclin D1 and p16 expression in follicular carcinomas and papillary carcinomas. I was unable to demonstrate a significant correlation between either p21 and p16 expression or p21 and cyclin D1 expression in the progression from a benign to a malignant thyroid tumour. I was also unable to demonstrate a significant correlation between p21 / cyclin D1 expression and MCM2 / cyclin A expression.

I therefore conclude that p21 has a minimal role to play in the abrogation of cell cycle control, or that this gene is mutated at a very late stage in thyroid tumorigenesis. This is because, according to previously published results, p21 continues to be expressed, although at low levels, in the undifferentiated aggressive anaplastic thyroid tumours, which are by definition undergoing uncontrolled proliferation. However the majority of cells in all thyroid cancers are negative for p21 expression. p21 may be acting as a tumour-suppressor gene to arrest proliferation only in the sub-population of cells in which it is

expressed. Furthermore, p53 mutation only occurs in these aggressive tumours, and therefore p53-mediated control of the cell cycle must also be lost, so that in these cancers, p21 must be being induced by p53-independent pathways. These p53-independent pathways may however give the sub-populations of p21-expressing tumour cells a different advantage in the malignant process, for example in de-differentiation or metastasis.

My results are in keeping with the known fact that well-differentiated thyroid cancers are indolent, slow-growing tumours, and this has been confirmed by the low levels of cyclin A expression seen in the well-differentiated thyroid tumours. The data indicates that the increase of both p16 and cyclin D1 expression in these adenomas may keep the cells in a slowly cycling state until they attain some of the other features needed to become malignant, as described by Hanahan and Weinberg (2000), namely self-sufficiency in growth signals, evasion of apoptosis, sustained angiogenesis and the ability to invade tissues and metastasise.

The continued increase in cyclin D1 and p16 expression seen in the malignant follicular and papillary carcinomas was unexpected, as stated in chapter 3. This may be one of the mechanisms behind the continued low proliferative rate in these tumours. A thyroid cancer may only develop unlimited replicative potential once all of the neoplastic features are in place as a result of further genetic mutations and rearrangements, as seen in the undifferentiated anaplastic carcinomas which have continued over-expression of cyclin D1, and a down-regulation of p16 expression (Ball et al., 2007).

It takes a finite amount of time for these genetic and epigenetic mutations to occur, and there needs to be a sustainable period of clonal expansion of the tumour cells for there to be a chance of another subsequent event, and for this event to co-operate with the previous one in the malignant transformation. Because thyroid cancers have such a slow turnover there is only a very small likelihood of all these genetic events occurring to produce an aggressive, rapidly proliferating tumour, in contrast to colorectal carcinomas and malignant melanomas, since their normal tissues have a much higher turnover. This would explain why there is such a low incidence and prevalence of anaplastic cancer when compared with follicular and papillary thyroid carcinoma.

Having ascertained that neither the loss of p16 or p21 is individually responsible for progression of early thyroid tumours to a malignant phenotype, there must either be another member of the Rb pathway that is mutated (for example cdk4), or another / several Rb-dependent or independent pathways involved in early thyroid tumorigenesis. This is because a follicular adenoma can develop into a follicular carcinoma without the loss of p16 or p21 expression. The tumour cells must be able to keep dividing, albeit slowly, in the presence of these tumour suppressor genes and this may be due to one or several pathways that maintain control over cell replication and tumorigenesis that are hitherto undiscovered.

#### 4.5 Conclusions

- p21 expression is minimally expressed in thyroid follicular adenomas, and is up-regulated in some follicular and papillary carcinomas.
- cyclin D1 expression is up-regulated in follicular adenomas and is up-regulated in some follicular and papillary carcinomas.
- There is a statistically significant correlation between cyclin D1 and p16 expression in the follicular and papillary carcinomas.
- There is no significant correlation between p21 and p16 expression in follicular and papillary carcinomas.
- Thyroid follicular cells are therefore able to transform into a malignant phenotype that has the ability to metastasise whilst still expressing the cell cycle inhibitors p16 and p21.
- Another hitherto undiscovered pathway may also be involved in the control of thyroid tumorigenesis, which prevents uncontrolled proliferation until the tumour develops a more aggressive phenotype, or other candidate genes in the Rb pathway may need to become mutated before cell cycle control is lost.

#### **4.6 Further work**

The repetition of this study with a much larger sample size, including poorly-differentiated papillary, insular and anaplastic carcinomas, would give a more accurate representation of the relationships between cyclin D1, p21 and p16 expression in thyroid tumorigenesis. The observers should be blinded to the diagnosis of each tissue specimen.

Long-term clinical follow-up of the patients would allow for analysis of cyclin D1, p21 and p16 expression with regards to metastases, tumour recurrence and length of survival, and to assess whether these genes can be used to determine clinical prognostic outcomes.

Co-analysis of other members of the Rb pathway, such as cdk4, cdk6, cyclin E and pRb, together with p16, cyclin D1 and p21 would further elucidate the function and abrogation of the Rb pathway during thyroid tumorigenesis.

## CHAPTER 5

### AN IMMUNOHISTOCHEMICAL STUDY OF INTERFERON-STIMULATED GENE EXPRESSION IN MULTISTEP THYROID TUMORIGENESIS

#### 5.1 Introduction

I have previously discussed the biological characteristics of thyroid tumours in Chapter 1, which range from benign, indolent follicular adenomas, to slow-growing yet potentially fatal follicular and papillary carcinomas, and rapidly proliferating, aggressive anaplastic carcinomas. A considerable amount of work has been published regarding the genetic changes involved in thyroid tumorigenesis, for example mutations in RAS, BRAF and RET/PTC. However, the early genetic mutations involved in the development of thyroid tumours either de novo from normal thyroid tissue or from follicular adenomas are not clear.

The forced expression of RAS in thyrocytes induces proliferation, and after 20-25 population doublings (p.d.) the clones stop dividing, and at this stage they are phenotypically similar to a follicular adenoma (Bond et al., 1994). The nature of the mechanism inhibiting this proliferation is uncertain. The number of p.d. that the thyrocytes undergo is too large to be explained by the "premature senescence" induced by RAS in fibroblasts (Serrano et al., 1997). Jones et al., (2000), demonstrated that this mechanism was telomere-independent, since the growth arrest was not prevented by the forced expression of sufficient telomerase to prevent telomere erosion. This growth arrest is tightly correlated with a progressive increase in p16 expression. My



work on p16 expression in thyroid tumours in vivo in Chapter 3 indicates that this is not the only gene involved in early thyroid tumorigenesis, and that a second pathway appears to be in play. The analysis of p21 and cyclin D1 expression in the same thyroid tumour groups also suggests the presence of another protein or pathway influencing thyroid tumorigenesis and cell proliferation.

One of the candidate mechanisms for this second pathway is the interferon pathway. There is long-standing evidence in the literature to suggest that the interferons and their downstream effectors have a role to play in tumour suppression. HLA-DR is one of the major interferon-stimulated genes that has been extensively studied in the literature, and de novo expression of HLA-DR has been observed in a wide range of human tumours, including melanoma (Brocker et al., 1984; Wilson et al., 1984; Natali et al., 1986), and breast (Feinmesser et al., 2000), lung (Wilson et al., 1984; Dammrich et al., 1990), and colon cancer (Daar et al., 1982; Norheim Andersen et al., 1996). In colorectal carcinoma, where the multiple stages of tumorigenesis can be easily defined (adenoma, well- and poorly-differentiated carcinoma), the data are consistent with ISG expression beginning in the late-stage adenomas. This data suggests that the up-regulation of interferon-stimulated genes such as HLA-DR may have some clinical relevance.

In order to evaluate whether the interferon pathway was a potential trigger for the in vitro growth arrest seen in RAS-induced thyrocytes colonies, our laboratory performed large scale expression profiling using high-density Affymetrix GeneChip oligonucleotide microarrays on untreated thyrocytes

colonies, and early- and late-stage RAS- induced thyrocyte colonies. Our data revealed a striking and un-expected up-regulation of many interferon-stimulated genes (ISG) in the RAS-induced colonies, and included ISGs involved in interferon signalling, antigen processing, and antigen presentation and antiviral responses. This up-regulation correlated with the spontaneous arrest of clonal expansion in these colonies. Additionally, the microarrays identified that the p16 gene increased in expression in the senescent late-stage RAS-induced colonies, and this confirms the in vitro protein expression of p16 in these colonies, described in chapter 3.

The up-regulation of ISGs occurred in the absence of experimentally-provided interferon to the tissue culture medium. This led us to postulate that this induction of interferon signalling in these thyrocytes may be a novel innate tumour suppressor mechanism in human epithelial cells, acting either by affecting the immunogenicity of the cells, or by controlling cell proliferation. Furthermore, the potentially cell-autonomous expression of these interferon-stimulated genes may act in tandem with established cell cycle inhibitors such as p16 in the early stages of thyroid tumorigenesis to restrain tumour growth.

The up-regulation of ISGs seen in this early stage of thyroid tumorigenesis may have a role to play in tumour suppression and limiting oncogene-induced proliferation, potentially by the enhancement of the tumour's immunogenicity (Kaplan et al., 1998). Alternatively, the activation of RAS and the tissue culture micro-environment could act as "stress signals" that are triggering the interferon pathway (Wright and Shay, 2001).

My earlier work involving p16 expression in vivo suggests that our model of early-stage thyroid tumorigenesis is a good representation of the in vivo neoplastic transformation. I therefore hypothesised from the Affymetrix data that the up-regulation of ISGs seen in vitro would also occur at the follicular adenoma stage in vivo. In order to test this hypothesis, I selected three ISGs that were up-regulated in the RAS colonies (HLA-DR, PKR and MxA) to use for immunohistochemical analysis on follicular adenomas, follicular and papillary carcinomas. This is the first study to analyse the immunohistochemical expression of these ISGs in thyroid tumours, and correlate their expression with that of p16. My work will further enhance our understanding of the complex pathways involved in early thyroid tumorigenesis.

## 5.2 Method

### 5.2.1 Immunohistochemistry

I performed immunohistochemistry on formalin-fixed, paraffin-embedded tissue sections. I used heat-mediated antigen retrieval (HMAR) prior to incubation with anti-HLA-DR and anti-PKR antibodies, using one litre of 10mM EDTA (pH 7.0) in a microwave oven (20 minutes at 800W). The sections being stained with anti-MxA antibody did not undergo HMAR. I then pre-treated the slides with a DAKO peroxidase-blocking solution (DakoCytomation) prior to incubation for one hour at room temperature with one of the following antibodies:-

- (i) mouse monoclonal anti-HLA-DR antibody clone TAL.1B5 (DakoCytomation) at a dilution of 1:200
- (ii) mouse monoclonal anti-PKR antibody sc-6282 (Santa-Cruz) at a dilution of 1:50 (4µg/ml)
- (iii) mouse monoclonal anti-MxA antibody (kindly supplied by G Kochs, Universität Freiberg, Germany at a dilution of 1:1000)

Secondary amplification was accomplished using the DAKO Envision<sup>+</sup>™ kit, and I visualised antibody binding using DAB chromogen (DakoCytomation), followed by counterstaining with haematoxylin.

### 5.2.2 Scoring of slides

I counted five hundred cells per slide, and calculated the percentage of positive-staining cells (labelling index, L.I.). The majority of tumours analysed were negative for all three antibodies, therefore I simply described the area and intensity of staining seen in those tumours that did show positive immunoreactivity for the given antibody, rather than give each tumour an individual staining score.

### 5.3 Results

#### 5.3.1 anti-HLA-DR, PKR, MxA antibody validation

I performed a literature search to look for research using anti-HLA-DR, anti-PKR and anti-MxA antibodies for immunohistochemical analysis of formalin-fixed, paraffin-embedded tissues. The majority of papers used the monoclonal DAKO anti-HLA-DR antibody and the monoclonal Santa-Cruz anti-PKR antibody. I selected these antibodies and trialled them at a range of dilutions for different incubation times. The dilutions that I used (stated above) gave the most reproducible results with minimal background staining. I used a normal human tonsil as a positive control tissue, and for negative controls I used an isotype-matched mouse monoclonal anti-prolactin antibody (Pharmingen) at equivalent dilutions, and antibody diluent solution (DAKO). The tonsil showed a strong positive reaction with all three antibodies (Figure 5.1), and produced a negative reaction when immunostained with the anti-prolactin antibody and the antibody diluent (Figure 5.2).

#### 5.3.2 Expression of HLA-DR

Four sections of normal thyroid tissue were stained, and all samples did not show HLA-DR protein expression (Figure 5.3). Ten follicular adenomas were analysed for HLA-DR expression, and all ten tumours did not show HLA-DR expression (Figure 5.4). I stained eight follicular carcinomas, and seven of the eight tumours did not show HLA-DR immunoreactivity (Figure 5.5A). However one of the carcinomas showed a small focus of intense HLA-DR staining, and this staining was reproduced on serial sections (Figure 5.5B).

Seven papillary carcinomas were immunostained, and four of the seven were negative for HLA-DR expression. The remaining three tumours however demonstrated a moderate intensity of HLA-DR expression in 60-80% of the papillary tumour cells (Figure 5.6). Two of the three HLA-DR positive tumours had a strong lymphocytic infiltrate. The staining results are summarised in Tables 5.1, 5.2 and 5.3.

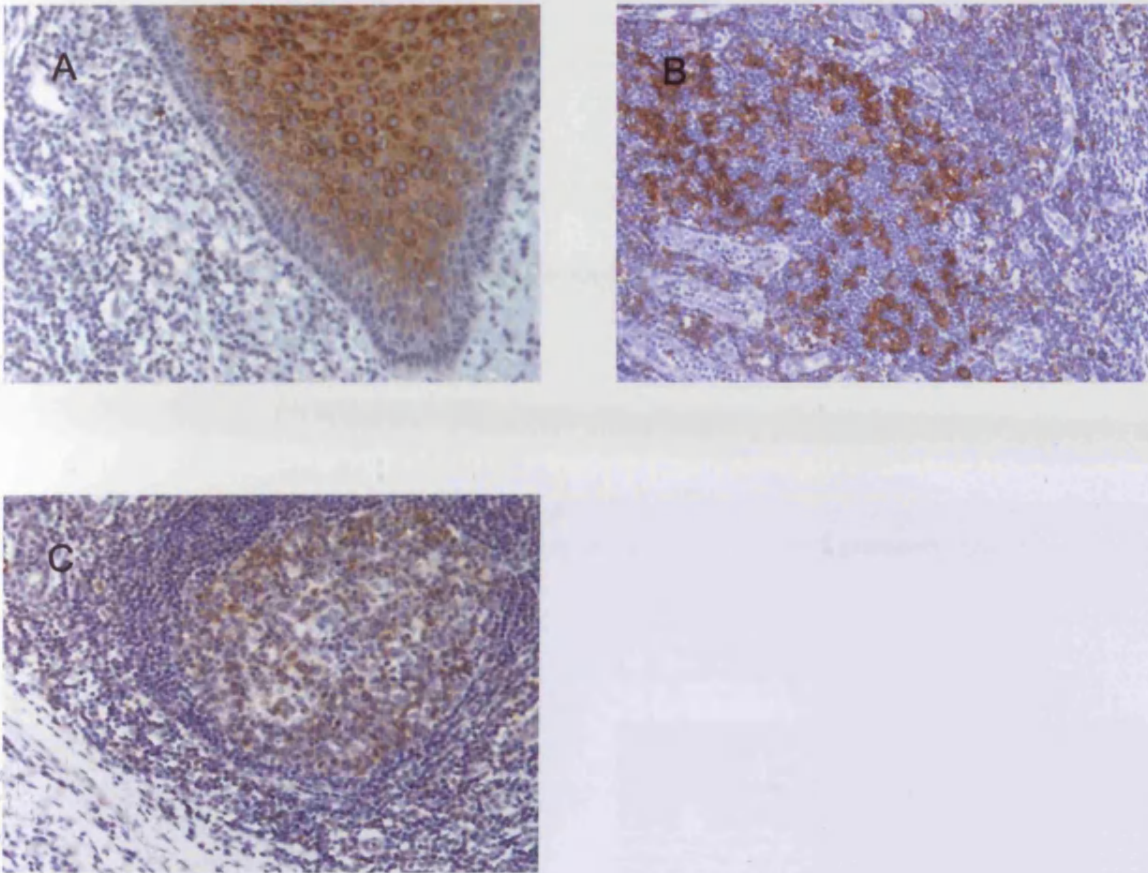


Figure 5.1 Immunohistochemical staining with anti-HLA-DR antibody (A), anti-PKR antibody (B) and anti-MxA antibody (C) of human tonsil tissue, demonstrating a positive brown reaction.

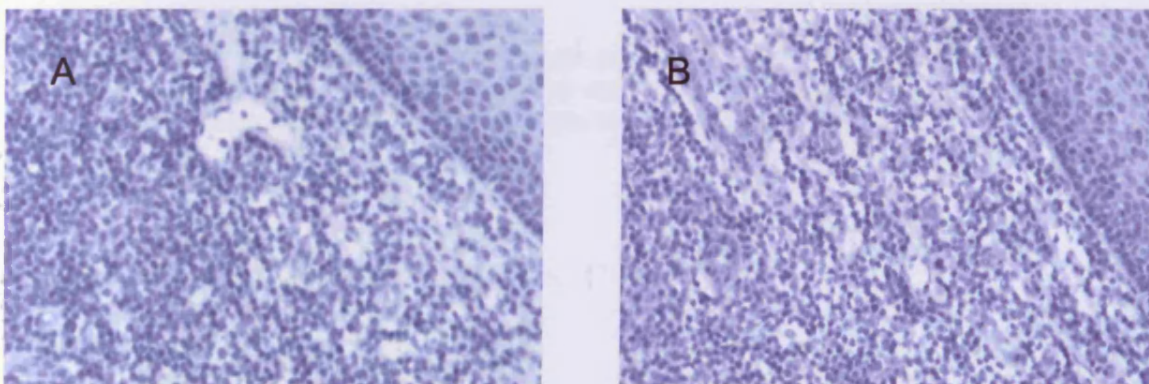


Figure 5.2 Immunohistochemical staining with anti-prolactin antibody (A) and antibody diluent solution (B) of human tonsil tissue demonstrating the absence of a positive reaction.



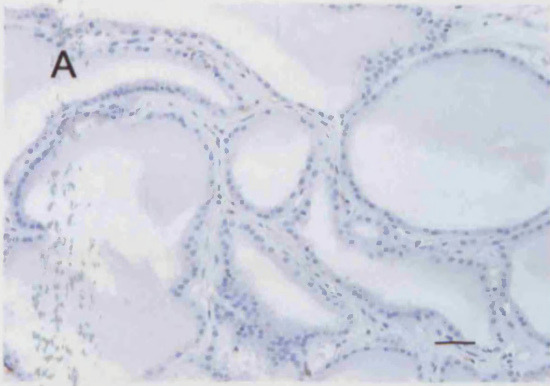


Figure 5.3 Immunohistochemical staining with anti-HLA-DR antibody of normal thyroid tissue showing the absence of a positive reaction. Scale bar represents 200 $\mu$ m.

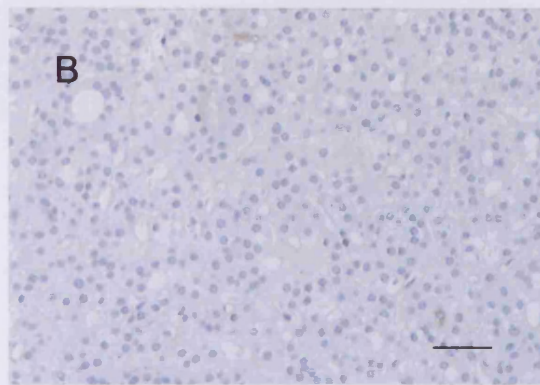
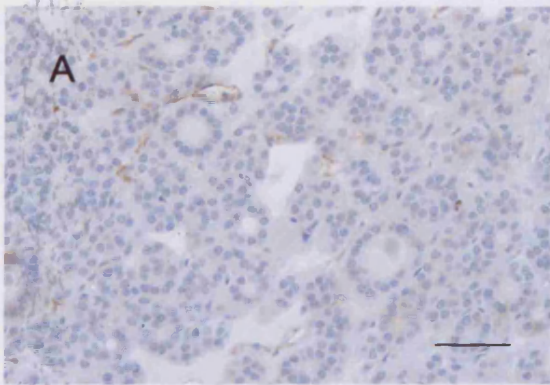


Figure 5.4 Immunohistochemical staining with anti-HLA-DR antibody of two follicular adenomas showing the absence of a positive reaction. Case A demonstrates the brown staining of associated dendritic cells. Scale bar represents 200 $\mu$ m.

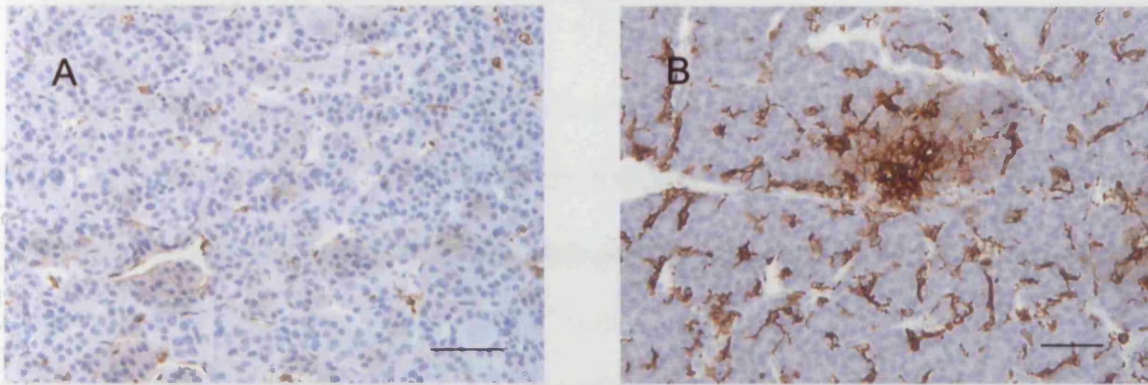


Figure 5.5 Immunohistochemical staining with anti-HLA-DR antibody of two follicular carcinomas. Case A represents a tumour that does not express HLA-DR. Case B represents the tumour with a cluster of positively staining cells. Both cases also demonstrate a positive reaction in associated dendritic cells. Scale bar represents 200 $\mu$ m.

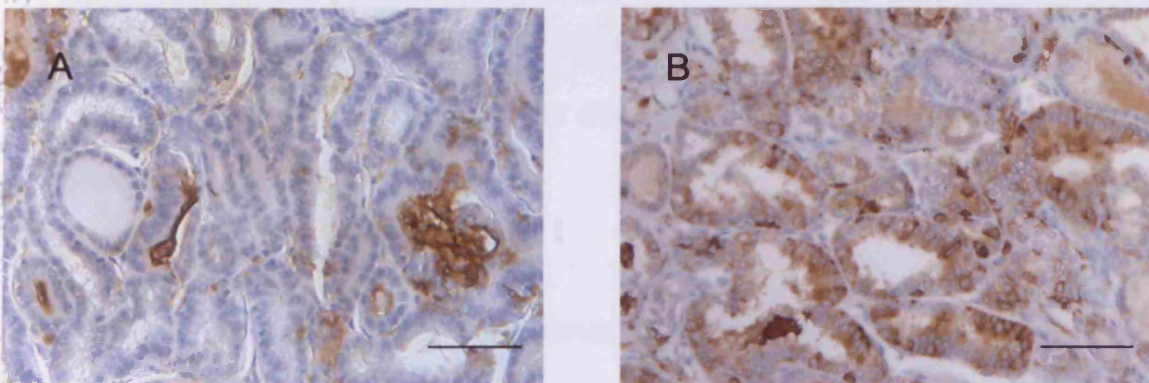


Figure 5.6 Immunohistochemical staining with anti-HLA-DR antibody of two papillary carcinomas, showing a positive brown cytoplasmic reaction, with associated positively staining dendritic cells. Scale bar represents 200 $\mu$ m.

### 5.3.3 Expression of PKR

All four sections of normal thyroid that were immunostained did not show PKR expression (Figure 5.7). Out of the ten follicular adenomas, eight did not show PKR expression. The remaining two adenomas demonstrated a moderate intensity of cytoplasmic staining in 75-85% of the tumour cells (Figure 5.8). Five out of the eight follicular carcinomas were negative for PKR expression. Two out of the remaining three tumours had 2-3 positively-staining cells in the whole tumour, but overall these tumours were negative for PKR expression. One of these was the carcinoma previously described that had the intense focus of HLA-DR staining (Figure 5.9A). The remaining follicular carcinoma showed some PKR expression, with 25% cells demonstrating weak cytoplasmic staining, and 10% tumour cells demonstrating a moderate staining intensity (Figure 5.9B).

Three of the seven papillary carcinomas did not show express PKR (Figure 5.10A). One cancer demonstrated weak expression in 15% cells. Two papillary cancers had weak expression in 50-70% cells with moderate expression in 10% cells, and the final tumour had weak staining in 10% cells and a moderate staining intensity in 60% cells. Two of the three papillary cancers with the higher PKR expression also had a lymphocytic infiltrate (Figure 5.10B). The staining results are summarised in Tables 5.1, 5.2 and 5.3.



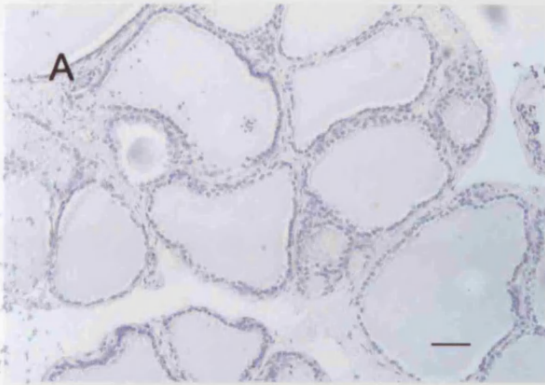


Figure 5.7 Immunohistochemical staining with anti-PKR antibody of normal thyroid tissue showing the absence of a positive reaction. Scale bar represents 200 $\mu$ m.

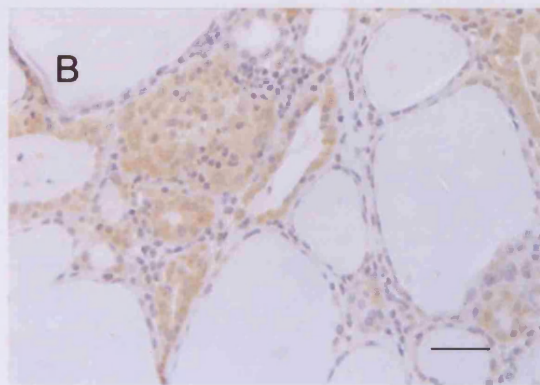
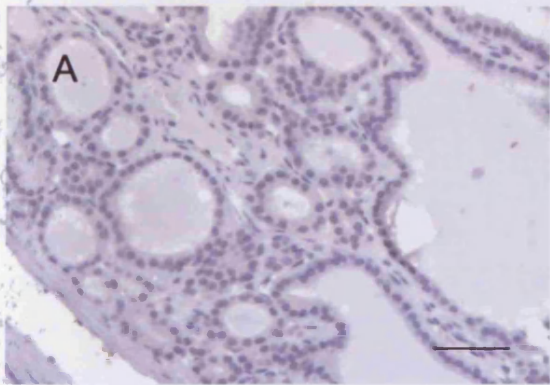
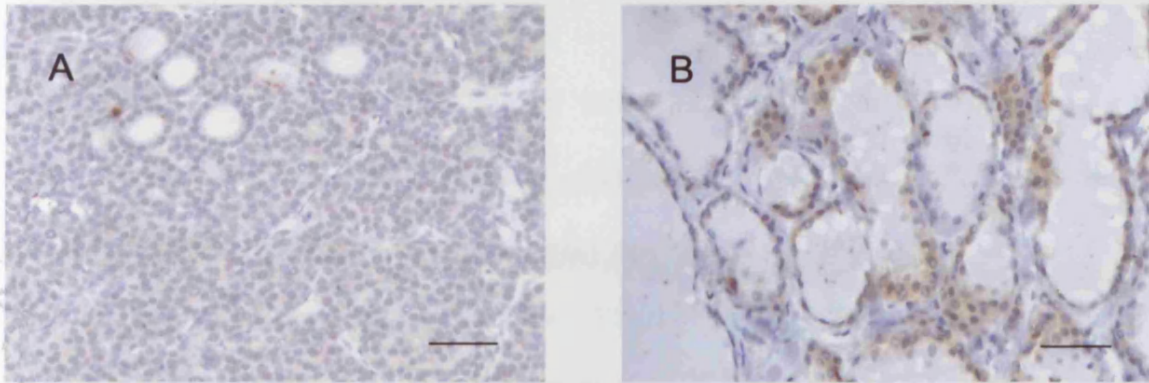
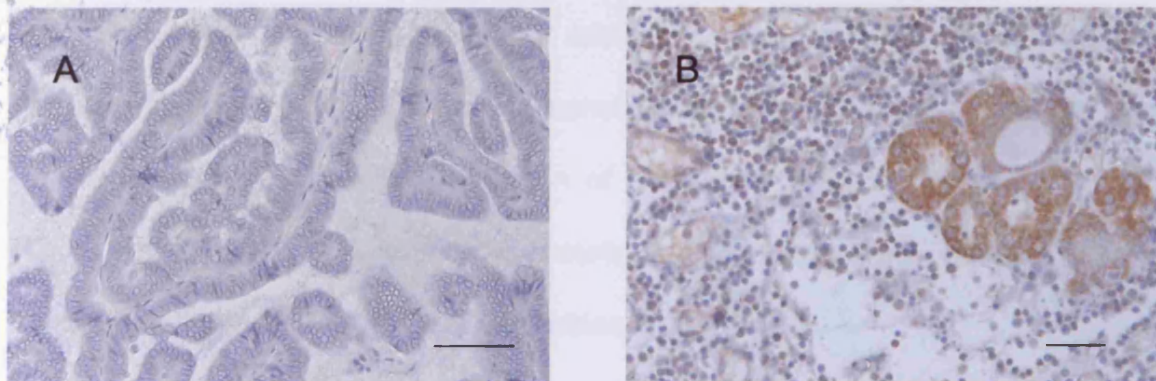


Figure 5.8 Immunohistochemical staining with anti-PKR antibody of two follicular adenomas. Case A does not express PKR, and case B demonstrates a positive reaction. Scale bar represents 200 $\mu$ m.



**Figure 5.9** Immunohistochemical staining with anti-PKR antibody of two follicular carcinomas. Case A represents the area of the tumour that had the cluster of HLA-DR expressing cells, and this tumour does not show PKR expression. Case B is the follicular cancer that had an up-regulation of PKR expression, as shown by the brown cytoplasmic reaction. Scale bar represents 200µm.



**Figure 5.10** Immunohistochemical staining with anti-PKR antibody of two papillary carcinomas. Case A is a cancer that did not express PKR protein, and case B is a papillary cancer with a lymphocytic infiltrate that showed an up-regulation of PKR expression. Scale bar represents 200µm.

#### 5.3.4 Expression of MxA

The four sections of normal thyroid were all negative for MxA expression (Figure 5.11). All ten follicular adenomas also did not show MxA immunoreactivity (Figure 5.12). Seven out of the eight follicular carcinomas did not demonstrate MxA expression (Figure 5.13A). The remaining cancer had a small cluster of cells that demonstrated a strong cytoplasmic reaction (Figure 5.13B). This was the same cancer that had an intense focus of HLA-DR staining, and the MxA staining focus was in the same position as the HLA-DR focus. The MxA focus was also reproduced in serial sections.

Five out of the seven papillary carcinomas did not demonstrate MxA expression (Figure 5.14A). The remaining two cancers showed weak cytoplasmic reactivity in 80% of the tumour cells (Figure 5.14B), and these two cases also showed an up-regulation of both HLA-DR and PKR expression. Only one of the MxA-positive tumours had a lymphocytic infiltrate. The staining results are summarised in Tables 5.1, 5.2 and 5.3.



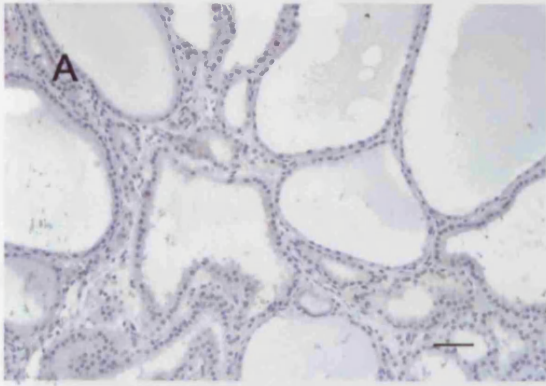


Figure 5.11 Immunohistochemical staining with anti-MxA antibody of normal thyroid tissue showing the absence of a positive reaction. Scale bar represents 200 $\mu$ m.

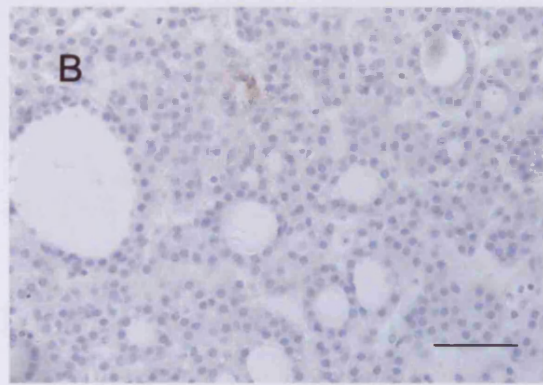
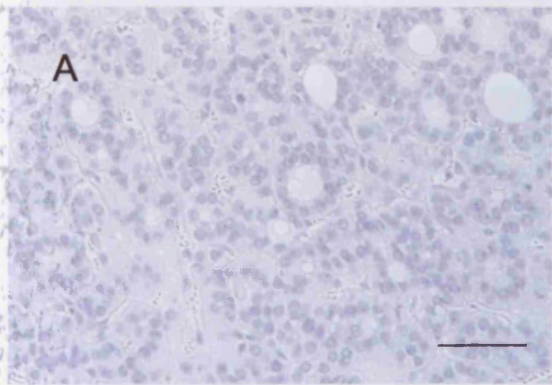


Figure 5.12 Immunohistochemical staining with anti-MxA antibody of two follicular adenomas showing the absence of a positive reaction. Scale bar represents 200 $\mu$ m.

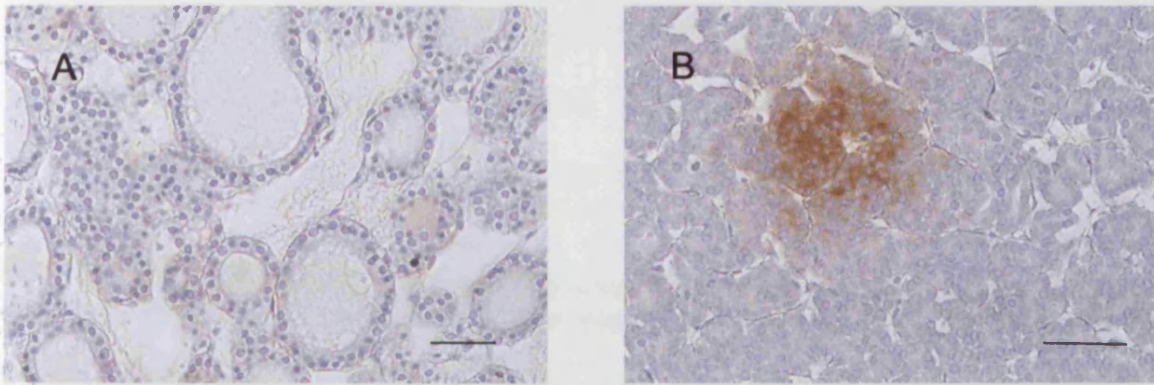


Figure 5.13 Immunohistochemical staining with anti-MxA antibody of two follicular carcinomas. Case A is a cancer that did not show MxA expression. Case B represents the area of the tumour that had the cluster of HLA-DR expressing cells, and this tumour also shows MxA expression in the same area of the cancer, as shown by a brown cytoplasmic reaction. Scale bar represents 200µm.

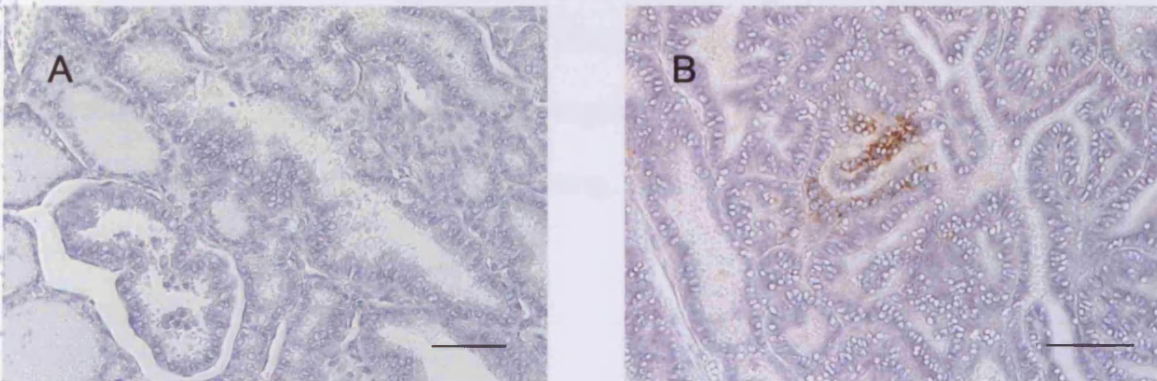


Figure 5.14 Immunohistochemical staining with anti-MxA antibody of two papillary carcinomas. Case A is a cancer that did not express MxA protein, and case B is a papillary cancer without a lymphocytic infiltrate that showed an up-regulation of MxA expression. Scale bar represents 200µm.



### 5.3.5 Co-expression of p16 with HLA-DR, PKR and MxA

HLA-DR and MxA were not expressed in the follicular adenomas. PKR was up-regulated with moderate expression in 75-80% tumour cells in 20% of the adenomas. As stated previously, p16 is up-regulated in the follicular adenomas, and the two tumours that expressed PKR had a p16 I.D. score of 0.5 and 0.8 (range 0.2 – 1.4). There was no significant correlation between p16 and ISG expression in the thyroid follicular adenomas studied.

HLA-DR and MxA were only expressed in one follicular carcinoma in an identical cluster of cells. This cancer had a p16 I.D. score of 1.6 (range 1-2.4), Figure 5.15. There was not an obvious correlation between the expression of ISGs and p16 in the follicular carcinomas, since the majority of tumours did not express ISGs. PKR was only up-regulated in one cancer, with 30% cells showing weak or moderate PKR staining, and this case had the lowest p16 I.D. score of 1.

It was only in the papillary carcinoma group that a trend could be observed between p16 and ISG expression. Three of the cancers with the lower p16 I.D. scores (1.1, 1.7, 1.7) did not express HLA-DR, PKR or MxA. One of the cancers with a low p16 I.D. score (1.3) did demonstrate an up-regulation of both HLA-DR and MxA, whilst another case with a mid-range p16 I.D. score (1.8) demonstrated weak PKR expression. The remaining two cases showed a large (in comparison to the other tumours studied) increase in HLA-DR, PKR and MxA expression, and these cases also had the highest p16 I.D. scores (2, 2.7), Figure 5.16.

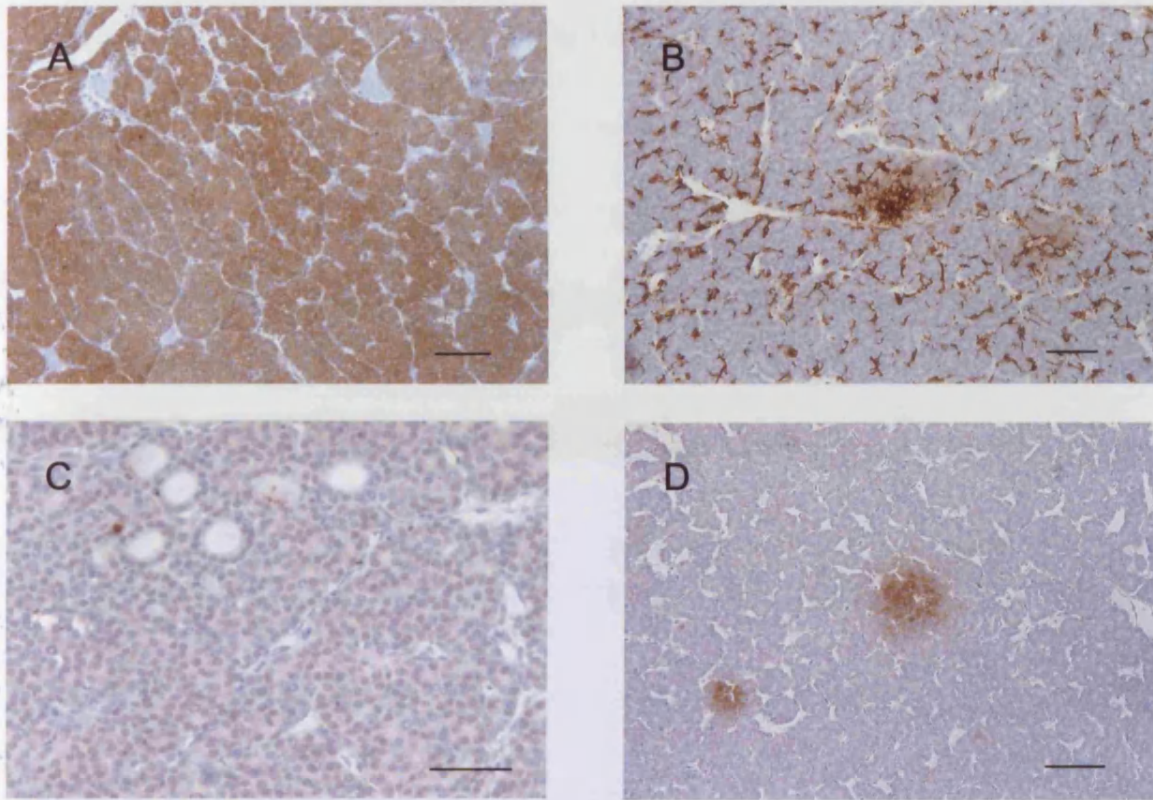


Fig 5.15 Immunohistochemical staining showing p16 (A), HLA-DR (B), PKR (C) and MxA (D) expression in the follicular carcinoma that expressed HLA-DR and MxA in a small cluster of cells. This area is shown in all four photographs. Scale bar represents 200 $\mu$ m.

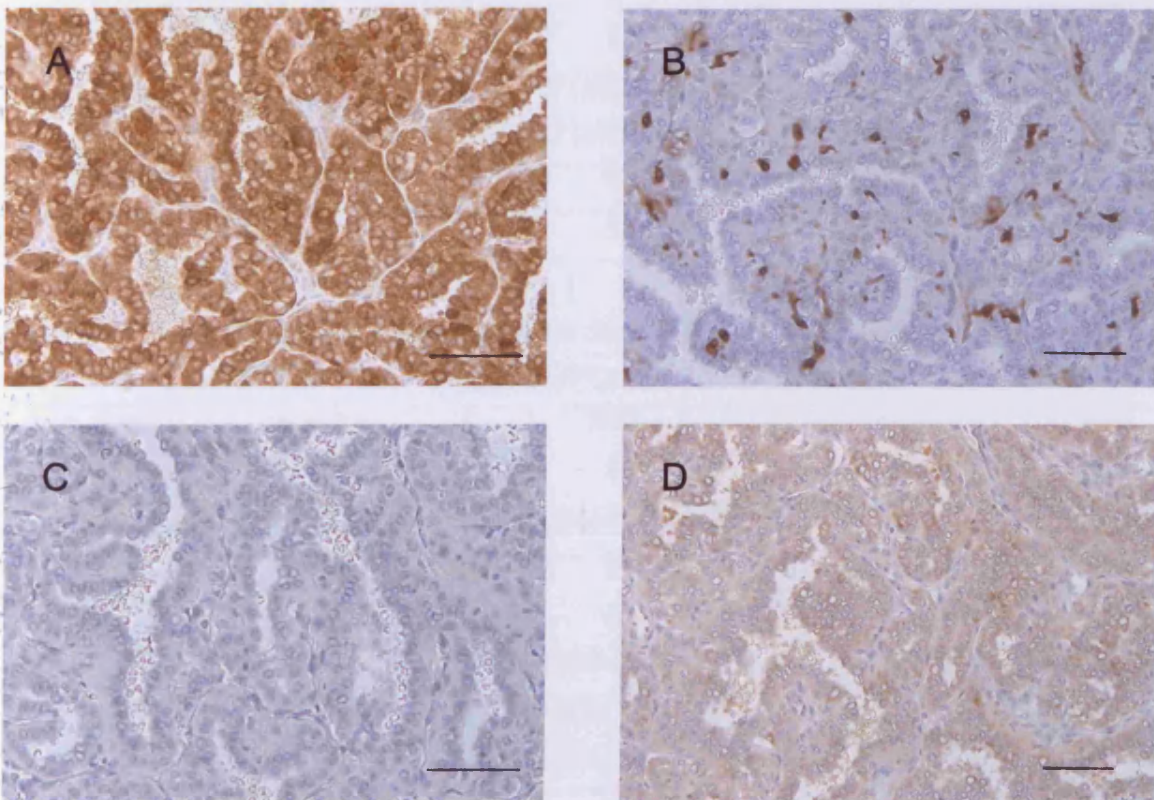


Fig 5.16 Immunohistochemical staining showing p16 (A), HLA-DR (B), PKR (C) and MxA (D) expression in a papillary carcinoma. The same area is shown in all four photographs. Scale bar represents 200 $\mu$ m.

Table 5.1 Immunohistochemistry results for HLA-DR, PKR, MxA and p16 expression in thyroid follicular adenomas (FA).

Pathology	HLA-DR	PKR	MxA	p16
FA	0	0	0	0.2
FA	0	0	0	0.3
FA	0	0	0	0.5
FA	0	75% mod.	0	0.5
FA	0	0	0	0.6
FA	0	85% mod.	0	0.8
FA	0	0	0	1
FA	0	0	0	1
FA	0	0	0	1
FA	0	0	0	1.4

Table 5.2 Immunohistochemistry results for HLA-DR, PKR, MxA and p16 expression in thyroid follicular carcinomas (FC).

Pathology	HLA-DR	PKR	MxA	p16
FC	0	25% weak, 10% mod.	0	1
FC	0	0	0	1.1
FC	0	0	0	1.2
FC	0	0	0	1.5
FC	0	2 cells only	0	1.5
FC	Intense focus	2 cells only	Intense focus	1.6
FC	0	0	0	1.8
FC	0	0	0	2.4

Table 5.3 Immunohistochemistry results for HLA-DR, PKR, MxA and p16 expression in thyroid papillary carcinomas (PC).

Pathology	HLA-DR	PKR	MxA	p16
PC	0	0	0	1.1
PC*	60% mod.	70% weak, 10% mod.	0	1.3
PC	0	0	0	1.7
PC	0	0	0	1.7
PC	0	15% weak	0	1.8
PC*	65% mod.	10% weak, 60% mod	80% weak	2
PC	80% mod.	50% weak, 10% mod.	80% weak	2.7

The two papillary carcinomas marked with '\*' had a lymphocytic infiltrate.

The staining intensity was categorised as weak, moderate (mod.) and intense.

## 5.4 Discussion

The exact molecular mechanisms involved in thyroid tumorigenesis remain unclear. Much work has been published regarding the members of the RAS/RAF/MAPK pathway, and we know that these genes are involved in both follicular and papillary thyroid carcinogenesis. However the alterations in the pathways controlling cellular proliferation and differentiation are less clear. I have investigated the expression of members of the Rb pathway, namely p16, p21, and cyclin D1, in all stages of thyroid tumorigenesis, and have so far been unable to provide a clear picture with regards to the events leading to uncontrolled cell proliferation in thyroid cancer. There appears to be a further, as yet unknown, pathway involved in the progression from adenoma to carcinoma, and from well-differentiated to poorly- and undifferentiated thyroid cancer.

This led us to perform Affymetrix microarrays on normal thyrocytes, early- and late-stage RAS-induced thyrocyte colonies, with the latter phenotypically resembling burnt-out thyroid adenomas in vivo. The resulting data revealed an unexpected up-regulation of interferon-stimulated genes in the late-stage RAS colonies, including the genes HLA-DR, PKR and MxA, and this was in the absence of interferon in the culture medium. I hypothesised therefore that these ISGs were in some way acting as a tumour suppressor mechanism, potentially in tandem with p16, in early thyroid tumorigenesis. We could not be certain, however, whether these genes were acting individually, or in the same pathway, and how many of the up-regulated genes were actually functional in initiating tumour development, as opposed to being a result of malignant progression.

My work is the first study to look collectively at the immunohistochemical expression of HLA-DR, PKR and MxA in thyroid tumours, specifically in follicular adenomas and follicular and papillary thyroid carcinomas. It is also the first body of work to compare the expression of these three ISGs with that of p16 in benign and well-differentiated thyroid tumours.

HLA-DR is a Molecular Histocompatibility Complex (MHC) antigen, and these are thought to regulate the immunologic interaction of immune cells and play a fundamental role in antigen recognition by helper T-lymphocytes. There are two classes of MHC antigens in humans, and HLA-DR belongs to class II. In humans, class II MHC genes are coded for by genes located in the HLA-D region on chromosome 6. This region can be further divided into three regions; HLADP, HLADQ, HLADR. Class II MHC antigens are commonly expressed on B-cells, T-cells, monocytes, macrophages, Langerhans cells of the skin, dendritic cells in lymph nodes and endothelial cells (Winchester and Kunkel, 1979; Kaufman et al., 1984). HLA-DR expression has been detected on epithelial cells in several benign and malignant tumours, although no clear prognostic significance has emerged.

HLA-DR was not expressed in the normal thyroid tissue that I studied. I also found that HLA-DR was generally not up-regulated in either the follicular adenomas or the follicular and papillary carcinomas. This was unexpected and the data is inconsistent with my original hypothesis, where HLA-DR was expressed in the late-stage RAS colonies which resemble follicular adenomas.

Interestingly, one of the follicular carcinomas had an isolated focus of intense HLA-DR expression in a small cluster of cells, which was persistent in serial sections. There was also a dramatic up-regulation of HLA-DR expression in three out of the seven papillary carcinomas, with 60-80% cells demonstrating a strong positive reaction. Two of these three papillary tumours had a lymphocytic infiltrate, suggesting that the induction of HLA-DR expression may in part be due to infiltration of lymphocytes into the tumour, although this cannot be the only mechanism involved, since a follicular and a papillary carcinoma also showed HLA-DR expression without such an infiltrate.

The data from the literature indicates that, like my findings, thyroid cells do not normally exhibit HLA-DR; however this protein can be induced in vitro by IFN gamma (Weetman et al., 1985). Panza et al., (1982), were the first group to report a strong association between HLADR and thyroid cancer. Lindhorst et al., (2002), studied HLA-DR expression in the complete spectrum of thyroid tumorigenesis, and found HLA-DR to be expressed on the cell membrane of both follicular and papillary cancer cells; however some anaplastic cancer cells had diffuse cytoplasmic staining. Follicular cancers have the weakest level of staining, followed by papillary cancers, and the aggressive, anaplastic cancers had the strongest degree of staining. The increase in HLA-DR expression correlated with an increase in proliferation in the poorly-differentiated tumours.

This in contrast to previous studies by Lloyd et al., (1985), Lucas-Martin et al., (1988), and Betterle et al., (1991), where only a low level of HLA-DR expression was seen in anaplastic carcinoma tissue sections. Lloyd's group also studied HLA-DR expression in follicular adenomas and follicular and

papillary carcinomas, and observed negligible levels of staining in the follicular adenomas and carcinomas, with an up-regulation in expression in the majority of papillary cancers.

Since then there have been several studies published with varying results concerning the correlation between HLA-DR expression and lymphocytic tumour infiltration. Lloyd et al., (1985), Kamma et al., (1998), and Knoll et al., (1992), performed immunohistochemistry on thyroid papillary carcinomas, and observed an up-regulation in HLA-DR expression when compared with normal tissue. This expression ranged from widespread staining, to scattered cells and concentrated small and large foci of positivity. These authors noted a close correlation between HLA-DR expression and a lymphocytic infiltrate.

Feinmesser et al., (1996), concluded that HLA-DR expression in papillary carcinomas was generally correlated with lymphocytic infiltration of the tumour, and that the intensity of HLA-DR expression was stronger in the tumours with distant metastases, compared to tumours that had not metastasised. However, there were a small number of cases, including some cases with distant metastases, which had HLA-DR expression without this infiltration of immune cells. There are several other studies that have confirmed that HLA-DR expression can occur in papillary carcinoma of the thyroid without the presence of a lymphocytic infiltrate (Goldsmith et al., 1988; Lucas-Martin et al., 1988; Fisfalen et al., 1990).

To summarise, the vast majority of studies have shown an up-regulation of HLA-DR expression in papillary carcinomas, and that for follicular adenomas



and carcinomas the expression of HLA-DR, when present, is weaker than that which is seen in papillary carcinomas. This corresponds with my own immunohistochemical data. There is some discordance regarding HLA-DR expression in anaplastic carcinomas, with some studies reporting an up-regulation and others reporting a loss of expression in these tumours. Secondly, the expression of HLA-DR in papillary thyroid carcinomas occurs both in the presence and absence of a lymphocytic infiltrate.

The expression of HLA-DR is often altered in human tumours when compared with the normal tissue from which the tumours originate. However the up-regulation of HLA-DR in tumours has been shown to have both a positive (Esteban et al., 1990) and a negative effect (Ruiter et al., 1986) effect with regard to prognosis. Rajendra et al., (2006), investigated HLA-DR expression in Barrett's oesophagus (a pre-malignant precursor lesion of oesophageal cancer) and found an up-regulation of HLA-DR expression in 51.6% of lesions when compared to 11.7% of normal control tissue. It was previously reported that this HLA-DR expression is down-regulated in the transition from adenoma to carcinoma, with only 16% tumours expressing HLA-DR (Rockett et al., 1995).

This down-regulation in tumours when compared with their corresponding pre-malignant lesions has also been noted in colon, cervical, laryngeal and breast carcinomas (Garrido et al., 1993). These results suggest that the induction of HLA-DR expression may confer an advantage to the host in terms of restricted tumour growth, and that HLA-DR is in part acting as a tumour suppressor. Normal colonic mucosa does not express HLA-DR; however de novo



expression has been reported in both colorectal adenomas and carcinomas. HLA-DR is also up-regulated in 38% colorectal adenomas, and its expression was correlated with increasing tumour size and the grade of dysplasia (Norheim Andersen et al., 1996). Patients with HLA-DR positive tumours have been shown to have a better survival than those patients without HLA-DR expression (Andersen et al., 1993), although this relationship has not been demonstrated by other studies (Ghosh et al., 1986; Moller et al., 1991). It has been demonstrated that some colon cancers that express multiple genetic mutations owing to DNA mismatch correction defects are highly immunogenic, as shown by a dense lymphocytic infiltrate (Kim et al., 1994), which may explain the favourable prognosis in this group of patients.

This relationship between HLA-DR expression and an improved survival in colorectal carcinoma was also reported by Lovig et al., (2002). An up-regulation of HLA-DR expression has also been seen exclusively in primary cervical carcinomas, and is absent in their corresponding metastases (Cromme et al., 1994). Overall, HLA-DR is up-regulated in several human carcinomas; however its role in tumorigenesis is still unclear. The expression of HLA-DR can be linked to an improved prognosis in colorectal, laryngeal and breast carcinoma (Brunner et al., 1991; Concha et al., 1991), whilst loss of expression can be associated with a worse prognosis or the presence of metastases in colorectal and cervical carcinoma and malignant melanoma (Lopez-Nevot et al., 1988).

PKR is a double-stranded RNA-activated protein kinase that is induced by interferons (Lengyel, 1982; Hovanessian, 1989). PKR is activated by binding

to double-stranded RNA (Galabru et al., 1989). Once activated, PKR phosphorylates eukaryotic initiation factor 2- $\alpha$  (eIF2- $\alpha$ ), a subunit of translation initiation factor 2. The eIF2- $\alpha$  then down-regulates cellular or viral translations of proteins (Lengyel, 1982). Furthermore PKR also induces apoptosis and suppresses cellular growth, differentiation and proliferation (Meurs et al., 1993; Yeung et al., 1996; Williams, 1999), and has a role to play in controlling the activation of several transcription factors such as p53. PKR may therefore have a role as a tumour suppressor gene (Jagus et al., 1999).

PKR was not expressed in the normal thyroid tissue that I studied. I observed an up-regulation of PKR expression in two out of the ten follicular adenomas that were stained, with 75-80% cells showing a positive reaction. This is partly consistent with my hypothesis that ISGs are up-regulated in vivo in follicular adenomas. Only one out of seven follicular carcinomas showed an up-regulation of PKR expression with 35% cells showing a positive result, and this was a down-regulation when compared with the two follicular adenomas that expressed PKR. It is difficult to draw accurate conclusions regarding whether the reduced expression in the one positively staining follicular carcinoma is a true down-regulation in staining intensity compared to the two follicular adenomas, and a much larger series of thyroid tumours would have to be immunostained to investigate whether PKR has a potential role as a tumour suppressor gene in early thyroid tumorigenesis.

PKR was also expressed in four out of the seven papillary carcinomas, and there was a down-regulation in the intensity of staining when compared to the adenomas. Two of the cancers that expressed PKR had a lymphocytic

infiltrate. Most of the positively staining papillary carcinoma cells had a weak intensity of staining, in comparison to the moderate intensity of staining seen in the follicular adenomas. This lends further evidence to the hypothesis that PKR may act as a tumour suppressor in thyroid tumorigenesis.

To date there has only been one published study researching the expression of PKR in thyroid cancer. Terada et al., (2000), analysed 80 papillary carcinomas and two follicular carcinomas. Like my own data, PKR was not expressed in normal thyroid tissue. However, 94% of the papillary carcinomas were positive for PKR expression, and this was predominantly localised in the cytoplasm of the tumour cells and at the peripheral invading front. Only one of the two follicular cancers showed PKR expression, and this was of a weaker intensity than that seen in the papillary tumours. The up-regulation in PKR expression was correlated with those tumours that had a greater degree of vascular invasion. Finally, the tumours with the highest PKR scores had the lowest proliferative rates, as judged by Ki-67 expression. This inverse correlation with proliferation has also been reported in head and neck carcinoma (Haines et al., 1996). The up-regulation of PKR expression seen in this series of papillary carcinomas, and the increase in staining intensity seen in the papillary carcinomas compared to the follicular carcinomas is consistent with my own data.

Elevated levels of PKR expression have been demonstrated in several human cancers, including breast (Haines et al., 1996), colon (Singh et al., 1995), lung (Haines et al., 1992), head and neck (Haines et al., 1993) and hepatocellular carcinomas (Shimada et al., 1998), as well as in the cell lines derived from

these tumours (Haines et al., 1996; Kim et al., 2000; Kim et al., 2002). Kim's group (2002) demonstrated that there is an increase in PKR expression which is consistent with the transition from a colorectal adenoma to a carcinoma, and this is similar to my own findings in thyroid tumorigenesis.

However the role of PKR in tumorigenesis varies according to the individual cancer. Increased expression of PKR has been correlated with a better prognosis in head and neck carcinoma and some studies analysing colorectal carcinomas (Haines et al., 1993; Singh et al., 1995). In contrast, Terada et al., (2000), as previously stated, reported that high PKR expression correlated with vascular invasion and satellite tumour nodules in thyroid cancer. Kim et al., (2002) also stated that the lymph node metastases from malignant melanomas had high levels of PKR expression.

These varying results are similar to the data regarding the significance of HLA-DR expression in human malignancies. At present, it is still unclear whether PKR is acting as a tumour suppressor gene in some carcinomas, or as a cellular response to neoplasia or it may act via an as yet undisclosed pathway. The analysis of PKR expression in poorly-differentiated and anaplastic thyroid carcinomas will help elucidate the role of PKR expression in thyroid tumorigenesis.

MxA is a 78kDa protein that belongs to the super-family of dynamin-like GTPases (Flohr et al., 1999), and they are key components of the anti-viral state that is induced in many species such as rodents and humans by the expression of type I interferons (Haller and Kochs, 2002). The Mx proteins

were first discovered over twenty years ago in an inbred mouse strain that showed a high degree of resistance towards a particular influenza virus (Horisberger et al., 1983). In humans, two distinct MxA GTPases, MxA and MxB are encoded on chromosome 21. Only MxA has anti-viral activity, and this is against a wide spectrum of viruses including bunyaviruses, orthomyxoviruses and hepatitis B virus. The MxA proteins can self-assemble into oligomeric complexes and they bind to viral nucleocapsids and block their intracellular transport (Haller and Kochs, 2002), and it has been suggested that these proteins function as an intra-cellular surveillance system to monitor the cell for viral infection. MxA is now widely accepted as a sensitive marker of interferon  $\alpha$  /  $\beta$  activity (Roers et al., 1994).

The expression of MxA was negligible in the vast majority of all the thyroid tumours studied. There was no expression of MxA protein in either normal thyroid tissue or in the follicular adenomas. This was unexpected, and was not consistent with my earlier hypothesis. Seven out of the eight follicular carcinomas did not express MxA protein; however one case had a small cluster of cells with an intense focus of positive staining. This same case had an intense focus of HLA-DR expressing cells in the same location. Because both MxA and HLA-DR expression were induced in this cluster of cells, it is highly unlikely that this is an artefact of immunohistochemical processing, and represents a true induction of ISG expression.

Five out of the seven papillary cancers that were immunostained did not express MxA protein. However the remaining two cancers demonstrated weak staining in 80% cells and one of these tumours had a lymphocytic infiltrate.

This data suggests that MxA has a minimal role to play in early thyroid tumorigenesis, since it is not expressed in the majority of thyroid adenomas and well-differentiated carcinomas.

There is very little published data regarding MxA immunohistochemistry, and the majority of papers concern its up-regulation in viral-induced diseases such as hepatitis (Leifeld et al., 2001). To date there are no published studies regarding MxA expression in human cancers. My study is therefore the first to investigate the immunohistochemical expression of MxA in thyroid tumorigenesis.

One potential source of bias in this study was the fact that I was not blinded to the pathological diagnosis of the tissue specimens prior to performing immunohistochemistry. Also, I only had access to a relatively small number of cases for each tumour group. Because the numbers of positively-staining cases were so low for each tumour group, a much larger number of samples need to be stained to be able to draw more accurate conclusions. There is very little information in the literature regarding the immunohistochemical expression of PKR and MxA in human cancers, and therefore there is little data regarding the ideal immunohistochemical protocols and scoring methods for these antibodies.

There was no obvious correlation between p16 expression and HLA-DR, PKR and MxA expression in the follicular adenomas and follicular carcinomas, since the ISGs were not expressed in the majority of these tumours. However, the increase in ISG expression observed in two of the three papillary carcinomas

that expressed all three proteins did appear to be linked to an increase in p16 expression, with these two cases having the two highest p16 I.D. values. One explanation for the up-regulation of ISGs in vivo in papillary carcinomas may be related to the genetic mutations and rearrangements that are only found in these cancers, such as RET/PTC rearrangements and the BRAF mutation.

These genetic changes may somehow be linked to the interferon pathway, and the de novo expression of interferons may have a specific role to play in papillary thyroid tumorigenesis. If this is the case, then this could be an explanation for the intense cluster of positively staining cells seen in one follicular carcinoma. If these cells harboured a genetic mutation more commonly seen in papillary cancers, such as a RET/PTC rearrangement, then they would be expected to express HLA-DR, PKR and MxA. However, PKR was not expressed in this cluster of cells, and so the function of these ISGs in thyroid tumorigenesis remains unclear.

The relationship between HLA-DR expression in papillary cancers and the presence of a lymphocytic infiltrate is unclear. One theory is that HLA-DR expression is a result of paracrine stimulation by cytokines derived from the infiltrating lymphocytes, dendritic cells and other inflammatory cells (Ikeda et al., 2002), although several authors have failed to demonstrate a convincing spatial relationship (Betterle et al., 1991; Feinmesser et al., 2000), and our in vitro data confirms that HLA-DR is up-regulated in the absence of interferon in the culture medium. HLA-DR expression can occur in the absence of lymphocytes, as seen in distant metastases, which suggests that the expression of HLA-DR may be related to a gene associated with the

development of metastases. This is unlikely to be the case in thyroid carcinoma, since follicular carcinomas are able to metastasise but have negligible HLA-DR expression.

It has been recently reported that the rearranged RET/PTC oncogene can induce the expression of MHC Class II molecules through a STAT-1 (signal transducer and activator of transcription-1) mediated mechanism (Hwang et al., 2004). Potentially this induction of cytokines by the thyroid tumour cells could promote the lymphocytic infiltration seen in papillary thyroid carcinomas. These infiltrating lymphocytic immune cells may have a role in tumour suppression by expressing co-stimulatory molecules that are not normally expressed by thyroid cells, and therefore activating the immune response (Lahat et al., 1993). On the other hand, the lymphocytes may produce mediators that can enhance tumour growth via a paracrine effect (Marx, 2004). However, HLA-DR, PKR and MxA expression were also up-regulated in papillary carcinomas that did not have a lymphocytic infiltrate; therefore there must be another mechanism involved.

One theory for the differences between our thyrocyte model's expression of ISGs and my *in vivo* findings is that the ISGs are stimulated *in vitro* as a delayed response to RAS oncogene activation in these thyrocyte colonies. This is unlikely because the papillary carcinomas are the tumour group that show the greatest up-regulation of ISGs, whilst the follicular carcinomas have a much greater prevalence of RAS mutation and a very low incidence of ISG up-regulation. Another possibility that must be considered is that our thyrocyte tumour model is not a completely accurate representation of the *in vivo*



development of thyroid tumours. However, the concurrent up-regulation of both p16 and cyclin D1 in both late-stage Ras colonies and in human follicular adenomas indicates that the in vitro model must bear some similarities to the in vivo neoplastic progression. Finally, as previously discussed, the up-regulation of both HLA-DR and PKR has been reported in follicular and papillary carcinomas, implying that these genes do have a role to play in thyroid tumorigenesis.

The process of malignant transformation is complex, and involves both epigenetic and genetic changes in an individual cell, as well as changes in the way that cell interacts with its environment. The immune system is increasingly thought to have a role to play in this process. Frequently, tumour cells express new 'neo-antigens' as a result of these multiple genetic changes (Little and Stern, 1999). The immunological recognition of these neo-antigens is a key event in tumorigenesis (Scanlan et al., 1998). The host's immune cells can potentially recognise these antigens if they are presented by HLA molecules, and therefore HLA molecules may have a crucial regulatory role in the neoplastic immune response.

The interferons and ISGs produced in response to neoplasia within a tissue may elicit anti-tumour effects by affecting tumour cellular proliferation or differentiation, and the development of resistance to the effects of interferon may be an important reason for the failure of interferon therapy in malignant disease (Chawla-Sarkar et al., 2003). The de novo increase in expression of MHC class I and II molecules, as seen in many human malignancies, will enhance the immunogenicity of a tumour cell and render it more detectable by

the host's immune system. However, interferons may have a more indirect effect on tumour suppression by affecting the modulation of the immune system in response to neoplasia, or by inhibiting angiogenesis of a tumour. Interferons are now well accepted as apoptosis-inducing cytokines, although the exact pathways through which apoptosis is achieved are still uncertain.

A tumour can potentially evade the immune responses triggered by these neo-antigens in several ways. This can be done by the physical exclusion of immune cells from the growing tumour, the natural disruption of immune cells in response to tumorigenesis, or a reduction in a tumour's immunogenicity, either by cells that interfere with antigen-presenting cells, or by blocking the production of cytokines needed to instigate the immune response. The involvement of the immune system in the neoplastic process is complex. A host's immune system not only protects it against the development of a tumour, but can also select for tumours with a low immunogenicity and therefore promote tumour growth. Recently, Dunn et al., (2004), developed an "immunosurveillance hypothesis of immunoediting". They envisaged that there are "three phases that are collectively denoted the three Es of cancer immunoediting: elimination, equilibrium and escape".

The elimination phase represents the initiation of the immune response when immune cells recognise a growing tumour, and Dunn suggests that this occurs only after a tumour cell has by-passed its own tumour-suppressor mechanisms. A tumour is recognised on the basis of a disruption in the tissue stroma, either by invasion or angiogenesis, two of the hallmarks of neoplasia

stipulated by Hanahan and Weinberg (2000). If this phase is successful, the body will successfully eradicate the developing tumour.

If the elimination phase is unsuccessful, then a dynamic equilibrium occurs. Lymphocytes and cytokines continue to exert a selection pressure on tumour cells but this is not strong enough to destroy the cell population, although many of the original malignant cells are destroyed. At the same time, it is proposed that new clones of tumour cells are produced with new mutations conferring increased resistance to the immune attack, and therefore a lower immunogenicity than the original tumour population.

Finally, because of their lower immunogenicity, the new tumour clones escape the immune response and the tumour can continue to grow, invade and metastasise. They suggest that this only occurs when a tumour cell acquires genetic and epigenetic changes which provide the cell with the capability to resist detection, and subsequently undergo apoptosis, by the immune system. This process of immunoediting has been put forward as the “seventh “hallmark of cancer”: the capacity of a malignant cell to evade the extrinsic tumour suppressor functions of the immune system” (Dunn et al., 2004).

Our Affymetrix results demonstrated that there was an up-regulation of interferon-stimulated genes in late-stage RAS colonies, which resemble *in vivo* follicular adenomas, and this would appear to tie in with Dunn’s hypothesis of immunoediting in neoplasia. *In vivo*, the ISGS were not expressed in the follicular adenomas and follicular carcinomas, and were only up-regulated in the papillary carcinomas. Follicular adenomas are benign, non-invasive tumours that are unable to overcome innate cell-intrinsic tumour suppressor

mechanisms, hence avoiding the need for the extrinsic immune system to come into play. However, follicular carcinomas are able to invade and metastasise, and these tumours did not appear to have a de novo expression of ISGs. It may be that papillary carcinomas have a higher expression of ISGs because they commonly have an associated lymphocytic infiltrate, and this may be a function of the immunoediting process, although it has been demonstrated that HLA-DR expression can occur in papillary carcinomas without the presence of this lymphocytic infiltrate.

The picture is still unclear with regards to the exact function of HLA-DR, PKR and MxA expression in thyroid cancer. The reduction in PKR staining intensity seen in the papillary carcinomas compared to the follicular adenomas suggests that PKR may act as a tumour suppressor gene in papillary thyroid tumorigenesis. Overall these genes may have a critical role to play in tumorigenesis itself, although at a later stage than was first predicted from our in vitro work, or their expression may simply be a response to the malignant transformation process.

## **5.5 Conclusions**

- HLA-DR protein was not expressed in normal thyroid tissue or follicular adenomas, was minimally expressed in follicular carcinomas, and was up-regulated in 43% papillary carcinomas in cancers both with and without a lymphocytic infiltrate.
- PKR protein is not expressed in normal thyroid tissue. It was up-regulated in 20% follicular adenomas, 12.5% follicular carcinomas and 57% papillary carcinomas, although there was a decrease in staining intensity in the cancers compared to the adenomas. PKR was strongly expressed in papillary cancers both with and without lymphocytic infiltration.
- MxA protein is not expressed in normal thyroid tissue or in follicular adenomas, and is minimally expressed in follicular carcinomas. An up-regulation of expression was only seen in two (29%) papillary carcinomas, one of which had a lymphocytic infiltrate.
- One follicular carcinoma had a small cluster of cells that showed intense staining of HLA-DR and MxA, but not PKR. This may represent a de novo mutation in the RAF/RET/MAPK pathway, normally seen in papillary cancers, which induced the expression of these genes.
- The absence of expression of all three proteins in the follicular adenomas was not in keeping with our original hypothesis, and the up-regulation of expression at the carcinoma stage suggests that HLA-DR, PKR and MxA may not purely act as tumour suppressors in thyroid tumorigenesis.

## **5.6 Further work**

To provide further data regarding the potential function of these three genes in thyroid tumorigenesis, and to investigate the role of PKR as a tumour suppressor gene, the immunohistochemical expression of these genes needs to be analysed in poorly-differentiated papillary, insular and anaplastic carcinomas. Larger numbers of cases for each tumour group are also needed to be able to draw more accurate conclusions.

Long-term clinical follow-up of the patients from whom the tissue was taken will enable us to correlate the expression of HLA-DR, PKR and MxA with the incidence of metastases and survival times, and to speculate whether any of these genes are potential markers of malignant or aggressive tumour behaviour.

Investigation of the expression of HLA-DR, PKR and MxA expression, together with proteins involved in both the Rb and RAF/RET/MAPK pathway in the selected follicular and papillary carcinomas, will provide data that may link these pathways in thyroid tumorigenesis, and may provide answers for the differences in expression of ISGs in follicular and papillary carcinomas.

## CHAPTER 6

### OVERALL CONCLUSIONS

Thyroid carcinoma, as previously discussed in chapter 1, is the commonest endocrine malignancy and the disease accounts for 300 deaths per year (Mallick *et al.*, 2000). The initiating events involved in both follicular and papillary thyroid carcinogenesis have been widely reviewed in the literature; however, the pathways involved in the subsequent malignant transformation from follicular adenoma to follicular, insular and anaplastic carcinoma, and from papillary carcinoma to poorly-differentiated papillary and anaplastic carcinoma are less clearly understood.

*In vitro*, normal human thyroid follicular cells have a very low proliferative rate, and this is dramatically increased *in vitro* by RAS oncogene activation, which results in thyrocytes clones that display a phenotype consistent with that of a follicular adenoma *in vivo*. The eventual cessation of growth of these colonies is closely correlated with the increasing expression of the tumour suppressor gene p16<sup>INK4A</sup>, suggesting that p16 may have a role to play in limiting clonal expansion in this tumour model. The observed up-regulation of p16 expression *in vitro* in our thyrocyte tumour model led us to hypothesise that p16 expression would be up-regulated *in vivo* in follicular adenomas, and would subsequently be down-regulated or absent in follicular and papillary carcinomas, in accordance with their malignant phenotype and ability to invade and metastasise to local and distant tissues.

I tested this hypothesis using immunohistochemistry, and produced novel research regarding p16 protein expression in benign thyroid adenomas and well-, poorly- and undifferentiated thyroid carcinomas. The second original aspect of this work was the correlation of p16 expression with that of MCM2 and cyclin A expression (two markers of cellular proliferation).

Although p16 expression was induced in follicular adenomas, there was a further increase in both staining intensity and the percentage of positively staining cells in both follicular and papillary carcinomas. This was surprising and unexpected, and was not consistent with my hypothesis. One explanation for the continued expression of p16 in well-differentiated thyroid carcinomas is that these cancers are relatively indolent and slow-growing, and therefore because they are not rapidly proliferating, the loss of p16-regulated cell cycle control is relatively unimportant in this stage of thyroid tumorigenesis. My data is also consistent with the few studies reported in the literature that have analysed p16 expression in thyroid tumours, as described in chapter 3.

Unfortunately it is impossible to follow the development of a well-differentiated carcinoma *in vivo*, since thyroid tumours are surgically excised to treat the patient. Pathologists have drawn conclusions regarding the natural progression of thyroid cancers from the histology of poorly-differentiated thyroid cancers that have areas of a well-differentiated tumour adjacent to the more aggressive tumour. The incidence of these aggressive anaplastic tumours is much lower than that of the well-differentiated follicular and papillary tumours. The rarity of anaplastic transformation seen in thyroid cancer is



consistent with the hypothesis that there are multiple pathways that need to be overcome, and that all pathways need to be affected before a tumour gains a selection advantage.

Thyroid tumours are generally slow-growing; my data regarding the expression of cyclin A, a marker of the S phase of the cell cycle, confirms this. This protein was expressed at very low levels (2-6% positively staining cells per tumour) in the follicular adenomas, and the follicular and papillary carcinomas. I only detected an increase in cyclin A expression in the insular carcinomas, and cyclin A was expressed at these high levels in insular carcinomas that were both positive and negative for p16 expression. This suggests that those poorly-differentiated tumours that continue to express p16 may somehow be bypassing the negative regulation of the cell cycle, to allow for an increase in the proliferative rate of the cancer. One mechanism for this would be a mutation in the Rb pathway downstream from p16, such that p16 would no longer have a tumour suppressor effect. Alternatively a newly acquired mutation, such as a p53 mutation, could mean that loss of p16 expression no longer confers a selective advantage on the cell.

If, as has been suggested by my data, the loss of p16 expression is not important for early thyroid tumorigenesis, and the majority of follicular adenomas, follicular and papillary carcinomas continue to express p16 protein, why does an insular or anaplastic thyroid cancer suppress p16 expression? What selective advantage does it give to these tumours? If p16 is no longer

functional because of a downstream mutation, it would be of no further advantage to the cell to stop expressing p16, because these tumours would already be capable of achieving uncontrolled proliferation. Mutations in Rb, the key downstream effector of p16, however, are rare in thyroid cancer, implicating that this is not the primary reason for the increase in proliferation seen in p16-expressing poorly-differentiated tumours.

Well-differentiated follicular and papillary carcinomas are therefore able to proliferate and metastasise, albeit at a low rate, despite the expression of p16, and the expression of p16 in these tumours reaches a level sufficient to severely limit, but not to totally block oncogene-induced proliferation. In a few cases, p16 expression is lost, and these tumours show a more rapid and aggressive pattern of tumour growth, as reported in the insular and anaplastic carcinomas. If p16 was the only rate-limiting step involved in the transformation from a well-differentiated to a poorly-differentiated tumour, I would expect the incidence of these tumours to be much higher than that reported in the literature. Furthermore, loss of p16 expression occurs at a very high frequency in many human malignancies and there should therefore be a strong selection pressure for this to occur in thyroid tumorigenesis. We propose that there is a second pathway that is also involved in cell cycle control, which may function independently of the Rb pathway, and that both pathways need to be altered prior to uncontrolled proliferation and the development of a more aggressive thyroid tumour.

The results from my immunohistochemical analysis of p16 expression in thyroid tumorigenesis were unexpected, and the role of p16 and the Rb pathway in early thyroid tumorigenesis is not straightforward. This led me to further investigate the role of the Rb pathway in early thyroid tumorigenesis through the immunohistochemical expression of the oncogene cyclin D1 and the tumour suppressor gene p21. I correlated the expression of these two proteins with that of p16 in follicular adenomas, and follicular and papillary carcinomas, to produce original research that would further our understanding of the Rb pathway and cell cycle control in early thyroid tumorigenesis.

There are several studies that have analysed both cyclin D1 and p21 expression in thyroid cancers, as previously described in chapter 4. I demonstrated an up-regulation of cyclin D1 expression in the follicular adenomas, and there was a further up-regulation of this protein in both the follicular and papillary carcinomas, consistent with the oncogenic function of cyclin D1, and the data in the literature. I observed a positive correlation between cyclin D1 and p16 expression in all three tumour groups, and this was statistically significant in the papillary carcinoma group.

The follicular adenoma group only showed a minimal up-regulation of p21 expression, with 90% of the tumours only having 0-3% positively staining cells. I did demonstrate a small increase in p21 expression in the follicular and papillary carcinoma groups, although 25-50% of the cancers did not express p21. The induction of p21 expression was not significantly correlated with p16 expression. These results are also compatible with those stated in the

literature. The expression of p21 therefore does not appear to have a major role to play in early thyroid tumorigenesis.

Taken together, the novel data from chapters 3 and 4 still indicates that there is a second pathway that is involved in early thyroid tumorigenesis and cell cycle control. Affymetrix microarrays were performed on our late-stage RAS-induced thyrocyte colonies to search for potential candidate genes involved in such a pathway. This data produced some surprising results. Together with p16, there was a significant up-regulation of the interferon-stimulated genes in these cells, such as HLA-DR, PKR and MxA. I performed original research to investigate the immunohistochemical expression of these three proteins in follicular adenomas and follicular and papillary carcinomas, and correlated this data with the expression of p16 in the same tumours. I hypothesised that all three genes would be up-regulated in the follicular adenomas, in keeping with the *in vitro* results.

However, my results did not correlate with the *in vivo* findings and therefore my hypothesis. Neither HLA-DR nor MxA were expressed in the follicular adenomas, and PKR was only expressed in 20% of these tumours. This was unexpected. There was obviously no correlation between p16 and ISG expression in the adenomas, because the ISGs were as a whole not expressed in this tumour group. Similar results were also seen in the follicular carcinomas, with the majority of tumours not showing ISG expression. One isolated cancer had a small cluster of cells which showed intense staining for

both HLA-DR and MxA, but not PKR, and this case had the highest p16 I.D. score in the group.

An up-regulation of all three ISGs was demonstrated in three out of the seven papillary carcinomas, and two of these cancers had an associated lymphocytic infiltrate. The two papillary cancers with the highest p16 I.D. scores were included in the sub-group with the up-regulation of ISG expression. This novel data suggests that although the lymphocytic infiltrate commonly seen in papillary cancers may be one mechanism for the induction of ISG expression, it cannot be the only mechanism, since HLA-DR, MxA and PKR were expressed in a papillary carcinoma and a follicular carcinoma that did not have a lymphocytic infiltration. There may also be a positive correlation between the induction of p16 and ISG expression in papillary carcinomas. I also observed a reduction in PKR staining intensity in the papillary carcinomas compared to the follicular adenomas, and together this suggests that PKR may have a role to play as a tumour suppressor in thyroid tumorigenesis, although greater numbers of both adenomas and carcinomas need to be stained to provide convincing evidence for this theory. At present, the exact nature of the relationship between HLA-DR, PKR, MxA and p16 expression remains unclear.

One theory for the *in vitro* up-regulation of ISG expression is that it is a delayed response to the introduction of RAS and subsequent RAS activation into normal human thyrocytes. However this cannot be true, because of the

absence of expression of the ISGs *in vivo* in follicular adenomas, and the high frequency of RAS mutations *in vivo* in follicular adenomas, follicular and papillary carcinomas. Therefore, either the *in vitro* ISG expression must be a consequence of another initiating event in thyroid tumorigenesis, or further mutations in the RAS/RAF/MAPK pathway are needed *in vivo* before these proteins are expressed.

I observed that ISG expression was more commonly seen in the papillary cancers and therefore their up-regulation could be related to mutations of either RET, BRAF or MET, which are specific to papillary carcinomas, and the ISGs may somehow function via the RET/RAF/MAPK pathway. Consequently, the intense focus of ISG-expressing cells in one particular follicular cancer might represent a sub-clone of cells that has selective advantage, and could therefore transform into a more aggressive phenotype. The clusters of cells that expressed HLA-DR and MxA might have developed a mutation of either RET, MET or BRAF, which are more commonly seen in papillary cancer, as part of the de-differentiation process. The role of MET expression in papillary thyroid tumorigenesis has been previously discussed in chapter 1. RAS mutations and RET/PTC rearrangements lead to an up-regulation of MET expression in papillary cancers, and this has been shown to recruit inflammatory cells to the cancer through the release of cytokines, and has been correlated with a poor clinical prognosis in some tumours. The recruitment of inflammatory cells to produce a lymphocytic infiltrate in these papillary cancers may partly explain the induction of ISGs in these tumours,

although it cannot be the only mechanism since the ISGs are also expressed in the absence of a lymphocytic infiltrate.

Alternatively, as discussed in chapter 5, the expression of ISGs *in vivo* could be the result of cancer immunoediting and the body's innate responses to tumorigenesis, with the *in vitro* results being an artefact of tissue culture. However, several studies have demonstrated that ISGs do have a role to play in tumorigenesis, including thyroid tumorigenesis, although this role as yet is unclear.

One of the major problems involved in research involving thyroid cancer is the relatively small number of tumours that are surgically excised each year, in comparison to colorectal carcinoma, for example. Furthermore, the incidence of the poorly-differentiated anaplastic thyroid cancers is very low in comparison to the well-differentiated thyroid cancers, and therefore it is difficult to get access to large numbers of these tumours. This means that the majority of papers in the literature, including my own, are analysing small numbers of tumours, and therefore caution has to be taken when drawing conclusions. One mechanism for increasing the number of cases that are available for research is a multi-centre study; however this would increase the potential sources of bias, with different techniques used for tissue fixation, slide processing, for example.

In summary, I have produced original research demonstrating that p16 is expressed in early thyroid tumorigenesis, and that it continues to be expressed at a higher level in well-differentiated thyroid tumours. Furthermore, p16 expression is only down-regulated or lost in a sub-group of papillary cancers, and in the poorly-differentiated insular and anaplastic carcinomas. I also demonstrated that the increase in p16 expression seen in the follicular and papillary carcinomas was statistically correlated with an increase in cyclin D1 expression, and that p21 has a minimal role to play in thyroid tumorigenesis. In contrast to the Affymetrix data from late-stage RAS-induced thyrocytes colonies, ISGS were not up-regulated in the majority of follicular adenomas, and there was therefore no correlation between the expression of these genes and p16 protein. However, HLA-DR, PKR and MxA were up-regulated in the papillary carcinomas, in cancers that either did or did not have a lymphocytic infiltrate. Finally, PKR expression seemed to be positively correlated with an increase in p16 expression, suggesting that PKR may be partially acting as a tumour suppressor in early thyroid tumorigenesis.

So far I have demonstrated that the loss of p16 is a late event in the malignant transformation of thyroid cancer from an indolent to a highly aggressive tumour, in that this phenomenon is only seen in insular and anaplastic thyroid carcinomas. The up-regulation or down-regulation of interferon-stimulated genes such as HLA-DR, PKR and MxA may have a role to play a role in this neoplastic process, through cancer immunoediting, but there still appears to be other pathways involved.



Thyroid cancer as a whole is unique because both histologically and biologically diverse tumours are derived from a single follicular thyroid cell of monoclonal origin (Moniz *et al.*, 2002). It has been suggested that these originating follicular cells behave similarly to stem cells, in that they can self-renew and give rise to phenotypically-differing daughter cells (Zhang *et al.*, 2006). Stem cells have been identified in breast, pancreatic, lung and prostate carcinomas and there is evidence to support the theory that the ability of a tumour to grow and divide resides in a small population of 'cancer stem cells', which are responsible for the original tumour initiation (Bonnet and Dick, 1997; Pardal *et al.*, 2003; Hope *et al.*, 2004; Wicha *et al.*, 2006). Thyroid cancer stem cells may develop *de novo* during foetal development, or may be formed from mature thyrocytes as part of the de-differentiation process involved in tumorigenesis; in which case a benign tumour would only become malignant if the lesion were able to produce cancer stem cells to ensure continued proliferation and de-differentiation.

Evidence to suggest that the thyroid gland may contain stem cells comes from studies of embryological thyroid remnants. The thyroid gland is the first endocrine gland to form in a foetus, and persistence of parts of the ultimobranchial body, as either thyroglossal cysts or lingual thyroids are common in adults, and these are thought to contain stem cells (Beckner *et al.*, 1990; Zelmanovitz *et al.*, 2004). The thyroid gland is thought to have three different types of stem cells, which are responsible for the regeneration of thyroid follicles during adult life (Zhang *et al.*, 2006). The three groups proposed are follicular progenitor stem cells derived from endoderm, C-cell

progenitor stem cells derived from neural crest tissue, and a bi-potential precursor of both follicular cells and C-cells. However, these three different groups may simply represent stem cell differentiation during adult life.

Zhang *et al.*, (2006) proposed that cancer stem cells continue to slowly divide and are kept in check by normal proliferation pathways, just like normal thyroid follicular cells. However, if these pathways become altered by genetic damage, then the cells would form a neoplastic lesion. Sell *et al.*, (2004), proposed that the developmental stage at which the stem cell is transformed will dictate the degree of differentiation of the resulting tumour, thus explaining the diversity of thyroid carcinomas. Furthermore, not only does the genetic damage need to accumulate in the necessary pathways involved in thyroid tumorigenesis, these changes need to occur in the cancer stem cells in order to begin the malignant transformation.

If thyroid cancers are derived from a minute stem cell population which can give rise to either follicular or papillary tumours, the genetic analysis of such tumours would give rise to artificial results, since the research would reflect the entire tumour, and not the small (1-2%) number of cancer stem cells in the tumour (Nuciforo and Fraggetta, 2004). This may explain why we do not yet have a clear understanding of the genetic pathways involved in the development of undifferentiated thyroid carcinomas.

An alternative theory for the transformation of a thyroid cancer from a well-differentiated to a poorly-differentiated phenotype is epithelial-to-mesenchymal transition (EMT). This phenomenon involves the “formation of mesenchymal cells from epithelia in different embryonic territories” (Thiery, 2003). The resulting cells lose their cell-to-cell contact, and develop a phenotype capable of migration and metastasis, which has been implicated in the early stages of tumorigenesis (Thiery and Sleeman, 2006).

One of the landmarks of tumorigenesis is tumour invasion and metastasis (Hanahan and Weinberg, 2000), and de-differentiation of epithelial cells is crucial for this to take place. There is now an accumulation of indirect evidence to suggest that EMT occurs in primary cancers (Thiery, 2002). Also, the presence of micro-metastatic tumour cells in bone marrow and lymph nodes also suggests a role for EMT in cancer progression, and the presence of these cells has been associated with a bad prognosis (Pierga *et al.*, 2003). However, are the mesenchymal cells the end result of de-differentiation, or are separate genetic pathways involved to create the mesenchymal transition process?

Alternatively, both cancer stem cells and EMT may have a role to play in thyroid tumorigenesis. Wynford-Thomas and Blaydes (1998) hypothesised that the nature of the tumour-initiating cell pre-determined the liability of that cell to develop a p53 mutation, and the extent to which that p53 mutation would control the proliferative lifespan of the cell. This would relate to different

stages of differentiation in cancer stem cells in the thyroid gland, which would then be affected by a p53 mutation in varying ways, and hence develop different phenotypes of thyroid cancer.

Work in our laboratory has identified a sub-population of thyrocytes present in human thyroid tissue culture that express the thyroid-specific transcription factor PAX8 and yet show a mesenchymal morphology and a dissociated pattern of growth. These changes are accompanied by a massive increase in cellular proliferation (Bond *et al.*, 1993). The frequency with which this event occurred was so high that it almost certainly had to be an epigenetic event rather than a genetic mutation. This data suggests that thyrocytes are capable of a spontaneous switch in differentiation to a mesenchymal phenotype.

The activation of the RAS/MAPK pathway has been shown to be important in the development of EMT (Janda *et al.*, 2002; Huber *et al.*, 2005). If EMT is involved in tumorigenesis, thyroid cancer would be an ideal candidate because of the frequency of genetic alterations in the RAS/RAF/MAPK pathway. Vasko and Saji, (2007), performed micro-arrays on widely invasive thyroid papillary carcinoma and poorly-differentiated papillary carcinoma cell lines, and demonstrated that the invasion of papillary cancer is associated with EMT through the over-expression of vimentin protein, which is critically involved in EMT regulation (Shook and Keller, 2003).

Differentiation switches are common in human neoplasia, and have been pathologically described as metaplasia, trans-differentiation and de-differentiation (Birchmeier and Behrens, 1994; Portella *et al.*, 1994). The thyrocyte model suggests that a cell can side-step cell-cycle control providing that both the pRb and p53 pathways have been abrogated, and begin to proliferate at an increased rate. Loss of differentiation is a key feature of anaplastic thyroid carcinoma, and is accompanied by a more aggressive behaviour and a worse prognosis, contrasting with the well-differentiated follicular and papillary cancers that have an excellent prognosis. The rare occurrence of these anaplastic cancers suggests that a thyroid tumour needs both a p53 mutation and a differentiation switch (EMT) before it acquires a selective advantage (Wynford-Thomas, 1993a).

I have produced original research investigating some of the molecular mechanisms involved in thyroid tumorigenesis. I have demonstrated that p16 expression is induced *in vivo* in follicular adenomas, consistent with my original hypothesis developed from the expression of p16 in our thyrocyte tumour model. However, because p16 expression is still up-regulated in follicular and papillary carcinomas, and is only reduced in the more aggressive insular and anaplastic carcinomas, there must be another pathway involved in the malignant transformation. Furthermore, it is only when a cell has lost the function of both the Rb and this second, as yet unknown pathway that it is able to develop into a more aggressive phenotype with a worse clinical prognosis. The expression of p16 is therefore not a good molecular marker to help pathologists differentiate between follicular adenomas and carcinomas.

However, loss of p16 expression may be a useful indicator of a worse clinical prognosis, although a much larger study with long-term clinical follow-up is needed to investigate this further.

Secondly, the expression of cyclin D1 is at all stages of thyroid tumorigenesis, and this is positively correlated with p16 expression in these cancers, and this is in keeping with the oncogenic activity of cyclin D1. When coupled with the tumour suppressive effects of p16 expression, these two genes may be acting to keep the thyroid tumour cell 'in check' until the proposed second pathway is altered, prior to the transformation of the tumour to a more malignant phenotype. The tumour suppressor gene p21 does not have a major role to play in thyroid tumorigenesis, and its expression is not significantly correlated with that of p16 in the well-differentiated thyroid cancers. Therefore neither cyclin D1 nor p21 are suitable molecular markers to aid in the diagnosis of thyroid cancer.

Finally, following on from thyrocyte data, I investigated the immunohistochemical expression of HLA-DR, PKR and MxA, to determine whether the interferon pathway was the second proposed pathway in thyroid tumorigenesis. HLA-DR, PKR and MxA are not over-expressed in follicular adenomas and follicular carcinomas, in contrast to the up-regulation seen in our thyrocyte tumour model. However, all three genes are expressed in a proportion of papillary carcinomas, and this occurs both in the presence and absence of a lymphocytic infiltrate in these cancers. The expression of PKR

was positively correlated with p16 expression, and the intensity of staining in the carcinomas was less than that seen in the adenomas, suggesting that PKR may function as a tumour suppressor gene in thyroid tumorigenesis. Again, a much larger study is needed to compare PKR and p16 expression in well-differentiated and poorly-differentiated thyroid cancers, and in other human malignancies to investigate this further.

My research has not been able to identify a candidate gene involved in the proposed second pathway. There are however two current theories in the literature. These are the existence of cancer stem cells that will pre-determine the end tumour phenotype, potentially independently of subsequent genetic alterations, and epithelial-to-mesenchymal transition.

The thyroid gland is unusual when compared to other human organs, because the majority of thyroid cancers are indolent and slow-growing and yet still have the potential to be fatal, despite the continued expression of cell cycle inhibitory proteins such as p16. One must question why the thyroid gland has such a strong defence mechanism to prevent the development of a more aggressive phenotype, in contrast to the majority of human malignancies. The pathways involved in limiting this aggressive transformation are obviously successful in preventing the development of anaplastic carcinoma, as shown by the rarity of this tumour. Therefore why don't organs such as the colon, pancreas and prostate also have these pathways in place?

Clearly further work is needed on both *in vitro* thyrocyte tumour models and on early and late *in vivo* thyroid tumours to try and elucidate the exact nature of these pathways, which will hopefully lead to increasing our understanding of thyroid tumorigenesis, and the development of novel treatment strategies for the more aggressive forms of the disease.



## PUBLICATIONS ARISING FROM THIS WORK

Ball, E., Bond, J., Franc, B., Demicco, C. & Wynford-Thomas, D. (2007). An immunohistochemical study of p16(INK4a) expression in multistep thyroid tumourigenesis. *Eur J Cancer*, **43**, 194-201.

## APPENDIX I

### Manufacturers and Suppliers

#### **DAKO**

DAKO Ltd, Denmark House, Angel Drove, Ely, Cambs. CB7 4ET

[www.dako.co.uk](http://www.dako.co.uk)

#### **Catherine de Micco**

Institut National de la Santé et de la Recherche Médicale U555, Laboratory of Pathology, Faculty of Medicine, Mediterranean University, Marseille 13385, France

#### **Brigitte Franc**

Service d'Anatomie et de Cytologie Pathologiques, Hôpital A Paré (AP-HP), Université de Versailles, St Quentin en Yvelines, France

#### **George Kochs**

Abteilung Virologie, Institut für Medizinische Mikrobiologie und Hygiene, Universität Freiberg,

D-79008 Freiberg, Germany

#### **Leica**

Leica Microsystems UK Ltd, Davy Avnue, Knowlhill, Milton Keynes MK5 8LB

[www.leica-microsystems.com/europe](http://www.leica-microsystems.com/europe)

**Novocastra**

Novocastra Laboratories Ltd, Balliol Business Park West, Benton Lane,  
Newcastle upon Tyne, NE12 8EW, United Kingdom

[www.novocastra.co.uk](http://www.novocastra.co.uk)

**Olympus**

Olympus UK Ltd (Head Office), 2-8 Honduras Street, London, EC1Y 0TX

[www.olympus.co.uk/microscopy](http://www.olympus.co.uk/microscopy)

**Pharmingen**

10975 Torreyana Road, San Diego CA 92121-1111, California, USA

[www.pharmingen.com](http://www.pharmingen.com)

**Santa Cruz**

Santa Cruz Biotechnology, Inc. 2145 Delaware Avenue, Santa Cruz, California  
95060, USA

[www.scbt.com](http://www.scbt.com)

**SPSS**

SPSS Inc. Headquarters, 233 S. Wacker Drive, 11th floor, Chicago, Illinois  
60606

[www.spss.com](http://www.spss.com)

**Surgipath**

Surgipath Europe Limited Venture Park, Stirling Way, Bretton, Peterborough,  
PE3 8YD

[www.surgipath.com](http://www.surgipath.com)

**Thermo Electron Corporation**

5344 John Lucas Dr, Burlington, Ontario L7L 6A6, Canada

[www.thermo.com](http://www.thermo.com)

**Professor GH Williams**

Dept of Pathology, University College London, Gower Street, London, WC1E  
6BT

## APPENDIX II

### Solutions

All solutions were made up with distilled H<sub>2</sub>O.

#### **EDTA (1 litre, 0.01M)**

3.72g EDTA

0.32g NaOH pearls

pH 7.0 / 9.0

#### **Mayer's Haematoxylin (1 litre)**

1g haematoxylin

0.2g sodium iodate

50g potassium aluminium sulphate

50g chloral hydrate

1g citric acid

## APPENDIX III

### DAKO Autostainer Set-up

All computer screen icons that need to be 'clicked' with a mouse are highlighted in **bold print**.

#### Choosing a template

- Left click on **program**
- Left click on **slides** (top left of menu bar)
- Enter number of slides and click **OK**
- Left click on **Protocol Template** (bottom of screen)
- Left click on **Get Template** and select **envision** from list, which highlights the following staining protocol -
  - Rinse buffer, endogenous enzyme block, rinse buffer,
  - Primary antibody, rinse buffer
  - Labelled polymer, rinse buffer
  - Substrate, rinse water
- Left click on **Use Template** (bottom of screen)
- Select the desired volume and drop zones for **all slides** and **200 µl** in **centre** of slide

#### Assigning slides

- Left click on **endogenous enzyme block** and select ChemMate HP block, and assign to all slides
- Left click on blank box for each slide in **primary antibody** column
- Select required antibody from the drop down list with left click, or insert by editing antibody (e.g. p16) and enter time for incubation (60 minutes)
- Left click on **labelled polymer** and select Envision<sup>+</sup> HRP (mouse or rabbit as required) and assign to all slides
- Left click on **substrate** and select DAB for all slides

### **Saving program and printing labels**

- Left click on **next**
- **Save program on disk** message appears. Left click on **yes** to save details of this run
- Enter name for run and press enter
- **Print slide labels** screen appears. Left click **all** to print labels
- A screen will appear showing a map of reagent volume needed and vial position in the reagent rack

### **Loading reagents**

- Place reagent vials in the white rack on the Autostainer machine as indicated
- Check volumes of buffer and deionised water for the run - (required volumes are stated at the top of the "load Reagents" screen)
- Left click on **next**

### **Load and scan slides**

- Place slides into slide rack and place 200 µl of DAKO wash buffer on them to prevent them drying out before the run starts.
- Left click on **scan slides** (message appears "is the pathway clear for arm to move?"). Check pathway. Left click on **yes**
- Left click on **Prime Pump (Water)**
- Left click on **Prime Pump (Buffer)** 3 times
- Left click on **start run**

## APPENDIX IV

### TISSUE SECTION AND TMA RESULTS

Table IV.1 Immunohistochemistry results for p16, MCM2 and cyclin A expression in follicular adenoma tissue sections (FA)

Pathology	p16 I.D. score	MCM2 L.I. score	cyclin A L.I. score
FA	0.2	3	0
FA	0.3	1	0.4
FA	0.5	25	0.3
FA	0.5	1	0
FA	0.6	15	1.1
FA	0.8	4	0
FA	1	2	0.7
FA	1	8	0.5
FA	1	12	0
FA	1.4	6	0.1

Table IV.2 Immunohistochemistry results for p16, MCM2 and cyclin A expression in follicular carcinoma tissue sections (FA)

Pathology	p16 I.D. score	MCM2 L.I. score	cyclin A L.I. score
FC	1	1.2	0
FC	1.1	5	1.8
FC	1.2	1	0
FC	1.5	2.3	0
FC	1.5	0	0.6
FC	1.6	0.6	0
FC	1.8	14	0.2
FC	2.4	3	1.1



Table IV.3 Immunohistochemistry results for p16, MCM2 and cyclin A expression in papillary carcinoma tissue sections (FA)

Pathology	p16 I.D. score	MCM2 L.I. score	cyclin A L.I. score
PC	1.1	38	0
PC	1.3	12	0.5
PC	1.7	7	1.2
PC	1.7	11	3
PC	1.8	2	0.7
PC	2	53	1.2
PC	2.7	18	5

Table IV.4 Immunohistochemistry results for p16, MCM2 and cyclin A expression for the follicular adenomas on the TMA slides

Case No.	p16 I.D.	MCM2 L.I.	cyclin A L.I.
1	0	1	0
2	0	3.3	0
3	0	1.3	0.7
4	0	5	0
5	0	28.3	1
6	0	41.2	2.3
7	0.4	0	0
8	0.4	11	0.3
9	0.5	1	0
10	1	3.7	0
11	1	11.7	3.7
12	1.2	4.3	1.7
13	1.4	4	1.3
14	1.8	1.7	0
15	1.85	0.7	0
16	1.9	10	2

Table IV.5 Immunohistochemistry results for p16, MCM2 and cyclin A expression for the atypical adenomas on the TMA slides

Case No.	p16 I.D.	MCM2 L.I.	cyclin A L.I.
1	0.05	7.3	0
2	0.25	3	1.7
3	0.9	3.3	0
4	1.05	7.3	0
5	1.3	5	0
6	1.9	0.7	0
7	1.9	4.3	0
8	2.2	32.3	3.3
9	2.7	3	0
10	2.95	5.3	0

Table IV.6 Immunohistochemistry results for p16, MCM2 and cyclin A expression for the follicular carcinomas on the TMA slides

Case No.	p16 I.D.	MCM2 L.I.	cyclin A L.I.
1	0.1	0.7	20
2	0.9	1	0
3	0.9	2.6	0
4	1	0	0
5	1	1.7	1.7
6	1	3	0
7	1.2	29.7	1
8	1.95	0.3	0.3

Table IV.7 Immunohistochemistry results for p16, MCM2 and cyclin A expression for the papillary carcinomas on the TMA slides

Case No.	p16 I.D.	MCM2 L.I.	cyclin A L.I.
1	0	0	0.7
2	0	4	0
3	0	21.3	0
4	0	63	0
5	0.04	58	0
6	0.05	6	0.7
7	0.05	43.3	0
8	0.1	1.7	0
9	0.1	2.3	0
10	0.3	2.3	0
11	0.3	5.3	No tissue
12	0.4	23.5	0.5
13	0.5	9	0.3
14	0.5	No tissue	1.3
15	0.6	36	6.7
16	0.9	1	1
17	0.95	3	2
18	1	1.7	2.5
19	1.4	6.7	0.7
20	1.5	5.7	No tissue
21	2.2	8	5.3
22	2.25	26.3	0
23	2.4	31.7	0
24	No tissue	15	4.3
25	No tissue	37.7	No tissue
26	No tissue	No tissue	1

Table IV.8 Immunohistochemistry results for p16, MCM2 and cyclin A expression scores for the insular carcinomas on the TMA slides

Case No.	p16 I.D.	MCM2 L.I.	cyclin A L.I.
1	0	0	0
2	0	0	21.7
3	0.02	4.3	1
4	0.14	8.3	0.7
5	0.4	2.7	0.2
6	0.85	6.7	2.7
7	0.95	5	3.3
8	1	0	0
9	1	3.3	2.5
10	1	15	6.7
11	1.05	3.7	1
12	1.25	6.7	3
13	1.45	8.3	1.7
14	1.9	20	13.3
15	2	0	0.3
16	2.3	10	1
17	2.7	6.7	3

## REFERENCES

- Aldred, M.A., Huang, Y., Liyanarachchi, S., Pellegata, N.S., Gimm, O., Jhiang, S., Davuluri, R.V., de la Chapelle, A. & Eng, C. (2004). Papillary and follicular thyroid carcinomas show distinctly different microarray expression profiles and can be distinguished by a minimum of five genes. *J Clin Oncol*, **22**, 3531-9.
- Andersen, S.N., Rognum, T.O., Lund, E., Meling, G.I. & Hauge, S. (1993). Strong HLA-DR expression in large bowel carcinomas is associated with good prognosis. *Br J Cancer*, **68**, 80-5.
- Asakawa, H. & Kobayashi, T. (2002). Multistep carcinogenesis in anaplastic thyroid carcinoma: a case report. *Pathology*, **34**, 94-7.
- Ball, E., Bond, J., Franc, B., Demicco, C. & Wynford-Thomas, D. (2007). An immunohistochemical study of p16(INK4a) expression in multistep thyroid tumourigenesis. *Eur J Cancer*, **43**, 194-201.
- Barroeta, J.E., Baloch, Z.W., Lal, P., Pasha, T.L., Zhang, P.J. & LiVolsi, V.A. (2006). Diagnostic value of differential expression of CK19, Galectin-3, HBME-1, ERK, RET, and p16 in benign and malignant follicular-derived lesions of the thyroid: an immunohistochemical tissue microarray analysis. *Endocr Pathol*, **17**, 225-34.
- Bartkova, J., Lukas, J., Strauss, M. & Bartek, J. (1994). Cell cycle-related variation and tissue-restricted expression of human cyclin D1 protein. *J Pathol*, **172**, 237-45.
- Basolo, F., Pinchera, A., Fugazzola, L., Fontanini, G., Elisei, R., Romei, C. & Pacini, F. (1994). Expression of p21 ras protein as a prognostic factor in papillary thyroid cancer. *Eur J Cancer*, **30A**, 171-4.

Basolo, F., Pollina, L., Fontanini, G., Fiore, L., Pacini, F. & Baldanzi, A. (1997). Apoptosis and proliferation in thyroid carcinoma: correlation with bcl-2 and p53 protein expression. *Br J Cancer*, **75**, 537-41.

Basolo, F., Pisaturo, F., Pollina, L.E., Fontanini, G., Elisei, R., Molinaro, E., Iacconi, P., Miccoli, P. & Pacini, F. (2000). N-ras mutation in poorly differentiated thyroid carcinomas: correlation with bone metastases and inverse correlation to thyroglobulin expression. *Thyroid*, **10**, 19-23.

Baylin, S.B., Herman, J.G., Graff, J.R., Vertino, P.M. & Issa, J.P. (1998). Alterations in DNA methylation: a fundamental aspect of neoplasia. *Adv Cancer Res*, **72**, 141-96.

Beckner, M.E., Shultz, J.J. & Richardson, T. (1990). Solid and cystic ultimobranchial body remnants in the thyroid. *Arch Pathol Lab Med*, **114**, 1049-52.

Benedict, W.F., Lerner, S.P., Zhou, J., Shen, X., Tokunaga, H. & Czerniak, B. (1999). Level of retinoblastoma protein expression correlates with p16 (MTS-1/INK4A/CDKN2) status in bladder cancer. *Oncogene*, **18**, 1197-203.

Betterle, C., Presotto, F., Caretto, A., Pelizzo, M.R., Pedini, B., Girelli, M.E. & Busnardo, B. (1991). Expression of class I and II human leukocyte antigens by thyrocytes and lymphocytic infiltration on human thyroid tumors. An immunofluorescence study. *Cancer*, **67**, 977-83.

Birchmeier, W. & Behrens, J. (1994). Cadherin expression in carcinomas: role in the formation of cell junctions and the prevention of invasiveness. *Biochim Biophys Acta*, **1198**, 11-26.

Boltze, C., Zack, S., Quednow, C., Bettge, S., Roessner, A. & Schneider-Stock, R. (2003). Hypermethylation of the CDKN2/p16INK4A promoter in thyroid carcinogenesis. *Pathol Res Pract*, **199**, 399-404.

Bond, J.A., Wyllie, F.S., Ivan, M., Dawson, T. & Wynford-Thomas, D. (1993). A variant epithelial sub-population in normal thyroid with high proliferative capacity in vitro. *Mol Cell Endocrinol*, **93**, 175-83.

Bond, J.A., Wyllie, F.S., Rowson, J., Radulescu, A. & Wynford-Thomas, D. (1994). In vitro reconstruction of tumour initiation in a human epithelium. *Oncogene*, **9**, 281-90.

Bond, J.A., Haughton, M.F., Rowson, J.M., Smith, P.J., Gire, V., Wynford-Thomas, D. & Wyllie, F.S. (1999). Control of replicative life span in human cells: barriers to clonal expansion intermediate between M1 senescence and M2 crisis. *Mol Cell Biol*, **19**, 3103-14.

Bond, J., Jones, C., Haughton, M., DeMicco, C., Kipling, D. & Wynford-Thomas, D. (2004). Direct evidence from siRNA-directed "knock down" that p16(INK4a) is required for human fibroblast senescence and for limiting ras-induced epithelial cell proliferation. *Exp Cell Res*, **292**, 151-6.

Bongarzone, I., Pierotti, M.A., Monzini, N., Mondellini, P., Manenti, G., Donghi, R., Pilotti, S., Grieco, M., Santoro, M., Fusco, A. & et al. (1989). High frequency of activation of tyrosine kinase oncogenes in human papillary thyroid carcinoma. *Oncogene*, **4**, 1457-62.

Bongarzone, I. & Pierotti, M.A. (2003). The molecular basis of thyroid epithelial tumorigenesis. *Tumori*, **89**, 514-6.

Bonnet, D. & Dick, J.E. (1997). Human acute myeloid leukemia is organized as a hierarchy that originates from a primitive hematopoietic cell. *Nat Med*, **3**, 730-7.

Bos, J.L. (1989). ras oncogenes in human cancer: a review. *Cancer Res*, **49**, 4682-9.

Bottaro, D.P., Rubin, J.S., Faletto, D.L., Chan, A.M., Kmiecik, T.E., Vande Woude, G.F. & Aaronson, S.A. (1991). Identification of the hepatocyte growth factor receptor as the c-met proto-oncogene product. *Science*, **251**, 802-4.

Brazil, D.P., Yang, Z.Z. & Hemmings, B.A. (2004). Advances in protein kinase B signalling: AKTion on multiple fronts. *Trends Biochem Sci*, **29**, 233-42.

Brocker, E.B., Suter, L. & Sorg, C. (1984). HLA-DR antigen expression in primary melanomas of the skin. *J Invest Dermatol*, **82**, 244-7.

Bruni, P., Boccia, A., Baldassarre, G., Trapasso, F., Santoro, M., Chiappetta, G., Fusco, A. & Viglietto, G. (2000). PTEN expression is reduced in a subset of sporadic thyroid carcinomas: evidence that PTEN-growth suppressing activity in thyroid cancer cells mediated by p27kip1. *Oncogene*, **19**, 3146-55.

Brunner, C.A., Gokel, J.M., Riethmuller & Johnson, J.P. (1991). Expression of HLA-D subloci DR and DQ by breast carcinomas is correlated with distinct parameters of favourable prognosis. *Eur J Cancer*, **27**, 411-6.

Brzezinski, J., Migodzinski, A., Toczek, A., Tazbir, J. & Dedecjus, M. (2005). Patterns of cyclin E, retinoblastoma protein, and p21Cip1/WAF1 immunostaining in the oncogenesis of papillary thyroid carcinoma. *Clin Cancer Res*, **11**, 1037-43.

Buckley, M.F., Sweeney, K.J., Hamilton, J.A., Sini, R.L., Manning, D.L., Nicholson, R.I., deFazio, A., Watts, C.K., Musgrove, E.A. & Sutherland, R.L. (1993). Expression and amplification of cyclin genes in human breast cancer. *Oncogene*, **8**, 2127-33.

Bukholm, I.R., Bukholm, G., Holm, R. & Nesland, J.M. (2003). Association between histology grade, expression of HsMCM2, and cyclin A in human invasive breast carcinomas. *J Clin Pathol*, **56**, 368-73.



Calabro, V., Strazzullo, M., La Mantia, G., Fedele, M., Paulin, C., Fusco, A. & Lania, L. (1996). Status and expression of the p16INK4 gene in human thyroid tumors and thyroid-tumor cell lines. *Int J Cancer*, **67**, 29-34.

Carcangiu, M.L., Zampi, G. & Rosai, J. (1984). Poorly differentiated ("insular") thyroid carcinoma. A reinterpretation of Langhans' "wuchernde Struma". *Am J Surg Pathol*, **8**, 655-68.

Chawla-Sarkar, M., Lindner, D.J., Liu, Y.F., Williams, B.R., Sen, G.C., Silverman, R.H. & Borden, E.C. (2003). Apoptosis and interferons: role of interferon-stimulated genes as mediators of apoptosis. *Apoptosis*, **8**, 237-49.

Chen, B.K., Ohtsuki, Y., Furihata, M., Takeuchi, T., Iwata, J., Liang, S.B. & Sonobe, H. (1999). Overexpression of c-Met protein in human thyroid tumors correlated with lymph node metastasis and clinicopathologic stage. *Pathol Res Pract*, **195**, 427-33.

Cheng, Y.L., Lee, S.C., Harn, H.J., Chen, C.J., Chang, Y.C., Chen, J.C. & Yu, C.P. (2003). Prognostic prediction of the immunohistochemical expression of p53 and p16 in resected non-small cell lung cancer. *Eur J Cardiothorac Surg*, **23**, 221-8.

Cheung, L., Messina, M., Gill, A., Clarkson, A., Learoyd, D., Delbridge, L., Wentworth, J., Philips, J., Clifton-Bligh, R. & Robinson, B.G. (2003). Detection of the PAX8-PPAR gamma fusion oncogene in both follicular thyroid carcinomas and adenomas. *J Clin Endocrinol Metab*, **88**, 354-7.

Concha, A., Esteban, F., Cabrera, T., Ruiz-Cabello, F. & Garrido, F. (1991). Tumor aggressiveness and MHC class I and II antigens in laryngeal and breast cancer. *Semin Cancer Biol*, **2**, 47-54.

Crespo, P. & Leon, J. (2000). Ras proteins in the control of the cell cycle and cell differentiation. *Cell Mol Life Sci*, **57**, 1613-36.

Cromme, F.V., van Bommel, P.F., Walboomers, J.M., Gallee, M.P., Stern, P.L., Kenemans, P., Helmerhorst, T.J., Stukart, M.J. & Meijer, C.J. (1994). Differences in MHC and TAP-1 expression in cervical cancer lymph node metastases as compared with the primary tumours. *Br J Cancer*, **69**, 1176-81.

Daar, A.S., Fuggle, S.V., Ting, A. & Fabre, J.W. (1982). Anomalous expression of HLA-DR antigens on human colorectal cancer cells. *J Immunol*, **129**, 447-9.

Dahia, P.L., Marsh, D.J., Zheng, Z., Zedenius, J., Komminoth, P., Frisk, T., Wallin, G., Parsons, R., Longy, M., Larsson, C. & Eng, C. (1997). Somatic deletions and mutations in the Cowden disease gene, PTEN, in sporadic thyroid tumors. *Cancer Res*, **57**, 4710-3.

Dai, C.Y., Furth, E.E., Mick, R., Koh, J., Takayama, T., Niitsu, Y. & Enders, G.H. (2000). p16(INK4a) expression begins early in human colon neoplasia and correlates inversely with markers of cell proliferation. *Gastroenterology*, **119**, 929-42.

Dammrich, J., Muller-Hermelink, H.K., Mattner, A., Buchwald, J. & Ziffer, S. (1990). Histocompatibility antigen expression in pulmonary carcinomas as indication of differentiation and of special subtypes. *Cancer*, **65**, 1942-54.

Davies, H., Bignell, G.R., Cox, C., Stephens, P., Edkins, S., Clegg, S., Teague, J., Woffendin, H., Garnett, M.J., Bottomley, W., Davis, N., Dicks, E., Ewing, R., Floyd, Y., Gray, K., Hall, S., Hawes, R., Hughes, J., Kosmidou, V., Menzies, A., Mould, C., Parker, A., Stevens, C., Watt, S., Hooper, S., Wilson, R., Jayatilake, H., Gusterson, B.A., Cooper, C., Shipley, J., Hargrave, D., Pritchard-Jones, K., Maitland, N., Chenevix-Trench, G., Riggins, G.J., Bigner, D.D., Palmieri, G., Cossu, A., Flanagan, A., Nicholson, A., Ho, J.W., Leung, S.Y., Yuen, S.T., Weber, B.L., Seigler, H.F., Darrow, T.L., Paterson, H., Marais, R., Marshall, C.J., Wooster, R., Stratton, M.R. & Futreal, P.A. (2002). Mutations of the BRAF gene in human cancer. *Nature*, **417**, 949-54.

Davies, R.J., Freeman, A., Morris, L.S., Bingham, S., Dilworth, S., Scott, I., Laskey, R.A., Miller, R. & Coleman, N. (2002). Analysis of minichromosome maintenance proteins as a novel method for detection of colorectal cancer in stool. *Lancet*, **359**, 1917-9.

DeLellis, R.A. (2006). Pathology and genetics of thyroid carcinoma. *J Surg Oncol*, **94**, 662-9.

Desvergne, B. & Wahli, W. (1999). Peroxisome proliferator-activated receptors: nuclear control of metabolism. *Endocr Rev*, **20**, 649-88.

Di Renzo, M.F., Olivero, M., Ferro, S., Prat, M., Bongarzone, I., Pilotti, S., Belfiore, A., Costantino, A., Vigneri, R., Pierotti, M.A. & et al. (1992). Overexpression of the c-MET/HGF receptor gene in human thyroid carcinomas. *Oncogene*, **7**, 2549-53.

Dierick, H. & Bejsovec, A. (1999). Cellular mechanisms of wingless/Wnt signal transduction. *Curr Top Dev Biol*, **43**, 153-90.

Dirks, P.B. & Rutka, J.T. (1997). Current concepts in neuro-oncology: the cell cycle--a review. *Neurosurgery*, **40**, 1000-13; discussion 1013-5.

Dobashi, Y., Sugimura, H., Sakamoto, A., Mernyei, M., Mori, M., Oyama, T. & Machinami, R. (1994). Stepwise participation of p53 gene mutation during dedifferentiation of human thyroid carcinomas. *Diagn Mol Pathol*, **3**, 9-14.

Doganavsargil, B., Simsir, A., Boyacioglu, H., Cal, C. & Hekimgil, M. (2006). A comparison of p21 and p27 immunoexpression in benign glands, prostatic intraepithelial neoplasia and prostate adenocarcinoma. *BJU Int*, **97**, 644-8.

Dogliani, C., Pelosio, P., Laurino, L., Macri, E., Meggiolaro, E., Favretti, F. & Barbareschi, M. (1996). p21/WAF1/CIP1 expression in normal mucosa and in adenomas and adenocarcinomas of the colon: its relationship with differentiation. *J Pathol*, **179**, 248-53.

Donghi, R., Longoni, A., Pilotti, S., Michieli, P., Della Porta, G. & Pierotti, M.A. (1993). Gene p53 mutations are restricted to poorly differentiated and undifferentiated carcinomas of the thyroid gland. *J Clin Invest*, **91**, 1753-60.

Dotto, G.P. (2000). p21(WAF1/Cip1): more than a break to the cell cycle? *Biochim Biophys Acta*, **1471**, M43-56.

Drobnjak, M., Osman, I., Scher, H.I., Fazzari, M. & Cordon-Cardo, C. (2000). Overexpression of cyclin D1 is associated with metastatic prostate cancer to bone. *Clin Cancer Res*, **6**, 1891-5.

Dunn, G.P., Old, L.J. & Schreiber, R.D. (2004). The three Es of cancer immunoediting. *Annu Rev Immunol*, **22**, 329-60.

el-Deiry, W.S., Tokino, T., Velculescu, V.E., Levy, D.B., Parsons, R., Trent, J.M., Lin, D., Mercer, W.E., Kinzler, K.W. & Vogelstein, B. (1993). WAF1, a potential mediator of p53 tumor suppression. *Cell*, **75**, 817-25.

el-Deiry, W.S., Harper, J.W., O'Connor, P.M., Velculescu, V.E., Canman, C.E., Jackman, J., Pietsenpol, J.A., Burrell, M., Hill, D.E., Wang, Y. & et al. (1994). WAF1/CIP1 is induced in p53-mediated G1 arrest and apoptosis. *Cancer Res*, **54**, 1169-74.

Elisei, R., Shiohara, M., Koeffler, H.P. & Fagin, J.A. (1998). Genetic and epigenetic alterations of the cyclin-dependent kinase inhibitors p15INK4b and p16INK4a in human thyroid carcinoma cell lines and primary thyroid carcinomas. *Cancer*, **83**, 2185-93.

Emig, R., Magener, A., Ehemann, V., Meyer, A., Stilgenbauer, F., Volkmann, M., Wallwiener, D. & Sinn, H.P. (1998). Aberrant cytoplasmic expression of the p16 protein in breast cancer is associated with accelerated tumour proliferation. *Br J Cancer*, **78**, 1661-8.

Esteban, F., Ruiz-Cabello, F., Concha, A., Perez-Ayala, M., Sanchez-Rozas, J.A. & Garrido, F. (1990). HLA-DR expression is associated with excellent prognosis in squamous cell carcinoma of the larynx. *Clin Exp Metastasis*, **8**, 319-28.

Ewen, M.E. & Lamb, J. (2004). The activities of cyclin D1 that drive tumorigenesis. *Trends Mol Med*, **10**, 158-62.

Fadare, O. & Sinard, J.H. (2002). Glandular patterns in a thyroid carcinoma with insular and anaplastic features: a case with possible implications for the classification of thyroid carcinomas. *Ann Diagn Pathol*, **6**, 389-98.

Fagin, J.A. (1992). Genetic basis of endocrine disease 3: Molecular defects in thyroid gland neoplasia. *J Clin Endocrinol Metab*, **75**, 1398-400.

Fagin, J.A., Matsuo, K., Karmakar, A., Chen, D.L., Tang, S.H. & Koeffler, H.P. (1993). High prevalence of mutations of the p53 gene in poorly differentiated human thyroid carcinomas. *J Clin Invest*, **91**, 179-84.

Fagin, J.A., Tang, S.H., Zeki, K., Di Lauro, R., Fusco, A. & Gonsky, R. (1996). Reexpression of thyroid peroxidase in a derivative of an undifferentiated thyroid carcinoma cell line by introduction of wild-type p53. *Cancer Res*, **56**, 765-71.

Fagin, J.A. (2002). Minireview: branded from the start-distinct oncogenic initiating events may determine tumor fate in the thyroid. *Mol Endocrinol*, **16**, 903-11.

Fagin, J.A. (2004). How thyroid tumors start and why it matters: kinase mutants as targets for solid cancer pharmacotherapy. *J Endocrinol*, **183**, 249-56.

Farid, N.R., Shi, Y. & Zou, M. (1994). Molecular basis of thyroid cancer. *Endocr Rev*, **15**, 202-32.

Feinmesser, M., Stern, S., Mechlis-Frish, S., Lubin, E., Feinmesser, R. & Kristt, D. (1996). HLA-DR expression and lymphocytic infiltration in metastatic and non-metastatic papillary carcinoma of the thyroid. *Eur J Surg Oncol*, **22**, 494-501.

Feinmesser, M., Sulkes, A., Morgenstern, S., Sulkes, J., Stern, S. & Okon, E. (2000). HLA-DR and beta 2 microglobulin expression in medullary and atypical medullary carcinoma of the breast: histopathologically similar but biologically distinct entities. *J Clin Pathol*, **53**, 286-91.

Ferenc, T., Lewinski, A., Lange, D., Niewiadomska, H., Sygut, J., Sporny, S., Jarzab, B., Salacinska-Los, E., Kulig, A. & Wloch, J. (2004a). Analysis of P161NK4A protein expression in follicular thyroid tumors. *Pol J Pathol*, **55**, 143-8.

Ferenc, T., Lewinski, A., Lange, D., Niewiadomska, H., Sygut, J., Sporny, S., Jarzab, B., Salacinska-Los, E., Kulig, A. & Wloch, J. (2004b). Analysis of P53 and P21WAF1 proteins expression in follicular thyroid tumors. *Pol J Pathol*, **55**, 133-41.

Ferenc, T., Lewinski, A., Lange, D., Niewiadomska, H., Sygut, J., Sporny, S., Jarzab, B., Satacinska-Los, E., Kulig, A. & Wloch, J. (2005). Analysis of cyclin D1 and retinoblastoma protein immunoreactivity in follicular thyroid tumors. *Pol J Pathol*, **56**, 27-35.

Ferru, A., Fromont, G., Gibelin, H., Guilhot, J., Savagner, F., Tourani, J.M., Kraimps, J.L., Larsen, C.J. & Karayan-Tapon, L. (2006). The status of CDKN2A alpha (p16INK4A) and beta (p14ARF) transcripts in thyroid tumour progression. *Br J Cancer*, **95**, 1670-7.

Fink, A., Tomlinson, G., Freeman, J.L., Rosen, I.B. & Asa, S.L. (1996). Occult micropapillary carcinoma associated with benign follicular thyroid disease and unrelated thyroid neoplasms. *Mod Pathol*, **9**, 816-20.

Fisfalen, M.E., Franklin, W.A., DeGroot, L.J., Cajulis, R.S., Soltani, K., Ryan, M. & Jones, N. (1990). Expression of HLA ABC and DR antigens in thyroid neoplasia and correlation with mononuclear leukocyte infiltration. *J Endocrinol Invest*, **13**, 41-8.

Flohr, F., Schneider-Schaulies, S., Haller, O. & Kochs, G. (1999). The central interactive region of human MxA GTPase is involved in GTPase activation and interaction with viral target structures. *FEBS Lett*, **463**, 24-8.

Flynn, S.D., Forman, B.H., Stewart, A.F. & Kinder, B.K. (1988). Poorly differentiated ("insular") carcinoma of the thyroid gland: an aggressive subset of differentiated thyroid neoplasms. *Surgery*, **104**, 963-70.

Franceschi, S., Levi, F., Negri, E., Fassina, A. & La Vecchia, C. (1991). Diet and thyroid cancer: a pooled analysis of four European case-control studies. *Int J Cancer*, **48**, 395-8.

Fredersdorf, S., Milne, A.W., Hall, P.A. & Lu, X. (1996). Characterization of a panel of novel anti-p21Waf1/Cip1 monoclonal antibodies and immunochemical analysis of p21Waf1/Cip1 expression in normal human tissues. *Am J Pathol*, **148**, 825-35.

Freeman, A., Morris, L.S., Mills, A.D., Stoeber, K., Laskey, R.A., Williams, G.H. & Coleman, N. (1999). Minichromosome maintenance proteins as biological markers of dysplasia and malignancy. *Clin Cancer Res*, **5**, 2121-32.

Furihata, M., Ohtsuki, Y., Sonobe, H., Shuin, T., Yamamoto, A., Terao, N. & Kuwahara, M. (1997). Cyclin A overexpression in carcinoma of the renal pelvis and ureter including dysplasia: immunohistochemical findings in relation to prognosis. *Clin Cancer Res*, **3**, 1399-404.

Galabru, J., Katze, M.G., Robert, N. & Hovanessian, A.G. (1989). The binding of double-stranded RNA and adenovirus VAI RNA to the interferon-induced protein kinase. *Eur J Biochem*, **178**, 581-9.

Garcia-Rostan, G., Camp, R.L., Herrero, A., Carcangiu, M.L., Rimm, D.L. & Tallini, G. (2001). Beta-catenin dysregulation in thyroid neoplasms: down-regulation, aberrant nuclear expression, and CTNNB1 exon 3 mutations are markers for aggressive tumor phenotypes and poor prognosis. *Am J Pathol*, **158**, 987-96.

Garcia-Rostan, G., Zhao, H., Camp, R.L., Pollan, M., Herrero, A., Pardo, J., Wu, R., Carcangiu, M.L., Costa, J. & Tallini, G. (2003). ras mutations are associated with aggressive tumor phenotypes and poor prognosis in thyroid cancer. *J Clin Oncol*, **21**, 3226-35.

Garrido, F., Cabrera, T., Concha, A., Glew, S., Ruiz-Cabello, F. & Stern, P.L. (1993). Natural history of HLA expression during tumour development. *Immunol Today*, **14**, 491-9.

Garrido, F., Ruiz-Cabello, F., Cabrera, T., Perez-Villar, J.J., Lopez-Botet, M., Duggan-Keen, M. & Stern, P.L. (1997). Implications for immunosurveillance of altered HLA class I phenotypes in human tumours. *Immunol Today*, **18**, 89-95.

Gasbarri, A., Sciacchitano, S., Marasco, A., Papotti, M., Di Napoli, A., Marzullo, A., Yushkov, P., Ruco, L. & Bartolazzi, A. (2004). Detection and molecular characterisation of thyroid cancer precursor lesions in a specific subset of Hashimoto's thyroiditis. *Br J Cancer*, **91**, 1096-104.

Geisler, S.A., Olshan, A.F., Weissler, M.C., Cai, J., Funkhouser, W.K., Smith, J. & Vick, K. (2002). p16 and p53 Protein expression as prognostic indicators of survival and disease recurrence from head and neck cancer. *Clin Cancer Res*, **8**, 3445-53.

Geradts, J., Kratzke, R.A., Niehans, G.A. & Lincoln, C.E. (1995). Immunohistochemical detection of the cyclin-dependent kinase inhibitor 2/multiple tumor suppressor gene 1 (CDKN2/MTS1) product p16INK4A in archival human solid tumors: correlation with retinoblastoma protein expression. *Cancer Res*, **55**, 6006-11.



Geradts, J., Hruban, R.H., Schutte, M., Kern, S.E. & Maynard, R. (2000). Immunohistochemical p16INK4a analysis of archival tumors with deletion, hypermethylation, or mutation of the CDKN2/MTS1 gene. A comparison of four commercial antibodies. *Appl Immunohistochem Mol Morphol*, **8**, 71-9.

Geradts, J. (2003). Abrogation of the RB-p16 tumor suppressor pathway in human lung cancer. *Methods Mol Med*, **74**, 89-99.

Gerdes, B., Ramaswamy, A., Ziegler, A., Lang, S.A., Kersting, M., Baumann, R., Wild, A., Moll, R., Rothmund, M. & Bartsch, D.K. (2002). p16INK4a is a prognostic marker in resected ductal pancreatic cancer: an analysis of p16INK4a, p53, MDM2, and Rb. *Ann Surg*, **235**, 51-9.

Ghosh, A.K., Moore, M., Street, A.J., Howat, J.M. & Schofield, P.F. (1986). Expression of HLA-D sub-region products on human colorectal carcinoma. *Int J Cancer*, **38**, 459-64.

Giordano, T.J., Kuick, R., Thomas, D.G., Misek, D.E., Vinco, M., Sanders, D., Zhu, Z., Ciampi, R., Roh, M., Shedden, K., Gauger, P., Doherty, G., Thompson, N.W., Hanash, S., Koenig, R.J. & Nikiforov, Y.E. (2005). Molecular classification of papillary thyroid carcinoma: distinct BRAF, RAS, and RET/PTC mutation-specific gene expression profiles discovered by DNA microarray analysis. *Oncogene*, **24**, 6646-56.

Gire, V. & Wynford-Thomas, D. (2000). RAS oncogene activation induces proliferation in normal human thyroid epithelial cells without loss of differentiation. *Oncogene*, **19**, 737-44.

Goldsmith, N.K., Dikman, S., Bermas, B., Davies, T.F. & Roman, S.H. (1988). HLA class II antigen expression and the autoimmune thyroid response in patients with benign and malignant thyroid tumors. *Clin Immunol Immunopathol*, **48**, 161-73.

Gonzalez, M.A., Pinder, S.E., Callagy, G., Vowler, S.L., Morris, L.S., Bird, K., Bell, J.A., Laskey, R.A. & Coleman, N. (2003). Minichromosome maintenance protein 2 is a strong independent prognostic marker in breast cancer. *J Clin Oncol*, **21**, 4306-13.

Gottlieb, T.M. & Oren, M. (1996). p53 in growth control and neoplasia. *Biochim Biophys Acta*, **1287**, 77-102.

Grieco, M., Santoro, M., Berlingieri, M.T., Melillo, R.M., Donghi, R., Bongarzone, I., Pierotti, M.A., Della Porta, G., Fusco, A. & Vecchio, G. (1990). PTC is a novel rearranged form of the ret proto-oncogene and is frequently detected in vivo in human thyroid papillary carcinomas. *Cell*, **60**, 557-63.

Guan, K.L., Jenkins, C.W., Li, Y., Nichols, M.A., Wu, X., O'Keefe, C.L., Matera, A.G. & Xiong, Y. (1994). Growth suppression by p18, a p16INK4/MTS1- and p14INK4B/MTS2-related CDK6 inhibitor, correlates with wild-type pRb function. *Genes Dev*, **8**, 2939-52.

Guida, T., Salvatore, G., Faviana, P., Giannini, R., Garcia-Rostan, G., Provitera, L., Basolo, F., Fusco, A., Carlomagno, F. & Santoro, M. (2005). Mitogenic effects of the up-regulation of minichromosome maintenance proteins in anaplastic thyroid carcinoma. *J Clin Endocrinol Metab*, **90**, 4703-9.

Guner, D., Sturm, I., Hemmati, P., Hermann, S., Hauptmann, S., Wurm, R., Budach, V., Dorken, B., Lorenz, M. & Daniel, P.T. (2003). Multigene analysis of Rb pathway and apoptosis control in esophageal squamous cell carcinoma identifies patients with good prognosis. *Int J Cancer*, **103**, 445-54.

Haines, G.K., Ghadge, G., Thimmappaya, B. & Radosevich, J.A. (1992). Expression of the protein kinase p-68 recognized by the monoclonal antibody TJ4C4 in human lung neoplasms. *Virchows Arch B Cell Pathol Incl Mol Pathol*, **62**, 151-8.

Haines, G.K., Ghadge, G.D., Becker, S., Kies, M., Pelzer, H., Thimmappaya, B. & Radosevich, J.A. (1993). Correlation of the expression of double-stranded RNA-dependent protein kinase (p68) with differentiation in head and neck squamous cell carcinoma. *Virchows Arch B Cell Pathol Incl Mol Pathol*, **63**, 289-95.

Haines, G.K., Cajulis, R., Hayden, R., Duda, R., Talamonti, M. & Radosevich, J.A. (1996). Expression of the double-stranded RNA-dependent protein kinase (p68) in human breast tissues. *Tumour Biol*, **17**, 5-12.

Halachmi, N., Halachmi, S., Evron, E., Cairns, P., Okami, K., Saji, M., Westra, W.H., Zeiger, M.A., Jen, J. & Sidransky, D. (1998). Somatic mutations of the PTEN tumor suppressor gene in sporadic follicular thyroid tumors. *Genes Chromosomes Cancer*, **23**, 239-43.

Hall, M. & Peters, G. (1996). Genetic alterations of cyclins, cyclin-dependent kinases, and Cdk inhibitors in human cancer. *Adv Cancer Res*, **68**, 67-108.

Haller, O. & Kochs, G. (2002). Interferon-induced mx proteins: dynamin-like GTPases with antiviral activity. *Traffic*, **3**, 710-7.

Hanahan, D. & Weinberg, R.A. (2000). The hallmarks of cancer. *Cell*, **100**, 57-70.

Hara, E., Smith, R., Parry, D., Tahara, H., Stone, S. & Peters, G. (1996). Regulation of p16CDKN2 expression and its implications for cell immortalization and senescence. *Mol Cell Biol*, **16**, 859-67.

Harada, T., Ito, K., Shimaoka, K., Hosoda, Y. & Yakumaru, K. (1977). Fatal thyroid carcinoma. Anaplastic transformation of adenocarcinoma. *Cancer*, **39**, 2588-96.

Harper, J.W., Adami, G.R., Wei, N., Keyomarsi, K. & Elledge, S.J. (1993). The p21 Cdk-interacting protein Cip1 is a potent inhibitor of G1 cyclin-dependent kinases. *Cell*, **75**, 805-16.

Harper, J.W., Elledge, S.J., Keyomarsi, K., Dynlacht, B., Tsai, L.H., Zhang, P., Dobrowolski, S., Bai, C., Connell-Crowley, L., Swindell, E. & et al. (1995). Inhibition of cyclin-dependent kinases by p21. *Mol Biol Cell*, **6**, 387-400.

Hartwell, L.H. & Kastan, M.B. (1994). Cell cycle control and cancer. *Science*, **266**, 1821-8.

Hazard, J.B. & Kenyon, R. (1954). Atypical adenoma of the thyroid. *AMA Arch Pathol*, **58**, 554-63.

Heaney, A.P., Nelson, V., Fernando, M. & Horwitz, G. (2001). Transforming events in thyroid tumorigenesis and their association with follicular lesions. *J Clin Endocrinol Metab*, **86**, 5025-32.

Hedinger, C., Williams, E.D. & Sobin, L.H. (1989). The WHO histological classification of thyroid tumors: a commentary on the second edition. *Cancer*, **63**, 908-11.

Hemmer, S., Wasenius, V.M., Knuutila, S., Franssila, K. & Joensuu, H. (1999). DNA copy number changes in thyroid carcinoma. *Am J Pathol*, **154**, 1539-47.

Hemminki, K., Eng, C. & Chen, B. (2005). Familial risks for nonmedullary thyroid cancer. *J Clin Endocrinol Metab*, **90**, 5747-53.

Hermann, S., Sturm, I., Mrozek, A., Klosterhalfen, B., Hauptmann, S., Dorken, B. & Daniel, P.T. (2001). Bax expression in benign and malignant thyroid tumours: dysregulation of wild-type P53 is associated with a high Bax and P21 expression in thyroid carcinoma. *Int J Cancer*, **92**, 805-11.

Hilton, D.A., Penney, M., Evans, B., Sanders, H. & Love, S. (2002). Evaluation of molecular markers in low-grade diffuse astrocytomas: loss of p16 and retinoblastoma protein expression is associated with short survival. *Am J Surg Pathol*, **26**, 472-8.

Hirama, T. & Koeffler, H.P. (1995). Role of the cyclin-dependent kinase inhibitors in the development of cancer. *Blood*, **86**, 841-54.

Hodges, A. & Smoller, B.R. (2002). Immunohistochemical comparison of p16 expression in actinic keratoses and squamous cell carcinomas of the skin. *Mod Pathol*, **15**, 1121-5.

Hope, K.J., Jin, L. & Dick, J.E. (2004). Acute myeloid leukemia originates from a hierarchy of leukemic stem cell classes that differ in self-renewal capacity. *Nat Immunol*, **5**, 738-43.

Hoque, M.O., Rosenbaum, E., Westra, W.H., Xing, M., Ladenson, P., Zeiger, M.A., Sidransky, D. & Umbricht, C.B. (2005). Quantitative assessment of promoter methylation profiles in thyroid neoplasms. *J Clin Endocrinol Metab*, **90**, 4011-8.

Horisberger, M.A., Staeheli, P. & Haller, O. (1983). Interferon induces a unique protein in mouse cells bearing a gene for resistance to influenza virus. *Proc Natl Acad Sci U S A*, **80**, 1910-4.

Hovanessian, A.G. (1989). The double stranded RNA-activated protein kinase induced by interferon: dsRNA-PK. *J Interferon Res*, **9**, 641-7.

Hu, Y.X., Watanabe, H., Ohtsubo, K., Yamaguchi, Y., Ha, A., Okai, T. & Sawabu, N. (1997). Frequent loss of p16 expression and its correlation with clinicopathological parameters in pancreatic carcinoma. *Clin Cancer Res*, **3**, 1473-7.

Huang, C.I., Taki, T., Higashiyama, M., Kohno, N. & Miyake, M. (2000). p16 protein expression is associated with a poor prognosis in squamous cell carcinoma of the lung. *Br J Cancer*, **82**, 374-80.

Huber, M.A., Kraut, N. & Beug, H. (2005). Molecular requirements for epithelial-mesenchymal transition during tumor progression. *Curr Opin Cell Biol*, **17**, 548-58.

Hundahl, S.A., Fleming, I.D., Fremgen, A.M. & Menck, H.R. (1998). A National Cancer Data Base report on 53,856 cases of thyroid carcinoma treated in the U.S., 1985-1995 [see comments]. *Cancer*, **83**, 2638-48.

Hunt, J.L., Tometsko, M., LiVolsi, V.A., Swalsky, P., Finkelstein, S.D. & Barnes, E.L. (2003). Molecular evidence of anaplastic transformation in coexisting well-differentiated and anaplastic carcinomas of the thyroid. *Am J Surg Pathol*, **27**, 1559-64.

Hwang, E.S., Kim, D.W., Hwang, J.H., Jung, H.S., Suh, J.M., Park, Y.J., Chung, H.K., Song, J.H., Park, K.C., Park, S.H., Yun, H.J., Kim, J.M. & Shong, M. (2004). Regulation of signal transducer and activator of transcription 1 (STAT1) and STAT1-dependent genes by RET/PTC (rearranged in transformation/papillary thyroid carcinoma) oncogenic tyrosine kinases. *Mol Endocrinol*, **18**, 2672-84.

Ikeda, Y., Akbar, S.M., Matsui, H. & Onji, M. (2002). Antigen-presenting dendritic cells in ulcerative colitis. *J Gastroenterol*, **37 Suppl 14**, 53-5.

Ito, T., Seyama, T., Mizuno, T., Tsuyama, N., Hayashi, T., Hayashi, Y., Dohi, K., Nakamura, N. & Akiyama, M. (1992). Unique association of p53 mutations with undifferentiated but not with differentiated carcinomas of the thyroid gland. *Cancer Res*, **52**, 1369-71.

Ito, T., Seyama, T., Mizuno, T., Tsuyama, N., Hayashi, Y., Dohi, K., Nakamura, N. & Akiyama, M. (1993). Genetic alterations in thyroid tumor progression: association with p53 gene mutations. *Jpn J Cancer Res*, **84**, 526-31.

Ito, Y., Kobayashi, T., Takeda, T., Komoike, Y., Wakasugi, E., Tamaki, Y., Tsujimoto, M., Matsuura, N. & Monden, M. (1996). Expression of p21 (WAF1/CIP1) protein in clinical thyroid tissues. *Br J Cancer*, **74**, 1269-74.

Ito, Y., Yoshida, H., Nakano, K., Takamura, Y., Kobayashi, K., Yokozawa, T., Matsuzuka, F., Matsuura, N., Kuma, K. & Miyauchi, A. (2002). Expression of G2-M modulators in thyroid neoplasms: correlation of cyclin A, B1 and cdc2 with differentiation. *Pathol Res Pract*, **198**, 397-402.

Ivan, M., Bond, J.A., Prat, M., Comoglio, P.M. & Wynford-Thomas, D. (1997). Activated ras and ret oncogenes induce over-expression of c-met (hepatocyte growth factor receptor) in human thyroid epithelial cells. *Oncogene*, **14**, 2417-23.

Jagus, R., Joshi, B. & Barber, G.N. (1999). PKR, apoptosis and cancer. *Int J Biochem Cell Biol*, **31**, 123-38.

Janda, E., Lehmann, K., Killisch, I., Jechlinger, M., Herzig, M., Downward, J., Beug, H. & Grunert, S. (2002). Ras and TGF[beta] cooperatively regulate epithelial cell plasticity and metastasis: dissection of Ras signaling pathways. *J Cell Biol*, **156**, 299-313.

Jiang, W., Kahn, S.M., Tomita, N., Zhang, Y.J., Lu, S.H. & Weinstein, I.B. (1992). Amplification and expression of the human cyclin D gene in esophageal cancer. *Cancer Res*, **52**, 2980-3.

Jones, C.J., Shaw, J.J., Wyllie, F.S., Gaillard, N., Schlumberger, M. & Wynford-Thomas, D. (1996). High frequency deletion of the tumour suppressor gene P16INK4a (MTS1) in human thyroid cancer cell lines. *Mol Cell Endocrinol*, **116**, 115-9.

Jones, C.J., Kipling, D., Morris, M., Hepburn, P., Skinner, J., Bounacer, A., Wyllie, F.S., Ivan, M., Bartek, J., Wynford-Thomas, D. & Bond, J.A. (2000). Evidence for a telomere-independent "clock" limiting RAS oncogene-driven proliferation of human thyroid epithelial cells. *Mol Cell Biol*, **20**, 5690-9.

Jung, A., Schrauder, M., Oswald, U., Knoll, C., Sellberg, P., Palmqvist, R., Niedobitek, G., Brabletz, T. & Kirchner, T. (2001). The invasion front of human colorectal adenocarcinomas shows co-localization of nuclear beta-catenin, cyclin D1, and p16INK4A and is a region of low proliferation. *Am J Pathol*, **159**, 1613-7.

Kada, F., Saji, M. & Ringel, M.D. (2004). Akt: a potential target for thyroid cancer therapy. *Curr Drug Targets Immune Endocr Metabol Disord*, **4**, 181-5.

Kamb, A., Gruis, N.A., Weaver-Feldhaus, J., Liu, Q., Harshman, K., Tavtigian, S.V., Stockert, E., Day, R.S., 3rd, Johnson, B.E. & Skolnick, M.H. (1994). A cell cycle regulator potentially involved in genesis of many tumor types. *Science*, **264**, 436-40.

Kamma, H., Fujii, K. & Ogata, T. (1988). Lymphocytic infiltration in juvenile thyroid carcinoma. *Cancer*, **62**, 1988-93.

Kaplan, D.H., Shankaran, V., Dighe, A.S., Stockert, E., Aguet, M., Old, L.J. & Schreiber, R.D. (1998). Demonstration of an interferon gamma-dependent tumor surveillance system in immunocompetent mice. *Proc Natl Acad Sci U S A*, **95**, 7556-61.

Kashiwabara, K., Oyama, T., Sano, T., Fukuda, T. & Nakajima, T. (1998). Correlation between methylation status of the p16/CDKN2 gene and the expression of p16 and Rb proteins in primary non-small cell lung cancers. *Int J Cancer*, **79**, 215-20.



Kato, J., Matsushime, H., Hiebert, S.W., Ewen, M.E. & Sherr, C.J. (1993). Direct binding of cyclin D to the retinoblastoma gene product (pRb) and pRb phosphorylation by the cyclin D-dependent kinase CDK4. *Genes Dev*, **7**, 331-42.

Katoh, R., Bray, C.E., Suzuki, K., Komiyama, A., Hemmi, A., Kawaoi, A., Oyama, T., Sugai, T. & Sasou, S. (1995). Growth activity in hyperplastic and neoplastic human thyroid determined by an immunohistochemical staining procedure using monoclonal antibody MIB-1. *Hum Pathol*, **26**, 139-46.

Kaufman, J.F., Auffray, C., Korman, A.J., Shackelford, D.A. & Strominger, J. (1984). The class II molecules of the human and murine major histocompatibility complex. *Cell*, **36**, 1-13.

Kawesha, A., Ghaneh, P., Andren-Sandberg, A., Ograed, D., Skar, R., Dawiskiba, S., Evans, J.D., Campbell, F., Lemoine, N. & Neoptolemos, J.P. (2000). K-ras oncogene subtype mutations are associated with survival but not expression of p53, p16(INK4A), p21(WAF-1), cyclin D1, erbB-2 and erbB-3 in resected pancreatic ductal adenocarcinoma. *Int J Cancer*, **89**, 469-74.

Kaye, P.V., Radebold, K., Isaacs, S. & Dent, D.M. (2000). Expression of p53 and p21waf1/cip1 in gastric carcinoma: lack of inter-relationship or correlation with prognosis. *Eur J Surg Oncol*, **26**, 39-43.

Kendall-Taylor, P. (2002). Managing differentiated thyroid cancer. *Bmj*, **324**, 988-9.

Khoo, M.L., Beasley, N.J., Ezzat, S., Freeman, J.L. & Asa, S.L. (2002a). Overexpression of cyclin D1 and underexpression of p27 predict lymph node metastases in papillary thyroid carcinoma. *J Clin Endocrinol Metab*, **87**, 1814-8.

Khoo, M.L., Ezzat, S., Freeman, J.L. & Asa, S.L. (2002b). Cyclin D1 protein expression predicts metastatic behavior in thyroid papillary microcarcinomas but is not associated with gene amplification. *J Clin Endocrinol Metab*, **87**, 1810-3.

Kim, H., Jen, J., Vogelstein, B. & Hamilton, S.R. (1994). Clinical and pathological characteristics of sporadic colorectal carcinomas with DNA replication errors in microsatellite sequences. *Am J Pathol*, **145**, 148-56.

Kim, S.H., Forman, A.P., Mathews, M.B. & Gunnery, S. (2000). Human breast cancer cells contain elevated levels and activity of the protein kinase, PKR. *Oncogene*, **19**, 3086-94.

Kim, S.H., Gunnery, S., Choe, J.K. & Mathews, M.B. (2002). Neoplastic progression in melanoma and colon cancer is associated with increased expression and activity of the interferon-inducible protein kinase, PKR. *Oncogene*, **21**, 8741-8.

Kim, D., Cheng, G.Z., Lindsley, C.W., Yang, H. & Cheng, J.Q. (2005). Targeting the phosphatidylinositol-3 kinase/Akt pathway for the treatment of cancer. *Curr Opin Investig Drugs*, **6**, 1250-8.

Kim, T.Y., Kim, W.B., Song, J.Y., Rhee, Y.S., Gong, G., Cho, Y.M., Kim, S.Y., Kim, S.C., Hong, S.J. & Shong, Y.K. (2005). The BRAF mutation is not associated with poor prognostic factors in Korean patients with conventional papillary thyroid microcarcinoma. *Clin Endocrinol (Oxf)*, **63**, 588-93.

Kimura, E.T., Nikiforova, M.N., Zhu, Z., Knauf, J.A., Nikiforov, Y.E. & Fagin, J.A. (2003). High prevalence of BRAF mutations in thyroid cancer: genetic evidence for constitutive activation of the RET/PTC-RAS-BRAF signaling pathway in papillary thyroid carcinoma. *Cancer Res*, **63**, 1454-7.

Kinzler, K.W. & Vogelstein, B. (1997). Cancer-susceptibility genes. Gatekeepers and caretakers. *Nature*, **386**, 761, 763.

Kitamura, Y., Shimizu, K., Tanaka, S., Ito, K. & Emi, M. (2000). Association of allelic loss on 1q, 4p, 7q, 9p, 9q, and 16q with postoperative death in papillary thyroid carcinoma. *Clin Cancer Res*, **6**, 1819-25.

Kjellman, P., Wallin, G., Hoog, A., Auer, G., Larsson, C. & Zedenius, J. (2003). MIB-1 index in thyroid tumors: a predictor of the clinical course in papillary thyroid carcinoma. *Thyroid*, **13**, 371-80.

Kleer, C.G., Bryant, B.R., Giordano, T.J., Sobel, M. & Merino, M.J. (2000). Genetic Changes in Chromosomes 1p and 17p in Thyroid Cancer Progression. *Endocr Pathol*, **11**, 137-143.

Knoll, M.R., Teuber, J., Zmierczak, H., Winter, J. & Usadel, K.H. (1992). Immunologic findings in tissue of thyroid carcinoma. *Cancer Detect Prev*, **16**, 149-53.

Knudson, A.G., Jr. (1971). Mutation and cancer: statistical study of retinoblastoma. *Proc Natl Acad Sci U S A*, **68**, 820-3.

Koff, A., Giordano, A., Desai, D., Yamashita, K., Harper, J.W., Elledge, S., Nishimoto, T., Morgan, D.O., Franza, B.R. & Roberts, J.M. (1992). Formation and activation of a cyclin E-cdk2 complex during the G1 phase of the human cell cycle. *Science*, **257**, 1689-94.

Koh, J., Enders, G.H., Dynlacht, B.D. & Harlow, E. (1995). Tumour-derived p16 alleles encoding proteins defective in cell-cycle inhibition. *Nature*, **375**, 506-10.

Kondo, T., Ezzat, S. & Asa, S.L. (2006). Pathogenetic mechanisms in thyroid follicular-cell neoplasia. *Nat Rev Cancer*, **6**, 292-306.

Kononen, J., Bubendorf, L., Kallioniemi, A., Barlund, M., Schraml, P., Leighton, S., Torhorst, J., Mihatsch, M.J., Sauter, G. & Kallioniemi, O.P. (1998). Tissue microarrays for high-throughput molecular profiling of tumor specimens. *Nat Med*, **4**, 844-7.

Kroll, T.G., Sarraf, P., Pecciarini, L., Chen, C.J., Mueller, E., Spiegelman, B.M. & Fletcher, J.A. (2000). PAX8-PPAR $\gamma$ 1 fusion oncogene in human thyroid carcinoma [corrected]. *Science*, **289**, 1357-60.

Labib, K., Kearsey, S.E. & Diffley, J.F. (2001). MCM2-7 proteins are essential components of prereplicative complexes that accumulate cooperatively in the nucleus during G1-phase and are required to establish, but not maintain, the S-phase checkpoint. *Mol Biol Cell*, **12**, 3658-67.

Lahat, N., Sobel, E. & Kraiem, Z. (1993). Control of HLA-DR antigen expression by gamma-interferon: separate signal transduction mechanisms in malignant and nonmalignant human thyroid cells. *Cancer Res*, **53**, 3943-7.

Lam, K.Y., Lo, C.Y., Chan, K.W. & Wan, K.Y. (2000). Insular and anaplastic carcinoma of the thyroid: a 45-year comparative study at a single institution and a review of the significance of p53 and p21. *Ann Surg*, **231**, 329-38.

Lam, A.K., Lo, C.Y., Leung, P., Lang, B.H., Chan, W.F. & Luk, J.M. (2007). Clinicopathological roles of alterations of tumor suppressor gene p16 in papillary thyroid carcinoma. *Ann Surg Oncol*, **14**, 1772-9.

Lang, W., Georgii, A., Stauch, G. & Kienzle, E. (1980). The differentiation of atypical adenomas and encapsulated follicular carcinomas in the thyroid gland. *Virchows Arch A Pathol Anat Histol*, **385**, 125-41.

Lantsov, D., Meirmanov, S., Nakashima, M., Kondo, H., Saenko, V., Naruke, Y., Namba, H., Ito, M., Abrosimov, A., Lushnikov, E., Sekine, I. & Yamashita, S. (2005). Cyclin D1 overexpression in thyroid papillary microcarcinoma: its association with tumour size and aberrant beta-catenin expression. *Histopathology*, **47**, 248-56.

Lazzereschi, D., Sambuco, L., Carnovale Scalzo, C., Ranieri, A., Mincione, G., Nardi, F. & Colletta, G. (1998). Cyclin D1 and Cyclin E expression in malignant thyroid cells and in human thyroid carcinomas. *Int J Cancer*, **76**, 806-11.

Lee, C.T., Capodiceci, P., Osman, I., Fazzari, M., Ferrara, J., Scher, H.I. & Cordon-Cardo, C. (1999). Overexpression of the cyclin-dependent kinase inhibitor p16 is associated with tumor recurrence in human prostate cancer. *Clin Cancer Res*, **5**, 977-83.

Leifeld, L., Ramakers, J., Schneiders, A.M., Dumoulin, F.L., Sterneck, M., Muller, A., Sauerbruch, T. & Spengler, U. (2001). Intrahepatic MxA expression is correlated with interferon-alpha expression in chronic and fulminant hepatitis. *J Pathol*, **194**, 478-83.

Lemoine, N.R., Mayall, E.S., Wyllie, F.S., Farr, C.J., Hughes, D., Padua, R.A., Thurston, V., Williams, E.D. & Wynford-Thomas, D. (1988). Activated ras oncogenes in human thyroid cancers. *Cancer Res*, **48**, 4459-63.

Lemoine, N.R., Mayall, E.S., Wyllie, F.S., Williams, E.D., Goyns, M., Stringer, B. & Wynford-Thomas, D. (1989). High frequency of ras oncogene activation in all stages of human thyroid tumorigenesis. *Oncogene*, **4**, 159-64.

Lemoine, N.R., Staddon, S., Bond, J., Wyllie, F.S., Shaw, J.J. & Wynford-Thomas, D. (1990). Partial transformation of human thyroid epithelial cells by mutant Ha-ras oncogene. *Oncogene*, **5**, 1833-7.

Lengyel, P. (1982). Biochemistry of interferons and their actions. *Annu Rev Biochem*, **51**, 251-82.

Leversha, M.A., Fielding, P., Watson, S., Gosney, J.R. & Field, J.K. (2003). Expression of p53, pRB, and p16 in lung tumours: a validation study on tissue microarrays. *J Pathol*, **200**, 610-9.

Li, W., Sanki, A., Karim, R.Z., Thompson, J.F., Soon Lee, C., Zhuang, L., McCarthy, S.W. & Scolyer, R.A. (2006). The role of cell cycle regulatory proteins in the pathogenesis of melanoma. *Pathology*, **38**, 287-301.

Lindhorst, E., Schumm-Draeger, P.M., Bojunga, J., Usadel, K.H. & Herrmann, G. (2002). Differences in tumor cell proliferation, HLA DR expression and lymphocytic infiltration in various types of thyroid carcinoma. *Exp Clin Endocrinol Diabetes*, **110**, 27-31.

Little, A.M. & Stern, P.L. (1999). Does HLA type predispose some individuals to cancer? *Mol Med Today*, **5**, 337-42.

Liu, X.P., Tsushimi, K., Tsushimi, M., Kawauchi, S., Oga, A., Furuya, T. & Sasaki, K. (2001). Expression of p21(WAF1/CIP1) and p53 proteins in gastric carcinoma: its relationships with cell proliferation activity and prognosis. *Cancer Lett*, **170**, 183-9.

Lloyd, R.V., Johnson, T.L., Blaivas, M., Sisson, J.C. & Wilson, B.S. (1985). Detection of HLA-DR antigens in paraffin-embedded thyroid epithelial cells with a monoclonal antibody. *Am J Pathol*, **120**, 106-11.

Lo, C.Y., Lam, K.Y. & Wan, K.Y. (1999). Anaplastic carcinoma of the thyroid. *Am J Surg*, **177**, 337-9.

Longy, M. & Lacombe, D. (1996). Cowden disease. Report of a family and review. *Ann Genet*, **39**, 35-42.

Lopez-Nevot, M.A., Garcia, E., Romero, C., Oliva, M.R., Serrano, S. & Garrido, F. (1988). Phenotypic and genetic analysis of HLA class I and HLA-DR antigen expression on human melanomas. *Exp Clin Immunogenet*, **5**, 203-12.

Lovig, T., Andersen, S.N., Thorstensen, L., Diep, C.B., Meling, G.I., Lothe, R.A. & Rognum, T.O. (2002). Strong HLA-DR expression in microsatellite stable carcinomas of the large bowel is associated with good prognosis. *Br J Cancer*, **87**, 756-62.

Lowhagen, T., Granberg, P.O., Lundell, G., Skinnari, P., Sundblad, R. & Willems, J.S. (1979). Aspiration biopsy cytology (ABC) in nodules of the thyroid gland suspected to be malignant. *Surg Clin North Am*, **59**, 3-18.

Lucas-Martin, A., Foz-Sala, M., Todd, I., Bottazzo, G.F. & Pujol-Borrell, R. (1988). Occurrence of thyrocyte HLA class II expression in a wide variety of thyroid diseases: relationship with lymphocytic infiltration and thyroid autoantibodies. *J Clin Endocrinol Metab*, **66**, 367-75.

Lukas, J., Parry, D., Aagaard, L., Mann, D.J., Bartkova, J., Strauss, M., Peters, G. & Bartek, J. (1995). Retinoblastoma-protein-dependent cell-cycle inhibition by the tumour suppressor p16. *Nature*, **375**, 503-6.

Lukas, J., Sorensen, C.S., Lukas, C., Santoni-Rugiu, E. & Bartek, J. (1999). p16INK4a, but not constitutively active pRb, can impose a sustained G1 arrest: molecular mechanisms and implications for oncogenesis. *Oncogene*, **18**, 3930-5

Lundberg, A.S. & Weinberg, R.A. (1998). Functional inactivation of the retinoblastoma protein requires sequential modification by at least two distinct cyclin-cdk complexes. *Mol Cell Biol*, **18**, 753-61.

Lundberg, A.S. & Weinberg, R.A. (1999). Control of the cell cycle and apoptosis. *Eur J Cancer*, **35**, 1886-94.

Madine, M.A., Swietlik, M., Pelizon, C., Romanowski, P., Mills, A.D. & Laskey, R.A. (2000). The roles of the MCM, ORC, and Cdc6 proteins in determining the replication competence of chromatin in quiescent cells. *J Struct Biol*, **129**, 198-210.

Mallick, U.K., Lucraft, H., Proud, G., Perros, P., Fenwick, J., Kendall-Taylor, P., Johnson, S., Lennard, T., Ball, S., James, R.A., Douglas, F. & Weightman, D.R. (2000). Optimizing the management of differentiated thyroid cancer. *Clin Oncol (R Coll Radiol)*, **12**, 363-4.

Mallick, U.K. & Charalambous, H. (2004). Current issues in the management of differentiated thyroid cancer. *Nucl Med Commun*, **25**, 873-81.

Manenti, G., Pilotti, S., Re, F.C., Della Porta, G. & Pierotti, M.A. (1994). Selective activation of ras oncogenes in follicular and undifferentiated thyroid carcinomas. *Eur J Cancer*, **30A**, 987-93.

Mariatos, G., Gorgoulis, V.G., Zacharatos, P., Kotsinas, A., Vogiatzi, T., Rassidakis, G., Foukas, P., Liloglou, T., Tiniakos, D., Angelou, N., Manolis, E.N., Veslemes, M., Field, J.K. & Kittas, C. (2000). Expression of p16(INK4A) and alterations of the 9p21-23 chromosome region in non-small-cell lung carcinomas: relationship with tumor growth parameters and ploidy status. *Int J Cancer*, **89**, 133-41.

Marques, A.R., Espadinha, C., Catarino, A.L., Moniz, S., Pereira, T., Sobrinho, L.G. & Leite, V. (2002). Expression of PAX8-PPAR gamma 1 rearrangements in both follicular thyroid carcinomas and adenomas. *J Clin Endocrinol Metab*, **87**, 3947-52.

Marx, J. (2004). Cancer research. Inflammation and cancer: the link grows stronger. *Science*, **306**, 966-8.

Matias-Guiu, X., Villanueva, A., Cuatrecasas, M., Capella, G., De Leiva, A. & Prat, J. (1996). p53 in a thyroid follicular carcinoma with foci of poorly differentiated and anaplastic carcinoma. *Pathol Res Pract*, **192**, 1242-9; discussion 1250-1.

Matsuda, Y., Ichida, T., Matsuzawa, J., Sugimura, K. & Asakura, H. (1999). p16(INK4) is inactivated by extensive CpG methylation in human hepatocellular carcinoma. *Gastroenterology*, **116**, 394-400.



McKay, J.A., Douglas, J.J., Ross, V.G., Curran, S., Ahmed, F.Y., Loane, J.F., Murray, G.I. & McLeod, H.L. (2000). Expression of cell cycle control proteins in primary colorectal tumors does not always predict expression in lymph node metastases. *Clin Cancer Res*, **6**, 1113-8.

McQuaid, S., McConnell, R., McMahon, J. & Herron, B. (1995). Microwave antigen retrieval for immunocytochemistry on formalin-fixed, paraffin-embedded post-mortem CNS tissue. *J Pathol*, **176**, 207-16.

Mehrotra, P., Gonzalez, M.A., Johnson, S.J., Coleman, N., Wilson, J.A., Davies, B.R. & Lennard, T.W. (2006). Mcm-2 and Ki-67 have limited potential in preoperative diagnosis of thyroid malignancy. *Laryngoscope*, **116**, 1434-8.

Mendez, J. & Stillman, B. (2000). Chromatin association of human origin recognition complex, cdc6, and minichromosome maintenance proteins during the cell cycle: assembly of prereplication complexes in late mitosis. *Mol Cell Biol*, **20**, 8602-12.

Meng, M.V., Grossfeld, G.D., Williams, G.H., Dilworth, S., Stoeber, K., Mulley, T.W., Weinberg, V., Carroll, P.R. & Tlsty, T.D. (2001). Minichromosome maintenance protein 2 expression in prostate: characterization and association with outcome after therapy for cancer. *Clin Cancer Res*, **7**, 2712-8.

Meurs, E.F., Galabru, J., Barber, G.N., Katze, M.G. & Hovanessian, A.G. (1993). Tumor suppressor function of the interferon-induced double-stranded RNA-activated protein kinase. *Proc Natl Acad Sci U S A*, **90**, 232-6.

Mitra, J., Dai, C.Y., Somasundaram, K., El-Deiry, W.S., Satyamoorthy, K., Herlyn, M. & Enders, G.H. (1999). Induction of p21(WAF1/CIP1) and inhibition of Cdk2 mediated by the tumor suppressor p16(INK4a). *Mol Cell Biol*, **19**, 3916-28.

Miyake, N., Maeta, H., Horie, S., Kitamura, Y., Nanba, E., Kobayashi, K. & Terada, T. (2001). Absence of mutations in the beta-catenin and adenomatous polyposis coli

genes in papillary and follicular thyroid carcinomas. *Pathol Int*, **51**, 680-5.

Moller, P., Momburg, F., Koretz, K., Moldenhauer, G., Herfarth, C., Otto, H.F., Hammerling, G.J. & Schlag, P. (1991). Influence of major histocompatibility complex class I and II antigens on survival in colorectal carcinoma. *Cancer Res*, **51**, 729-36.

Monaco, R., Chen, J.M., Friedman, F.K., Brandt-Rauf, P., Chung, D. & Pincus, M.R. (1995). Structural effects of the binding of GTP to the wild-type and oncogenic forms of the ras-gene-encoded p21 proteins. *J Protein Chem*, **14**, 721-9.

Moniz, S., Catarino, A.L., Marques, A.R., Cavaco, B., Sobrinho, L. & Leite, V. (2002). Clonal origin of non-medullary thyroid tumours assessed by non-random X-chromosome inactivation. *Eur J Endocrinol*, **146**, 27-33.

Moretti, F., Farsetti, A., Soddu, S., Misiti, S., Crescenzi, M., Filetti, S., Andreoli, M., Sacchi, A. & Pontecorvi, A. (1997). p53 re-expression inhibits proliferation and restores differentiation of human thyroid anaplastic carcinoma cells. *Oncogene*, **14**, 729-40.

Moretti, F., Nanni, S. & Pontecorvi, A. (2000). Molecular pathogenesis of thyroid nodules and cancer. *Baillieres Best Pract Res Clin Endocrinol Metab*, **14**, 517-39.

Morgan, J. (2001). A protocol for preparing cell suspensions with formalin fixation and paraffin embedding which minimises the formation of cell aggregates. *Journal of cellular pathology*, **5**, 171-180.

Motoi, N., Sakamoto, A., Yamochi, T., Horiuchi, H., Motoi, T. & Machinami, R. (2000). Role of ras mutation in the progression of thyroid carcinoma of follicular epithelial origin. *Pathol Res Pract*, **196**, 1-7.

Motokura, T., Bloom, T., Kim, H.G., Juppner, H., Ruderman, J.V., Kronenberg, H.M. & Arnold, A. (1991). A novel cyclin encoded by a bcl1-linked candidate oncogene. *Nature*, **350**, 512-5.

Murphy N, R.M., Killalea AG, Uhlmann V, O'Donovan M, Mulcahy F, Turner M, McGuinness E, Griffin M, Martin C, Sheils O, O'Leary JJ. (2003). p16<sup>INK4a</sup> as a marker for cervical dyskaryosis: CIN and cGIN in cervical biopsies and ThinPrep<sup>TM</sup> smears. *Journal of Clinical Pathology*, **56**, 56-63.

Murray, A. (1994). Cell cycle checkpoints. *Curr Opin Cell Biol*, **6**, 872-6.

Myers, S.M., Eng, C., Ponder, B.A. & Mulligan, L.M. (1995). Characterization of RET proto-oncogene 3' splicing variants and polyadenylation sites: a novel C-terminus for RET. *Oncogene*, **11**, 2039-45.

Naito, H., Pairojkul, C., Kitahori, Y., Yane, K., Miyahara, H., Konishi, N., Matsunaga, T. & Hiasa, Y. (1998). Different ras gene mutational frequencies in thyroid papillary carcinomas in Japan and Thailand. *Cancer Lett*, **131**, 171-5.

Nakamura, T., Yana, I., Kobayashi, T., Shin, E., Karakawa, K., Fujita, S., Miya, A., Mori, T., Nishisho, I. & Takai, S. (1992). p53 gene mutations associated with anaplastic transformation of human thyroid carcinomas. *Jpn J Cancer Res*, **83**, 1293-8.

Namba, H., Matsuo, K. & Fagin, J.A. (1990a). Clonal composition of benign and malignant human thyroid tumors. *J Clin Invest*, **86**, 120-5.

Namba, H., Rubin, S.A. & Fagin, J.A. (1990b). Point mutations of ras oncogenes are an early event in thyroid tumorigenesis. *Mol Endocrinol*, **4**, 1474-9.

Namba, H., Nakashima, M., Hayashi, T., Hayashida, N., Maeda, S., Rogounovitch, T.I., Ohtsuru, A., Saenko, V.A., Kanematsu, T. & Yamashita, S. (2003). Clinical implication of hot spot BRAF mutation, V599E, in papillary thyroid cancers. *J Clin Endocrinol Metab*, **88**, 4393-7.

Natali, P., Bigotti, A., Cavalieri, R., Nicotra, M.R., Tecce, R., Manfredi, D., Chen, Y.X., Nadler, L.M. & Ferrone, S. (1986). Gene products of the HLA-D region in normal and malignant tissues of nonlymphoid origin. *Hum Immunol*, **15**, 220-33.

Nevins, J.R. (2001). The Rb/E2F pathway and cancer. *Hum Mol Genet*, **10**, 699-703.

Niehans, G.A., Kratzke, R.A., Froberg, M.K., Aeppli, D.M., Nguyen, P.L. & Geradts, J. (1999). G1 checkpoint protein and p53 abnormalities occur in most invasive transitional cell carcinomas of the urinary bladder. *Br J Cancer*, **80**, 1175-84.

Nikiforov, Y.E. (2004). Genetic alterations involved in the transition from well-differentiated to poorly differentiated and anaplastic thyroid carcinomas. *Endocr Pathol*, **15**, 319-27.

Nikiforov, Y.E. (2006). Radiation-induced thyroid cancer: what we have learned from chernobyl. *Endocr Pathol*, **17**, 307-17.

Nikiforova, M.N., Lynch, R.A., Biddinger, P.W., Alexander, E.K., Dorn, G.W., 2nd, Tallini, G., Kroll, T.G. & Nikiforov, Y.E. (2003a). RAS point mutations and PAX8-PPAR gamma rearrangement in thyroid tumors: evidence for distinct molecular pathways in thyroid follicular carcinoma. *J Clin Endocrinol Metab*, **88**, 2318-26.

Nikiforova, M.N., Kimura, E.T., Gandhi, M., Biddinger, P.W., Knauf, J.A., Basolo, F., Zhu, Z., Giannini, R., Salvatore, G., Fusco, A., Santoro, M., Fagin, J.A. & Nikiforov, Y.E. (2003b). BRAF mutations in thyroid tumors are restricted to papillary carcinomas and anaplastic or poorly differentiated carcinomas arising from papillary carcinomas. *J Clin Endocrinol Metab*, **88**, 5399-404.

Nobori, T., Miura, K., Wu, D.J., Lois, A., Takabayashi, K. & Carson, D.A. (1994). Deletions of the cyclin-dependent kinase-4 inhibitor gene in multiple human cancers. *Nature*, **368**, 753-6.

Noda, H., Maehara, Y., Irie, K., Kakeji, Y., Yonemura, T. & Sugimachi, K. (2001). Growth pattern and expressions of cell cycle regulator proteins p53 and p21WAF1/CIP1 in early gastric carcinoma. *Cancer*, **92**, 1828-35.

Noda, H., Maehara, Y., Irie, K., Kakeji, Y., Yonemura, T. & Sugimachi, K. (2002). Increased proliferative activity caused by loss of p21(WAF1/CIP1) expression and its clinical significance in patients with early-stage gastric carcinoma. *Cancer*, **94**, 2107-12.

Norheim Andersen, S., Breivik, J., Lovig, T., Meling, G.I., Gaudernack, G., Clausen, O.P., Schjolberg, A., Fausa, O., Langmark, F., Lund, E. & Rognum, T.O. (1996). K-ras mutations and HLA-DR expression in large bowel adenomas. *Br J Cancer*, **74**, 99-108.

Nuciforo, P. & Fraggetta, F. (2004). Cancer stem cell theory: pathologists' considerations and ruminations about wasting time and wrong evaluations. *J Clin Pathol*, **57**, 782.

Ohtani, N., Yamakoshi, K., Takahashi, A. & Hara, E. (2004). The p16INK4a-RB pathway: molecular link between cellular senescence and tumor suppression. *J Med Invest*, **51**, 146-53.

Okamoto, A., Demetrick, D.J., Spillare, E.A., Hagiwara, K., Hussain, S.P., Bennett, W.P., Forrester, K., Gerwin, B., Serrano, M., Beach, D.H. & et al. (1994). Mutations and altered expression of p16INK4 in human cancer. *Proc Natl Acad Sci U S A*, **91**, 11045-9.

Okayasu, I., Osakabe, T., Onozawa, M., Mikami, T. & Fujiwara, M. (1998). p53 and p21(WAF1) expression in lymphocytic thyroiditis and thyroid tumors. *Clin Immunol Immunopathol*, **88**, 183-91.

Pagano, M., Pepperkok, R., Verde, F., Ansorge, W. & Draetta, G. (1992). Cyclin A is required at two points in the human cell cycle. *Embo J*, **11**, 961-71.

Palmqvist, R., Rutegard, J.N., Bozoky, B., Landberg, G. & Stenling, R. (2000). Human colorectal cancers with an intact p16/cyclin D1/pRb pathway have up-regulated p16 expression and decreased proliferation in small invasive tumor clusters. *Am J Pathol*, **157**, 1947-53.

Panza, N., Del Vecchio, L., Maio, M., De Felice, M., Lombardi, G., Minozzi, M. & Zappacosta, S. (1982). Strong association between an HLA-DR antigen and thyroid carcinoma. *Tissue Antigens*, **20**, 155-8.

Papadimitrakopoulou, V., Izzo, J., Lippman, S.M., Lee, J.S., Fan, Y.H., Clayman, G., Ro, J.Y., Hittelman, W.N., Lotan, R., Hong, W.K. & Mao, L. (1997). Frequent inactivation of p16INK4a in oral premalignant lesions. *Oncogene*, **14**, 1799-803.

Papotti, M., Botto Micca, F., Favero, A., Palestini, N. & Bussolati, G. (1993). Poorly differentiated thyroid carcinomas with primordial cell component. A group of aggressive lesions sharing insular, trabecular, and solid patterns. *Am J Surg Pathol*, **17**, 291-301.

Pardal, R., Clarke, M.F. & Morrison, S.J. (2003). Applying the principles of stem-cell biology to cancer. *Nat Rev Cancer*, **3**, 895-902.

Pardee, A.B. (1989). G1 events and regulation of cell proliferation. *Science*, **246**, 603-8.

Pawson, T. (2002). Regulation and targets of receptor tyrosine kinases. *Eur J Cancer*, **38 Suppl 5**, S3-10.

Pestell, R.G., Albanese, C., Reutens, A.T., Segall, J.E., Lee, R.J. & Arnold, A. (1999). The cyclins and cyclin-dependent kinase inhibitors in hormonal regulation of proliferation and differentiation. *Endocr Rev*, **20**, 501-34.

Pickett, C.A., Agoff, S.N., Widman, T.J. & Bronner, M.P. (2005). Altered expression of cyclins and cell cycle inhibitors in papillary thyroid cancer: prognostic implications. *Thyroid*, **15**, 461-73.

Pierga, J.Y., Bonneton, C., Magdelenat, H., Vincent-Salomon, A., Nos, C., Pouillart, P. & Thiery, J.P. (2003). Clinical significance of proliferative potential of occult metastatic cells in bone marrow of patients with breast cancer. *Br J Cancer*, **89**, 539-45.

Pilotti, S., Collini, P., Mariani, L., Placucci, M., Bongarzone, I., Vigneri, P., Cipriani, S., Falcetta, F., Miceli, R., Pierotti, M.A. & Rilke, F. (1997). Insular carcinoma: a distinct de novo entity among follicular carcinomas of the thyroid gland. *Am J Surg Pathol*, **21**, 1466-73.

Pines, J. & Hunter, T. (1989). Isolation of a human cyclin cDNA: evidence for cyclin mRNA and protein regulation in the cell cycle and for interaction with p34cdc2. *Cell*, **58**, 833-46.

Pizzi, S., Azzoni, C., Bassi, D., Bottarelli, L., Milione, M. & Bordi, C. (2003). Genetic alterations in poorly differentiated endocrine carcinomas of the gastrointestinal tract. *Cancer*, **98**, 1273-82.

Poghosyan, Z. & Wynford-Thomas, D. (2005). Analysis of ras transformation of human thyroid epithelial cells. *Methods Enzymol*, **407**, 648-60.

Polsky, D., Young, A.Z., Busam, K.J. & Alani, R.M. (2001). The transcriptional repressor of p16/Ink4a, Id1, is up-regulated in early melanomas. *Cancer Res*, **61**, 6008-11.

Portella, G., Liddell, J., Crombie, R., Haddow, S., Clarke, M., Stoler, A.B. & Balmain, A. (1994). Molecular mechanisms of invasion and metastasis during mouse skin tumour progression. *Invasion Metastasis*, **14**, 7-16.

Rajendra, S., Ackroyd, R., Karim, N., Mohan, C., Ho, J.J. & Kutty, M.K. (2006). Loss of human leucocyte antigen class I and gain of class II expression are early events in carcinogenesis: clues from a study of Barrett's oesophagus. *J Clin Pathol*, **59**, 952-7.

Reed, J.A., Loganzo, F., Jr., Shea, C.R., Walker, G.J., Flores, J.F., Glendening, J.M., Bogdany, J.K., Shiel, M.J., Haluska, F.G., Fountain, J.W. & et al. (1995). Loss of expression of the p16/cyclin-dependent kinase inhibitor 2 tumor suppressor gene in melanocytic lesions correlates with invasive stage of tumor progression. *Cancer Res*, **55**, 2713-8.

Ringel, M.D., Hayre, N., Saito, J., Saunier, B., Schuppert, F., Burch, H., Bernet, V., Burman, K.D., Kohn, L.D. & Saji, M. (2001). Overexpression and overactivation of Akt in thyroid carcinoma. *Cancer Res*, **61**, 6105-11.

Rocco, J.W. & Sidransky, D. (2001). p16(MTS-1/CDKN2/INK4a) in cancer progression. *Exp Cell Res*, **264**, 42-55.

Rockett, J.C., Darnton, S.J., Crocker, J., Matthews, H.R. & Morris, A.G. (1995). Expression of HLA-ABC, HLA-DR and intercellular adhesion molecule-1 in oesophageal carcinoma. *J Clin Pathol*, **48**, 539-44.



Roers, A., Hochkeppel, H.K., Horisberger, M.A., Hovanessian, A. & Haller, O. (1994). MxA gene expression after live virus vaccination: a sensitive marker for endogenous type I interferon. *J Infect Dis*, **169**, 807-13.

Ruas, M. & Peters, G. (1998). The p16INK4a/CDKN2A tumor suppressor and its relatives. *Biochim Biophys Acta*, **1378**, F115-77.

Ruco, L.P., Stoppacciaro, A., Ballarini, F., Prat, M. & Scarpino, S. (2001). Met protein and hepatocyte growth factor (HGF) in papillary carcinoma of the thyroid: evidence for a pathogenetic role in tumourigenesis. *J Pathol*, **194**, 4-8.

Ruiter, D.J., Brocker, E.B. & Ferrone, S. (1986). Expression and susceptibility to modulation by interferons of HLA class I and II antigens on melanoma cells. Immunohistochemical analysis and clinical relevance. *J Immunogenet*, **13**, 229-34.

Sabattini, E., Bisgaard, K., Ascani, S., Poggi, S., Piccioli, M., Ceccarelli, C., Pieri, F., Fraternali-Orcioni, G. & Pileri, S.A. (1998). The EnVision++ system: a new immunohistochemical method for diagnostics and research. Critical comparison with the APAAP, ChemMate, CSA, LABC, and SABC techniques. *J Clin Pathol*, **51**, 506-11.

Saiz, A.D., Olvera, M., Rezk, S., Florentine, B.A., McCourty, A. & Brynes, R.K. (2002). Immunohistochemical expression of cyclin D1, E2F-1, and Ki-67 in benign and malignant thyroid lesions. *J Pathol*, **198**, 157-62.

Sakaguchi, M., Fujii, Y., Hirabayashi, H., Yoon, H.E., Komoto, Y., Oue, T., Kusafuka, T., Okada, A. & Matsuda, H. (1996). Inversely correlated expression of p16 and Rb protein in non-small cell lung cancers: an immunohistochemical study. *Int J Cancer*, **65**, 442-5.

Sakamoto, A., Kasai, N. & Sugano, H. (1983). Poorly differentiated carcinoma of the thyroid. A clinicopathologic entity for a high-risk group of papillary and follicular carcinomas. *Cancer*, **52**, 1849-55.

Santelli, G., de Franciscis, V., Chiappetta, G., D'Alessio, A., Califano, D., Mineo, A., Monaco, C. & Vecchio, G. (1993). Thyroid specific expression of the Ki-ras oncogene in transgenic mice. *Adv Exp Med Biol*, **348**, 59-62.

Santoro, M., Carlomagno, F., Hay, I.D., Herrmann, M.A., Grieco, M., Melillo, R., Pierotti, M.A., Bongarzone, I., Della Porta, G., Berger, N. & et al. (1992). Ret oncogene activation in human thyroid neoplasms is restricted to the papillary cancer subtype. *J Clin Invest*, **89**, 1517-22.

Santoro, M., Papotti, M., Chiappetta, G., Garcia-Rostan, G., Volante, M., Johnson, C., Camp, R.L., Pentimalli, F., Monaco, C., Herrero, A., Carcangiu, M.L., Fusco, A. & Tallini, G. (2002). RET activation and clinicopathologic features in poorly differentiated thyroid tumors. *J Clin Endocrinol Metab*, **87**, 370-9.

Sapi, Z., Lukacs, G., Sztan, M., Papp, J. & Olah, E. (1995). Contribution of p53 gene alterations to development of metastatic forms of follicular thyroid carcinoma. *Diagn Mol Pathol*, **4**, 256-60.

Scanlan, M.J., Chen, Y.T., Williamson, B., Gure, A.O., Stockert, E., Gordan, J.D., Tureci, O., Sahin, U., Pfreundschuh, M. & Old, L.J. (1998). Characterization of human colon cancer antigens recognized by autologous antibodies. *Int J Cancer*, **76**, 652-8.

Scarpino, S., Stoppacciaro, A., Colarossi, C., Cancellario, F., Marzullo, A., Marchesi, M., Biffoni, M., Comoglio, P.M., Prat, M. & Ruco, L.P. (1999). Hepatocyte growth factor (HGF) stimulates tumour invasiveness in papillary carcinoma of the thyroid. *J Pathol*, **189**, 570-5.

Scarpino, S., D'Alena, F.C., Di Napoli, A., Ballarini, F., Prat, M. & Ruco, L.P. (2003). Papillary carcinoma of the thyroid: evidence for a role for hepatocyte growth factor (HGF) in promoting tumour angiogenesis. *J Pathol*, **199**, 243-50.

Schagdarsurenjin, U., Gimm, O., Hoang-Vu, C., Dralle, H., Pfeifer, G.P. & Dammann, R. (2002). Frequent epigenetic silencing of the CpG island promoter of RASSF1A in thyroid carcinoma. *Cancer Res*, **62**, 3698-701.

Schutte, M., Hruban, R.H., Geradts, J., Maynard, R., Hilgers, W., Rabindran, S.K., Moskaluk, C.A., Hahn, S.A., Schwarte-Waldhoff, I., Schmiegel, W., Baylin, S.B., Kern, S.E. & Herman, J.G. (1997). Abrogation of the Rb/p16 tumor-suppressive pathway in virtually all pancreatic carcinomas. *Cancer Res*, **57**, 3126-30.

Scott, I.S., Morris, L.S., Bird, K., Davies, R.J., Vowler, S.L., Rushbrook, S.M., Marshall, A.E., Laskey, R.A., Miller, R., Arends, M.J. & Coleman, N. (2003). A novel immunohistochemical method to estimate cell-cycle phase distribution in archival tissue: implications for the prediction of outcome in colorectal cancer. *J Pathol*, **201**, 187-97.

Sedliarou, I., Saenko, V., Lantsov, D., Rogounovitch, T., Namba, H., Abrosimov, A., Lushnikov, E., Kumagai, A., Nakashima, M., Meirmanov, S., Mine, M., Hayashi, T. & Yamashita, S. (2004). The BRAFT1796A transversion is a prevalent mutational event in human thyroid microcarcinoma. *Int J Oncol*, **25**, 1729-35.

Segev, D.L., Umbricht, C. & Zeiger, M.A. (2003). Molecular pathogenesis of thyroid cancer. *Surg Oncol*, **12**, 69-90.

Sell, S. (2004). Stem cell origin of cancer and differentiation therapy. *Crit Rev Oncol Hematol*, **51**, 1-28.

Serrano, M., Hannon, G.J. & Beach, D. (1993). A new regulatory motif in cell-cycle control causing specific inhibition of cyclin D/CDK4. *Nature*, **366**, 704-7.

Serrano, M., Lin, A.W., McCurrach, M.E., Beach, D. & Lowe, S.W. (1997). Oncogenic ras provokes premature cell senescence associated with accumulation of p53 and p16INK4a. *Cell*, **88**, 593-602.

Shapiro, G.I., Edwards, C.D., Kobzik, L., Godleski, J., Richards, W., Sugarbaker, D.J. & Rollins, B.J. (1995). Reciprocal Rb inactivation and p16INK4 expression in primary lung cancers and cell lines. *Cancer Res*, **55**, 505-9.

Sherr, C.J. (1995). D-type cyclins. *Trends Biochem Sci*, **20**, 187-90.

Sherr, C.J. & Roberts, J.M. (1995). Inhibitors of mammalian G1 cyclin-dependent kinases. *Genes Dev*, **9**, 1149-63.

Sherr, C.J. (1996). Cancer cell cycles. *Science*, **274**, 1672-7.

Sherr, C.J. & Roberts, J.M. (1999). CDK inhibitors: positive and negative regulators of G1-phase progression. *Genes Dev*, **13**, 1501-12.

Sherr, C.J. (2000). Cell cycle control and cancer. *Harvey Lect*, **96**, 73-92.

Shi, S.R., Key, M.E. & Kalra, K.L. (1991). Antigen retrieval in formalin-fixed, paraffin-embedded tissues: an enhancement method for immunohistochemical staining based on microwave oven heating of tissue sections. *J Histochem Cytochem*, **39**, 741-8.

Shi, Y.F., Zou, M.J., Schmidt, H., Juhasz, F., Stensky, V., Robb, D. & Farid, N.R. (1991). High rates of ras codon 61 mutation in thyroid tumors in an iodide-deficient area. *Cancer Res*, **51**, 2690-3.

Shi, Y.Z., Hui, A.M., Li, X., Takayama, T. & Makuuchi, M. (2000). Overexpression of retinoblastoma protein predicts decreased survival and correlates with loss of p16INK4 protein in gallbladder carcinomas. *Clin Cancer Res*, **6**, 4096-100.

Shimada, A., Shiota, G., Miyata, H., Kamahora, T., Kawasaki, H., Shiraki, K., Hino, S. & Terada, T. (1998). Aberrant expression of double-stranded RNA-

dependent protein kinase in hepatocytes of chronic hepatitis and differentiated hepatocellular carcinoma. *Cancer Res*, **58**, 4434-8.

Shin, E., Hong, S.W., Kim, S.H. & Yang, W.I. (2004). Expression of down stream molecules of RET (p-ERK, p-p38 MAPK, p-JNK and p-AKT) in papillary thyroid carcinomas. *Yonsei Med J*, **45**, 306-13.

Shook, D. & Keller, R. (2003). Mechanisms, mechanics and function of epithelial-mesenchymal transitions in early development. *Mech Dev*, **120**, 1351-83.

Singh, C., Haines, G.K., Talamonti, M.S. & Radosевич, J.A. (1995). Expression of p68 in human colon cancer. *Tumour Biol*, **16**, 281-9.

Sinicrope, F.A., Roddey, G., Lemoine, M., Ruan, S., Stephens, L.C., Frazier, M.L.,

Shen, Y. & Zhang, W. (1998). Loss of p21WAF1/Cip1 protein expression accompanies progression of sporadic colorectal neoplasms but not hereditary nonpolyposis colorectal cancers. *Clin Cancer Res*, **4**, 1251-61.

Skinner, J., Bounacer, A., Bond, J.A., Haughton, M.F., DeMicco, C. & Wynford-Thomas, D. (2004). Opposing effects of mutant ras oncoprotein on human fibroblast and epithelial cell proliferation: implications for models of human tumorigenesis. *Oncogene*.

Smith, B.D., Haffty, B.G. & Sasaki, C.T. (2001). Molecular markers in head and neck squamous cell carcinoma: their biological function and prognostic significance. *Ann Otol Rhinol Laryngol*, **110**, 221-8.

Soares, P., Trovisco, V., Rocha, A.S., Lima, J., Castro, P., Preto, A., Maximo, V., Botelho, T., Seruca, R. & Sobrinho-Simoes, M. (2003). BRAF mutations and RET/PTC rearrangements are alternative events in the etiopathogenesis of PTC. *Oncogene*, **22**, 4578-80.

Soares, P., Trovisco, V., Rocha, A.S., Feijao, T., Rebocho, A.P., Fonseca, E., Vieira de Castro, I., Cameselle-Teijeiro, J., Cardoso-Oliveira, M. & Sobrinho-Simoes, M. (2004). BRAF mutations typical of papillary thyroid carcinoma are more frequently detected in undifferentiated than in insular and insular-like poorly differentiated carcinomas. *Virchows Arch*, **444**, 572-6.

Soderstrom, N. (1952). Puncture of goiters for aspiration biopsy. *Acta Med Scand*, **144**, 237-44.

Sogol, P.B., Sugawara, M., Gordon, H.E., Shellow, W.V., Hernandez, F. & Hershman, J.M. (1983). Cowden's disease: familial goiter and skin hamartomas. A report of three cases. *West J Med*, **139**, 324-8.

Spitzweg, C. & Morris, J.C. (2004). Gene therapy for thyroid cancer: current status and future prospects. *Thyroid*, **14**, 424-34.

Stoeber, K., Halsall, I., Freeman, A., Swinn, R., Doble, A., Morris, L., Coleman, N., Bullock, N., Laskey, R.A., Hales, C.N. & Williams, G.H. (1999). Immunoassay for urothelial cancers that detects DNA replication protein Mcm5 in urine. *Lancet*, **354**, 1524-5.

Stoeber, K., Tlsty, T.D., Happerfield, L., Thomas, G.A., Romanov, S., Bobrow, L., Williams, E.D. & Williams, G.H. (2001). DNA replication licensing and human cell proliferation. *J Cell Sci*, **114**, 2027-41.

Straume, O., Sviland, L. & Akslén, L.A. (2000). Loss of nuclear p16 protein expression correlates with increased tumor cell proliferation (Ki-67) and poor prognosis in patients with vertical growth phase melanoma. *Clin Cancer Res*, **6**, 1845-53.

Suarez, H.G., Du Villard, J.A., Caillou, B., Schlumberger, M., Tubiana, M., Parmentier, C. & Monier, R. (1988). Detection of activated ras oncogenes in human thyroid carcinomas. *Oncogene*, **2**, 403-6.

Suarez, H.G., du Villard, J.A., Severino, M., Caillou, B., Schlumberger, M., Tubiana, M., Parmentier, C. & Monier, R. (1990). Presence of mutations in all three ras genes in human thyroid tumors. *Oncogene*, **5**, 565-70.

Sugg, S.L., Ezzat, S., Rosen, I.B., Freeman, J.L. & Asa, S.L. (1998). Distinct multiple RET/PTC gene rearrangements in multifocal papillary thyroid neoplasia. *J Clin Endocrinol Metab*, **83**, 4116-22.

Svensson, S., Nilsson, K., Ringberg, A. & Landberg, G. (2003). Invade or proliferate? Two contrasting events in malignant behavior governed by p16(INK4a) and an intact Rb pathway illustrated by a model system of basal cell carcinoma. *Cancer Res*, **63**, 1737-42.

Taga, S., Osaki, T., Ohgami, A., Imoto, H., Yoshimatsu, T., Yoshino, I., Yano, K., Nakanishi, R., Ichiyoshi, Y. & Yasumoto, K. (1997). Prognostic value of the immunohistochemical detection of p16INK4 expression in nonsmall cell lung carcinoma. *Cancer*, **80**, 389-95.

Takagi, Y., Takashi, M., Koshikawa, T., Sakata, T. & Ohshima, S. (2000). Immunohistochemical demonstration of cyclin D1 in bladder cancers as an inverse indicator of invasiveness but not an independent prognostic factor. *Int J Urol*, **7**, 366-72.

Takahashi, M., Ritz, J. & Cooper, G.M. (1985). Activation of a novel human transforming gene, ret, by DNA rearrangement. *Cell*, **42**, 581-8.

Takeuchi, H., Ozawa, S., Ando, N., Shih, C.H., Koyanagi, K., Ueda, M. & Kitajima, M. (1997). Altered p16/MTS1/CDKN2 and cyclin D1/PRAD-1 gene expression is associated with the prognosis of squamous cell carcinoma of the esophagus. *Clin Cancer Res*, **3**, 2229-36.

Takeuchi, Y., Daa, T., Kashima, K., Yokoyama, S., Nakayama, I. & Noguchi, S. (1999). Mutations of p53 in thyroid carcinoma with an insular component. *Thyroid*, **9**, 377-81.

Tallini, G., Santoro, M., Helie, M., Carlomagno, F., Salvatore, G., Chiappetta, G., Carcangiu, M.L. & Fusco, A. (1998). RET/PTC oncogene activation defines a subset of papillary thyroid carcinomas lacking evidence of progression to poorly differentiated or undifferentiated tumor phenotypes. *Clin Cancer Res*, **4**, 287-94.

Tallini, G. (2002). Molecular pathobiology of thyroid neoplasms. *Endocr Pathol*, **13**, 271-88.

Talve, L., Sauroja, I., Collan, Y., Punnonen, K. & Ekfors, T. (1997). Loss of expression of the p16INK4/CDKN2 gene in cutaneous malignant melanoma correlates with tumor cell proliferation and invasive stage. *Int J Cancer*, **74**, 255-9.

Temnim, L., Ebraheem, A.K., Baker, H. & Sinowatz, F. (2006). Cyclin D1 protein expression in human thyroid gland and thyroid cancer. *Anat Histol Embryol*, **35**, 125-9.

Terada, T., Maeta, H., Endo, K. & Ohta, T. (2000). Protein expression of double-stranded RNA-activated protein kinase in thyroid carcinomas: correlations with histologic types, pathologic parameters, and Ki-67 labeling. *Hum Pathol*, **31**, 817-21.

Thiery, J.P. (2002). Epithelial-mesenchymal transitions in tumour progression. *Nat Rev Cancer*, **2**, 442-54.

Thiery, J.P. (2003). Epithelial-mesenchymal transitions in development and pathologies. *Curr Opin Cell Biol*, **15**, 740-6.

Thiery, J.P. & Sleeman, J.P. (2006). Complex networks orchestrate epithelial-mesenchymal transitions. *Nat Rev Mol Cell Biol*, **7**, 131-42.



Thompson, J.S., Harned, R.K., Anderson, J.C. & Hodgson, P.E. (1983). Papillary carcinoma of the thyroid and familial polyposis coli. *Dis Colon Rectum*, **26**, 583-5.

Trovato, M., Villari, D., Bartolone, L., Spinella, S., Simone, A., Violi, M.A., Trimarchi, F., Batolo, D. & Benvenga, S. (1998). Expression of the hepatocyte growth factor and c-met in normal thyroid, non-neoplastic, and neoplastic nodules. *Thyroid*, **8**, 125-31.

Trovisco, V., Soares, P. & Sobrinho-Simoes, M. (2006). B-RAF mutations in the etiopathogenesis, diagnosis, and prognosis of thyroid carcinomas. *Hum Pathol*, **37**, 781-6.

Tung, W.S., Shevlin, D.W., Bartsch, D., Norton, J.A., Wells, S.A., Jr. & Goodfellow, P.J. (1996). Infrequent CDKN2 mutation in human differentiated thyroid cancers. *Mol Carcinog*, **15**, 5-10.

Tzen, C.Y., Huang, Y.W. & Fu, Y.S. (2003). Is atypical follicular adenoma of the thyroid a preinvasive malignancy? *Hum Pathol*, **34**, 666-9.

Vasko, V., Ferrand, M., Di Cristofaro, J., Carayon, P., Henry, J.F. & de Micco, C. (2003). Specific pattern of RAS oncogene mutations in follicular thyroid tumors. *J Clin Endocrinol Metab*, **88**, 2745-52.

Vasko, V.V., Gaudart, J., Allasia, C., Savchenko, V., Di Cristofaro, J., Saji, M., Ringel, M.D. & De Micco, C. (2004a). Thyroid follicular adenomas may display features of follicular carcinoma and follicular variant of papillary carcinoma. *Eur J Endocrinol*, **151**, 779-86.

Vasko, V., Saji, M., Hardy, E., Kruhlak, M., Larin, A., Savchenko, V., Miyakawa, M., Isozaki, O., Murakami, H., Tsushima, T., Burman, K.D., De Micco, C. & Ringel, M.D. (2004b). Akt activation and localisation correlate with tumour invasion and oncogene expression in thyroid cancer. *J Med Genet*, **41**, 161-70.

Vasko, V.V. & Saji, M. (2007). Molecular mechanisms involved in differentiated thyroid cancer invasion and metastasis. *Curr Opin Oncol*, **19**, 11-7.

Viglietto, G., Chiappetta, G., Martinez-Tello, F.J., Fukunaga, F.H., Tallini, G., Rigopoulou, D., Visconti, R., Mastro, A., Santoro, M. & Fusco, A. (1995). RET/PTC oncogene activation is an early event in thyroid carcinogenesis. *Oncogene*, **11**, 1207-10.

Vogelstein, B. & Kinzler, K.W. (1992). p53 function and dysfunction. *Cell*, **70**, 523-6.

Wang, S., Lloyd, R.V., Hutzler, M.J., Safran, M.S., Patwardhan, N.A. & Khan, A. (2000). The role of cell cycle regulatory protein, cyclin D1, in the progression of thyroid cancer. *Mod Pathol*, **13**, 882-7.

Ward, L.S., Brenta, G., Medvedovic, M. & Fagin, J.A. (1998). Studies of allelic loss in thyroid tumors reveal major differences in chromosomal instability between papillary and follicular carcinomas. *J Clin Endocrinol Metab*, **83**, 525-30.

Weetman, A.P., Volkman, D.J., Burman, K.D., Gerrard, T.L. & Fauci, A.S. (1985). The in vitro regulation of human thyrocyte HLA-DR antigen expression. *J Clin Endocrinol Metab*, **61**, 817-24.

Wicha, M.S., Liu, S. & Dontu, G. (2006). Cancer stem cells: an old idea--a paradigm shift. *Cancer Res*, **66**, 1883-90; discussion 1895-6.

Williams, B.R. (1999). PKR; a sentinel kinase for cellular stress. *Oncogene*, **18**, 6112-20.

Williams, E.D. (1979). The aetiology of thyroid tumours. *Clin Endocrinol Metab*, **8**, 193-207.

Williams, G.H., Romanowski, P., Morris, L., Madine, M., Mills, A.D., Stoeber, K., Marr, J., Laskey, R.A. & Coleman, N. (1998). Improved cervical smear assessment using antibodies against proteins that regulate DNA replication. *Proc Natl Acad Sci U S A*, **95**, 14932-7.

Wilson, B.S., Herzig, M.A. & Lloyd, R.V. (1984). Immunoperoxidase staining for Ia-like antigens in paraffin-embedded tissues from human melanoma and lung carcinoma. *Am J Pathol*, **115**, 102-8.

Winchester, R.J. & Kunkel, H.G. (1979). The human Ia system. *Adv Immunol*, **28**, 221-92.

Wiseman, S.M., Loree, T.R., Rigual, N.R., Hicks, W.L., Jr., Douglas, W.G., Anderson, G.R. & Stoler, D.L. (2003). Anaplastic transformation of thyroid cancer: review of clinical, pathologic, and molecular evidence provides new insights into disease biology and future therapy. *Head Neck*, **25**, 662-70.

Wreesmann, V.B., Ghossein, R.A., Patel, S.G., Harris, C.P., Schnaser, E.A., Shaha, A.R., Tuttle, R.M., Shah, J.P., Rao, P.H. & Singh, B. (2002). Genome-wide appraisal of thyroid cancer progression. *Am J Pathol*, **161**, 1549-56.

Wright, P.A., Lemoine, N.R., Mayall, E.S., Wyllie, F.S., Hughes, D., Williams, E.D. & Wynford-Thomas, D. (1989). Papillary and follicular thyroid carcinomas show a different pattern of ras oncogene mutation. *Br J Cancer*, **60**, 576-7.

Wright, W.E. & Shay, J.W. (2001). Cellular senescence as a tumor-protection mechanism: the essential role of counting. *Curr Opin Genet Dev*, **11**, 98-103.

Wyllie, F.S., Haughton, M.F., Blaydes, J.P., Schlumberger, M. & Wynford-Thomas, D. (1995). Evasion of p53-mediated growth control occurs by three alternative mechanisms in transformed thyroid epithelial cells. *Oncogene*, **10**, 49-59.

Wynford-Thomas, D. (1991). Oncogenes and anti-oncogenes; the molecular basis of tumour behaviour. *J Pathol*, **165**, 187-201.

Wynford-Thomas, D. (1993a). Molecular basis of epithelial tumorigenesis: the thyroid model. *Crit Rev Oncog*, **4**, 1-23.

Wynford-Thomas, D. (1993b). In vitro models of thyroid cancer. *Cancer Surv*, **16**, 115-34.

Wynford-Thomas, D. (1997). Origin and progression of thyroid epithelial tumours: cellular and molecular mechanisms. *Horm Res*, **47**, 145-57.

Wynford-Thomas, D. & Blaydes, J. (1998). The influence of cell context on the selection pressure for p53 mutation in human cancer. *Carcinogenesis*, **19**, 29-36.

Xing, M., Westra, W.H., Tufano, R.P., Cohen, Y., Rosenbaum, E., Rhoden, K.J., Carson, K.A., Vasko, V., Larin, A., Tallini, G., Tolaney, S., Holt, E.H., Hui, P., Umbricht, C.B., Basaria, S., Ewertz, M., Tufaro, A.P., Califano, J.A., Ringel, M.D., Zeiger, M.A., Sidransky, D. & Ladenson, P.W. (2005). BRAF mutation predicts a poorer clinical prognosis for papillary thyroid cancer. *J Clin Endocrinol Metab*, **90**, 6373-9.

Yam, C.H., Fung, T.K. & Poon, R.Y. (2002). Cyclin A in cell cycle control and cancer. *Cell Mol Life Sci*, **59**, 1317-26.

Yane, K., Konishi, N., Kitahori, Y., Naito, H., Okaichi, K., Ohnishi, T., Miyahara, H., Matsunaga, T. & Hiasa, Y. (1996). Lack of p16/CDKN2 alterations in thyroid carcinomas. *Cancer Lett*, **101**, 85-92.

Yeung, M.C., Liu, J. & Lau, A.S. (1996). An essential role for the interferon-inducible, double-stranded RNA-activated protein kinase PKR in the tumor necrosis factor-induced apoptosis in U937 cells. *Proc Natl Acad Sci U S A*, **93**, 12451-5.

Yoshida, A., Nakamura, Y., Imada, T., Asaga, T., Shimizu, A. & Harada, M. (1999). Apoptosis and proliferative activity in thyroid tumors. *Surg Today*, **29**, 204-8.

Zamanian-Daryoush, M., Der, S.D. & Williams, B.R. (1999). Cell cycle regulation of the double stranded RNA activated protein kinase, PKR. *Oncogene*, **18**, 315-26.

Zedenius, J., Larsson, C., Wallin, G., Backdahl, M., Aspenblad, U., Hoog, A., Borresen, A.L. & Auer, G. (1996). Alterations of p53 and expression of WAF1/p21 in human thyroid tumors. *Thyroid*, **6**, 1-9.

Zelmanovitz, F., Moraes, I.V., Spiro, B.L. & Masiero, P.R. (2004). Activation of thyroid tissue in thyroglossal duct. *Thyroid*, **14**, 475-6.

Zeng, Y.X. & el-Deiry, W.S. (1996). Regulation of p21WAF1/CIP1 expression by p53-independent pathways. *Oncogene*, **12**, 1557-64.

Zhang, P., Zuo, H., Ozaki, T., Nakagomi, N. & Kakudo, K. (2006). Cancer stem cell hypothesis in thyroid cancer. *Pathol Int*, **56**, 485-9.

Zhao, P., Hu, Y.C. & Talbot, I.C. (2003). Expressing patterns of p16 and CDK4 correlated to prognosis in colorectal carcinoma. *World J Gastroenterol*, **9**, 2202-6.

Zhu, X.L., Hartwick, W., Rohan, T. & Kandel, R. (1998). Cyclin D1 gene amplification and protein expression in benign breast disease and breast carcinoma. *Mod Pathol*, **11**, 1082-8.

Zhu, Z., Ciampi, R., Nikiforova, M.N., Gandhi, M. & Nikiforov, Y.E. (2006). Prevalence of RET/PTC rearrangements in thyroid papillary carcinomas: effects of the detection methods and genetic heterogeneity. *J Clin Endocrinol Metab*, **91**, 3603-10.

Zimmerman, L.M., Wagner, D.H., Perlmutter, H.M. & Amromin, G.D. (1950). Benign and malignant epithelial tumors of the thyroid gland. *Arch Surg*, **60**, 1183-98.

Zindy, F., Lamas, E., Chenivesse, X., Sobczak, J., Wang, J., Fesquet, D., Henglein, B. & Brechot, C. (1992). Cyclin A is required in S phase in normal epithelial cells. *Biochem Biophys Res Commun*, **182**, 1144-54.