

Child abuse and fabricated or induced illness in the ENT setting: a systematic review

Rees, P.,* Al-Hussaini, A.† & Maguire, S.*

*Cochrane Institute of Primary Care and Public Health, Cardiff University, Cardiff, UK †Department of Otolaryngology, Head and Neck Surgery, University Hospital of Wales, Cardiff, UK

Accepted for publication 2 May 2016
Clin. Otolaryngol. 2016, **00**, 000–000

Background: Child maltreatment is persistently under-recognised. Given that a third of maltreated children may return with serious or fatal injuries, it is imperative that otolaryngologists who are in frequent contact with children are able to detect maltreatment at first presentation.

Objective of review: This review aims to identify ENT injuries, signs or symptoms that are indicative of physical abuse or fabricated or induced illness (child maltreatment).

Type of review: Systematic review.

Search strategy: An all-language search, developed in Medline Ovid and consisting of 76 key words, was conducted of published and grey literature across 10 databases from inception to July 2015, for primary observational studies involving children aged <18 years.

Evaluation method: Each relevant article underwent two independent reviews with full critical appraisal, applying strict quality standards.

Results: Of the 2448 studies identified and screened, 371 underwent full review, resulting in 38 included studies that detailed 122 maltreated children. Pharyngeal perforations ($n = 20$) were the most frequent abusive ENT injury, predominantly affecting neonates and infants, presenting with dysphagia, drooling, haemoptysis and surgical

emphysema. At least 52% of children with abusive pharyngeal injuries had additional co-existent injuries. The majority of ear injuries were inflicted to the external ear ($n = 11$) and included auricular deformity, abrasions, petechiae, lacerations and burns. Fabricated or induced illness cases presented most commonly with recurrent, unexplained otorrhoea or ENT lesions that failed to heal despite appropriate therapy.

Conclusions: All clinicians should be familiar with the signs of child maltreatment. Pharyngeal injuries, or injuries to the external ear, presenting in young children without an explicit history of witnessed injury should prompt a child protection referral for full evaluation. Likewise, children who present with recurrent, or apparently intractable symptoms and signs despite appropriate treatment, should raise the possibility of fabricated or induced illness, and discussion with a child protection specialist is advised. Early recognition of possible child maltreatment and instigation of appropriate safeguarding measures are essential to prevent repetition and escalation of injury. This is of paramount importance to otolaryngologists, who have the potential to identify these children in their practice.

Paediatric otolaryngology accounts for approximately 30–50% of otolaryngologists' workload, and head and neck injuries are commonly described amongst abused children.^{1–3} It is estimated that child maltreatment is significantly under-recognised in almost every healthcare setting; potentially as few as 10% of cases are detected.⁴ Of those undetected children who are discharged, approximately a third may subsequently return with serious or fatal injuries.⁵ It is therefore imperative that healthcare

professionals, particularly those in frequent contact with children, are cognisant of the frequency of maltreatment in this population and that they are vigilant in detecting, investigating and consulting child protection specialists whenever safeguarding concerns arise, to prevent the repetition or escalation of maltreatment.⁶

The World Health Organisation considers five types of child maltreatment: physical abuse, fabricated or induced illness, sexual abuse, neglect and emotional abuse.⁷ This prominent public health issue is of importance to numerous specialties including otolaryngology. Child maltreatment is prevalent: annually there are an estimated 70 child homicides in the UK alone, and as many as 16% of children globally are estimated to suffer maltreatment.^{4,8} This represents a

Correspondence: S. Maguire, Senior Lecturer in Child Health, Cochrane Institute of Primary Care and Public Health, Cardiff University, 5th Floor, Neuadd Meirionnydd, Heath Park, Cardiff CF14 4YS, UK. Tel.: +44 0 29 20687189; Fax: +44 0 2920 687944; e-mail: sabinemaguire@gmail.com

significant societal and economic burden, and is known to have severe long-term consequences.⁴ The wide-ranging and protracted consequences of child maltreatment include an increased risk of mental health problems, cardiovascular disease and risky health behaviours throughout the lifespan.⁹

While neglect is the most common form of maltreatment, physical abuse, which is more easily recognisable by clinicians, is the second most common.^{10,11} Physical abuse is defined as ‘hitting, shaking, throwing, poisoning, burning or scalding, drowning, suffocating or otherwise causing physical harm to a child’.¹² Fabricated or induced illness (FII) is defined as an illness, which is fabricated or induced by caregivers in a child, in order for them to receive medical attention.¹³ This more covert form of maltreatment is difficult to detect and has a poor prognosis.¹⁴ The diverse range of symptoms experienced by children with FII and the importance of FII in the ENT setting is emphasised in the published literature.^{15,16}

Systematic reviews are an essential resource for clinicians in this era where it is incumbent upon healthcare professionals to practice, and stay up-to-date with evidence-based medicine. This systematic review aims to identify the features of ENT injuries as a consequence of physical child maltreatment and the features of FII presenting with ENT symptoms and signs.

Methods

Search strategy

An all-language search of published and grey literature was conducted across ten databases from 1900 to 2015 (Appendix 1). The search strategy was developed in Medline Ovid using MeSH headings, and consisted of 76 key words, which were modified for other databases (Appendix 2). Search sensitivity was augmented through hand searching non-indexed journals and searching the references of all full-text articles reviewed.

Data extraction

Duplicate references were removed and each abstract scanned for relevance, independently, by two trained reviewers (SM and PR). Each article deemed relevant was then assessed for inclusion and critically appraised using a standardised critical appraisal form adapted from multiple sources including the NHS Centre for Reviews and Dissemination criteria and previous reviews.^{17–21} Third-reviewer (AA) arbitration was used to resolve disagreements. Data from included studies were extracted by two independent reviewers (AA and PR) using a purpose built data extraction sheet. This review was conducted in-line with the preferred

reporting items for systematic reviews and meta-analyses (PRISMA) guidelines.²²

Quality standards

Inclusion criteria (Table 1) were as follows: all studies of children aged <18 completed years experiencing ENT injuries as a result of physical abuse or exhibiting signs or symptoms of FII. For the purposes of this review, definitions used were as follows: the ear included the auricle (external ear) to the internal auditory meatus and the Eustachian tubes. Nose was defined as the external nose to the nasopharynx including the sinuses. Throat was defined as the oropharynx including the palatine and lingual tonsils to the laryngopharynx. The UK Department of Health definitions of physical abuse and FII were used.¹² Due to the paucity of comparative studies addressing our review questions, observational studies of all designs were included. Exclusion criteria comprised fractures or bruising (addressed by separate reviews);^{18,21} studies which only addressed accidental or iatrogenic ENT injuries; sexual abuse; the outcomes of child maltreatment or management of ENT injuries; reviews or expert opinion; and studies where adult and child data could not be separated. In addition, we excluded studies of oral injuries with the anatomical boundaries being the vermilion border of the lips to the soft palate, and studies on epistaxis as a presentation of asphyxiation, as these are addressed in recent systematic reviews.^{23,24}

To minimise the risk of circularity, that is to exclude studies that used ENT injuries, signs or symptoms to confirm maltreatment, cases within each study were assessed against an internationally recognised and previously used ranking of maltreatment confirmation (Table 2).^{18,23} Cases with a ranking of 1–3 were included: rank 1 representing the highest confidence that maltreatment occurred, that is the decision did not rest exclusively on the clinical features, and rank 5 representing the poorest quality of maltreatment confirmation. Additionally, we ranked the quality of examination of the ear, nose and/or throat. The highest rank of examination (rank 1) included a post-mortem examination, or examination of the throat or nose with endoscopy, or the ears by an otolaryngologist with adequate equipment and illumination. The lowest ranking included those where no details of examinations were provided.

Results

Study selection

Figure 1 illustrates the number of studies screened, assessed for eligibility and included in this review, with reasons for exclusions at each stage. In summary, 2448 references were

Table 1. Inclusion and exclusion criteria for systematic review of ear, nose or throat injuries, signs or symptoms associated with physical abuse or fabricated or induced illness

Inclusion criteria	Exclusion criteria
Studies of all observational evidence types	Formal consensus/expert opinion/personal practice/review article
English and non-English articles	Studies only involving accidental or iatrogenic ear nose or throat injuries
Patients aged <18 completed years	Management of injury papers
Ear is defined as the auricle (external ear) to the internal acoustic meatus including the pharyngotympanic tubes	Studies of complications or outcomes of abusive ear, nose or throat injuries
Nose is defined as the external nose to the nasopharynx including the sinuses	Studies where the population includes adults and children and the data for children cannot be extracted
Throat is defined as the oropharynx to the laryngopharynx including the lingual and palatine tonsils	Oral injuries
Ear, nose or throat injuries, signs or symptoms as a result of physical abuse or fabricated or induced illness	Bruising alone
Physical abuse or FII (confirmation of abuse rank 1–3)	Burns to throat or external nose
No physical abuse or fabricated or induced illness (confirmation rank A–B2)	Ear, nose or throat injuries as a result of sexual abuse
	Epistaxis as a result of asphyxiation
	Likelihood of physical abuse or fabricated or induced illness rank 4–5, or mixed rank
	Likelihood of no physical abuse or fabricated or induced illness C1–C2

screened, with 371 full-text articles reviewed and 38 studies included.^{25–63}

Study characteristics

Included studies were separated into those pertaining to physical abuse (24 studies),^{26,27,31,33,35,36,38–41,44,45,48–53,56,57,59,61–64} and those relevant to FII (14 studies).^{25,28–30,32,34,37,42,43,46,47,55,58,60} Within the physical abuse category, the studies were grouped into injuries to the throat (16 studies),^{26,27,33,35,36,39,40,44,45,48,49,51,52,56,57,59,64} ear (eight studies),^{31,35,36,38,41,50,53,62,63} and miscellaneous injuries (one study).⁶¹

Physical abuse: throat injuries

Table 3 summarises the characteristics of studies describing injuries to the throat as a result of physical abuse. There were 16 studies detailing throat injuries in 25 children, with an age range of 15 days to 2 years, median 4 months.^{26, 27, 33, 35, 36, 39, 40, 44, 45, 48, 49, 51, 52, 56, 57, 59, 64} These studies were predominantly case reports of neonates and infants with pharyngeal lacerations or perforations ($n = 20$). Typically, these patients presented with symptoms

including dysphagia, drooling, respiratory distress, haemoptysis or haematemesis, neck swelling and pyrexia. Surgical emphysema of the neck and/or chest was often present on examination ($n = 5$) and/or chest X-ray ($n = 7$); in addition, evidence of pneumomediastinum and/or pneumothorax was seen in four cases on chest X-ray.^{26,27,33,44,64} In some cases ($n = 3$), a contrast swallow study was undertaken, demonstrating leak of contrast from the hypopharynx or oesophagus.^{39,51,56} In the majority of reports ($n = 18$), rigid endoscopy confirmed the pharyngeal laceration or perforation.^{26,27,33,35,36,40,44,45,48,49,51,52,57,59,64}

A substantial number of these injuries ($n = 12$) were thought to be the result of forceful introduction of an object or finger through the child's oral cavity into the upper aerodigestive tract.^{26,27,39,40,44,45,56,59,64} However, the mechanism of injury remained unknown or unconfirmed in a considerable number of cases ($n = 11$).^{33,35,36,44,49,51,52,57,64}

Co-existent injuries were described in 52% ($n = 13$) of included children with pharyngeal injuries,^{26,33,35,36,39,40,44,48,49,52,56,59,64} most commonly rib fractures ($n = 7$);^{26,33,39,40,44,48,52} however, six did not report undergoing imaging for occult injuries.^{27,40,44,45,52,57} Four further children had associated bruising elsewhere on the body, and two had intracranial injury.^{35,36,40,48,56,64}

Table 2. Ranking of confirmation of physical abuse or fabricated or induced illness (FII) in children presenting with ear, nose or throat injuries, signs or symptoms thereof, studies ranking 1–3 were included; ranking of exclusion of physical abuse and FII in children presenting with ear, nose or throat injuries, signs or symptoms, studies ranking A–B2 were included. Ranking of quality of examination, studies were not excluded on these standards

Ranking	
1	Criteria used to confirm physical abuse or FII Physical abuse or FII confirmed at case conference, family, civil or criminal court proceedings, admitted by perpetrator or independently witnessed
2	Physical abuse or FII confirmed by stated criteria including multidisciplinary assessment
3	Physical abuse or FII defined by stated criteria
4	Physical abuse or FII stated but no supporting detail given
5	Suspected physical abuse or FII
A	Criteria used for active exclusion of physical abuse and FII from control group By multidisciplinary assessment or child protection, clinical investigation or forensic recreation of the scene or sudden death investigation
B1	By checking either the child abuse register or records of previous maltreatment
B2	By confirmation of organic disease or witnessed accidental causes
C1	Stated but no detail given
C2	No attempt made to exclude physical abuse and FII
Quality of ear examination	
1	Examination by otolaryngologist with appropriate illumination
2	Examination by doctor with appropriate illumination
3	No examination or no details provided
Quality of nasal examination	
1	Endoscopy with decongestant
2	Examination by otolaryngologist with appropriate illumination
3	Examination by doctor with appropriate illumination
4	No examination or no details provided
Quality of throat examination	
1	Endoscopy
2	Examination by otolaryngologist with appropriate illumination
3	Examination by doctor with appropriate illumination
4	No examination or no details provided

Physical abuse: ear injuries

Table 4 summarises the characteristics of studies describing ear injuries as a result of physical abuse. There were eight studies detailing injuries in 13 children, with an age range of 9 months to 12 years, median 2 years.^{31,35,36,38,41,50,53,62,63}

The majority of these injuries were inflicted to the external ear ($n = 11$) and included auricular deformity, abrasions, petechiae, lacerations and burns.^{31,38,41,50,53,62,63} However, traumatic tympanic membrane perforations were also described in six children.^{35,36,38,63}

Co-existent injuries were described in five children, with bruising, burns and intracranial injury being the most common injuries recorded.^{31,35,36,41,50,53,62} The location of

co-existent bruising in children with abusive ear injuries included the scrotum, buttocks, thighs, neck, calf, shoulder, forehead and back.^{41,50,62} Although only one child had concomitant fractures, investigations were only undertaken in six.

Physical abuse: miscellaneous injuries

Willgling *et al.* conducted a retrospective case series of 4340 children with suspected abuse over a 5-year period, with ages ranging from 1 day to 17.9 years (mean 5.6 years). Of these children, 1390 children encountered physical abuse; 641 (49%) of these children had evidence of injury to the head and neck region.⁶¹ The face and scalp were the most common

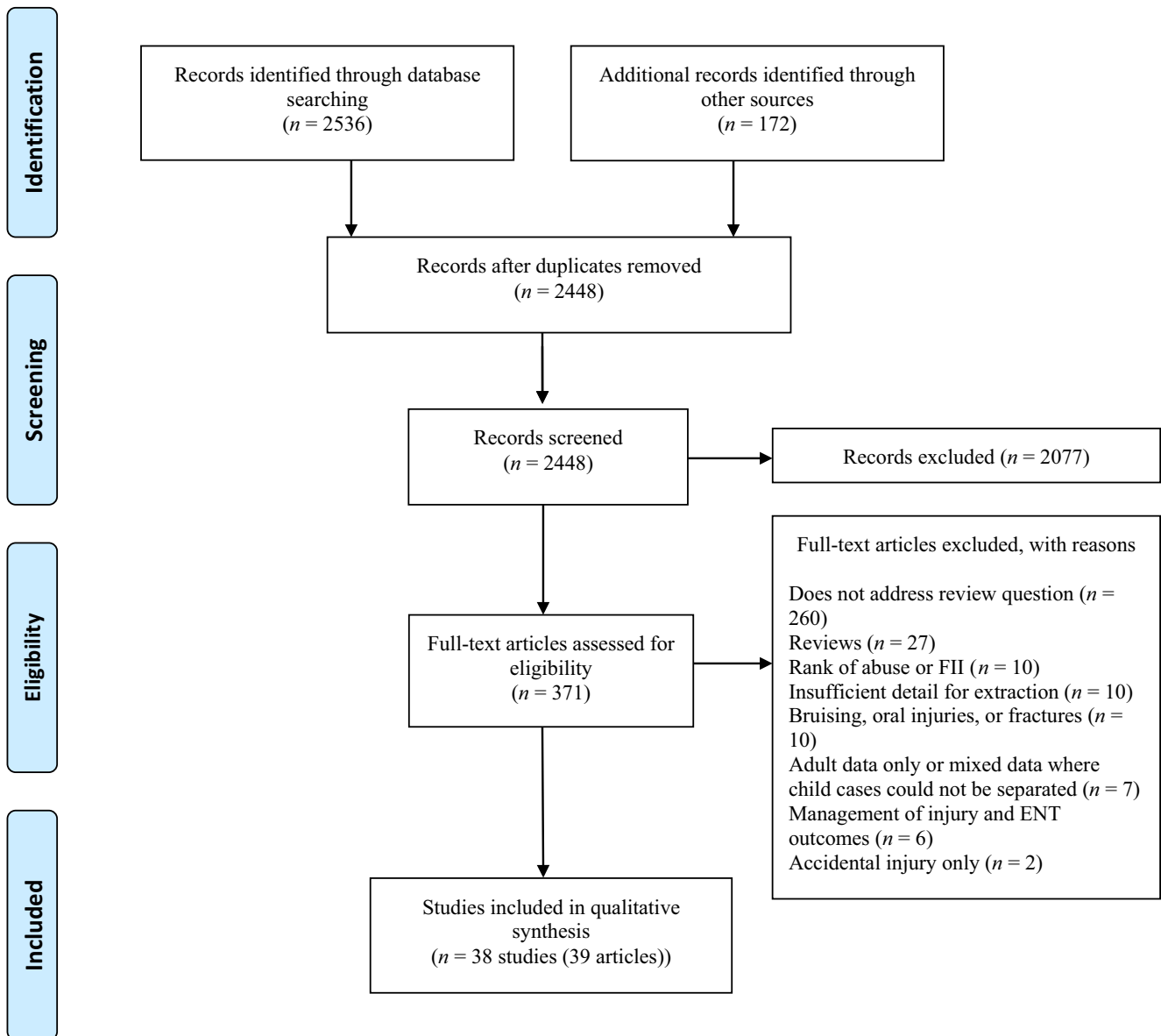


Fig. 1. PRISMA flow diagram demonstrating included and excluded studies and the reasons for exclusion in the systematic review of ENT injuries, signs or symptoms in relation to physical child abuse or fabricated or induced illness.

sites of injury, accounting for 64% and 25% of all head and neck injuries, respectively, with the most common mechanism being a blow by hand or blow with an object. The neck (16%), ears (6%) and nose (5%) were also common sites of injury in this particular case series. Overall, the majority of injuries were ecchymoses (62%) or abrasions (15%). Notably, this case series did not differentiate between injuries to the oral cavity and oropharynx, but delineated that when an injury was noted in the oral cavity, oropharynx or nasopharynx (that accounted for 2% of head and neck injuries), the majority were lacerations.

Fabricated or induced illness

Table 5 summarises the characteristics of FII studies that were included. There were 14 studies detailing FII in 84 children, with an age range of 7 months to 14 years, median 2 years (from detailed ages).^{25,28–30,32,34,37,42,43,46,47,55,58,60} The included studies comprised a case series of 71 children presenting with hearing loss, recurrent ear infections and sinusitis, and 13 case reports. The most common presenting symptom within the case reports was otorrhoea ($n = 7$), predominantly blood-stained or frank blood ($n = 5$) that

Table 3. Characteristics of physical abuse studies: throat injuries

Author, year, and country	Design	Number of children (age range) Rank of confirmation of abuse	Presenting features	Injuries present	Suspected mechanism of injury	Co-existent injuries
Bansal & Abramo, 1997, USA ²⁶	Case report	1 (2 months) Rank 1	Neck and chest swelling; muffled cry	Extensive subcutaneous emphysema over neck and chest Posterior oropharyngeal tear and trauma to supraglottis on direct laryngoscopy	Trauma to throat via oral cavity with fingers/bulb suction	Rib fractures
Barrett & Debelle, 1995, UK ²⁷	Case report	1 (4 months) Rank 1	Bleeding from the mouth and respiratory distress	Tear to right posterior pharyngeal wall; mucosal tear to left soft palate Surgical emphysema anterior chest wall Right pneumothorax and pneumomediastinum on chest X-ray Laceration at posterior pharyngo-oesophageal junction on direct laryngoscopy	Infant's dummy forced into mouth and retrieved	Not investigated
Dolgin <i>et al.</i> 1992, USA ³³	Case series (1 child with abuse)	1 (18 days) Rank 1	Haematemesis	Surgical emphysema on lateral soft tissue neck X-ray Pneumomediastinum on chest X-ray Laceration of posterior pharyngeal wall extending to prevertebral fascia on rigid oesophagoscopy	Unknown	Healing rib fractures
Kleinman <i>et al.</i> 1992, USA ³⁹	Case report	1 (5 weeks) Rank 3	Inspiratory stridor and respiratory distress	Posterior mediastinal mass on chest X-ray Contrast swallow: pharyngeal leak into retropharynx MRI elicited posterior mediastinal pseudocyst	Forceful introduction of spoon into mouth	Bilateral rib fractures Tibial and metatarsal fractures

Table 3. continued

Author, year, and country	Design	Number of children (age range) Rank of confirmation of abuse	Presenting features	Injuries present	Suspected mechanism of injury	Co-existent injuries
Krugman <i>et al.</i> 2007, USA ⁴⁰	Case reports	4 (3–4 months) Rank 1	Respiratory distress following inhalation of baby wipe (4)	Pharyngeal lacerations on direct laryngoscopy (3) Foreign body lodged in posterior oropharynx at autopsy (caused asphyxiation) (1)	Forceful insertion of baby wipes (4)	Bilateral distal femur fractures (1) Multiple bilateral rib fractures (1) Parietal bone fracture (1) Bruising of scalp and anterior left hip (1) Not investigated (1)
McDowell & Fielding, 1984, UK ⁴⁴	Case reports	2 (3–4 months) Rank 1	Dysphagia and haemoptysis (1) Irritability and pyrexia (1)	Surgical emphysema of neck (2) Perforation of posterior pharyngeal wall on direct laryngoscopy (2)	Forceful introduction of cooking spatula into mouth (1) Unknown (1)	Healing lower rib fractures (1) Not investigated (2)
Myer <i>et al.</i> 1988, USA ⁴⁸	Case report	1 (5 months) Rank 2	Respiratory distress	Bilateral vocal cord paralysis on flexible laryngoscopy	Shaking	Rib fractures Intracranial bleed
Ng <i>et al.</i> 1997, UK ⁴⁹	Case reports	2 (7 weeks–1.5 years) Rank 2	Stridor, drooling, respiratory distress, neck swelling (1) Asymptomatic (1)	Laceration of right hypopharynx with cotton wool-like material impacted into wound on pharyngoscopy Multiple needle puncture marks on neck and needles identified close to left carotid sheath	Precise mechanism unknown (2)	Torn frenulum Needles identified in neck, mediastinum, left temporal region and left forearm.
Pramuk <i>et al.</i> 2004, USA ⁵¹	Case report	1 (15 days) Rank 1	Increased oral and nasal secretions and alleged fall from parent's arms	Contrast swallow demonstrated extravasation of barium in hypopharynx Posterior pharyngeal tear from uvula to cricopharyngeus on pharyngoscopy	Unknown	None found

Table 3. continued

Author, year, and country	Design	Number of children (age range) Rank of confirmation of abuse	Presenting features	Injuries present	Suspected mechanism of injury	Co-existent injuries
Reece <i>et al.</i> 1996, USA ⁵²	Case reports	3 (18 days–4 months) Rank 1	Haematemesis (1) Oral bleeding (1) Acute dysphagia (1)	Laceration of posterior hypopharyngeal mucosa on direct laryngoscopy (2) Ulcerating lesion right posterior soft palate and retropharyngeal abscess on direct laryngoscopy (1) Torticollis, surgical emphysema and pneumomediastinum on chest X-ray. 2 cm perforation of the right hypopharyngeal wall at the pyriform fossa on pharyngoscopy; separate abrasion below the right tonsil	Unknown (3)	Healing rib fractures (1) Occipital linear fracture (1) Not investigated (2)
Ramnarayan <i>et al.</i> 2004, UK ⁶⁴	Case series	2 (6–10 months) Rank 2	Neck swelling, dyspnoea, drooling (1) Dyspnoeic and irritable since feed (1)	Face and neck swelling, gross surgical emphysema and pneumomediastinum on chest X-ray. Laryngeal oedema on CT neck. No abnormality seen on microlaryngobronchoscopy (delayed until extubation 10 days later)	Injury thought to be forceful insertion of blunt object into oropharynx (1) Unknown (1)	Small finger-shaped bruises on trunk (1) Bruises on neck, arm and wrist; bony fractures seen on skeletal survey (1)
Thevasagayam <i>et al.</i> 2007, UK ⁵⁶	Case report & literature review	1 (7 months) Rank 2	Dysphagia and irritability	CT neck demonstrated retropharyngeal air and soft tissue oedema Contrast swallow: leakage of contrast behind oesophagus at levels C3–C4 characteristic of hypopharyngeal perforation	Forceful insertion of plastic spoon into mouth	Facial bruising and petechiae on neck

Table 3. continued

Author, year, and country	Design	Number of children (age range) Rank of confirmation of abuse	Presenting features	Injuries present	Suspected mechanism of injury	Co-existent injuries
Wadhwa <i>et al.</i> 2013, India ⁵⁹	Case report	1 (2 years) Rank 1	Dysphagia	Excessive secretions in oral cavity and oropharynx Lateral soft tissue neck X-ray and chest X-ray showed radio-opaque shadows Rigid oesophagoscopy and removal of bolt from hypopharynx	Foreign bodies forced into child's throat	Foreign bodies on AXR, managed conservatively
Melzer & Baldassari, 2014, USA ⁴⁵	Case report	1 (3 months) Rank 1	Dysphagia, drooling and haemoptysis	Posterior oropharyngeal laceration extending to hypopharynx and upper oesophageal perforation on pharyngo-oesophagoscopy	Unidentified object stuck into oropharynx to silence patient	Not investigated
Grace & Grace, 1987; Grace <i>et al.</i> 1984, UK ^{35,36}	Cross-sectional survey	1 (18 months) Rank 1	Cardiac arrest (1)	Midline puncture wound in posterior pharyngeal wall on direct laryngoscopy	Unknown	Multiple fractures (unspecified) and intracranial injury
Tostevin <i>et al.</i> 1995, UK ⁵⁷	Comparative case series	2 (7 weeks–2 months) Rank 1	Oral bleeding and dyspnoea (2)	Torn upper gingival frenulum; right-sided neck lump; vocal cord cyst on laryngoscopy; right hypopharyngeal wall laceration on pharyngoscopy Laceration extending from right inferior tonsillar pole to pyriform fossa on pharyngoscopy	Unknown	CT head and skeletal survey: NAD
					Upper airway obstruction by ingestion of tissue that had to be removed	Not investigated

Table 4. Characteristics of physical abuse studies: ear injuries

Author, year, and country	Design	Number of children included (age range) Rank of confirmation of abuse	Presenting features	Injuries present	Suspected mechanism of injury	Co-existent injuries
Cuesta <i>et al.</i> 2012, Spain ³¹	Case report	1 (10 years) Rank 2	Lump in left ear of unknown duration	Cauliflower ear (auricular perichondritis) deformity	Trauma from repeated slapping	Several burn marks on body
Grace & Grace, 1987; Grace <i>et al.</i> 1984, UK ^{35,36}	Cross-sectional survey	4 (10 months–2 years) Rank 1	Bilateral bleeding ears (2)	Bilateral meatal lacerations and tympanic membrane perforations (2)	Injury with orange stick (1)	Not investigated (4)
			Unilateral (right) bleeding ear (1)	Unilateral tympanic membrane perforation and CSF leak	Unknown	Burn to hand, posterior pharyngeal tear, foreign body (open safety pin) in throat
			Hearing loss (1)	Ossicular discontinuity and conductive hearing loss	Trauma from blow	
Kini <i>et al.</i> 1997, USA ³⁸	Case report	1 (1 year) Rank 1	Sudden onset of 'fussiness' with right otorrhoea of 2-h duration	Erythematous pinna with multiple blisters and crusted white margin Greenish-white discharge from right ear canal Progressive tympanic membrane perforation	Chemical burn with acidic liquid	Not investigated

Table 4. continued

Author, year, and country	Design	Number of children included (age range) Rank of confirmation of abuse	Presenting features	Injuries present	Suspected mechanism of injury	Co-existent injuries
Lopez <i>et al.</i> 2014, USA ⁴¹	Prospective observational study	2 (9 months–30 months) Rank 2	Children that underwent intubation	Left ear abrasion (1) Right ear petechiae (1)	Unknown (2)	Bite mark to tongue, scrotal, buttocks and thigh bruising, right corneal abrasion with chemosis Bruising of neck, calf, shoulder, buttocks, laceration of tongue, intracranial haemorrhage, bilateral retinal haemorrhages, skull fractures
Porzionato <i>et al.</i> 2008, Italy ⁵⁰	Case report	1 (30 months) Rank 1	Cardiac arrest	Excoriations left ear	Beating and shaking	Haemorrhage of pharynx and retropharyngeal space on post-mortem, widespread bruising, intracranial bleed, jejunal perforation and pneumoperitoneum
Steele & Brennan, 2002, UK ⁵³	Prospective comparative case series	111 (10 months–15 years) 1 child abused (10 months) Rank 2	One child aged 10 months presented with unexplained bleeding from ear	Unexplained grazing of pinna and meatal opening	Trauma by blow	Grazing of chin Long-standing nappy rash Previous head injury
Willner <i>et al.</i> 1992, USA ⁶²	Case report	1 (3 years) Rank 2	Worsening left ear infection	Swelling and tissue destruction of left auricle	Trauma	Ecchymosis on forehead; abrasions on abdomen; circular healed scars on dorsum of right hand; right heel ulcer; ecchymosis on back; marked cerebral atrophy on CT

Table 4. continued

Author, year, and country	Design	Number of children included (age range) Rank of confirmation of abuse	Presenting features	Injuries present	Suspected mechanism of injury	Co-existent injuries
Wolter <i>et al.</i> 2012, Canada ⁶³	Case reports	2 (8–12 years) Rank 2	Altered mental status, ataxia and right-sided hearing loss (2)	Superficial burn to tragus, lobule and neck (1) Superficial burn to tragus and conchal bowl (1) Mucopurulent otorrhoea and tympanic membrane perforation (2) Left beating horizontal nystagmus (2) Right facial weakness (2) Right profound sensorineural hearing loss (2)	Caustic substance instilled into right ear (2)	Not stated (2)

Table 5. Characteristics of fabricated or induced illness studies

Author, year, and country	Design	Number of children included (age range) Rank of confirmation of FII	Presenting features	Injuries present	Induced illness	Reasons to suspect FII	Previous medical history
Awadallah <i>et al.</i> 2005, USA ²⁵	Case report	1 (14 years) Rank 2	Facial pain; rhinorrhoea; persistent fevers	Nil	Chronic rhinosinusitis	Parental eagerness for more tests/procedures Discrepancies in history given by mother and patient Lack of objective evidence for chronic rhinosinusitis	11 surgical sinus procedures Reflux, multiple GI endoscopies and gastric fundoplication (aged 9) Overall, 40 operations since age 8 Extensive psychiatric history: oppositional defiant disorder; bipolar disorder; attention deficit disorder
Tamay <i>et al.</i> 2007, Turkey ⁵⁵	Case report	1 (6 years) Rank 2	Oral lesions and bleeding	Purple discoloration and swelling of lips Oral aphthous ulcers Oral mucosal erosions and bleeding Burns in pharynx and oesophagus on endoscopy	Allergic reaction	Persistent recurrence of lesions despite healing	On 19 medications None relevant

Table 5. continued

Author, year, and country	Design	Number of children included (age range)	Rank of confirmation of FII	Presenting features	Injuries present	Induced illness	Reasons to suspect FII	Previous medical history
Feldman <i>et al.</i> 2002, USA ³⁴	Case series	71 (not given)	Rank 2	Deafness, recurrent ear infections and sinusitis	Nil	Acute/chronic rhinosinusitis Hearing loss	Reports by parents of severe hearing loss in spite of normal otoscopy and normal hearing tests Normal radiological investigations (e.g. CT sinuses) Claims of immune deficiency despite no objective medical evidence	None relevant
Manning <i>et al.</i> 1990, USA ⁴³	Case report	1 (2 years)	Rank 2	Persistent bilateral bloody otorrhoea	Bilateral tympanic membrane perforations	Chronic suppurative otitis media	Persistent bloody otorrhoea despite treatment with systemic and topical antibiotics and surgical exploration	Cleft palate repair and bilateral myringotomy and tympanostomy tube procedures; during this presentation had bilateral tympanostomy
Mira <i>et al.</i> 1997, USA ⁴⁷	Case report	1 (3 years)	Rank 1	Persistent right-sided CSF otorrhoea	No evidence of CSF leak (after initial repair surgery)	Post-traumatic CSF otorrhoea	No acute fracture lines or abnormal communication on CT imaging No CSF leak noted during revision surgery Well-healing wound with no collections	Failure to thrive Right parietal skull fracture (from RTA), bacterial meningitis, right CSF leak repair and lumbar drain placement

Table 5. continued

Author, year, and country	Design	Number of children included (age range)	Rank of confirmation of FII	Presenting features	Injuries present	Induced illness	Reasons to suspect FII	Previous medical history
DiBiase <i>et al.</i> 1996, USA ³²	Case report	1 (3 years)	Rank 1	Chronic left-sided otorrhoea	Recurrent sepsis requiring ITU support	Chronic suppurative otitis media	Recurrent sepsis despite antibiotic therapy Blood cultures yielded <i>E. coli</i> and <i>Candida</i>	Two previous insertions of grommets and bilateral tympanomastoidectomy
Bennett <i>et al.</i> 2005, UK ²⁸	Case report	1 (8 months)	Rank 1	Persistent left-sided sticky and blood-stained otorrhoea		Recurrent acute otitis media	Normal EUA left ear Bubbles in ear discharge Ear discharge extending from conchal bowl to outer part of EAC Ear discharge contained amylase (salivary fistula excluded)	None relevant
Magnay <i>et al.</i> 1994, UK ⁴²	Case report	1 (7 months)	Rank 1	Nasal lesions; diarrhoea; denuded anal lesion; cutaneous lesions	Circumferential excoriation on inner aspect of both nostrils	Granulomatous disorder	Nasal lesions appeared traumatic Normal colonoscopy CRP not elevated	Gastroduodenoscopy and laparotomy
Milroy <i>et al.</i> 1999, UK ⁴⁶	Case report	1 (21 months)	Rank 1	Cardiorespiratory arrest (mortality)	Balloon found in oropharynx Intra-alveolar haemosiderin on post-mortem examination	Upper airway obstruction by foreign body	Post-mortem examination suggested multiple episodes of deliberate partial smothering	Five episodes of attendance to emergency department with alleged choking or apnoea

Table 5. continued

Author, year, and country	Design	Number of children included (age range)	Rank of confirmation of FII	Presenting features	Injuries present	Induced illness	Reasons to suspect FII	Previous medical history
White <i>et al.</i> 1985, USA ⁶⁰	Case report	1 (11 months)	Rank 1	Left-sided bloody otorrhoea	Left EAC filled with blood Multiple haematomas on forehead, chest and limbs	Acute suppurative otitis media	Haematomas not consistent with ear infection Serum warfarin elevated to pharmacological level Normal blood tests (including coagulation studies) Normal ENT examination Analysis of 'blood' found it to be dyed liquid	Gastroenteritis with dehydration Intermittent vomiting Failure to thrive
Trajber <i>et al.</i> 1996, Latin America ⁵⁸	Case report	1 (3 years)	Rank 1	Episodes of bleeding from ears, nose, mouth, haematuria with loss of consciousness	No injuries present	Bleeding disorder	Normal ENT examination Normal ENT examination Analysis of 'blood' found it to be dyed liquid	Alleged road traffic accident
Guandolo, 1985, USA ³⁷	Case report	1 (5 years)	Rank 2	Intractable otalgia and nasal congestion	No injuries present	Recurrent acute otitis media	Normal ENT examination	Afebrile generalised seizures, migraine, hyperallergenic, chronic spontaneous patellar dislocation (all alleged)
Bourchier, 1983, New Zealand ²⁹	Case report	1 (2 years)	Rank 2	Bleeding from ears	No injuries present	Acute otitis media	Normal ENT examination Blood tests including coagulation studies normal Blood from ears different to patient's blood group	Haematemesis and melena with normal investigations
Brown <i>et al.</i> 2014, USA ³⁰	Case reports	1 (13 months)	Rank 2	Feeding aversion; tongue tie; noisy breathing	No injuries present	Swallowing disorder	Symptoms resolved on removal of child from parent Normal ENT examination	Food allergies, constipation, failure to thrive, reflux, apnoea, developmental delay

was persistent and recalcitrant to therapeutic interventions.^{28,29,32,43,47,60}

These children typically had extensive medical histories including failure to thrive ($n = 3$), allergies or immunodeficiency ($n = 3$), mental health or developmental problems ($n = 2$), and they had often had multiple invasive investigations and surgical interventions ($n = 6$).

Discussion

Summary of main results

This systematic review describes the injuries associated with physical child abuse and the presenting features of FII within the otolaryngology setting. Pharyngeal injuries were the most frequent ENT injury resulting from physical abuse identified in this review. Children with abusive pharyngeal injuries tended to be <1 year old and had co-existent injuries (from bruising to rib fractures). Children with ENT signs and symptoms as a result of FII tended to present with a variety of signs and symptoms such as persistent or recurrent otorrhoea that was resistant to treatment.

Context of current literature

Pharyngeal perforation is rare in the paediatric population.^{56,65,66} Non-accidental injury should be considered as a possibility when this is encountered in clinical practice, particularly in neonates and infants.⁵⁶ Non-accidental injury is the commonest reported cause of this condition after exclusion of iatrogenia (from suctioning, intubation, nasogastric tube insertion) and external trauma.^{56,67–69} Accidental pharyngeal injuries described in the paediatric population are largely confined to children over 1 year old.^{56,57,70–73} These are typically the result of traumatic penetration with a foreign body from falling while brushing teeth or swallowing glass splinters; one report even describes a fizzy drink exploding its cap into the child's mouth while the child attempts to open it using their teeth.^{57,70–73} However, we cannot categorically label these cases as accidental as the literature rarely specifies the details of how abuse was excluded as a potential cause.

It is important to note that children with pharyngeal injuries (abusive or accidental in aetiology) can be difficult to detect, may appear initially well, and can present symptomatically up to 24 h later.^{57,72} Dysphagia is the commonest presenting symptom and other presenting features include drooling, respiratory distress, haemoptysis, haematemesis, neck swelling and pyrexia. Surgical emphysema is an important clinical sign.^{56,64}

This review stresses that external ear injuries including haematoma, swelling or deformity of the auricle, lacerations,

abrasions, petechiae and burns, and traumatic tympanic membrane perforations, may be indicative of physical abuse. However, it is important to note that although rare, spontaneous auricular haematoma has been described in the literature. Mathur *et al.*⁷⁴ present a case of a 5-week-old boy with a spontaneous auricular haematoma with no history of trauma, no evidence of bleeding diathesis and no evidence of abuse on skeletal survey, CT head or ophthalmic examination: three key considerations in a child presenting in this manner.

In a prospective survey by Steele and Brennan, no accidental bilateral ear injuries were identified amongst the 111 included children presenting to the emergency department with presumed accidental ear injuries.⁵³ Thus, it may be postulated that ear injuries in children that are bilateral are uncommon and should prompt a non-accidental injury evaluation.

Steele and Brennan also highlight that those aged <1 year rarely present with accidental ear injuries.⁵³ The only infant (aged 10 months) included in their study had unexplained bleeding from his ear and unexplained grazing of his external auditory meatus, pinna and chin. These injuries were later confirmed as abusive in aetiology as the child subsequently presented with multiple additional injuries.⁵³ The rarity of accidental ear injuries in infants may be a reflection of many children <1 year old being pre-mobile and therefore less likely to have accidental falls. In addition, accidental injury in this age group tends to occur predominantly on the front of the body, particularly over the 'facial T', or to the occiput as the child falls directly forwards or backwards.^{75,76} Bruising to the ear is rare at all ages, suggesting this area is infrequently injured.⁷⁶ This highlights the importance of always considering the child's age, developmental stage and the plausibility of any explanation provided when assessing a child with an injury.

Children with FII do present to the otolaryngologist, particularly in the outpatient clinic setting. Although the parents or caregivers report a variety of symptoms in their children, this review ascertained persistent otorrhoea to be a pertinent presenting complaint and in particular blood-stained discharge. Characteristically, there is a discrepancy between the history and clinical examination or investigation findings, where the child's clinical presentation is not adequately explained by a confirmed illness, and the situation is impacting upon the child's well-being or health.

Children suffering FII included in this review often had extensive medical histories consisting of a variety of unusual signs and symptoms including unexplained failure to thrive and alleged allergies, and they had often undergone numerous invasive procedures, which is consistent with the literature.^{77–81} As noted in the included study by Feldman *et al.*,³⁴ up to 43% of FII cases had undergone

otolaryngologic surgery. Key presentations of FII described in the literature include failure to thrive induced by withholding food; alleged allergies used as a reason to withhold food; allegation or fabrication of medical symptoms; and active interference through poisoning or disrupting medical treatment.^{77–81} Therefore, a detailed chronology of the child's involvement with health care is an essential first step and may highlight areas of concern.⁸²

Concerning features for the identification of child abuse include other injuries with a high specificity for abuse such as bruising to the ears, neck, genitalia or hands;^{21,76} clusters or patterned bruises;^{21,76} unexplained intracranial injury;^{83,84} fractures in non-mobile infants or rib fractures in the absence of major trauma;^{18,83} multiple fractures at different stages of healing;⁸⁵ traumatic injury without appropriate history;⁸⁶ co-existent risk factors such as domestic violence or substance misuse in the parents;⁸⁷ and injuries that are inconsistent with the child's developmental age or mechanism described.⁸⁸

Strengths and limitations

This systematic review's methods were robust and rigorous clinical standards were applied. Thus, the included studies represent the highest quality of evidence available in this field. It was a disappointment that so few large-scale comparative studies of accidental and non-accidental ENT injuries were conducted, thus precluding a meta-analysis of specific injuries or clinical features. It is unclear whether this indicates a failure to recognise child maltreatment by otolaryngologists or a lack of research in this field; however, there are clearly injuries which should prompt child maltreatment assessments.

Although stringent standards for the confirmation of maltreatment were applied to minimise the risk of circularity with regard to diagnosing maltreatment, it is impossible to exclude the possibility that the injuries in question did contribute to the final decision made by the multidisciplinary child protection team. In the absence of a 'gold standard' test for confirming abuse, ensuring that the diagnosis of maltreatment has been made having considered all of the relevant medical and social factors is a robust way of confirming maltreatment. In addition, while some authors provided considerable detail with regard to the ENT examination undertaken, others simply alluded to an 'ENT examination'. Although we have categorised the quality of examination amongst the included studies, it would have been preferable to limit the review to those with full operative or post-mortem details.

While traumatic ENT injuries, such as foreign body injuries, are frequently reported in children - child abuse is rarely recorded as a potential mechanism of injury.⁸⁹ The

failure of many paediatric ENT epidemiology studies to detail the mechanisms of injury makes it extremely difficult to determine the true prevalence of abusive ENT injuries. Where assault is explored as a mechanism, for instance amongst adolescents, children who have been abused are explicitly excluded, thus further preventing a detailed analysis of relevant social and physical features.⁹⁰ This review was limited to children who presented with ENT injuries that may be due to maltreatment, rather than focussing on the long-term outcomes. However, it must be remembered that some children may present with longer term effects, caused directly or indirectly by early childhood maltreatment such as vocal cord paralysis from excessive crying or screaming.⁹¹

Implications for clinical practice

Child protection is everybody's responsibility. It is imperative that all clinicians in contact with children are familiar with the common signs and risk factors for child maltreatment. Given that the head and neck is one of the most commonly injured sites in abused children, otolaryngologists must be vigilant and consider the possibility of maltreatment in children presenting with such injuries.

Detecting and reporting suspected child maltreatment is extremely challenging. Prioritising the safety of the child while maintaining the trust of parents or caregivers can be particularly difficult. However, despite its challenges, early recognition and notification of maltreatment is essential to prevent repetition and escalation of injury. This review has not been prescriptive in what the otolaryngologist should do if they suspect abuse as this is beyond the scope of this article. That noted, all clinicians should familiarise themselves with their local child protection protocols and policies, in addition to national child protection guidelines.⁸²

Conclusion

This review highlights that children who have experienced physical abuse or FII do present with injuries, signs and symptoms to the otolaryngologist in both emergency and outpatient settings. Pharyngeal injuries, or injuries to the external ear, presenting in young children without an explicit history of witnessed injury should prompt a child protection referral for full evaluation. Likewise, children who present with recurrent, or apparently intractable, symptoms and signs despite appropriate treatment should raise the possibility of FII, and discussion with a child protection specialist is advised. Recognition of possible child maltreatment and instigation of appropriate safeguarding measures are of paramount importance to

otolaryngologists, who have the potential to identify these children in their practice.

Keypoints

- Children with maltreatment in the form of physical abuse or fabricated or induced illness do present to the otolaryngologist.
- Non-accidental injury must be considered in children presenting with pharyngeal perforations.
- External ear injuries in infants, bilateral ear injuries, in addition to traumatic tympanic membrane perforations may be indicative of physical abuse.
- Fabricated or induced illness may have a multitude of presenting features including otorrhoea that is recalcitrant to therapeutic interventions. There is usually an extensive medical history and discrepancy between the alleged history and findings from clinical examination and investigations.
- The recognition of possible child maltreatment and instigation of appropriate safeguarding measures is of paramount importance to otolaryngologists.

Conflict of interest

None declared.

References

- Osman E.Z., Aneeshkumar M.K. & Clarke R.W. (2005) Paediatric otolaryngology services in the UK: a postal questionnaire survey of ENT consultants. *J. Laryngol. Otol.* **119**, 259–263
- Leavitt E.B., Pincus R.L. & Bukachevsky R. (1992) Otolaryngologic manifestations of child abuse. *Arch. Otolaryngol. Head Neck Surg.* **118**, 629–631
- Petska H.W., Sheets L.K. & Knox B.L. (2013) Facial bruising as a precursor to abusive head trauma. *Clin. Pediatr.* **52**, 86–88
- Gilbert R., Widom C.S., Browne K. *et al.* (2009) Burden and consequences of child maltreatment in high-income countries. *Lancet* **373**, 68–81
- Sheets L.K., Leach M.E., Koszewski I.J. *et al.* (2013) Sentinel injuries in infants evaluated for child physical abuse. *Pediatrics* **131**, 701–707
- Gilbert R., Kemp A., Thoburn J. *et al.* (2009) Recognising and responding to child maltreatment. *Lancet* **373**, 167–180
- World Health Organization. (2015) Child maltreatment. [www document]. URL http://www.who.int/topics/child_abuse/en/ [accessed on 14 December 2015]
- Harker L., Ju'tte S., Murphy T. *et al.* (2013) How safe are our children?. [www document]. URL <https://www.nspcc.org.uk/globalassets/documents/research-reports/how-safe-children-2013-report.pdf> [accessed on 16 May 2016]
- Felitti V.J., Anda R.F., Nordenberg D. *et al.* (1998) Relationship of childhood abuse and household dysfunction to many of the leading causes of death in adults: the Adverse Childhood Experiences (ACE) Study. *Am. J. Prev. Med.* **14**, 245–258
- Munro E.R., Brown R. & Marful E. (2011) *Safeguarding Children Statistics: The Availability and Comparability of Data in the UK. Research Brief DFE-RB153*. Childhood Wellbeing Research Centre, Leicestershire
- US Department of Health and Human Services. (2009) Child maltreatment 2009. Washington
- Department for Children Schools and Family. (2013) Working together to safeguard children: A guide to inter-agency working to safeguard and promote the welfare of children
- Department for Children Schools and Family. (2008) Safeguarding children in whom illness is fabricated or induced. [www document]. URL http://www.gov.uk/government/uploads/system/uploads/attachment_data/file/190235/DCSF-00277-2008.pdf [accessed on 16 May 2016]
- Bools C., Neale B. & Meadow R. (1994) Munchausen syndrome by proxy: a study of psychopathology. *Child Abuse Negl.* **18**, 773–788
- Sheridan M.S. (2003) The deceit continues: an updated literature review of Munchausen Syndrome by Proxy. *Child Abuse Negl.* **27**, 431–451
- Alicandri-Ciuffelli M., Moretti V., Ruberto M. *et al.* (2012) Otolaryngology fantastica: the ear, nose, and throat manifestations of Munchausen's syndrome. *Laryngoscope* **122**, 51–57
- Centre for Reviews and Dissemination. (2009) Systematic Reviews: CRD's guidance for undertaking systematic reviews in health care. [www document]. URL http://www.york.ac.uk/inst/crd/index_guidance.htm [accessed on 1 March 2014]
- Kemp A.M., Dunstan F., Harrison S. *et al.* (2008) Patterns of skeletal fractures in child abuse: systematic review. *BMJ* **337**, a1518
- Maguire S. & Mann M. (2013) Systematic reviews of bruising in relation to child abuse-what have we learnt: an overview of review updates. *Evid. Based Child Health* **8**, 255–263
- Maguire S.A., Upadhyaya M., Evans A. *et al.* (2013) A systematic review of abusive visceral injuries in childhood - their range and recognition. *Child Abuse Negl.* **37**, 430–445
- Maguire S., Mann M.K., Sibert J. *et al.* (2005) Are there patterns of bruising in childhood which are diagnostic or suggestive of abuse? A systematic review *Arch. Dis. Child.* **90**, 182–186
- Moher D., Liberati A., Tetzlaff J. *et al.* (2009) Preferred reporting items for systematic reviews and meta-analyses: the PRISMA statement. *PLoS Med.* **6**, e1000097
- Maguire S., Hunter B., Hunter L. *et al.* (2007) Diagnosing abuse: a systematic review of torn frenum and other intra-oral injuries. *Arch. Dis. Child.* **92**, 1113–1117
- Rees P., Kemp A., Carter B. *et al.* (2016) A systematic review of the probability of asphyxia in children aged <2 years with unexplained epistaxis. *J. Pediatr.* **168**, 178–184
- Awadallah N., Vaughan A., Franco K. *et al.* (2005) Munchausen by proxy: a case, chart series, and literature review of older victims. *Child Abuse Negl.* **29**, 931–941
- Bansal B.C. & Abramo T.J. (1997) Subcutaneous emphysema as an uncommon presentation of child abuse. *Am. J. Emerg. Med.* **15**, 573–575
- Barrett T.G. & DeBelle G.D. (1995) Near-fatal aspiration of a child's dummy: design fault or deliberate injury? *J. Accid. Emerg. Med.* **12**, 154–155

- 28 Bennett A.M., Bennett S.M., Prinsley P.R. *et al.* (2005) Spitting in the ear: a falsified disease using video evidence. *J. Laryngol. Otol.* **119**, 926–927
- 29 Bouchier D. (1983) Bleeding ears: case report of Munchausen syndrome by proxy. *Aust. Paediatr. J.* **19**, 256–257
- 30 Brown A.N., Gonzalez G.R., Wiester R.T. *et al.* (2014) Care taker blogs in caregiver fabricated illness in a child: a window on the caretaker's thinking? *Child Abuse Negl.* **38**, 488–497
- 31 Cuesta L., Betlloch I., Bañals J. *et al.* (2012) "Cauliflower ear" in a teenager: a possible sign of child abuse. *Pediatr. Dermatol.* **29**, 226–227
- 32 DiBiase P., Timmis H., Bonilla J.A. *et al.* (1996) Munchausen syndrome by proxy complicating ear surgery. *Arch. Otolaryngol. Head Neck Surg.* **122**, 1377–1380
- 33 Dolgin S.R., Kumar N.R., Wykoff T.W. *et al.* (1992) Conservative medical management of traumatic pharyngoesophageal perforations. *Ann. Otol. Rhinol. Laryngol.* **101**, 209–215
- 34 Feldman K.W., Stout J.W. & Inglis A.F. Jr (2002) Asthma, allergy, and sinopulmonary disease in pediatric condition falsification. *Child Maltreat.* **7**, 125–131
- 35 Grace A. & Grace S. (1987) Child abuse within the ear, nose and throat. *J. Otolaryngol.* **16**, 108–111
- 36 Grace A., Kalinkiewicz M. & Drake-Lee A.B. (1984) Covert manifestations of child abuse. *BMJ* **289**, 1041–1042
- 37 Guandolo V.L. (1985) Munchausen syndrome by proxy: an outpatient challenge. *Pediatrics* **75**, 526–530
- 38 Kini N., Lazoritz S., Ott C. *et al.* (1997) Caustic instillation into the ear as a form of child abuse. *Am. J. Emerg. Med.* **15**, 442–443
- 39 Kleinman P.K., Spevak M.R. & Hansen M. (1992) Mediastinal pseudocyst caused by pharyngeal perforation during child abuse. *Am. J. Roentgenol.* **158**, 1111–1113
- 40 Krugman S.D., Lantz P.E., Sinal S. *et al.* (2007) Forced suffocation of infants with baby wipes: a previously undescribed form of child abuse. *Child Abuse Negl.* **31**, 615–621
- 41 Lopez M.R., Abd-Allah S., Deming D.D. *et al.* (2014) Oral, jaw, and neck injury in infants and children from abusive trauma or intubation? *Pediatr. Emerg. Care* **30**, 305–310
- 42 Magnay A.R., Debelle G., Proops D.W. *et al.* (1994) Munchausen syndrome by proxy unmasked by nasal signs. *J. Laryngol. Otol.* **108**, 336–338
- 43 Manning S.C., Casselbrant M. & Lammers D. (1990) Otolaryngologic manifestations of child abuse. *Int. J. Pediatr. Otorhinolaryngol.* **20**, 7–16
- 44 McDowell H.P. & Fielding D.W. (1984) Traumatic perforation of the hypopharynx - an unusual form of abuse. *Arch. Dis. Child.* **59**, 888–889
- 45 Melzer J.M. & Baldassari C.M. (2014) Hypopharyngeal injury in an infant from non-accidental trauma. *Int. J. Pediatr. Otorhinolaryngol.* **78**, 2312–2313
- 46 Milroy C.M. (1999) Munchausen syndrome by proxy and intra-alveolar haemosiderin. *Int. J. Legal Med.* **112**, 309–312
- 47 Mra Z., McCormick J.A. & Poje C.P. (1997) Persistent cerebrospinal fluid otorrhea: a case of Munchausen's syndrome by proxy. *Int. J. Pediatr. Otorhinolaryngol.* **41**, 59–63
- 48 Myer C.M. & Fitton C.M. (1988) Vocal cord paralysis following child abuse. *Int. J. Pediatr. Otorhinolaryngol.* **15**, 217–220
- 49 Ng C.S., Hall C.M. & Shaw D.G. (1997) The range of visceral manifestations of non-accidental injury. *Arch. Dis. Child.* **77**, 167–174
- 50 Porzionato A., Macchi V., Aprile A. *et al.* (2008) Cervical soft tissue lesions in the shaken infant syndrome: a case report. *Med. Sci. Law* **48**, 346–349
- 51 Pramuk L.A., Sirotnak A. & Friedman N.R. (2004) Esophageal perforation preceding fatal closed head injury in a child abuse case. *Int. J. Pediatr. Otorhinolaryngol.* **68**, 831–835
- 52 Reece R.M., Arnold J. & Splain J. (1996) Pharyngeal perforation as a manifestation of child abuse. *Child Maltreat.* **1**, 364–367
- 53 Steele B.D. & Brennan P.O. (2002) A prospective survey of patients with presumed accidental ear injury presenting to a paediatric accident and emergency department. *Emerg. Med. J.* **19**, 226–228
- 54 Stricker T., Lips U. & Sennhauser F. (2002) Oral bleeding: child abuse alert. *J. Paediatr. Child Health* **38**, 528–529
- 55 Tamay Z., Akcay A., Kilic G. *et al.* (2007) Corrosive poisoning mimicking cicatricial pemphigoid: munchausen by proxy. *Child Care Health Dev.* **33**, 496–499
- 56 Thevasagayam M.S., Siemers M.D., Debelle G.D. *et al.* (2007) Paediatric hypopharyngeal perforation: child abuse until proved otherwise? *Int. J. Pediatr. Otorhinolaryngol.* **71**, 665–670
- 57 Tostevin P.M., Hollis L.J. & Bailey C.M. (1995) Pharyngeal trauma in children accidental and otherwise. *J. Laryngol. Otol.* **109**, 1168–1175
- 58 Trajber Z., Murahovschi J., Candio S. *et al.* (1996) Munchausen's syndrome by proxy: a case report of a girl with a recurrent factitious bleeding ear. *J. Pediatr.* **72**, 35–39
- 59 Wadhwa R., Kalra V., Gulati S.P. *et al.* (2013) Child abuse: multiple foreign bodies in gastrointestinal tract. *Int. J. Pediatr. Otorhinolaryngol.* **77**, 287–289
- 60 White S.T., Voter K. & Perry J. (1985) Surreptitious warfarin ingestion. *Child Abuse Negl.* **9**, 349–352
- 61 Willging J.P., Bower C.M. & Cotton R.T. (1992) Physical abuse of children: a retrospective review and an otolaryngology perspective. *Arch. Otolaryngol. Head Neck Surg.* **118**, 584–590
- 62 Willner A., Ledereich P.S. & De Vries E.J. (1992) Auricular injury as a presentation of child abuse. *Arch. Otolaryngol. Head Neck Surg.* **118**, 634–637
- 63 Wolter N.E., Cushing S.L., Das-Purkayastha P.K. *et al.* (2012) Non-accidental caustic ear injury: two cases of profound cochleo-vestibular loss and facial nerve injury. *Int. J. Pediatr. Otorhinolaryngol.* **76**, 145–148
- 64 Ramnarayan P., Qayyum A., Tolley N. *et al.* (2004) Subcutaneous emphysema of the neck in infancy: under-recognized presentation of child abuse. *J. Laryngol. Otol.* **118**, 468–470
- 65 Butler A.P., O'Rourke A.K., Wood B.P. *et al.* (2005) Acute external laryngeal trauma: experience with 112 patients. *Ann. Otol. Rhinol. Laryngol.* **114**, 361–368
- 66 Soose R.J., Simons J.P. & Mandell D.L. (2006) Evaluation and management of pediatric oropharyngeal trauma. *Arch. Otolaryngol. Head Neck Surg.* **132**, 446–451
- 67 Meyers A.D., Lillydahl P. & Brown G. (1978) Hypopharyngeal perforations in neonates. *Arch. Otolaryngol.* **104**, 51–54
- 68 Clarke T.A., Coen R.W., Feldman B. *et al.* (1980) Esophageal perforations in premature infants and comments on the diagnosis. *Am. J. Dis. Child.* **134**, 367–368
- 69 Eklöf O., Löhr G. & Okmian L. (1969) Submucosal perforation of the esophagus in the neonate. *Acta Radiol. Diagn.* **8**, 187–192
- 70 Okada T., Sasaki F. & Todo S. (2004) Perforation of the piriform recessus by a swallowed glass splinter presenting as pneumomediastinum in a child. *Pediatr. Surg. Int.* **20**, 643–645

- 71 Ratan S.K., Rattan K.N., Malhotra N. *et al.* (2005) Complicated hypopharyngeal perforation in a child owing to internal penetrating trauma by a knitting needle parents beware. *J. Otolaryngol.* **34**, 267–269
- 72 Rowley H., Christian J. & Dennis A. (1995) Pharyngeal perforation: an easily missed finding following intra-oral injury. *J. Accid. Emerg. Med.* **12**, 145–146
- 73 Goldenberg D., Golz A. & Joachims H.Z. (1997) Retropharyngeal abscess: a clinical review. *J. Laryngol. Otol.* **111**, 546–550
- 74 Mathur S., Clarke R. & John C.M. (2009) ‘Spontaneous’ auricular haematoma: a rare differential diagnosis of NAI. *Acta Paediatr.* **98**, 928
- 75 Chang L. & Tsai M. (2007) Craniofacial injuries from slip, trip, and fall accidents of children. *J. Trauma* **63**, 70–74
- 76 Kemp A.M., Dunstan F., Nuttall D. *et al.* (2015) Patterns of bruising in preschool children - a longitudinal study. *Arch. Dis. Child.* **100**, 426–431
- 77 Gray J. & Bentovim A. (1996) Illness induction syndrome: paper I—A series of 41 children from 37 families identified at the great ormond street hospital for children NHS trust. *Child Abuse Negl.* **20**, 655–673
- 78 Meadow R. (1977) Munchausen syndrome by proxy. The hinterland of child abuse. *Lancet* **2**, 343–345
- 79 Rogers D., Tripp J., Bentovim A. *et al.* (1976) Nonaccidental poisoning: an extended syndrome of child abuse. *BMJ* **1**, 793–796
- 80 Rosenberg D.A. (1987) Web of deceit: a literature review of Munchausen syndrome by proxy. *Child Abuse Negl.* **11**, 547–563
- 81 Warner J.O. & Hathaway M.J. (1984) Allergic form of Meadow’s syndrome (Munchausen by proxy). *Arch. Dis. Child.* **59**, 151–156
- 82 Royal College of Paediatrics and Child Health. (2015) *Child Protection Companion*, 2nd edn. Royal College of Paediatrics and Child Health, London
- 83 Maguire S.A., Kemp A.M., Lumb R.C. *et al.* (2011) Estimating the probability of abusive head trauma: a pooled analysis. *Pediatrics* **128**, e550–e564
- 84 Maguire S., Pickerd N., Farewell D. *et al.* (2009) Which clinical features distinguish inflicted from non-inflicted brain injury? A systematic review *Arch. Dis. Child.* **94**, 860–867
- 85 Leventhal J.M., Thomas S.A., Rosenfield N.S. *et al.* (1993) Fractures in young children: distinguishing child abuse from unintentional injuries. *Am. J. Dis. Child.* **147**, 87–92
- 86 Hettler J. & Greenes D.S. (2003) Can the initial history predict whether a child with a head injury has been abused? *Pediatrics* **111**, 602–607
- 87 Cleaver H., Unell I. & Aldgate J. (2011) *Child Abuse: Parental Mental Illness, Learning Disability, Substance Misuse and Domestic Violence. Children’s Needs – Parenting Capacity*. The Stationary Office, London
- 88 Schwend R.M., Werth C. & Johnston A. (2000) Femur shaft fractures in toddlers and young children: rarely from child abuse. *J. Pediatr. Orthop.* **20**, 475–481
- 89 Chotigavanich C., Ballali S., Foltran F. *et al.* (2012) Foreign bodies injuries in children: analysis of Thailand data. *Int. J. Pediatr. Otorhinolaryngol.* **76**, S80–S83
- 90 Cheng T.L., Schwarz D., Brenner R.A. *et al.* (2003) Adolescent assault injury: risk and protective factors and locations of contact for intervention. *Pediatrics* **112**, 931–938
- 91 Drake A.F., Makielski K., McDonaldbell C. *et al.* (1995) Two new otolaryngologic findings in child abuse. *Arch. Otolaryngol. Head Neck Surg.* **121**, 1417–1420

Appendix 1 Databases searched for systematic review of children with ENT injuries, signs, or symptoms consistent with child abuse or fabricated or induced illness

Databases searched	Time period searched
Cochrane Central Register of Controlled Trials	1960–2014*
EBSCO – CINAHL (Cumulative Index to Nursing and Allied Health Literature)	1960–2015
Google Scholar	Inception-2014*
Ovid – EMBASE	1947–2015
Ovid – HMIC (Health Management Information Consortium)	1983–2014*
Ovid – MEDLINE	1946–2015
Ovid – MEDLINE In-Process and Other Non-Indexed Citations	2014–2015
Pubmed	2014*
Scopus	1960–2015
Web of Knowledge (science citation index expanded and conference proceedings citation index science)	1900–2015

* No yield so ceased searching during review update.

Appendix 2 Medline search strategy for systematic review of ENT injuries, signs, or symptoms in relation to child abuse or fabricated or induced illness

1. Exp Child/	46. Intra-alveolar hemorrhag*.mp.
2. Exp Child, Preschool/	47. Oronasal bleed*.mp.
3. Exp Adolescent/	48. Oronasal haemorrhag*.mp.
4. Exp Infant/	49. Oronasal hemorrhag*.mp.
5. Infant/or exp Infant, Newborn/	50. otalgia.mp.
6. (Child: or toddler: or baby or infant* or adolescent*:.).mp.	51. (Otitis adj3 extern*).mp.
7. 1 or 2 or 3 or 4 or 5 or 6	52. Otitis media.mp.
8. Exp Child Abuse/	53. Pharyngitis.mp.
9. exp Battered Child Syndrome/	54. oropharynx.mp.
10. Exp Shaken Baby Syndrome/	55. laryngopharynx.mp.
11. Exp Airway Obstruction/or exp Asphyxia/	56. Otorhinolaryng*.mp.
12. (Child abuse or battered child or battered baby or shaken baby or asphyxia or airway obstruction).mp.	57. Otolaryngo*.mp.
13. Suffocat*.mp.	58. paranasal sinus*.mp.
14. Asphxia*.mp.	59. Submandibular gland*.mp.
15. Nonaccidental injur*.mp.	60. Parotid gland*.mp.
16. non-accidental injur*.mp.	61. Palatine tonsil*.mp.
17. Nonaccidental trauma.mp.	62. (Bleed* adj3 ear*).mp.
18. Non-accidental trauma.mp.	63. (Caustic adj3 ear*).mp.
19. Soft tissue injur*.mp.	64. Hypopharynx*.mp.
20. Infanticide.mp.	65. Hypopharynx* perforat*.mp.
21. Abusive trauma.mp.	66. Perichondritis.mp.
22. (Child maltreatment or child protection).mp.	67. Animals/
23. (Child adj3 maltreatment).mp.	68. Animal stud*.mp.
24. (Child adj3 physical abuse).mp.	69. Exp "Review"/
25. child murder.mp.	70. Exp Child Abuse, Sexual/
26. Covert homicide.mp.	71. Sexual abuse.mp.
27. Child homicide.mp.	72. Allerg*.ti.
28. Exp Munchausen Syndrome by Proxy/	73. Surg*.ti.
29. Factitious disorder by proxy.mp.	74. Congenital.ti.
30. Fabricat* ill*.mp.	75. 67 or 68 or 69 or 70 or 71 or 72 or 73 or 74
31. Induc* ill*.mp.	76. Cohort*.tw.
32. Munchausen Syndrome by proxy.mp.	77. Controlled clinical trial.pt.
33. Unnatural death.mp.	78. Exp Epidemiologic Methods/
34. Exp Epistaxis/	79. Exp Case-Control Studies/
35. Exp Ear/	80. (Case\$ and control\$).tw.
36. exp Nose/	81. Exp case report/
37. Exp Pharynx/	82. (Case\$ and series).tw.
38. (Epistaxis or ear or nose or throat or pharynx).mp.	83. Exp case studies/
39. Nosebleed.mp.	84. Exp Cohort Studies/
40. Nose bleed.mp.	85. 8 or 9 or 10 or 11 or 12 or 13 or 14 or 15 or 16 or 17 or 18 or 19 or 20 or 21 or 22 or 23 or 24 or 25 or 26 or 27 or 28 or 29 or 30 or 32 or 33
41. (bleed* adj3 nose).mp.	86. 34 or 35 or 36 or 37 or 38 or 39 or 40 or 41 or 42 or 43 or 44 or 45 or 46 or 47 or 48 or 49 or 50 or 51 or 52 or 53 or 54 or 55 or 56 or 57 or 58 or 59 or 60 or 61 or 62 or 63 or 64 or 65 or 66
42. Nasal hemorrhage.mp.	87. 76 or 77 or 78 or 79 or 80 or 82 or 84
43. Nasal haemorrhage.mp.	88. 7 and 85 and 86 and 87
44. Nasal bleed*.mp.	89. 88 not 75
45. Intra-alveolar haemorrhag*.mp.	